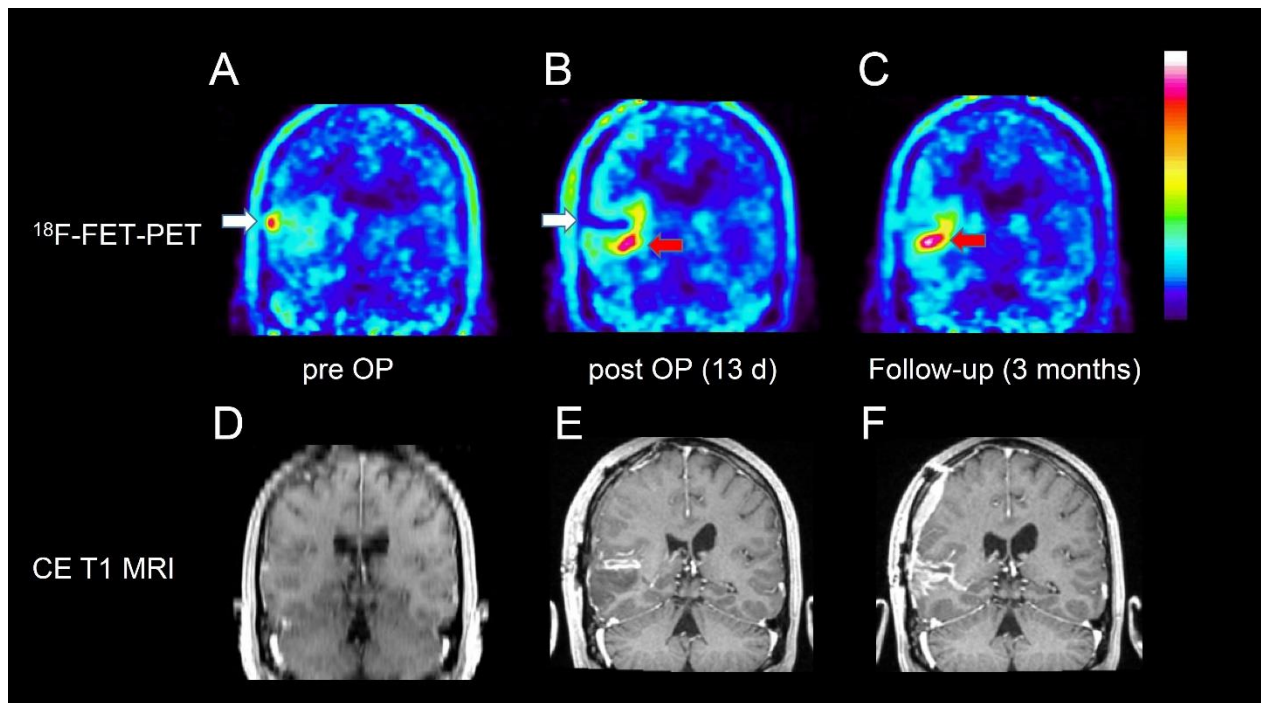


Supplemental Figure 1:



Coronal brain slices of a patient with temporal glioblastoma WHO grade IV in the right hemisphere (Pat. No 17): Pre-, postoperative, and follow-up ^{18}F -FET PET (A - C), and corresponding contrast-enhanced T1-weighted MRI (D - F). ^{18}F -FET PET after surgery (B) shows resection of the ^{18}F -FET positive area (white arrow) in the preoperative scan (A), but a flare phenomenon is noted medial to the resection cavity (red arrow). The follow-up PET after chemotherapy shows a progressive tumor in that area.