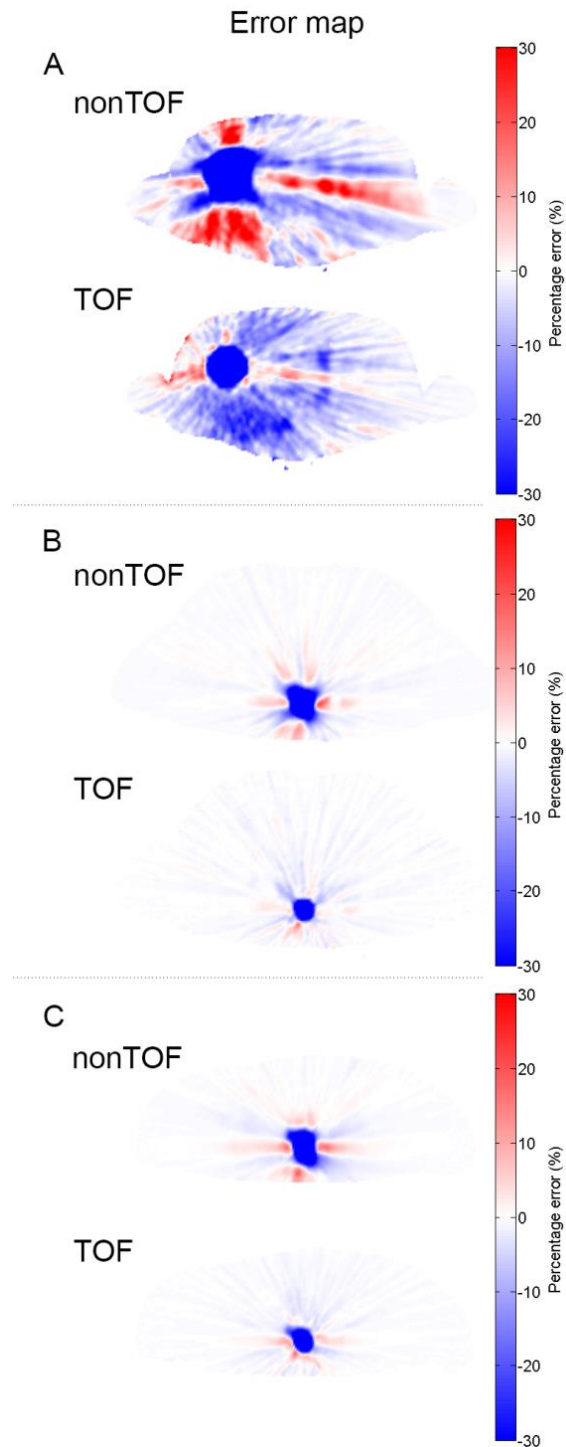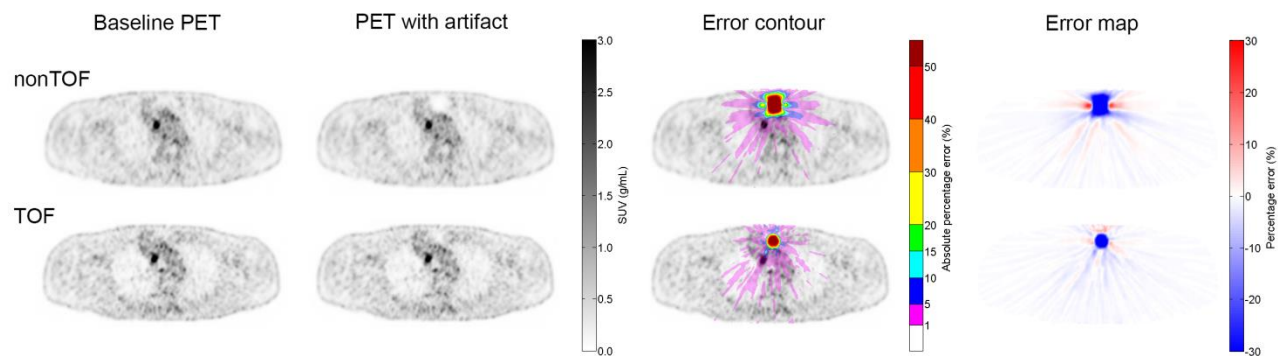


Supplemental Figure 1: Three examples of the percentage error map. A, B and C correspond to the three patient cases in Fig. 2.



Supplemental Figure 2: Example of a patient with multiple ^{18}F -FDG avid lesions and a simulated artifact in the sternum. Baseline PET images (first column), PET images reconstructed with a simulated metal artifact in the AC (second column), the absolute percentage error contour plot (third column), and the percentage error map (fourth column).