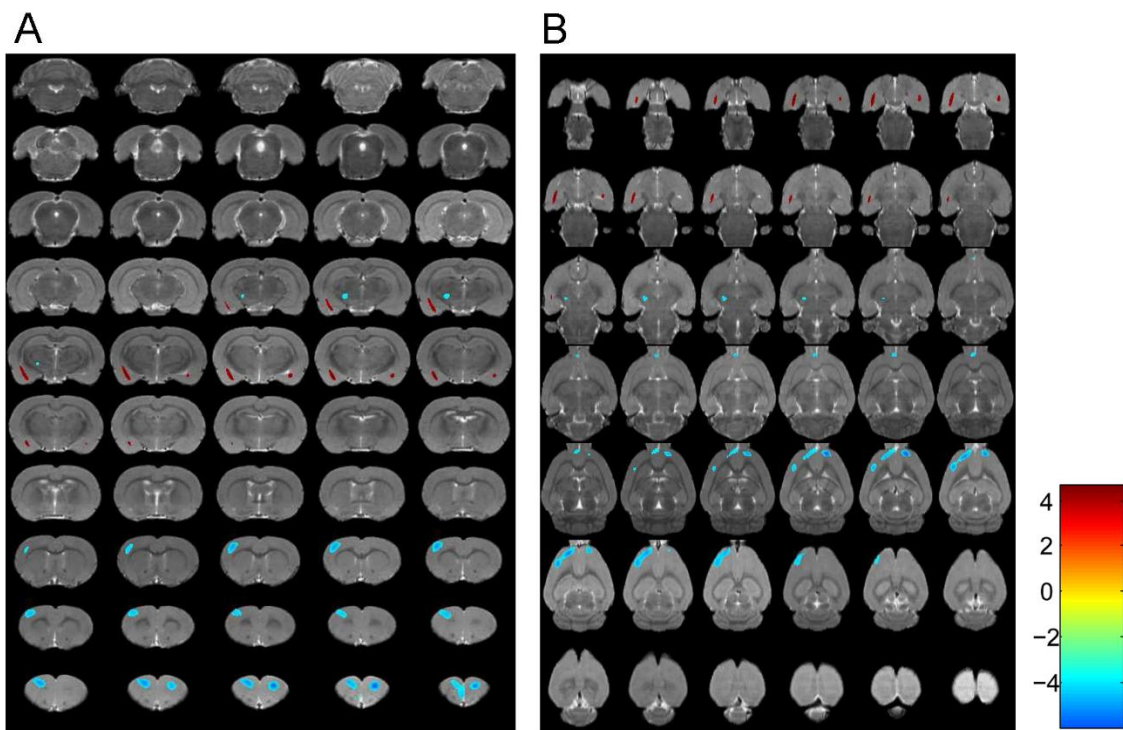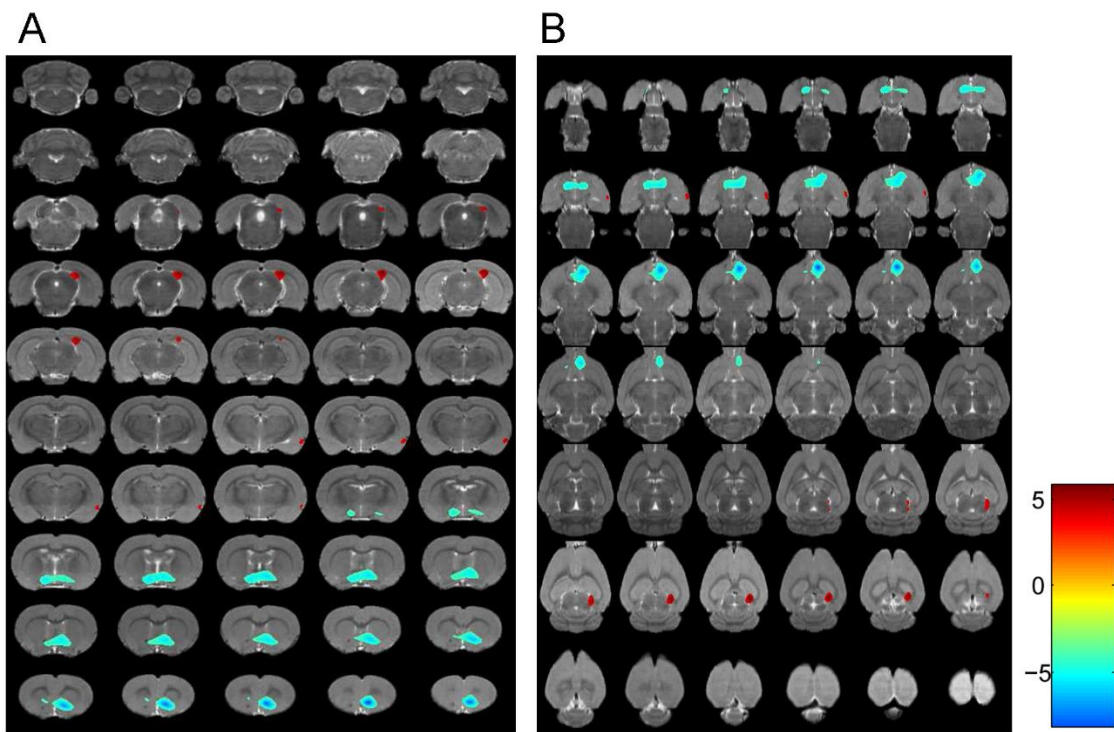


SUPPLEMENTAL FIGURE 1. Coronal (A) and transverse (B) PET images demonstrated significant changes of glucose metabolism under fear conditioning ($n = 8$, $P < 0.001$). Differences for brain regions have been color coded and are superimposed on MRI template.



SUPPLEMENTAL FIGURE 2. Coronal (A) and transverse (B) PET images demonstrated significant changes of glucose metabolism under extinction retrieval ($n = 8$, $P < 0.001$). Differences for brain regions have been color coded and are superimposed on MRI template.