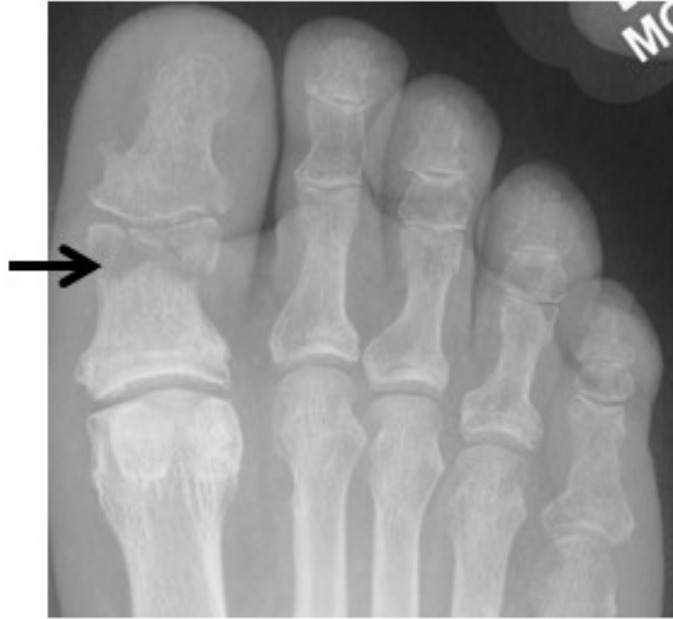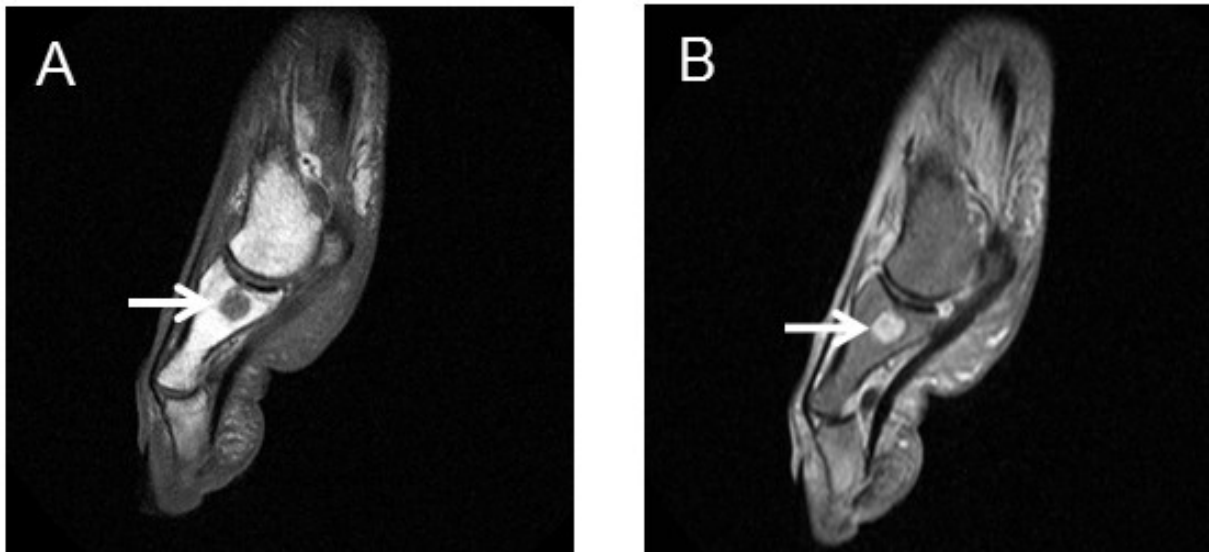




**Supplemental Figure 1.** Osteomyelitis of right great toe. There is cortical erosion (arrow) of the right proximal phalanx and a superimposed fracture extending laterally. (Image courtesy of T. Ali, MD.)

p



**Supplemental Figure 2.** Osteomyelitis of left great toe. There is decreased marrow signal (arrow) on the T1-weighted sagittal image (A) and increased marrow signal (arrow) on the T2-weighted sagittal image (B). (Image courtesy of T. Ali, MD.)