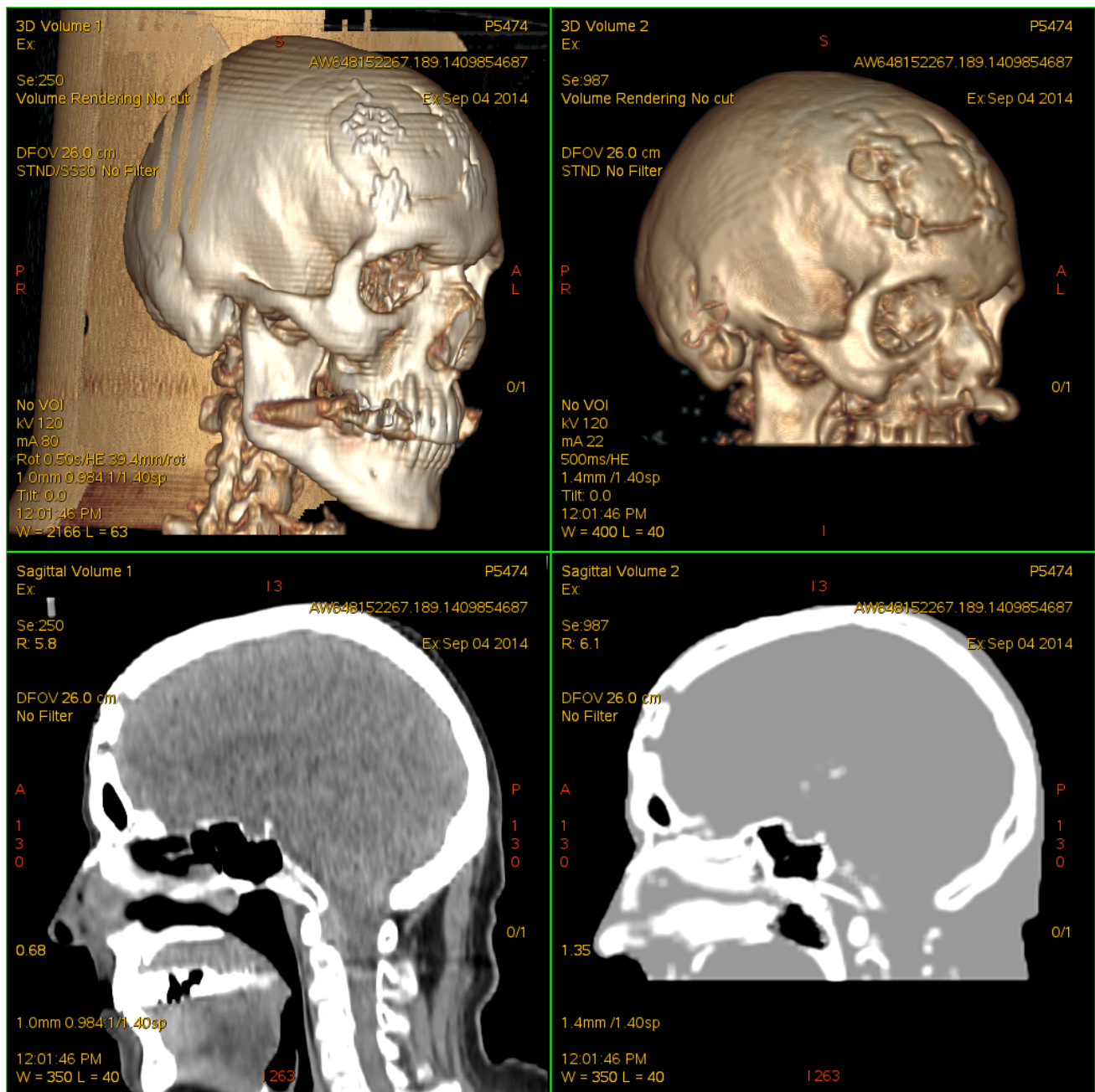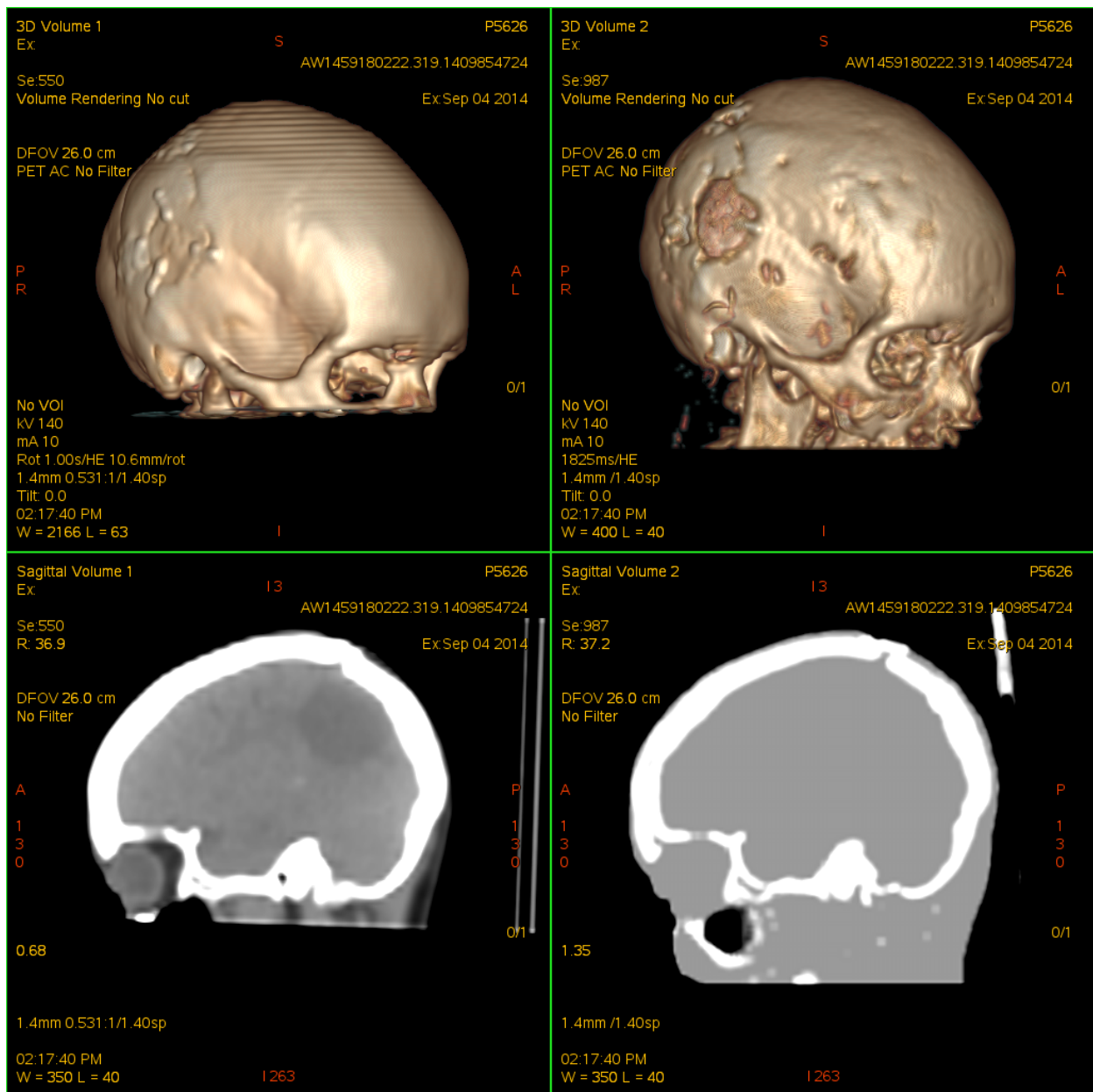


Supplemental Figure 1: Volume rendering and sagittal views of a CT dataset (left) and the corresponding segmented ZTE dataset (right). Notice craniotomy site.



Supplemental Figure 2: Volume rendering and sagittal views of a CT dataset (left) and the corresponding segmented ZTE dataset (right). Notice craniotomy site.