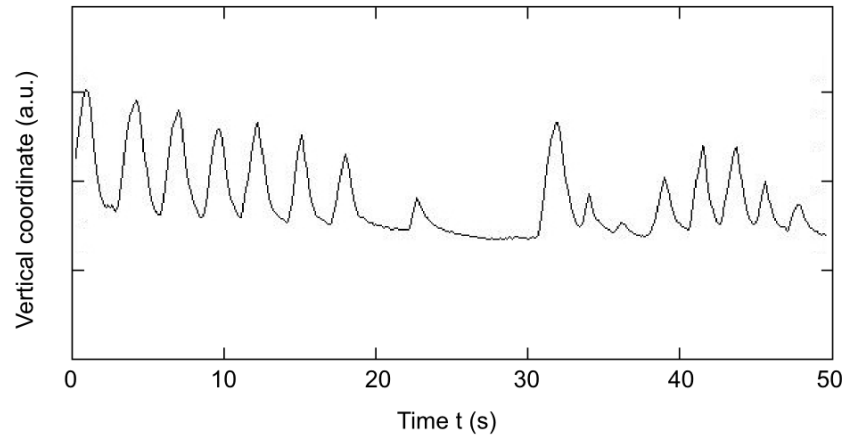
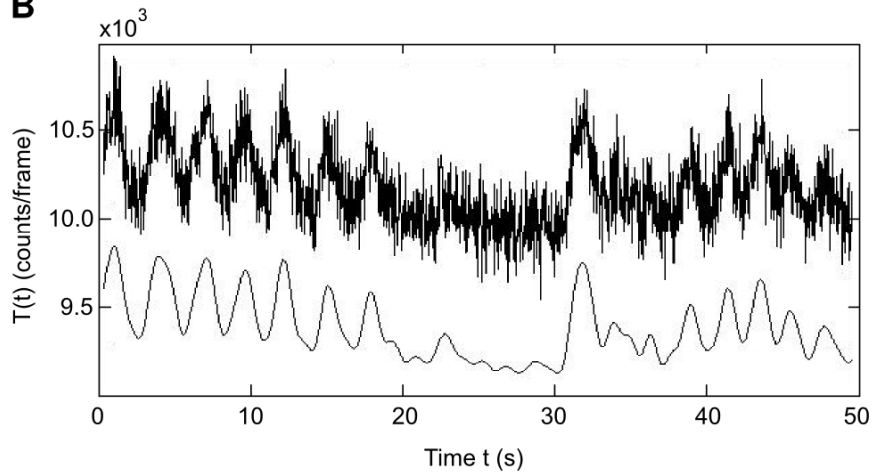


SUPPLEMENTAL FIGURE 1: Obtained respiratory curves of a typical patient scan using video method (VID) (A), sensitivity method (SENS) (B), and center-of-mass method (COM) (C). The upper and lower curves in B and C represent raw and filtered data, respectively. The smoothed curves are shifted for demonstration.

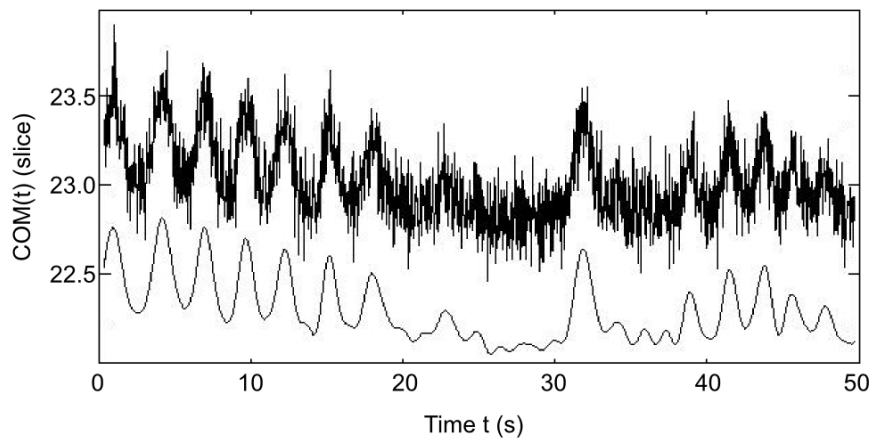
A



B



C



SUPPLEMENTAL FIGURE 2: Comparison of non-gated and gated (mid-inspiration) cardiac PET images in short axis and vertical long axis. The non-gated image shows motion blurring especially in the anterior ventricular wall. The profile plot was taken along the indicated arrow.

