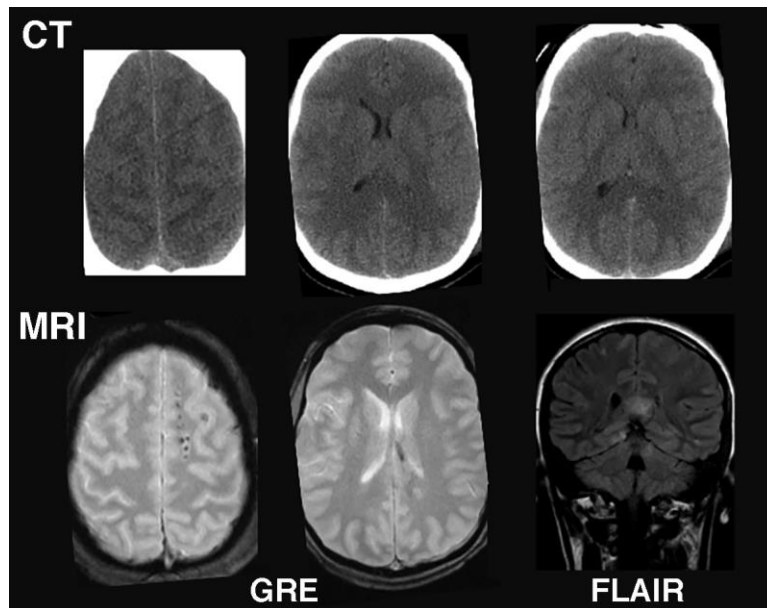


SUPPLEMENTAL FIGURE 1: MRI vs CT for imaging acute mild TBI: Example from a mild TBI patient in which CT (top row) was read as normal. However, a subsequent MRI (bottom row) shows multiple, small, elliptical "lesions" located in the white matter on the gradient echo (GRE) image and callosal hyperintensity on the Fluid-attenuated inversion recovery (FLAIR), indicating diffuse axonal injury.



Supplemental References

1. Graham NS, Sharp DJ. Understanding neurodegeneration after traumatic brain injury: from mechanisms to clinical trials in dementia. *J Neurol Neurosurg Psychiatry*. 2019;90:1221-1233.
2. Ng SY, Lee AYW. Traumatic Brain Injuries: Pathophysiology and Potential Therapeutic Targets. *Front Cell Neurosci*. 2019;13:528.
3. Yokobori S, Hosein K, Burks S, Sharma I, Gajavelli S, Bullock R. Biomarkers for the clinical differential diagnosis in traumatic brain injury--a systematic review. *CNS Neurosci Ther*. 2013;19:556-565.
4. Risling M, Smith D, Stein TD, et al. Modelling human pathology of traumatic brain injury in animal models. *J Intern Med*. 2019;285:594-607.
5. Saatman KE, Duhaime A-C, Bullock R, et al. Classification of traumatic brain injury for targeted therapies. *J Neurotrauma*. 2008;25:719-738.
6. Tagliaferri F, Compagnone C, Korsic M, Servadei F, Kraus J. A systematic review of brain injury epidemiology in Europe. *Acta Neurochir (Wien)*. 2006;148:255-268; discussion 268.
7. Cuthbert JP, Harrison-Felix C, Corrigan JD, et al. Epidemiology of adults receiving acute inpatient rehabilitation for a primary diagnosis of traumatic brain injury in the United States. *J Head*

Trauma Rehabil. 2015;30:122-135.

8. Stiell IG, Wells GA, Vandemheen K, et al. The Canadian CT Head Rule for patients with minor head injury. *Lancet.* 2001;357:1391-1396.
 9. Manolakaki D, Velmahos GC, Spaniolas K, de Moya M, Alam HB. Early magnetic resonance imaging is unnecessary in patients with traumatic brain injury. *J Trauma.* 2009;66:1008-1012; discussion 1012-1014.
 10. Smith DH, Hicks R, Povlishock JT. Therapy development for diffuse axonal injury. *J Neurotrauma.* 2013;30:307-323.
 11. McKee AC, Cantu RC, Nowinski CJ, et al. Chronic traumatic encephalopathy in athletes: progressive tauopathy after repetitive head injury. *J Neuropathol Exp Neurol.* 2009;68:709-735.
 12. Ramos-Cejudo J, Wisniewski T, Marmar C, et al. Traumatic Brain Injury and Alzheimer's Disease: The Cerebrovascular Link. *EBioMedicine.* 2018;28:21-30.
 13. Smith DH, Johnson VE, Stewart W. Chronic neuropathologies of single and repetitive TBI: substrates of dementia? *Nat Rev Neurol.* 2013;9:211-221.
 14. Katz DI, Bernick C, Dodick DW, et al. National Institute of Neurological Disorders and Stroke Consensus Diagnostic Criteria for Traumatic Encephalopathy Syndrome. *Neurology.* 2021;96:848-863.
 15. Blennow K, Brody DL, Kochanek PM, et al. Traumatic brain injuries. *Nat Rev Dis Primers.* 2016;2:16084.
 16. Corps KN, Roth TL, McGavern DB. Inflammation and neuroprotection in traumatic brain injury. *JAMA Neurol.* 2015;72:355-362.
 17. Hoge CW, McGurk D, Thomas JL, Cox AL, Engel CC, Castro CA. Mild Traumatic Brain Injury in U.S. Soldiers Returning from Iraq. *N Engl J Med.* 2008;358:453-463.
 18. Bryden DW, Tilghman JJ, Hinds SR. Blast-Related Traumatic Brain Injury: Current Concepts and Research Considerations. *J Exp Neurosci.* 2019;13:1179069519872213.
 19. Nadel J, McNally JS, DiGiorgio A, Grandhi R. Emerging Utility of Applied Magnetic Resonance Imaging in the Management of Traumatic Brain Injury. *Med Sci (Basel).* 2021;9:10.
 20. Trifan G, Gattu R, Haacke EM, Kou Z, Benson RR. MR imaging findings in mild traumatic brain injury with persistent neurological impairment. *Magn Reson Imaging.* 2017;37:243-251.
 21. Shenton ME, Hamoda HM, Schneiderman JS, et al. A review of magnetic resonance imaging and diffusion tensor imaging findings in mild traumatic brain injury. *Brain Imaging Behav.* 2012;6:137-192.
 22. Petrie EC, Cross DJ, Yarnykh VL, et al. Neuroimaging, behavioral, and psychological sequelae of repetitive combined blast/impact mild traumatic brain injury in Iraq and Afghanistan war veterans. *J Neurotrauma.* 2014;31:425-436.
 23. Smith LGF, Milliron E, Ho M-L, et al. Advanced neuroimaging in traumatic brain injury: an overview. *Neurosurg Focus.* 2019;47:E17.
 24. Lin AP, Liao HJ, Merugumala SK, Prabhu SP, Meehan WP, Ross BD. Metabolic imaging of mild traumatic brain injury. *Brain Imaging Behav.* 2012;6:208-223.
 25. Brown M, Baradaran H, Christos PJ, Wright D, Gupta A, Tsiouris AJ. Magnetic resonance spectroscopy abnormalities in traumatic brain injury: A meta-analysis. *J Neuroradiol.* 2018;45:123-129.
 26. Skibsted AP, Amiri M, Fisher PM, et al. Consciousness in Neurocritical Care Cohort Study Using fMRI and EEG (CONNECT-ME): Protocol for a Longitudinal Prospective Study and a Tertiary Clinical Care Service. *Frontiers in Neurology.* 2018;9.
 27. Yin Z, Romano AJ, Manduca A, Ehman RL, Huston J. Stiffness and beyond: what MR elastography can tell us about brain structure and function under physiologic and pathologic conditions. *Top Magn Reson Imaging.* 2018;27:305-318.
 28. Underhill HR, Rostomily RC, Mikheev AM, Yuan C, Yarnykh VL. Fast Bound Pool Fraction Imaging of the In Vivo Rat Brain: Association with Myelin Content and Validation in the C6 Glioma Model. *Neuroimage.* 2011;54:2052-2065.
- Annu Rev Neurosci.* 2017;40:189-210.