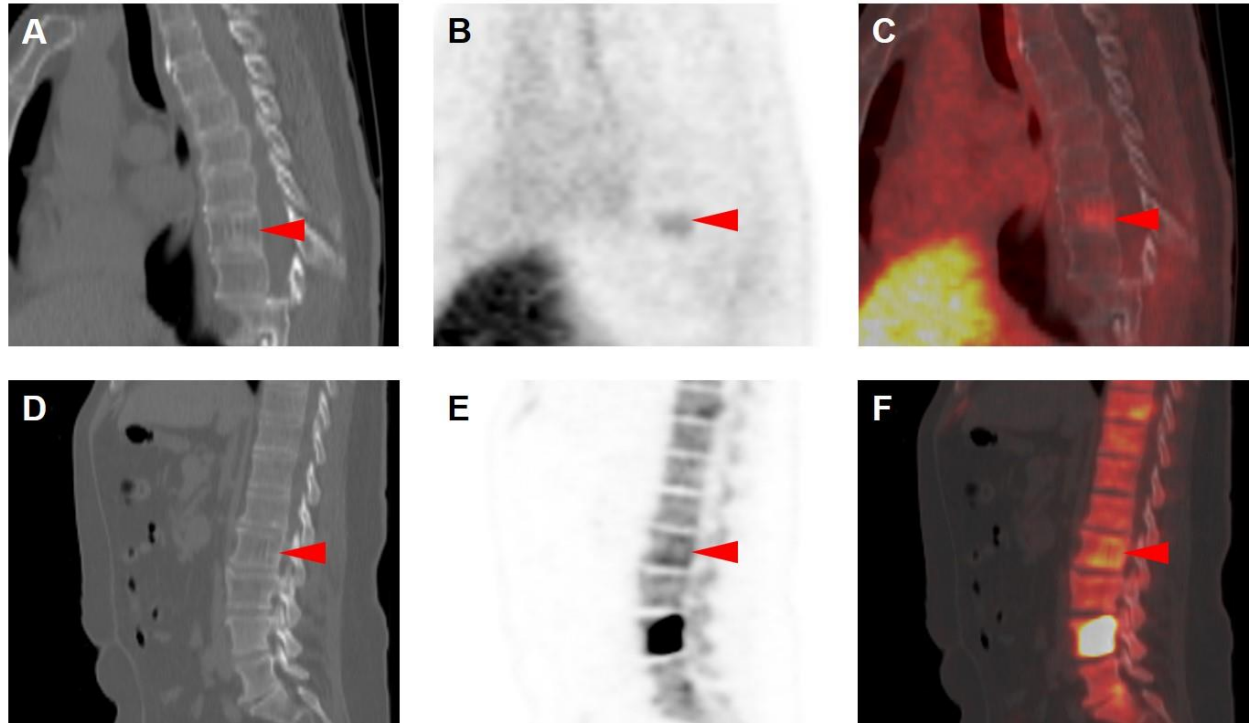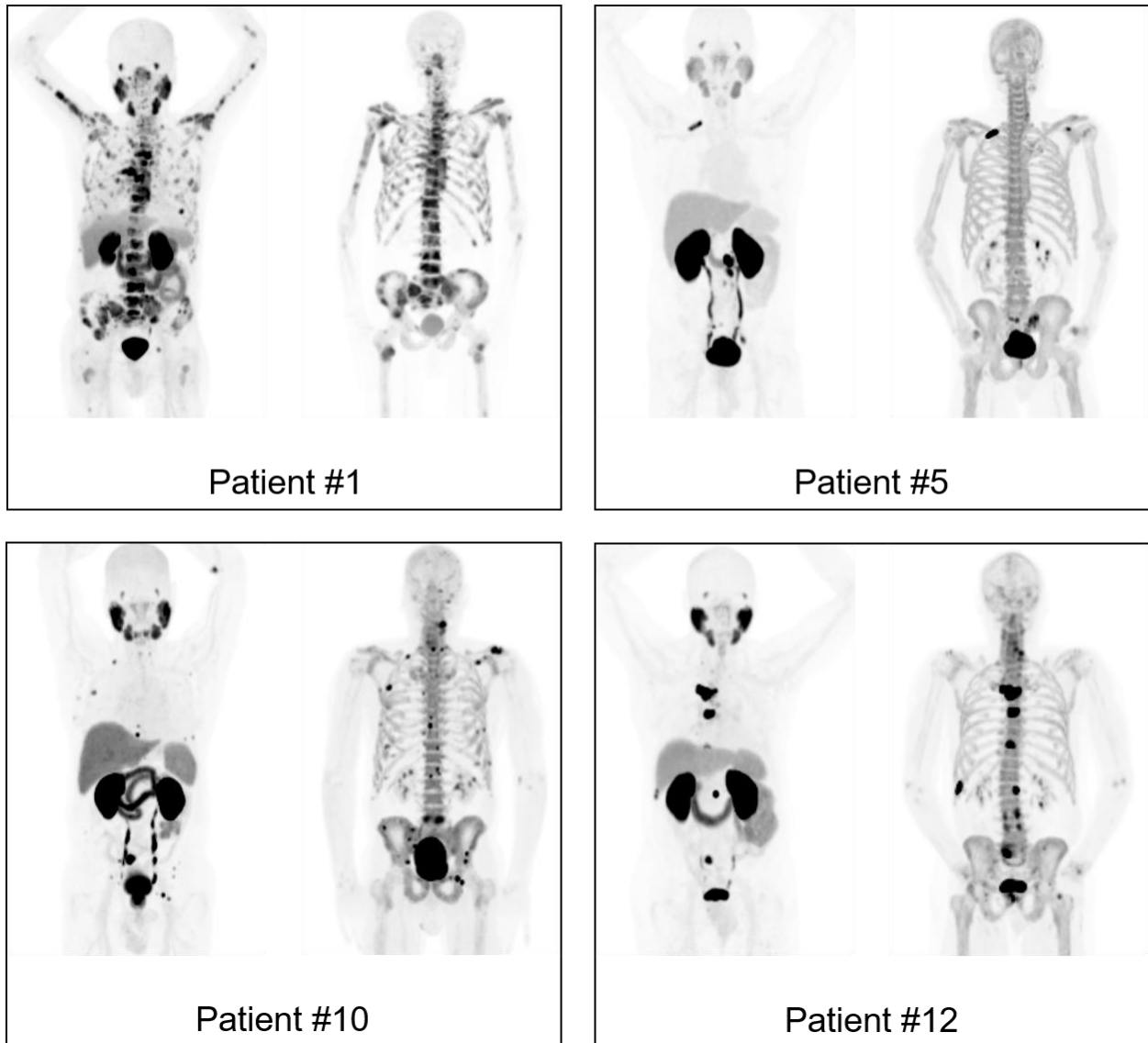


**Supplemental Figure 1.** Benign findings with uptake detected on  $^{18}\text{F}$ -DCFPyL and  $\text{Na}^{18}\text{F}$  PET/CT. (A) Sagittal CT, (B) sagittal  $^{18}\text{F}$ -DCFPyL PET, and (C) sagittal  $^{18}\text{F}$ -DCFPyL PET/CT images through the thoracic spine show radiotracer uptake in a spinal hemangioma (red arrowheads). (D) Sagittal CT, (E) sagittal  $\text{Na}^{18}\text{F}$  PET, and (C) sagittal  $\text{Na}^{18}\text{F}$  PET/CT images show similar uptake in a spinal hemangioma of another patient (red arrowheads). It is important for readers of these imaging modalities to correctly characterize these lesions and to not record them as (false) positive findings. These lesions were not included in the analysis of this patient cohort.



**Supplementary Figure 2.** Representative comparison MIP images from the  $^{18}\text{F}$ -DCFPyL and  $\text{Na}^{18}\text{F}$  PET studies on patients from this study. Note the overall high level of concordance of sites of abnormal skeletal uptake. Patient #1, who was undergoing treatment with Sipuleucel-T at the time of imaging, had findings of extensive bone metastatic disease on both scans, with the majority of lesions showing concordant uptake. Patient #5, who was undergoing treatment with abiraterone, had limited bone disease that demonstrated uptake on both scans, as well as adenopathy better-characterized by

<sup>18</sup>F-DCFPyL PET. Patient #10, who was off therapy at the time of imaging, had multiple, generally small-volume, sites of bone metastatic disease that were nearly entirely concordant on the two PET scans. Lastly, patient #12, who was on treatment with bicalutamide at the time of imaging, had a smaller number of larger-volume sites of bone metastatic disease in comparison to patient #10, although again the two PET scans demonstrated predominantly concordant results.

**Supplementary Table 1.** Selected demographic and clinical data from the patients included in this study.

Age	Race	Gleason	PSA (ng/mL)	Testosterone (ng/dL)	Current or Recent Therapy
77	White	7	224.5	<20.0	Sipuleucel-T
64	White	8	2.6	147	None
75	White	9	1.2	<20.0	Leuprorelin, Bicalutamide
69	White	7	0.2	<20.0	Abiraterone
54	White	8	6.2	<20.0	Abiraterone
67	White	9	1.43	<20.0	Leuprorelin
70	White	8	7.3	<20.0	Leuprorelin, SBRT to pelvis ending 3 months prior
59	White	9	65	25.3	Leuprorelin 45mg 2 months prior, Radiation ending 2 months prior
54	White	8	5.5	<20.0	Leuprorelin
59	White	9	5.9	365	None
70	White	9	3.2	<20.0	Discontinued testosterone replacement
79	African American	7	9	376	Bicalutamide
73	White	7	2.9	<20.0	Triptorelin Pamoate 4 months prior, 4 Cycles of Docetaxel ending 2 months prior
62	White	7	2.33	540	Bicalutamide ending 3 months prior
52	Hispanic/Latino	9	5.97	1025	Bicalutamide
68	White	7	3.16	<20.0	Sipuleucel-T ending 5 months prior, Ipilimumab ending 2 months prior

**Supplementary Table 2.** Patient-level findings on  $^{18}\text{F}$ -DCFPyL PET/CT and  $\text{Na}^{18}\text{F}$  PET/CT.

Patient	Definitively Positive Uptake on $^{18}\text{F}$ -DCFPyL PET/CT	Equivocally Positive Uptake on $^{18}\text{F}$ -DCFPyL PET/CT	Negative for Uptake on $^{18}\text{F}$ -DCFPyL PET/CT	Definitively Positive Uptake on $\text{Na}^{18}\text{F}$ PET/CT	Equivocally Positive Uptake on $\text{Na}^{18}\text{F}$ PET/CT	Negative for Uptake on $\text{Na}^{18}\text{F}$ PET/CT
#1	158	0	2	153	0	7
#2	10	0	0	8	0	2
#3	1	0	0	1	0	0
#4	1	1	0	2	0	0
#5	2	0	0	2	0	0
#6	Patient excluded from imaging analysis because of refusal to undergo $\text{Na}^{18}\text{F}$ PET imaging.					
#7	8	2	6	13	3	0
#8	155	0	0	154	0	1
#9	1	1	0	2	0	0
#10	35	0	0	34	1	0
#11	4	0	1	5	0	0

#12	9	0	0	8	0	1
#13	1	0	0	1	0	0
#14	3	0	0	2	0	1
#15	2	0	1	3	0	0
#16	1	0	0	0	0	1