

Incidental focal 68Ga-FAPI-46 uptake in a urachal remnant: a potential pitfall mimicking a malignant peritoneal lesion.

Authors:

Peter George Maliha¹

Mahbod Jafarvard¹

Johannes Czernin¹

Calais, Jeremie¹

Masatoshi, Hotta¹

Affiliation:

1. Ahmanson Translational Theranostics Division, Department of Molecular & Medical Pharmacology, University of California, Los Angeles, USA

Corresponding author:

Peter George Maliha
pmaliha@mednet.ucla.edu
(310)628-5542

ORCID-ID: [0000-0002-9811-3980](https://orcid.org/0000-0002-9811-3980)

Financial disclosures: None

Word count: 498 words

CASE PRESENTATION:

A 75-year-old man who was scheduled for resection of a left upper back lipomatous lesion underwent a pre-operative ⁶⁸Ga-fibroblast activation protein inhibitor (⁶⁸Ga-FAPI)-46 PET/CT scan as part of a prospective study (NCT04147494). The ⁶⁸Ga-FAPI-46 PET/CT images revealed an incidental small focus of FAPI uptake (SUVmax 4.1) in a 0.8 x 0.7 x 1.2 cm cystic structure in the inferior third of a urachus remnant (Fig. 1). There was no FAPI uptake in the remainder of the urachus remnant. A prior ¹⁸F-fluorodeoxyglucose (¹⁸F-FDG) PET/CT study with IV CT contrast performed 4 years and 1 month before was retrospectively reviewed. There was incomplete obliteration of the urachus with a cystic structure in its inferior third, consistent with a urachus remnant, and it had no FDG uptake. The urachal remnant and cystic structure on ⁶⁸Ga-FAPI-46 PET/CT were anatomically stable to the reviewed ¹⁸F-FDG PET/CT and on a subsequent follow-up CT performed 1 year and 3 months later, suggesting a benign etiology. Differential diagnosis included a FAPI(+)/FDG(-) urachal cyst due to fibrosis and a urachal diverticulum intermittently accumulating urine-excreted radiotracer.

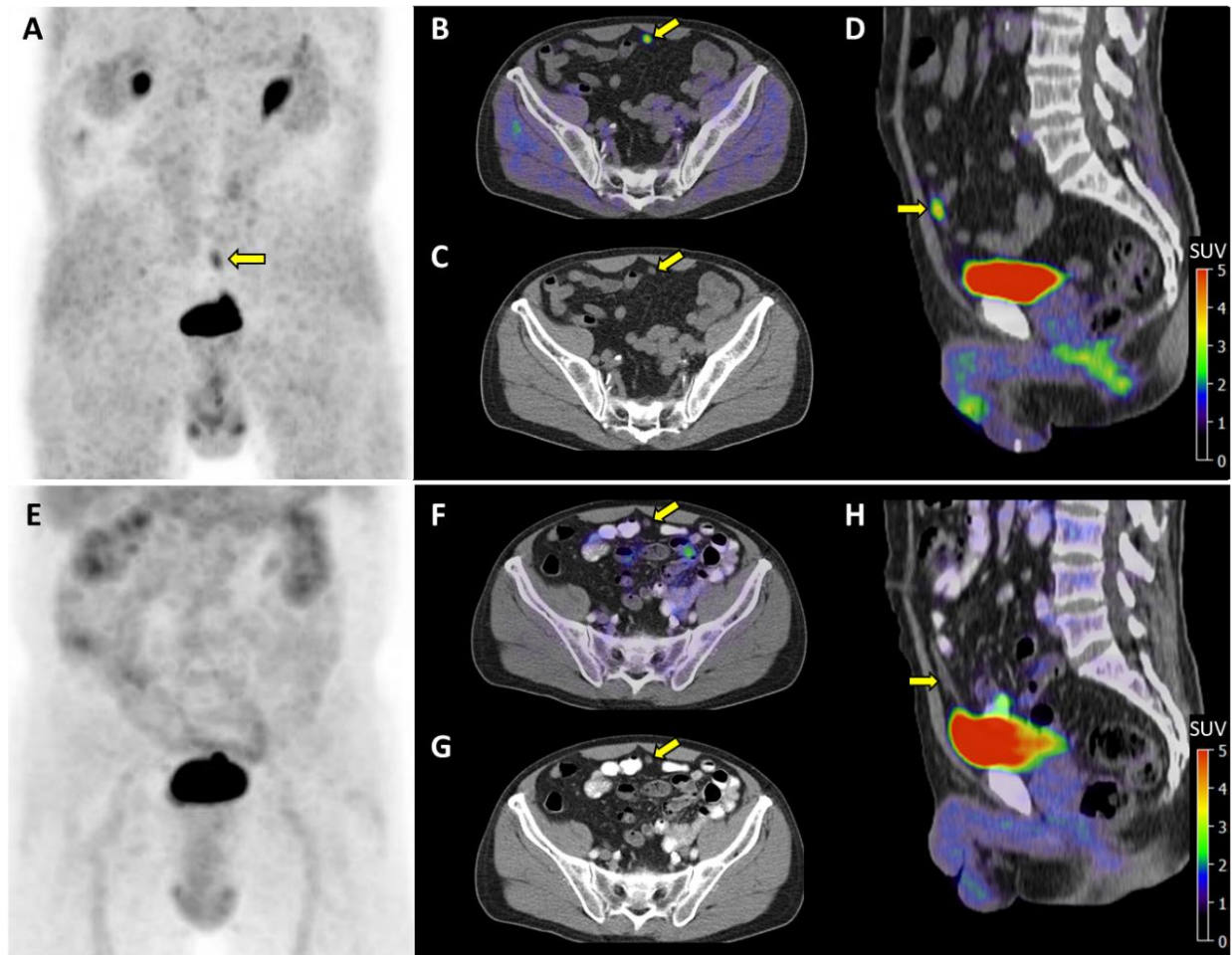


Figure 1. Maximum intensity projection, axial (fused, CT), and sagittal of ^{68}Ga -FAPI-46 PET/CT (top, A-D) and ^{18}F -FDG-PET/CT (bottom, E-H) images demonstrating mild FAPI uptake (SUVmax 4.1) and absent FDG uptake in a cystic structure of a urachal remnant (arrows).

DISCUSSION:

The urachus is an embryological structure connecting the umbilicus to the bladder. Normally, it obliterates to become the medial umbilical ligament. Very rarely, it does not and remnant urachal anomalies persist into adulthood ¹. Of these anomalies, a cystic structure can remain between the umbilicus and the bladder.

Several studies suggest that FAPI PET/CT has a promising role in the detection of peritoneal metastases in various malignancies, notably due to low physiological bowel uptake ²⁻⁴. The above-described FAPI PET signal in urachal remnant should be a potentially known false positive pitfall in that region.

DISCLOSURES:

"No potential conflicts of interest relevant to this article exist."

REFERENCES:

1. Wilson AL, Gandhi J, Seyam O, et al. Urachal anomalies: A review of pathological conditions, diagnosis, and management. *Translational Research in Anatomy*. 2019;16:100041.
2. Veldhuijzen van Zanten SEM, Pieterman KJ, Wijnhoven BPL, et al. FAPI PET versus FDG PET, CT or MRI for staging pancreatic-, gastric- and cholangiocarcinoma: systematic review and head-to-head comparisons of diagnostic performances. *Diagnostics (Basel)*. 2022;12:1958.
3. Guo W, Chen H. (68)Ga FAPI PET/CT imaging in peritoneal carcinomatosis. *Radiology*. 2020;297:521.
4. Meyer C, Dahlbom M, Lindner T, et al. Radiation dosimetry and biodistribution of (68)Ga-FAPI-46 PET imaging in cancer patients. *J Nucl Med*. 2020;61:1171-1177.