

Dual Positron Emission Tomography imaging in bronchial neuroendocrine neoplasms (NENs): The NETPET score as a prognostic biomarker

David L Chan^{1,2}, Gary A Ulaner³, David Pattison^{4,5}, David Wyld^{5,6}, Rahul Ladwa^{5,6}, Julian Kirchner³, Bob T Li⁷, W. Victoria Lai⁷, Nick Pavlakis^{1,2}, Paul J Roach^{8,9}, Dale L Bailey^{8,9,10}

1. Department of Medical Oncology, Royal North Shore Hospital, St Leonards, New South Wales, Australia

2. Bill Walsh Translational Cancer Research Laboratory, Kolling Institute, University of Sydney, Australia

3. Department of Radiology, Memorial Sloan Kettering Cancer Center, New York, New York, USA

4. Department of Nuclear Medicine, Royal Brisbane and Women's Hospital, Herston, Queensland, Australia

5. School of Medicine, University of Queensland, Australia

6. Department of Medical Oncology, Royal Brisbane and Women's Hospital, Herston, Queensland, Australia

7. Department of Thoracic Oncology, Memorial Sloan Kettering Cancer Center, New York, New York, USA

8. Department of Nuclear Medicine, Royal North Shore Hospital, St Leonards, New South Wales, Australia

9. Faculty of Medicine and Health, University of Sydney, Australia

10. Sydney Vital Translational Cancer Research Centre, Sydney New South Wales, Australia

Keywords: Neuroendocrine tumor, FDG PET, DOTATATE PET, NETPET, biomarker

Running head: NETPET score in lung NEN

Corresponding author: David L Chan, Northern Sydney Cancer Centre, Royal North Shore Hospital, St Leonards, NSW 2065, Australia. T: +61294631172 F: +61294631092 E: David.chan@sydney.edu.au

Word count: 2618 (3 figures, 5 tables)

Financial support: National Health and Medical Research Council (APP175788)

Abstract

Background: PET scans using [¹⁸F]FDG and somatostatin receptor imaging agents are both used in imaging of neuroendocrine neoplasms (NENs). We have suggested the “NETPET score”, utilizing uptake of both PET tracers, as a prognostic biomarker in NENs. We previously demonstrated the effectiveness of the NETPET score in gastroenteropancreatic (GEP) NENs. Its prognostic relevance in bronchial NENs remains undetermined.

Methods: This is a retrospective multicentre study (2011-2018) assessing patients who had advanced bronchial NEN and who underwent both [¹⁸F]FDG and [⁶⁸Ga]Ga-DOTATATE PET within 60 days of each other. The NETPET score was assigned by experienced nuclear medicine physicians and compared with other clinical data such as WHO grade. The primary outcome was overall survival (OS); NETPET score and other prognostic variables were analysed using univariate and multivariate analyses by the Cox proportional-hazards model.

Results: Thirty-eight patients were included for review. The NETPET score and histology were significantly correlated with OS in univariate analyses ($p=0.003$, $p=0.01$). On multivariate analysis, only the NETPET score remained significant ($p=0.03$). The NETPET score was significantly associated with histological grade ($p=0.006$, chi-squared test).

Conclusion: The NETPET score is a prognostic biomarker in bronchial NENs as well as GEPNENs. Whilst it needs to be validated in prospective studies, it holds significant promise as a biomarker for a wide range of NENs.

Introduction

Neuroendocrine neoplasms (NENs) are a heterogeneous group of tumours which may secrete bioactive peptides. Whilst uncommon, they are increasing in incidence[1,2]. They can arise in different parts of the body, most commonly in the gastrointestinal tract, pancreas and lung. Whilst they vary considerably in biological behaviour, surgical resection is the only cure, and patients with high grade metastatic NEN have a very guarded prognosis [3]. Tumours in the gastrointestinal (GI) tract and pancreas are known collectively as gastroenteropancreatic NENs (GEPNENs). Bronchial NENs are often considered separately, and have a different classification system to GEPNENs [4,5]. Bronchial NENs have a differing genetic basis to GEPNENs and may also exhibit different clinical behaviour, with a median overall survival comparable to pancreatic NEN but inferior to that of small bowel NEN[6–8]. Treatment for patients with advanced bronchial NENs tends to be extrapolated from GEPNENs due to a lack of prospective trials in this subgroup. For instance, the only systemic treatment for bronchial NENs supported by phase III trial evidence is everolimus[9], whereas such evidence exists in various GEPNENs for somatostatin analogues, everolimus, sunitinib and peptide receptor radionuclide therapy (PRRT) [10–13].

Clinicians find it challenging to predict prognosis and select optimal systemic therapies in metastatic NEN due to the widely variant biological aggressiveness of different NENs. Whilst histological grade can predict disease behaviour to some extent, grade may be inaccurately measured in small biopsies, may vary in different metastatic sites, and may also evolve over time. Tissue- and blood-based biomarkers have been suggested, but few have been validated prospectively[14]. Positron Emission Tomography (PET) imaging has been increasingly used to image NENs and even to guide optimal choice of systemic therapies. It is recognised that somatostatin receptor-based radiotracers (such as [⁶⁸Ga]Ga-DOTATATE PET) highlights well-differentiated NEN cells which express the somatostatin receptor (SSTR). Conversely, avidity on [¹⁸F]FDG (FDG) PET as well as high metabolic tumour volume predict aggressive tumour biology and poorer prognosis[15–18]. The distribution and intensity of SSTR

expression measured by [⁶⁸Ga]Ga-DOTATATE PET, together with the absence of sites of discordant [¹⁸F]FDG avid disease, also provides a theranostic role by confirming suitability for treatment with PRRT. In a similar fashion to NEN treatment, much of the data regarding PET imaging in NENs has been extrapolated from publications concerning GEPNENs.

Given the different roles of these two scans, we proposed a system to interpret the complementary findings of the two scans – the NETPET score [19]. This score was investigated in a group of predominantly GEPNEN patients, showed prognostic significance independent of histological grade, and was subsequently validated in two other patient cohorts [20,21]. As the prognostic impact of the NETPET score had not been formally investigated in bronchial NENs, we aimed to measure this impact in a retrospective study.

Methods

This was a multicentre retrospective study conducted in Australia (Royal North Shore Hospital, Sydney and Royal Brisbane and Women's Hospital, Brisbane), and the USA (Memorial Sloan Kettering Cancer Center, New York, New York). Subjects aged 18 or above with histologically confirmed, advanced (unresectable and/or metastatic) NENs originating from the lung were eligible. All NEN histologies (typical carcinoid, atypical carcinoid, large cell and small cell neuroendocrine carcinoma) were included. Other pathologies (e.g. adenocarcinoma, squamous cell carcinoma) were excluded.

Searches of each site's nuclear medicine database were conducted. All patients fulfilling the above criteria who underwent [⁶⁸Ga]Ga-DOTATATE and [¹⁸F]FDG PET imaging within 60 days of each other with no local or systemic therapy in between the two scans were included. In case of multiple pairs of eligible scans in the same individual, the earliest pair acquired after diagnosis of advanced disease was chosen.

Imaging

Image data were acquired on PET/CT scanners at each institution. All image data were acquired on current generation PET/CT scanners with Time-of-Flight (ToF), scatter correction and point spread function resolution recovery (UltraHD) capabilities (RNSH – Biograph mCT.S/64 PET/CT, Siemens Healthcare, Hoffman Estates, USA. RBWH - Biograph mCT.S/128 PET/CT, Siemens Healthcare, Hoffman Estates, USA MSKCC – GE PET/CT 690 or 710). Data were typically acquired as whole body scans (top of skull to mid-thigh), usually requiring 6-8 bed positions in step-and-shoot mode.

For the [⁶⁸Ga]Ga-DOTATATE PET scans, the patients were injected with 120-200MBq of [⁶⁸Ga]-DOTA-(Tyr3)-octreotate with imaging commencing approximately 45-60 minutes after injection with whole body low-dose CT followed by the PET acquisition of 120-180 secs/bed. Subjects were advised to cease somatostatin analogues four weeks prior to the scan.

For the [¹⁸F]FDG scans, patients were required to fast for at least 6 hours prior to the scan and blood glucose levels were checked to ensure they were within the range of 4-11 mmol/L. Subjects were administered [¹⁸F]FDG in the range 250-450MBq.¹ according to standard institutional protocols At approximately 60 minutes after injection of the [¹⁸F]FDG scanning commenced with whole body low-dose CT followed by the PET acquisition of 120-150 secs/bed.

Image analysis

Scans were graded subjectively by visual interpretation on dedicated nuclear medicine reporting workstations. Interpretation was undertaken by experienced nuclear medicine physicians at each site (RNSH – PR, EB; RBWH – DP; MSKCC – GU, JK). Both scans were displayed simultaneously in transverse, coronal and sagittal planes accompanied by a maximal intensity projection (MIP) of the PET data, with both image sets anatomically co-registered. The scans were initially windowed with preset

¹ The administered dose of [¹⁸F]FDG at each institution was as follows: RNSH – 250MBq if patient weight under 90kg and 300MBq if over 90kg; RBWH – 4.5MBq/kg up to a maximum of 350MBq; MSKCC – 444MBq (+- 10%).

SUV values of 0-15 for [⁶⁸Ga]Ga-DOTATATE PET and 0-7 for [¹⁸F]FDG PET, as these were the values used for reporting in clinical practice. The readers had full access to all software tools in the reporting software. Positivity on [¹⁸F]FDG and [⁶⁸Ga]Ga-DOTATATE scans was defined as uptake greater than that regarded as physiological for the organ/tissue in question on the respective scan.

All readers underwent initial training with a standardised data set of 10 NEN cases (taken from the initial NETPET study) prior to commencing grading. According to our prior study, scoring was focussed on the most “discordant” lesion on dual PET. (Fig.1) A score of P5 was assigned if there was significant [¹⁸F]FDG avid, [⁶⁸Ga]Ga-DOTATATE non-avid disease. A score of P2-4 corresponded with the presence of [¹⁸F]FDG avid, [⁶⁸Ga]Ga-DOTATATE avid disease in any of the lesions, with the exact score dependent on the relative avidity on [¹⁸F]FDG and [⁶⁸Ga]Ga-DOTATATE PET. P1 denoted [⁶⁸Ga]Ga-DOTATATE but not [¹⁸F]FDG avidity in all lesions; P0 denoted neither [⁶⁸Ga]Ga-DOTATATE nor [¹⁸F]FDG avidity (Table 1).

Clinicopathological data

Chart review was performed on included patients to extract demographic and prognostic data (including primary site and histological grade). Outcomes included overall survival (OS) and progression-free survival (PFS), defined as a composite of RECIST-defined radiological progression, commencement of another systemic therapy after the index scan, and death. [22] The primary outcome was overall survival, measured in days from the latter of the two paired PET scans to the date of death or last follow-up.

Statistical analysis

Patient demographics were presented descriptively. For survival analysis, included patients were separated into three cohorts – P1, P2-4 and P5 – in the same fashion as the original NETPET study[19]. Patients with P2, P3 and P4 findings were grouped together as there is no consensus regarding exact quantitative cutoffs to separate patients who have lesions exhibiting more [⁶⁸Ga]Ga-DOTATATE than [¹⁸F]FDG avidity from those with more [¹⁸F]FDG than [⁶⁸Ga]Ga-DOTATATE avidity. Patients with P0 disease were noted but excluded from this analysis (the authors considered that this was an uncommon finding from their clinical experience). Survival outcomes in the different cohorts were compared using the log-rank test. Univariate and multivariate regression was performed using the Cox proportional hazards model with the following variables: age, presence/absence of distant extrahepatic disease, histological grade and NETPET score. Histological grade was divided into three groups: i) Typical carcinoid, ii) atypical carcinoid, and iii) those with large cell/small cell neuroendocrine carcinoma. Other potential prognostic markers (most pertinently the mitotic count and Ki-67 index) were not included in multivariate analysis due to the potential for introducing collinear factors into multivariate analysis. We conducted sensitivity analyses to determine the value of replacing histological grade by the Ki-67 index for OS analyses. Finally, the correlation between NETPET score and histological grade (as well as NETPET score and Ki-67 index) was analysed using the chi-squared test.

Ethics approval

This study was approved by the Northern Sydney Local Health District Human Research Ethics Committee, 2019/ETH09817, and relevant local ethics committees for each participating site. The requirement to obtain informed consent for this retrospective study was waived.

Results

Thirty-eight patients were included in this study from three sites. Female patients comprised 61% of the cohort, and the median age was 66 years (Table 2). The median time from histological diagnosis to PET imaging was 13 months (range 1-151). Treatments prior to PET imaging included SSAs (18% of patients), chemotherapy (26%) and PRRT (5%). Treatment after PET imaging included SSAs (24%), chemotherapy (45%) and PRRT (37%). The median follow-up for patients was 18.5 months.

When the NETPET scoring system was applied to included patients, more than half of the included patients (61%) had disease that was both [⁶⁸Ga]Ga-DOTATATE and [¹⁸F]FDG avid (Table 3). The distribution of scores was not significantly different between the participating institutions (Chi-square test $p=0.27$). Eight percent of patients had a NETPET score of P1 (denoting purely [⁶⁸Ga]Ga-DOTATATE avid disease), and 26% of patients had a score of 5, denoting the presence of significant [¹⁸F]FDG avid, [⁶⁸Ga]Ga-DOTATATE negative “discordant” disease. Two patients (5%) had disease that was scored as P0 (i.e. all lesions were negative on both [⁶⁸Ga]Ga-DOTATATE and [¹⁸F]FDG PET). In all, 16 of the 38 included patients (42%) underwent PRRT at some point of their disease journey (14/16 after the dual PET scans). These patients had NETPET scoring as follows: P1 – 1/16 (6%), P2-4 – 13/16 (81%), P5 – 2/16 (13%).

Overall survival

Death had occurred in 10 of the 38 patients (26%) at time of censoring. The median overall survival was not reached but was estimated at 53 months. An increasing NETPET score was associated with poorer median overall survival (P1 – not reached, P2-4 – 49.1 months, P5 – 14.5 months; $p=0.003$, log-rank test). (Fig.2) On univariate analysis, overall survival was associated with NETPET score ($p=0.003$) and histology ($p=0.01$). On multivariate analysis, only NETPET score remained significant as a prognostic factor ($p=0.03$), with histology no longer significant ($p=0.39$). (Table 4)

Progression-free survival

Of the included patients, 29 of 38 (76%) had progressed at time of censoring. The median progression-free survival was 12.9 months. Median PFS was not reached in patients grouped as P1, 14.1 months in those grouped as P2-4, and 4.8 months in those grouped as P5 ($p < 0.0001$, log-rank test) (Fig.3).

On univariate analysis, progression-free survival was significantly associated with NETPET score ($p < 0.00001$) and histological grade ($p = 0.04$), but not age ($p = 0.88$) nor the presence of extrahepatic disease ($p = 0.68$). On multivariate analysis, only NETPET score remained a significant predictor of PFS ($p < 0.00001$). (Table 5) Finally, NETPET score was significantly associated with histological grade ($p = 0.006$, chi-squared test).

Sensitivity analyses

We performed sensitivity analyses to investigate the impact of substituting histological grade with Ki-67 index. On univariate analysis, Ki-67 index was also associated with overall survival ($p = 0.004$, log-rank test). This association remained significant on multivariate analysis ($p = 0.034$). The NETPET classification was not significantly associated with OS after adjustment for Ki-67 index ($p = 0.08$). Finally, the NETPET score was associated with the Ki-67 index ($p = 0.01$ by ANOVA).

Discussion

The current project and indeed the NETPET score proposal arose from the hypothesis that [^{68}Ga]Ga-DOTATATE and [^{18}F]FDG PET provide complementary information about tumour biology. [^{68}Ga]Ga-DOTATATE assesses the presence and extent of somatostatin receptors, whereas [^{18}F]FDG uptake reflects glucose metabolism with avidity typically highest in more aggressive and less well differentiated tumours. . The NETPET score divides patients into three main groups – those who only had

[⁶⁸Ga]Ga-DOTATATE avidity on dual PET (favourable), those with [¹⁸F]FDG avid, [⁶⁸Ga]Ga-DOTATATE negative “discordant” disease (unfavourable) and those with at least one [¹⁸F]FDG avid, [⁶⁸Ga]Ga-DOTATATE avid lesion on dual PET without any discordance (intermediate). This NETPET score was a significant prognostic biomarker in the original study, which mainly investigated GEPNENs [19]. This multicentre study demonstrates the NETPET scoring system has a similar prognostic ability in bronchial NENs.

In the current study, we extended the findings of the original study of NETPET score to patients with bronchial NENs. Previously suggested factors such as histological grade, age and presence/absence of extrahepatic disease had less prognostic value in the current study. Whilst histological grade and the NETPET score were associated with OS and PFS in univariate analyses, the NETPET score was the only predictor for both OS and PFS in multivariate analyses. The fact that histological grade is a recognised predictor of outcome further highlights the potential of the NETPET score [23]. The lack of overall survival difference between typical and atypical carcinoids in the current study (compared to the cited reference) may be due to the smaller size of our cohort. However, this only serves to show the ability of the NETPET score to reflect the most aggressive lesion on dual PET, particularly relevant in presence of metastatic heterogeneity. In contrast, histology only samples one unselected site of known disease, and is also affected by sample size (needle biopsies may underestimate grade due to the paucity of tumour tissue). This data supports a potential role for dual PET in addition to biopsy to determine tumour aggressiveness and optimal therapy in a patient with bronchial NEN. In addition, as PET is a non-invasive modality, the NETPET score may also highlight changes in disease biology over time without the risks incurred with repeat tissue biopsies.

To our knowledge, our findings confirm the prognostic value of the NETPET score in bronchial NENs for the first time, extending the findings from previous GEPNEN studies [20,21]. Whilst a similar analysis in bronchial NENs has recently been published and demonstrated a significant proportion of patients with discordant lesions, a different scoring system was used, and the impact of dual PET scoring

on overall survival was not reported. [24] This study suggests that patients with no avidity on either PET (analogous to P0) and patients with significant [¹⁸F]FDG avid, [⁶⁸Ga]Ga-DOTATATE non-avid disease (analogous to P5) should not receive PRRT, which is concordant with our clinical experience. Further investigations into a molecular imaging-led paradigm for treatment selection may impact care for patients with bronchial NEN (e.g. a score of P1 leading to the use of somatostatin analogues, and a score of P5 arguing more for the use of systemic chemotherapy).

We acknowledge limitations in the current study. The relatively small numbers in this study reflect the uncommon nature of bronchial NENs. As such, the study should be regarded as hypothesis-generating at this point whilst awaiting additional confirmatory data. As dual PET for bronchial NENs is not routinely practiced (due to the paucity of data regarding its utility to date), there is also a possibility of selection bias, as clinicians may order both PET examinations for patients with more aggressive disease, as reflected in the high proportion of patients with atypical carcinoids rather than typical carcinoids. This bias may also explain the relatively small number of patients with P1 grading. The retrospective nature of this study meant that the PET scans were not performed on the same day. This raises the possibility that there may have been changes in tumour size/characteristics between the performance of the two PET scans. We restricted inclusion to patients who had both scans done within 60 days of each other to minimise this potential issue. The current findings (particularly the interplay between Ki-67, NETPET score and prognosis) should ideally be confirmed by a prospective study. Finally, we note that we included bronchial NENs of all histologies (from typical carcinoid to small cell neuroendocrine carcinoma), as opposed to a recent study which enrolled only patients with typical and atypical carcinoid [25]. This inclusion allowed us to demonstrate the value of dual PET imaging and its correlation to high-grade histologies; our results remained significant for NETPET score alone on restriction of the cohort to typical and atypical carcinoid histologies (data not shown).

Future research from this study might include investigation of dual PET as a predictive biomarker for PRRT (that is, one that predicts for differential efficacy from PRRT as opposed to just predicting for

poorer prognosis *per se*). However, ideally this needs to be done in the context of a prospective clinical trial. The best systemic therapy for each NETPET score and the relative importance of this compared to histological grade needs to be determined. The current study treats the P2-4 group (patients with lesions which are both [⁶⁸Ga]Ga-DOTATATE and [¹⁸F]FDG avid) as a single group meaning that subtle differences in relative [⁶⁸Ga]Ga-DOTATATE and [¹⁸F]FDG avidity has not been shown to be of significance to date; the P2/P3/P4 classes may be refined into separate prognostic subgroups with larger studies and quantitative evaluation of [⁶⁸Ga]Ga-DOTATATE and [¹⁸F]FDG metrics. Further research may show a link between different dual PET imaging phenotypes and molecular changes in bronchial NENs [26]. Finally, the aetiology and significance of disease that is non-avid on both [⁶⁸Ga]Ga-DOTATATE and [¹⁸F]FDG PET remains to be determined [24].

This study also raises some intriguing possibilities for further preclinical investigation. Relatively little is known about the interplay between the molecular bases of NENs and PET findings. Recent studies investigating gene expression profiles of bronchial NENs have implicated multiple abnormalities involving the NF-KB and ERK/MAPK pathways and also demonstrated significant differences between SCLC and typical/atypical carcinoids.[27,28] The upregulation of these pathways may lead to metabolic reprogramming in favour of increased glycolytic rates and more aggressive behaviour. Further understanding of these molecular pathways may shed light on the dual PET findings observed in the current study, and also lead to the development of new imaging tracers to better define disease biology.

In conclusion, dual PET divides patients into four groups – purely [⁶⁸Ga]Ga-DOTATATE avid disease (P1), dual [⁶⁸Ga]Ga-DOTATATE and [¹⁸F]FDG avidity (P2-4), those with [¹⁸F]FDG avid, [⁶⁸Ga]Ga-DOTATATE negative disease (P5), and dual negative disease (P0). The NETPET score predicts overall survival in patients with metastatic bronchial NEN. This remains true after adjustment for known prognostic variables such as histological grade. If confirmed by prospective studies, this would confirm

its value as a prognostic biomarker above that of histological grade alone in predicting disease aggressiveness and guide best care.

Financial disclosures: DLC has received a National Health and Medical Research Council investigator grant to fund this research in part (APP1175788). Dale Bailey is supported in part by Sydney Vital, which receives its funding from a Translational Cancer Research Centre programme grant from the Cancer Institute of New South Wales.

Acknowledgements: We acknowledge Dr Elizabeth Bernard (Royal North Shore Hospital) for her assistance in image analysis.

Competing Interests: The authors have declared that no competing interest exists.

KEY POINTS

Question: What is the prognostic significance of the proposed NETPET scoring system for dual [¹⁸F]FDG and [⁶⁸Ga]Ga-DOTATATE PET imaging in patients with metastatic bronchial NEN?

Pertinent findings: In a multicentre retrospective study of 38 patients, increasing NETPET score (signifying [¹⁸F]FDG avidity and loss of [⁶⁸Ga]Ga-DOTATATE avidity) was associated with worsened overall survival on univariate and multivariate analysis.

Implications for patient care: The NETPET score holds significant promise as a biomarker in patients with advanced bronchial NENs.

References

1. Hallet J, Law CHL, Cukier M, Saskin R, Liu N, Singh S. Exploring the rising incidence of neuroendocrine tumors: a population-based analysis of epidemiology, metastatic presentation, and outcomes. *Cancer*. 2015 Feb 15;121(4):589–97.
2. Dasari A, Shen C, Halperin D, Zhao B, Zhou S, Xu Y, et al. Trends in the Incidence, Prevalence, and Survival Outcomes in Patients With Neuroendocrine Tumors in the United States. *JAMA Oncol*. 2017 Apr 27;
3. Sorbye H, Welin S, Langer SW, Vestermark LW, Holt N, Osterlund P, et al. Predictive and prognostic factors for treatment and survival in 305 patients with advanced gastrointestinal neuroendocrine carcinoma (WHO G3): the NORDIC NEC study. *Ann Oncol*. 2013 Jan;24(1):152–60.
4. Travis WD, Brambilla E, Nicholson AG, Yatabe Y, Austin JHM, Beasley MB, et al. The 2015 World Health Organization Classification of Lung Tumors: Impact of Genetic, Clinical and Radiologic Advances Since the 2004 Classification. *J Thorac Oncol Off Publ Int Assoc Study Lung Cancer*. 2015 Sep;10(9):1243–60.
5. Bosman FT, World Health Organization, International Agency for Research on Cancer, editors. WHO classification of tumours of the digestive system. 4th ed. Lyon: International Agency for Research on Cancer; 2010. 417 p. (World Health Organization classification of tumours).
6. Yao JC, Hassan M, Phan A, Dagohoy C, Leary C, Mares JE, et al. One Hundred Years After “Carcinoid”: Epidemiology of and Prognostic Factors for Neuroendocrine Tumors in 35,825 Cases in the United States. *J Clin Oncol*. 2008 Jun 20;26(18):3063–72.
7. Li X, Hou Y, Shi T, He Y, Ren D, Song Z, et al. Clinicopathological characteristics and genetic analysis of pulmonary carcinoid tumors: A single-center retrospective cohort study and literature review. *Oncol Lett*. 2020 Mar;19(3):2446–56.
8. Scarpa A, Chang DK, Nones K, Corbo V, Patch A-M, Bailey P, et al. Whole-genome landscape of pancreatic neuroendocrine tumours. *Nature*. 2017 02;543(7643):65–71.
9. Yao JC, Fazio N, Singh S, Buzzoni R, Carnaghi C, Wolin E, et al. Everolimus for the treatment of advanced, non-functional neuroendocrine tumours of the lung or gastrointestinal tract (RADIANT-4): a randomised, placebo-controlled, phase 3 study. *Lancet Lond Engl*. 2016 Mar 5;387(10022):968–77.
10. Rinke A, Muller HH, Schade-Brittinger C, Klose KJ, Barth P, Wied M, et al. Placebo-controlled, double-blind, prospective, randomized study on the effect of octreotide LAR in the control of tumor growth in patients with metastatic neuroendocrine midgut tumors: a report from the PROMID Study Group. *J Clin Oncol*. 2009 Oct 1;27:4656–63.
11. Caplin ME, Pavel M, Cwikla JB, Phan AT, Raderer M, Sedlackova E, et al. Lanreotide in metastatic enteropancreatic neuroendocrine tumors. *N Engl J Med*. 2014 Jul 17;371:224–33.
12. Yao JC, Shah MH, Ito T, Bohas CL, Wolin EM, Van Cutsem E, et al. Everolimus for advanced pancreatic neuroendocrine tumors. *N Engl J Med*. 2011 Feb 10;364:514–23.

13. Strosberg J, El-Haddad G, Wolin E, Hendifar A, Yao J, Chasen B, et al. Phase 3 Trial of ¹⁷⁷Lu-Dotatate for Midgut Neuroendocrine Tumors. *N Engl J Med*. 2017 Jan 12;376(2):125–35.
14. Chan DL, Clarke SJ, Diakos CI, Roach PJ, Bailey DL, Singh S, et al. Prognostic and predictive biomarkers in neuroendocrine tumours. *Crit Rev Oncol Hematol*. 2017 May;113:268–82.
15. Binderup T, Knigge U, Loft A, Federspiel B, Kjaer A. 18F-fluorodeoxyglucose positron emission tomography predicts survival of patients with neuroendocrine tumors. *Clin Cancer Res*. 2010 Feb 1;16:978–85.
16. Chan DL, Bernard E, Schembri G, Roach P, Johnson M, Pavlakis N, et al. High metabolic tumour volume on FDG PET predicts poor survival from neuroendocrine neoplasms. *Neuroendocrinology*. 2019 Nov 12;
17. Zhang J, Liu Q, Singh A, Schuchardt C, Kulkarni HR, Baum RP. Prognostic Value of 18F-FDG PET/CT in a Large Cohort of 495 Patients with Advanced Metastatic Neuroendocrine Neoplasms (NEN) Treated with Peptide Receptor Radionuclide Therapy (PRRT). *J Nucl Med Off Publ Soc Nucl Med*. 2020 Mar 13;
18. Johnbeck CB, Knigge U, Langer SW, Loft A, Berthelsen AK, Federspiel B, et al. Prognostic Value of 18F-FLT PET in Patients with Neuroendocrine Neoplasms: A Prospective Head-to-Head Comparison with 18F-FDG PET and Ki-67 in 100 Patients. *J Nucl Med Off Publ Soc Nucl Med*. 2016 Dec;57(12):1851–7.
19. Chan DL, Pavlakis N, Schembri GP, Bernard EJ, Hsiao E, Hayes A, et al. Dual Somatostatin Receptor/FDG PET/CT Imaging in Metastatic Neuroendocrine Tumours: Proposal for a Novel Grading Scheme with Prognostic Significance. *Theranostics*. 2017;7(5):1149–58.
20. Karfis I, Marin G, Levillain H, Drisis S, Muteganya R, Critchi G, et al. Prognostic value of a three-scale grading system based on combining molecular imaging with 68Ga-DOTATATE and 18F-FDG PET/CT in patients with metastatic gastroenteropancreatic neuroendocrine neoplasias. *Oncotarget*. 2020 Feb 11;11(6):589–99.
21. Furtado O'Mahony L. Combination of 68Ga-DOTATATE and 18F-FDG PET/CT in Advanced Gastroenteropancreatic Neuroendocrine Tumours (GEPNET) – Clinical and Prognostic Implications. *Neuroendocrinology*. 108(Suppl.1):D20.
22. Eisenhauer EA, Therasse P, Bogaerts J, Schwartz LH, Sargent D, Ford R, et al. New response evaluation criteria in solid tumours: revised RECIST guideline (version 1.1). *Eur J Cancer Oxf Engl* 1990. 2009 Jan;45(2):228–47.
23. Ramirez RA, Beyer DT, Diebold AE, Voros BA, Chester MM, Wang Y-Z, et al. Prognostic Factors in Typical and Atypical Pulmonary Carcinoids. *Ochsner J*. 2017;17(4):335–40.
24. Zidan L, Iravani A, Kong G, Akhurst T, Michael M, Hicks RJ. Theranostic implications of molecular imaging phenotype of well-differentiated pulmonary carcinoid based on 68Ga-DOTATATE PET/CT and 18F-FDG PET/CT. *Eur J Nucl Med Mol Imaging [Internet]*. 2020 Jun 22 [cited 2020 Jun 28]; Available from: <http://link.springer.com/10.1007/s00259-020-04915-7>
25. Zidan L, Iravani A, Kong G, Akhurst T, Michael M, Hicks RJ. Theranostic Implication of Molecular Imaging Phenotype of Well-Differentiated Lung Carcinoid by 68Ga-DOTATATE

PET/CT and 18F-FDG PET/CT. In: Proceedings of the European Neuroendocrine Tumor Society, 2020. Barcelona, Spain; 2020.

26. Pelosi G, Sonzogni A, Harari S, Albini A, Bresaola E, Marchiò C, et al. Classification of pulmonary neuroendocrine tumors: new insights. *Transl Lung Cancer Res.* 2017 Oct;6(5):513–29.
27. Voortman J, Lee J-H, Killian JK, Suuriniemi M, Wang Y, Lucchi M, et al. Array comparative genomic hybridization-based characterization of genetic alterations in pulmonary neuroendocrine tumors. *Proc Natl Acad Sci.* 2010 Jul 20;107(29):13040–5.
28. Asiedu MK, Thomas CF, Dong J, Schulte SC, Khadka P, Sun Z, et al. Pathways Impacted by Genomic Alterations in Pulmonary Carcinoid Tumors. *Clin Cancer Res.* 2018 Apr 1;24(7):1691–704.

FIGURES WITH LEGENDS

Figure 1: Original NETPET schema (reproduced from Chan et al, Theranostics 2017)

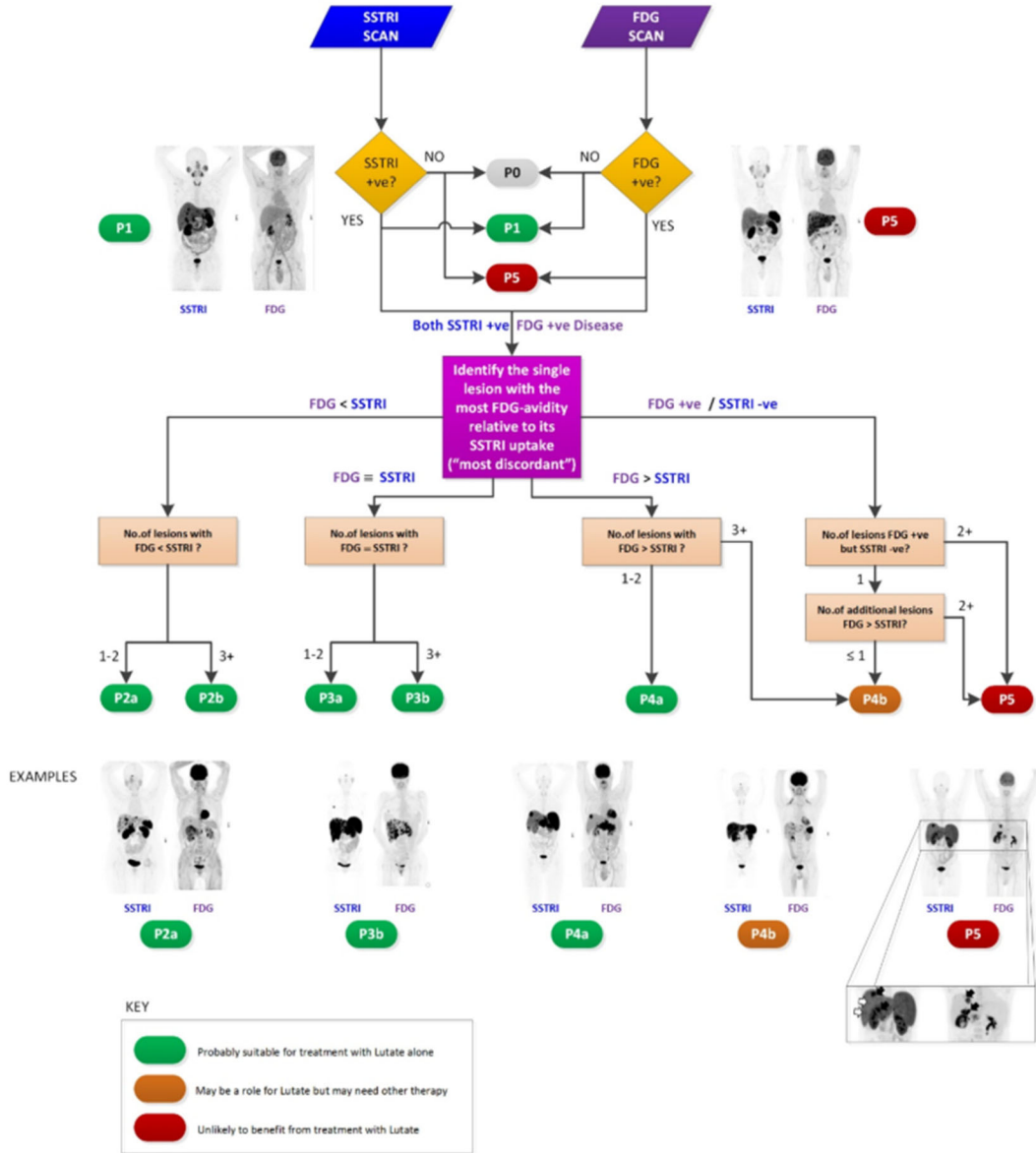
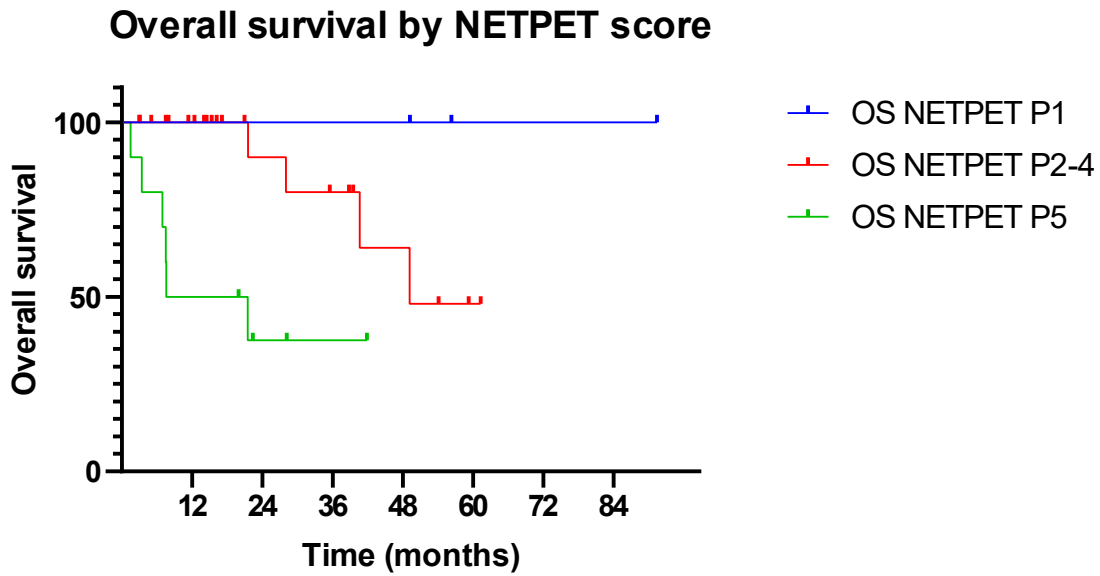
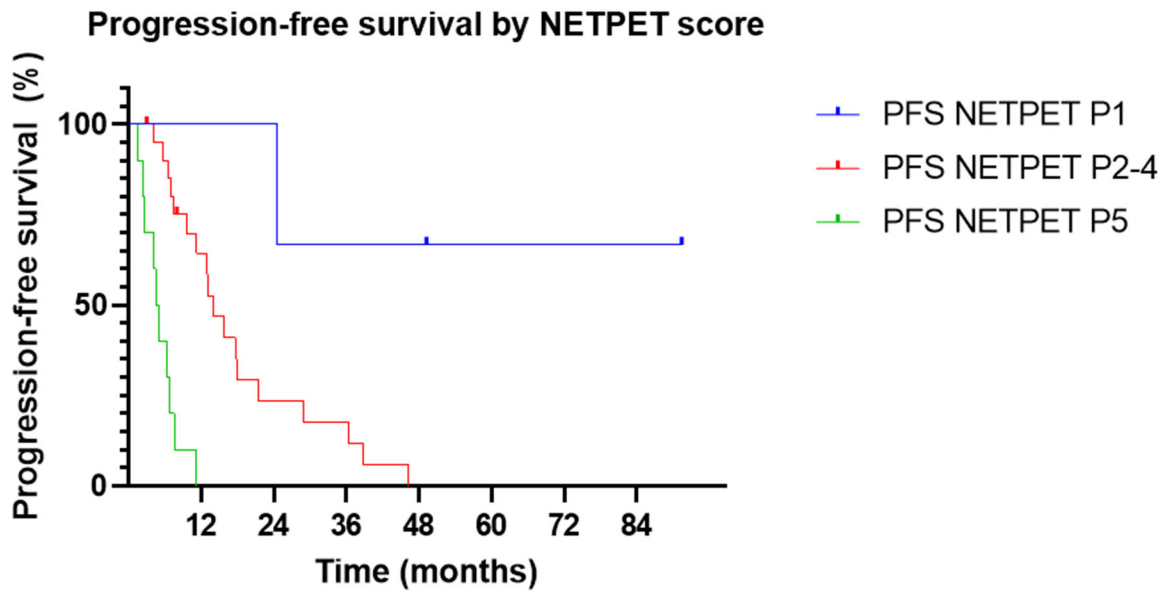


Figure 2: Overall Survival by NETPET score



Figure

3: Progression-free Survival by NETPET score



TABLES

Table 1: Simplified schematic of the relationship between the NETPET score and dual PET avidity

NETPET Grade	[⁶⁸Ga]Ga-DOTATATE Result	[¹⁸F]FDG Result
0	-	-
1	++	-
2	++	+
3	++	++
4	+	++
5	-	++

Table 2: Demographics of study cohort (n=38)

Characteristic		Number	Proportion (%)
Total		38	100
Gender	Male	15	39
	Female	23	61
Age (years)	Median	66 (range 28-81)	
Primary site	Lung	38	100
Grade for bronchial NEN	Typical Carcinoid	9	24
	Atypical carcinoid	22	58
	LCNEC	3	8
	SCNEC	1	3
	Unknown*	3	8
Mitotic count	Median (range)	3.5 (0-50)	
Ki-67 index	Median (range)	15 (1-80)	
Necrosis	Yes	16	42
	No	11	29
	Unknown	11	39
Site of metastasis	Lungs	19	50
	Lymph nodes	19	50
	Liver	21	55
	Bone	23	61
	Brain	4	11
	Other**	11	32
Extrahepatic disease	Yes	36	95
	No	2	5
Received PRRT	Yes	19	50
	No	19	50

PRRT: Peptide Receptor Radionuclide Therapy

* Of these three cases, two were well-differentiated NEN without a specific comment on the histological report as to whether this represented a typical or atypical carcinoid. One was a mixed high-grade and low-grade NEN.

**Other sites of disease included the peritoneum (4 patients), pancreas (3 patients), adrenal glands (2 patients), pericardium (1 patient), and ovary (1 patient).

Table 3: Distribution of NETPET scores

NETPET score	Number (proportion)
0	2 (5%)
1	3 (8%)
2A/2B	7 (18%)
3A/3B	4 (11%)
4A/4B	12 (32%)
5	10 (26%)

Table 4: Univariate and multivariate analyses for OS. Significant values bolded.

Variable	Univariate p value	Multivariate p value
NETPET score	P=0.003	P=0.03
Histology	P=0.010	P=0.39
Presence of extrahepatic disease	P=0.474	P=0.09
Age>65	P=0.429	P=0.46

Table 5: Univariate and multivariate analyses for PFS. Significant values bolded.

Variable	Univariate p value	Multivariate p value
NETPET score	P<0.00001	P<0.00001
Histology	P=0.04	P=0.871
Presence of extrahepatic disease	P=0.68	P=0.998
Age>65	P=0.88	P=0.78

Graphical Abstract

