

DIAGNOSIS OF PULMONARY EMBOLISM WITH SCANNING AND ANGIOGRAPHIC TECHNIQUES—A CORRELATIVE STUDY

Leonard M. Freeman, Melvin N. Zelefsky,* Neville Kaplan, Chien-Hsing Meng and Robert Bernstein

*Albert Einstein College of Medicine of Yeshiva University,
The Bronx Municipal Hospital Center and the Hospital of
the Albert Einstein College of Medicine, Bronx, New York*

The recent medical literature has contained numerous reports on the various diagnostic procedures available for studying pulmonary embolism (1-4). The availability of macroaggregates of serum albumin for blocking pulmonary capillary beds (5-7) has contributed greatly to our diagnostic armamentarium in embolic disease of the lung.

The advent of lung scanning has caused some controversy when compared with the established method of pulmonary angiography (3). The purpose of this paper is to stress that these two diagnostic procedures should be considered complementary rather than competitive. The clinical situation will dictate which one may be of greater value at a given time. Often, both examinations may contribute to the management of a single patient.

MATERIALS AND METHODS

Thirteen female and 11 male patients ranging in age from 23 to 81 yr (average of 60 yr) suspected of having pulmonary embolism were studied with both pulmonary angiography and scanning. In almost all instances, the studies were performed within 1-6 hr of one another with the scan always preceding the angiogram.

Lung scanning was performed on a Picker Magnascanner equipped with a 3 × 2-in. sodium iodide crystal and a 19-hole focusing collimator with a 3-in. focal depth. A standard dose of 300 μ c of 131 I-macroaggregated albumin was given intravenously. Each examination consisted of both anterior and posterior views except in three cases where time did not allow for this. In these cases, single posterior scans were performed because experience has shown this projection to be more rewarding than any other when it is necessary to make a choice. Including follow-up studies, a total of 48 lung-scan examinations was performed on the 24 patients.

Pulmonary angiography was performed with a Robb-Steinberg needle positioned in an antecubital vessel. In several cases a venous catheter was passed with its tip located in the superior vena cava. At no time was an intracardiac injection used. Seventy-five to 90 cc of Conray 400† was pressure injected at a rate of 25 cc/sec. Twenty serial, anteroposterior stereoscopic films at ½-sec intervals were then exposed using Schonander apparatus. A total of 26 angiographic studies were performed on the 24 patients.

ILLUSTRATIVE CASES

The following case histories will present some of the pertinent observations made using angiography and scanning in pulmonary thromboembolism.

Case 1. B.R., a 29-year-old Negro female was admitted to the Bronx Municipal Hospital Center on June 10, 1966, with shortness of breath for a 2-week duration. Ten days earlier some left-flank and left-chest pleuritic pain was diagnosed elsewhere as acute pyelonephritis, and the patient responded well to a sulfa preparation.

One day prior to admission, she developed increasing dyspnea, chest tightness and palpitations. She also had some right upper-quadrant pain.

Physical examination revealed a BP of 110/80, pulse 120/min and regular, respiration 24/min and regular. The lungs were clear and a presystolic gallop was present, as well as a Grade II systolic murmur at the left sternal border.

On the second hospital day, she had a syncopal episode with mild hypotension that lasted a few

Received Aug. 14, 1967; revision accepted Feb. 9, 1968.

* Scholar in radiological research of the James Picker Foundation.

† Sodium Iothalamate Injection U.S.P. 66.8%; Mallinckrodt Pharmaceuticals, St. Louis, Mo.

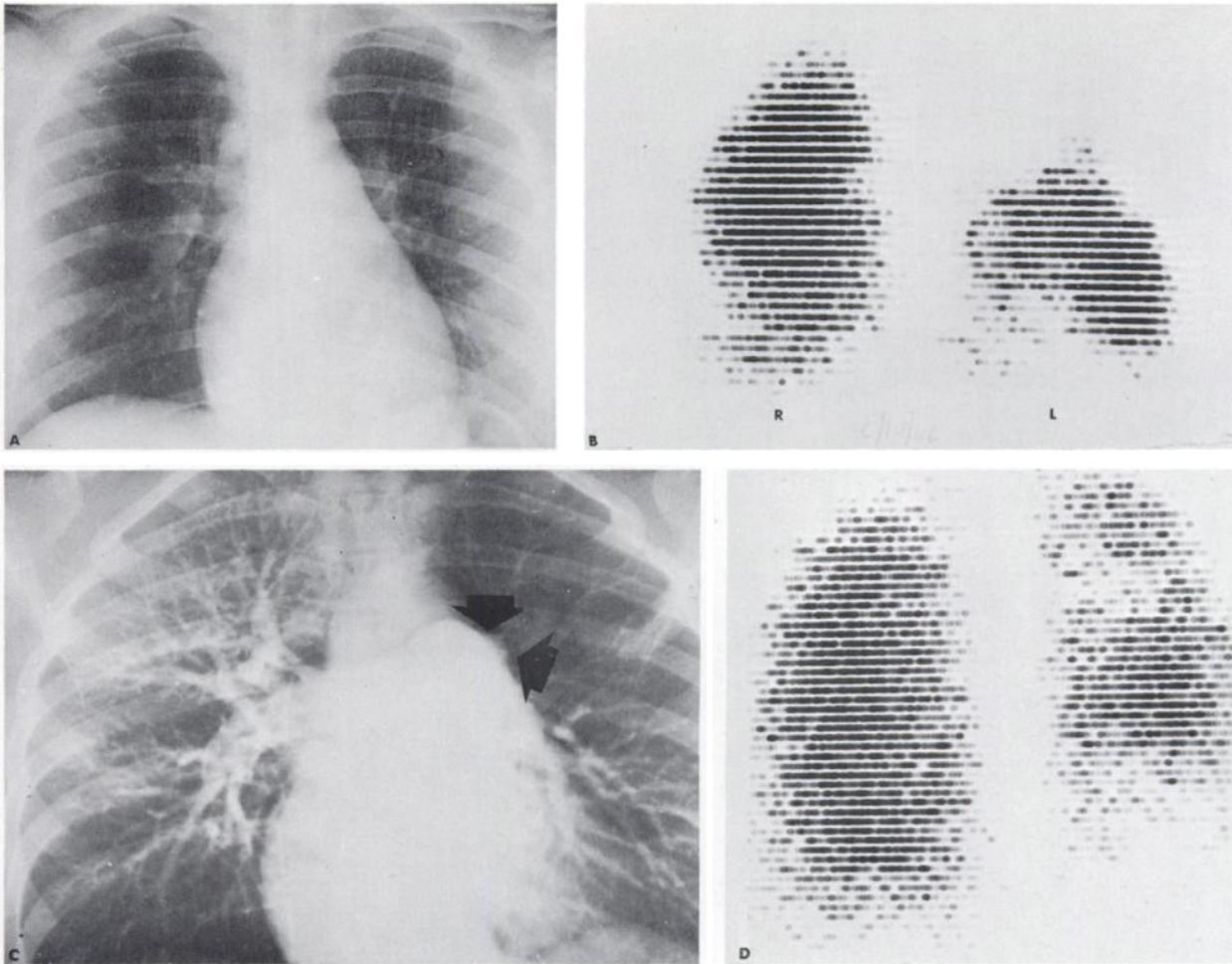


FIG. 1. Case 1. Left upper-lobe embolus in 29-year-old female. A: Chest roentgenogram is unremarkable. B: Posterior lung scan reveals large perfusion defect in left upper lobe. There is also some patchiness of activity at right base with motion artifact also present. C: Pulmonary angiogram demonstrates complete occlusion of left upper-lobe pulmonary artery (arrows) with relative avascularity of left upper lobe. D: Repeat posterior lung scan 6 weeks later shows a moderate return of left upper-lobe activity. Some generalized diminution of left lung activity is seen at this time. Right base has relatively normal perfusion.

minutes. The following day she spiked a fever of 101.4°F and developed severe right upper-quadrant pain with a persistent tachycardia. An intravenous urogram as well as an oral cholecystogram were normal. An EKG showed an incomplete right bundle branch block.

A chest x-ray on the fourth hospital day was normal (Fig. 1 A). A lung scan surprisingly showed markedly diminished left upper-lobe perfusion (Fig. 1 B). The right lower-lobe area (clinically suspect because of the right upper-quadrant pain) appeared relatively normal. There was, perhaps, a mild diminution in perfusion to this area. Pulmonary angiography demonstrated complete occlusion of the left upper-lobe artery with total avascularity of the left upper lobe (Fig. 1 C).

The patient was anticoagulated and did well. She was discharged on June 24, 1966. A follow-up scan 6 weeks later showed a moderate return of left upper-lobe perfusion with some generalized diminution of activity in other areas (Fig. 1 D).

Comment. This case shows that a large embolus may be present without any significant alterations

in the chest roentgenogram. The left upper-lobe vascular occlusion was probably unrelated to the clinical findings in the right upper quadrant. In this frequently insidious disease entity, it is not unusual to find emboli in unsuspected locations.

During the recovery process, one often notes an unpredictable series of changes in the perfusion pattern. Some areas appear to be improving while other previously normal-appearing regions may show diminished radioactivity as in Fig. 1 D. In following the course of many emboli, this rather striking change in perfusion pattern has been noted both in this series as well as another large number of cases (8) (See Case 2).

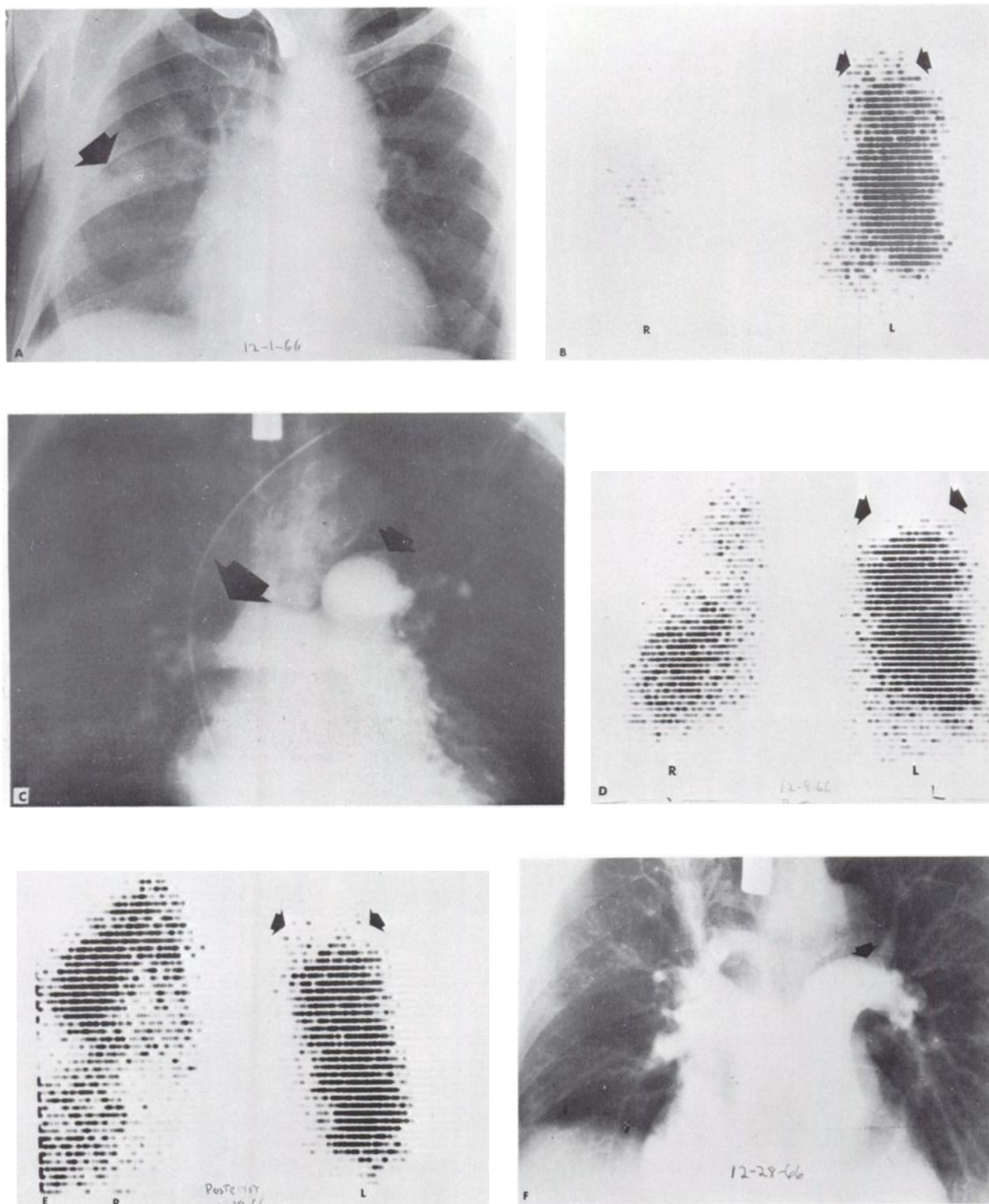


FIG. 2. Case 2. Bilateral pulmonary emboli in 76-year-old male. A: Chest roentgenogram reveals right-sided infiltrate (arrow) which was present on study 2 days previously. B: Posterior lung scan shows massive right-sided perfusion defect with only small amount of activity in midlung field. Smaller defect is noted at left apex (arrows). C: Pulmonary angiogram demonstrates large clot in right main pulmonary artery (large arrow) as well as smaller left upper-lobe vascular defect (smaller arrow). D: Follow-up pos-

terior lung scan 8 days later reveals return of right-lung activity, in lower lobe. Left apical defect is even more apparent (arrows). E: Follow-up posterior lung scan 28 days after initial scan reveals further change in right-sided perfusion pattern with upper lobe area now having better perfusion (see comment on case 2). Left apical defect (arrows) is unchanged. F: Repeat angiogram 28 days after initial study shows patency of previously occluded right-sided vessels. Small intravascular clot remains (arrow).

Case 2. A.B., a 76-year-old white male with a known laryngeal carcinoma for 5 yr was admitted to the Bronx Municipal Hospital Center on Nov. 3, 1966, for the third time. Due to increasing dysphagia, a feeding gastrostomy tube was inserted.

For a 2½-week period in the hospital, he had several episodes of dizziness, the last of which was associated with right-sided chest pain and T-wave inversions in leads V₁₋₄ on electrocardiogram. A positive Homans sign was finally elicited in the left calf and some moist rales were auscultated at the right base.

A right midlung infiltrate present for several days and believed to represent an aspiration pneumonia had not changed appreciably on the chest x-ray of Dec. 1, 1966 (Fig. 2 A). A lung scan on the same day showed a massive perfusion defect in the right lung as well as a smaller one in the left apical region (Fig. 2 B). A large filling defect in the main right pulmonary artery was demonstrated on angiography (Fig. 2 C). A smaller left upper-lobe lesion was also noted.

After anticoagulation, the patient did fairly well for a while. On Dec. 12, 1966, he underwent a laryngectomy for total removal of the tumor. Follow-up scans on Dec. 9, 1966 (Fig. 2 D) and Dec. 28, 1966 (Fig. 2 E) showed progressive improvement in perfusion of the right lung. A repeat pulmonary angiogram on the latter date demonstrated patency of almost all the involved vessels (Fig. 2 F).

Unfortunately, hemorrhage through the gastrostomy tube on Jan. 8, 1967, necessitated stopping anticoagulation and commencing blood transfusion. The patient then went into renal failure and did poorly. He expired on Jan. 29, 1967.

Comment. This case demonstrates how useful information can be obtained from a lung scan despite the presence of an infiltrate on the chest film. The large size of the perfusion defect is well out of proportion to the smaller size of the density on x-ray. This is a major point in favor of a diagnosis of pulmonary embolus.

In addition, perfusion defects were noted bilaterally, while only a right-sided infiltrate was present on the chest film. In this particular series of cases, 70% of the defects seen on lung scan were bilateral. The point that pulmonary emboli most often occur in showers has been emphasized by Tow and Wagner, who found that 65% of their patients had more than one underperfused area on the lung scan (8).

Specific anatomic localization of the clot is often needed, particularly when surgical intervention is contemplated. In this case, the large right-sided perfusion defect could be due either to multiple right-

sided emboli or a single big clot in the main right pulmonary artery. This is where pulmonary angiography plays a major role; as in the present case where a single large filling defect was demonstrated.

With the recent trend being in favor of less surgery and more conservative treatment in the majority of large pulmonary emboli (9), lung scanning should become an increasingly important procedure for the diagnosis and management of patients with pulmonary embolism.

The relatively rapid improvement of large central types of emboli has been noted previously in contrast to the localized peripheral type of embolus that resolves more slowly (8).

The striking, unpredictable changes in perfusion pattern frequently seen during the recovery process (as in Case 1) is also seen here (Figs. 2 D and E).

Case 3. J.Q., an 80-year-old white male was admitted to the Albert Einstein College Hospital for the first time on Dec. 3, 1966, with rectal hemorrhage. Physical examination revealed a chronically ill, febrile, anemic white male. A barium enema showed colonic diverticulitis. His hematocrit was 33. He was treated with antibiotics, iron and blood transfusion. Two weeks after admission, he developed left-sided pleuritic chest pain and a left lower-lobe infiltrate on chest x-ray. A lung scan showed large perfusion defects at both bases (Fig. 3 A). A pulmonary angiogram performed 2 hr later was initially thought to be negative, but careful review demonstrated a small filling defect in the right lower-lobe branch vessel (Fig. 3 B). This finding was seen on only one film in the series of 20. The left lower-lobe blood supply appeared normal.

Anticoagulation was withheld because of his bleeding history. The patient did not do well. He developed renal problems and progressively deteriorated, expiring on Feb. 8, 1967. Postmortem examination revealed organized pulmonary emboli with infarcted areas in both lower lobes.

Comment. One of the great difficulties involved in angiographic interpretation is seen in this case. The intraluminal filling defect (Fig. 3 B) was present on only one early film in an entire series of 20 films. As the density of the contrast media increased, the lesion was covered over. Other difficulties in angiographic interpretation will be discussed below.

In addition, the bilaterality of emboli on scan once again demonstrates why, despite the left lower-lobe infiltrative process, it was possible to obtain useful information from the lung scan.

Case 4. M.C., an 81-year-old white female with advanced peripheral vascular disease was admitted to the Albert Einstein College Hospital on Dec. 18, 1967, with right chest pain and severe shortness of

breath. She had long-standing arteriosclerotic heart disease and congestive heart failure. One month previously, she underwent a right lumbar sympathectomy for intractable leg pain.

Physical examination on admission revealed a chronically ill female with a BP of 120/70, pulse 88/min and irregular and shallow respirations 30/min. The heart was enlarged and a systolic murmur was audible over the entire precordium. Scattered rales were auscultated over both lungs.

Cardiomegaly, pulmonary vascular engorgement and a right lower-lobe infiltrate were noted on a chest x-ray (Fig. 4 A). Bilateral diminution in lower-lobe perfusion was seen on the lung scan (Fig. 4 B). This was particularly marked on the right side. Slightly diminished left upper-lobe perfusion was also noted. A complete occlusion of the right lower-lobe pulmonary artery as well as relative avascularity of the left upper-lobe was demonstrated on angiography (Fig. 4 C).

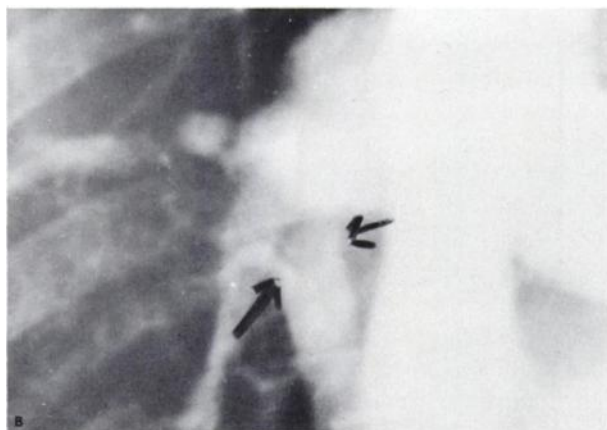



FIG. 3. Case 3. Bilateral lower-lobe emboli in 80-year-old male. A: Posterior lung scan reveals bilateral lower-lobe perfusion defects. This is most marked at right base (arrows). B: Cone down view of pulmonary angiogram shows filling defect within right lower-lobe pulmonary artery (arrows).

Anticoagulation was instituted, but the patient did poorly. On Dec. 29, 1966, she had an above-the-knee amputation for arteriosclerotic gangrene of the right foot. A follow-up lung scan on Jan. 3, 1967 (Fig. 4 D) did not show any change from the initial study 2 weeks previously. On Jan. 20, 1967, the patient became comatose following a cerebrovascular accident. She never regained consciousness and expired on Feb. 1, 1967.

Comment. Cardiopulmonary problems, such as congestive heart failure or mitral stenosis with elevated left atrial pressure, often cause a reversal in the normal distribution of flow resulting in relative diminution of basilar perfusion (10). This phenomenon is most marked after an erect injection of ^{131}I -MAA, but we have frequently made the same observation after recumbent injections such as those performed in this series of cases. The lung scan in congestive heart failure is illustrated in the present case. In addition, the presence of a right lower-lobe infiltrate is also a reason for diminished regional perfusion. Once again, the size of the right lower-lobe perfusion defect is out of proportion to the size of the pneumonia. However, a certain degree of doubt exists as far as making a definitive diagnosis of pulmonary embolism. It is here that the angiogram contributes. The demonstration of a total occlusion of the right lower-lobe vessel allows the diagnosis to be made with greater confidence.

The fact that there was little or no change in the appearance of the lung scan 2 weeks later is also interesting. Chait *et al* (11) have confirmed that the presence of pre-existing cardiovascular disease negatively affects the rate of recovery from pulmonary embolism.

DISCUSSION

The combined diagnostic approach of lung scanning and angiography is invaluable if one appreciates the limitations in each method. A great deal of emphasis has been placed upon the fact that a variety of conditions besides pulmonary embolism cause perfusion defects on the lung scan (3,12). Some of the more frequently encountered disease processes that may decrease regional pulmonary perfusion are presented in Table 1. As may be noted, almost all of these entities are well appreciated on the plain chest roentgenogram. Therefore, if a chest x-ray taken immediately before or after the scan is carefully examined, erroneous interpretations of embolic disease should be minimized. Pulmonary angiography then becomes a particularly valuable procedure in instances where nonembolic perfusion defects are present on the scan.

The limitations of the angiographic method have

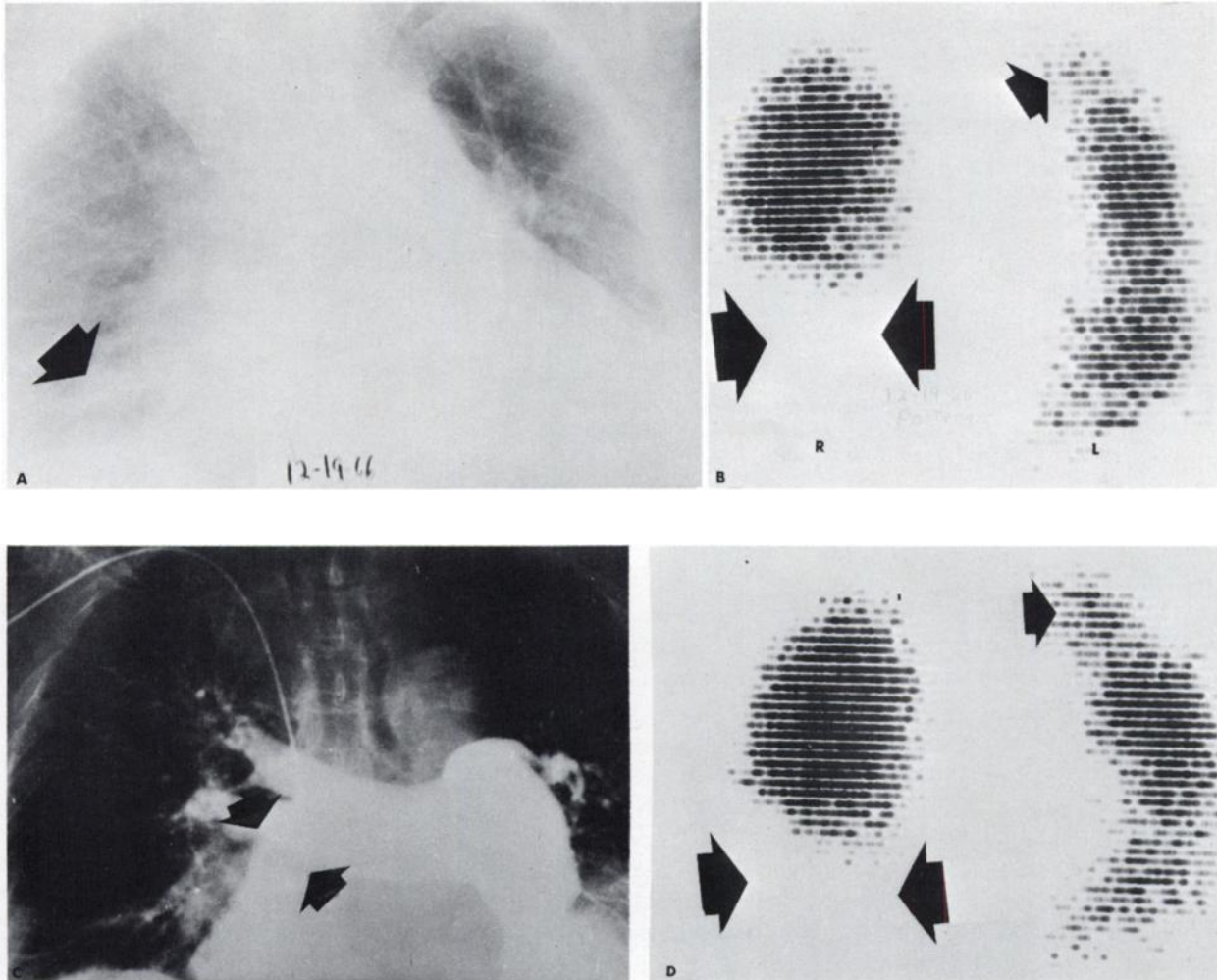


FIG. 4. Case 4. Bilateral pulmonary emboli in 81-year-old female with pre-existing cardiopulmonary disease. A: Chest roentgenogram reveals cardiomegaly and vascular engorgement. Right lower-lobe infiltrate is also present. B: Posterior lung scan shows large perfusion defect in right lower lobe (large opposing arrows) and smaller defect at left apex (single smaller arrow). C: Pulmonary angiogram demonstrates complete occlusion of right lower-lobe pulmonary artery (opposing arrows) as well as relative avascularity of left upper lobe. D: Follow-up posterior lung scan 2 weeks after previous study shows little or no change in right lower lobe (opposing arrows) and left apical defect (single arrow).

not received as much emphasis as the scan difficulties. The major underlying principle to keep in mind is that the only pathognomonic angiographic finding in pulmonary embolism is the demonstration of an intraluminal filling defect with or without actual vascular occlusion. This is not always a simple task. True filling defects are often masked by the density of overlying contrast media. In Case 3 above, the filling defect (Fig. 3 B) was retrospectively seen on only one early film in a Schonander series of films exposed at 1-sec intervals. Air-filled bronchi crossing over or under vascular structures may also frequently create the mistaken impression that an em-

bolus is present. One particularly troublesome area is where the left main stem bronchus crosses under the left pulmonary artery.

Certain vessels run in oblique or perpendicular directions when viewed on an anteroposterior roentgenogram (e.g. the main left pulmonary artery runs posterolaterally). The necessity for sometimes obtaining oblique and/or lateral views is therefore apparent.

There are several secondary angiographic signs of pulmonary embolism which may be present. These include relative avascularity, segmental diminution in flow with attenuation and tortuosity of vessels, poor capillary filling and diminished or absent venous return. These findings are nonspecific, however, and have been described in other cardiopulmonary diseases such as congestive heart failure (13), pneumonia (13), emphysema (14), pulmonary hypertension (1,15) and mitral stenosis (16).

Frequently, several different experienced radiologists viewing the same set of films differ in their opinion of whether or not an embolus is present.

TABLE 1. MECHANISMS CAUSING A DECREASE IN REGIONAL PULMONARY PERFUSION

1. Mechanical arterial obstruction
e.g. pulmonary embolism, invasive bronchogenic carcinoma.
2. Capillary displacement
e.g. cysts and bullae
3. Arterio-venous shunting
e.g. chronic bronchitis and emphysema (14)
4. Increased peripheral resistance
 - a. due to decreased PO₂
e.g. pneumonia, atelectasis, diminished ventilation secondary to obstructing bronchial lesion
 - b. due to perivascular edema (17)
e.g. congestive heart failure, mitral stenosis
5. Other factors
 - a. position of patient during injection
 - b. pleural disease
 - c. high diaphragm

Therefore the importance of having experienced observers conduct a careful, diligent search for emboli on the pulmonary angiogram cannot be overemphasized.

Another point to be considered is that the accuracy of intravenous pulmonary angiography in the detection of embolic disease decreases markedly when the intraluminal filling defects are located beyond the secondary and tertiary branches of the arterial tree. In several instances we have detected peripheral emboli on the scan that were not appreciated on the radiographic study. The documentation of these findings was based on clinical improvement as well as a return of the lung scan to normal.

The major angiographic findings in 20 cases of pulmonary embolism are shown in Table 2.

SUMMARY AND CONCLUSIONS

1. Pulmonary scanning and angiography are complementary. They should not be considered competitive.
2. Lung scanning has helped bridge the diagnostic gap between clinical suspicion on one hand and the

TABLE 2. MAJOR ANGIOGRAPHIC FINDINGS IN 20 CASES OF PULMONARY EMBOLISM*

Intraluminal filling defects	11
Cut-off of affected vessel	2
Relative avascularity	1
Delayed flow and/or drainage	2
Attenuation and tortuosity of vessels	4

* Documented by clinical improvement as well as by serial lung scans showing improved perfusion in comparison to initially abnormal areas.

pulmonary angiogram on the other. It is simpler and less hazardous to perform.

3. Angiography is particularly helpful when various pre-existing cardiopulmonary conditions cause a decrease in regional pulmonary perfusion.

4. Precise pre-operative anatomic localization of thrombi may be obtained only with angiography.

5. Localized peripheral emboli are more easily detected on the scan.

6. In following the progress of the disease, serial scans are safe and simple to perform at frequent intervals.

ACKNOWLEDGMENT

We wish to express our gratitude to Dr. Harold S. Goldman for reviewing parts of this manuscript and offering many helpful suggestions.

REFERENCES

1. WEINER, S. N., EDELSTEIN, J. AND CHARMS, B. L.: Observations on pulmonary embolism and the pulmonary angiogram. *Am. J. Roentgenol. Radium Therapy Nucl. Med.* **98**:859, 1967.
2. AMADOR, E. AND POTCHEN, E. J.: Serum lactic dehydrogenase activity and radioactive lung scanning in the diagnosis of pulmonary embolism. *Ann. Intern. Med.* **65**:1,247, 1966.
3. FRED, H. L., BURDINE, J. A., GONZALES, D. A., LOCKHART, R. W., PEABODY, C. A. AND ALEXANDER, J. K.: Arteriographic assessment of lung scanning in the diagnosis of pulmonary thromboembolism. *New Engl. J. Med.* **275**:1,026, 1966.
4. MOSER, K. M., TISI, G. M., RHODES, P. G., LANDIS, G. A. AND MIALE, A.: Correlation of lung photoscans with pulmonary angiography in pulmonary embolism. *Am. J. Cardiol.* **18**:810, 1966.
5. TAPLIN, G. V., JOHNSON, D. F., DORE, E. K. AND KAPLAN, H. S.: Suspensions of radioalbumin aggregates for photoscanning the liver, spleen, lung and other organs. *J. Nucl. Med.* **5**:259, 1964.
6. QUINN, J. L. AND WHITLEY, J. E.: Lung scintiscanning. *Radiology* **83**:937, 1964.
7. WAGNER, H. N., JR., SABISTON, D. C., JR., MCAFEE, J. G., TOW, D. E. AND STERN, H. S.: Diagnosis of massive pulmonary embolism in man by radioisotope scanning. *New Engl. J. Med.* **271**:377, 1964.
8. TOW, D. E. AND WAGNER, H. N., JR.: Recovery of pulmonary arterial blood flow in patients with pulmonary embolism. *New Engl. J. Med.* **276**:1,053, 1967.
9. MEYEROWITZ, B.: Pulmonary embolism in surgical patients: is embolectomy superior to prophylaxis? *Surgery* **60**:521, 1966.
10. FRIEDMAN, W. F. AND BRAUNWALD, E.: Alterations in regional pulmonary blood flow in mitral valve disease studied by radioisotope scanning: a simple, nontraumatic technic for estimation of left atrial pressure. *Circulation* **34**:363, 1966.
11. CHAIT, A., SUMMERS, D., KRASNOW, N. AND WECHS-

- LER, B. M.: Observations on the fate of large pulmonary emboli. *Am. J. Roentgenol. Radium Therapy Nucl. Med.* **100**:364, 1967.
12. MOSER, K. M., RHODES, P. G., LANDIS, G. A., TISI, G. M. AND MIALE, A.: Interpretive pitfalls in lung scanning. *J. Nucl. Med.* **7**:353, 1966.
13. FERRIS, E. J., STANZLER, R. M., ROURKE, J. A., BLUMENTHAL, J. AND MESSER, J. V.: Pulmonary angiography in pulmonary embolic disease. *Am. J. Roentgenol. Radium Therapy Nucl. Med.* **100**:355, 1967.
14. JACOBSON, G., TURNER, A. F., BALCHUM, O. J. AND JUNG, R.: Vascular changes in pulmonary emphysema. *Am. J. Roentgenol. Radium Therapy Nucl. Med.* **100**:374, 1967.
15. STEINER, R. E.: Pulmonary hypertension; Symposium II. Radiological appearances of pulmonary hypertension. *Brit. J. Radiol.* **31**:188, 1958.
16. FLEISCHNER, F. G.: Angiographic diagnosis of pulmonary embolism in the "mitral lung." *Radiology* **87**:705, 1966.
17. WEST, J. B.: Perivascular edema, a factor in pulmonary vascular resistance. *Am. Heart J.* **70**:570, 1965.

AVAILABLE NOW

PROCEEDINGS OF THE SYMPOSIUM ON COMPUTERS AND SCANNING

Edited by John U. Hidalgo

The Proceedings of the "Symposium on Computers and Scanning," held at Tulane University on December 16-17, 1965, are now available from the Society of Nuclear Medicine at a cost of \$5 (\$5.50 outside USA). The symposium, which brought together speakers experienced in both the technology of computers and the technology of scanning, covered the many uses to which computers are now being put in nuclear medicine. The Proceedings contain 19 papers totaling 216 pages. Send orders to: The Society of Nuclear Medicine, 211 East 43rd St., New York, New York 10017.