

NUM / LETTER TO THE EDITOR

USING SPLENIC SCANS TO EVALUATE DIAPHRAGMATIC HERNIA

Diaphragmatic hernia is a common occurrence in radiologic practice. These hernias occur in various portions of the diaphragm and can contain any abdominal viscus—intraperitoneal or retroperitoneal. The case reported here shows how useful isotope scans can be in supplementing radiographic examinations for evaluating the hernial contents and for differentiating an opaque hernia through the foramen of Morgagni from a tumor in the chest.

A 76-year-old woman was admitted to Misericordia Hospital on November 19, 1966, with cystitis.

Conventional PA and lateral roentgenograms of the chest show a mass in the posterior portion of the left side of the chest. The air shadows appear to be overlapping the lesion rather than in it. The small opaque shadow at its inferior margin is barium in the colon which does not enter the hernial sac (Fig. 1).

The AP supine abdominal roentgenogram also shows the opaque lesion in the left lower chest, and the barium-filled esophagus, colon and kidneys are located completely below the diaphragm (Fig. 2).

We performed a splenic scan using the ^{51}Cr heat-

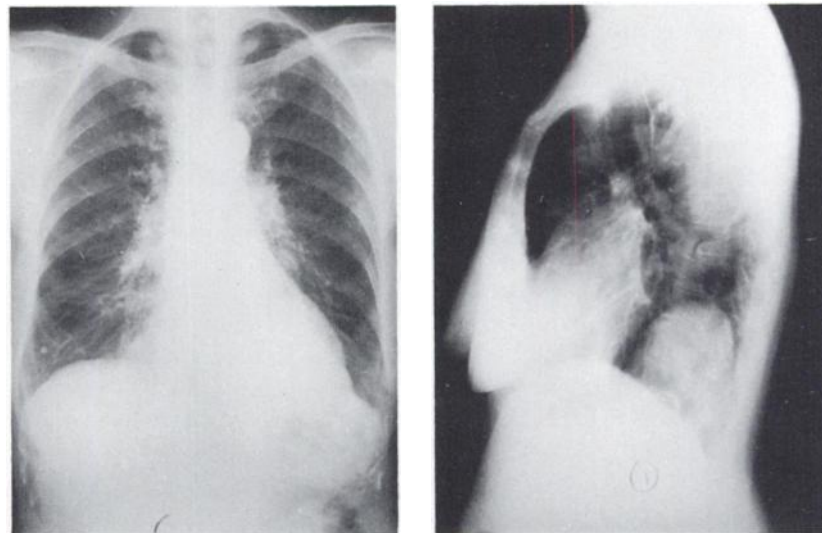


FIG. 1. Conventional PA and lateral roentgenogram of chest mass to be located in posterior portion of chest.

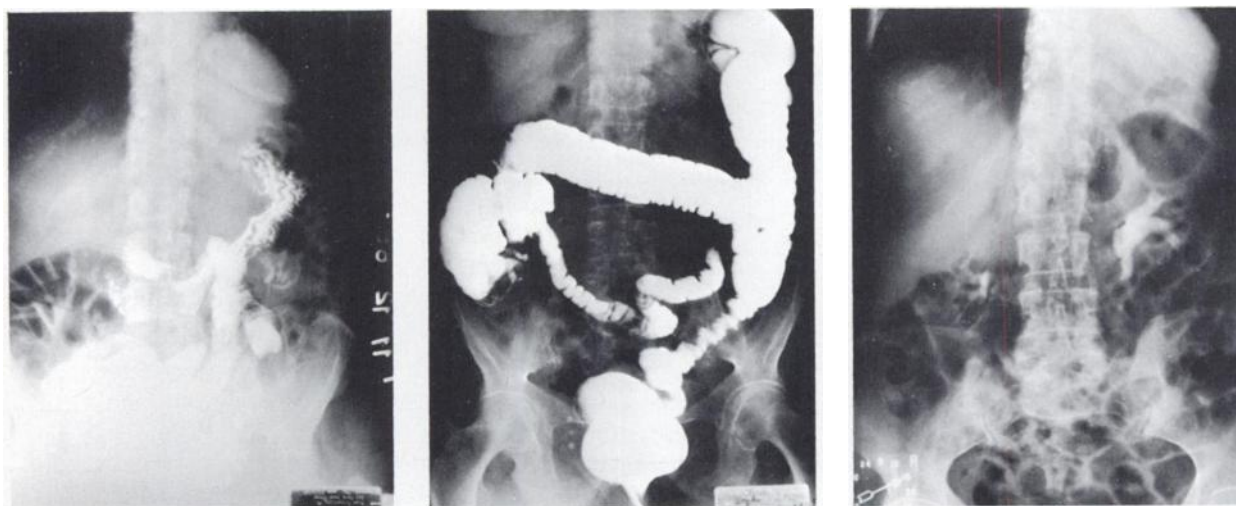


FIG. 2. AP supine abdominal roentgenograms shown above indicate that opaque lesion of left lower chest and barium-filled stomach, colon and kidneys are located completely below diaphragm in this patient.

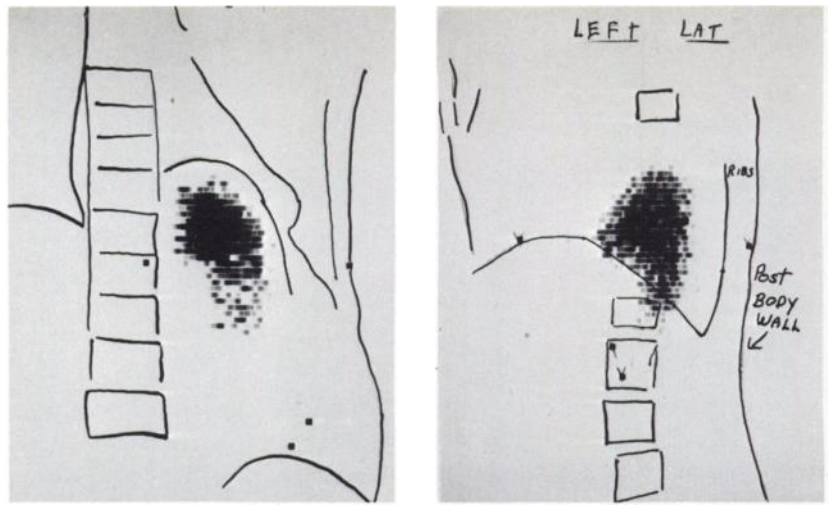


FIG. 3. Posterior and left lateral splenic scans show that spleen is located in hernia.

treated labeled red-blood-cell method using prone and left lateral positions (Fig. 3). These show that the spleen coincides with the shadow on the roentgenograms.

Because the patient was asymptomatic, she was discharged without operative intervention. Thus the splenic scan in this case convincingly showed that

the "mass lesion" was the spleen. While we had considered this a strong possibility on the roentgenograms, the scan was so conclusive that the patient was spared a major thoracic surgical operation.

C. JULES ROMINGER
 Misericordia Hospital
 Philadelphia, Pennsylvania

AN ANSWER TO THE AEC ON ^{197}Hg -CHLORMERODRIN

In his March 18, 1968, letter to medical licensees, Mr. Cecil R. Buchanan of the Atomic Energy Commission announced the removal of kidney scanning with ^{203}Hg -chlormerodrin from the Commission's list of routine, well-established medical uses. Brain scanning with ^{203}Hg -chlormerodrin is considered justifiable only in patients suspected of having deep intracranial lesions (sic). This action was taken on the advice of AEC's Advisory Committee on the Medical Uses of Isotopes. The AEC recommends the use of ^{197}Hg -chlormerodrin and bases this change in policy on "the higher radiation dose to the kidney resulting from the use of ^{203}Hg " and on "reports on the comparability of brain or kidney scans with either agent."

Mr. Buchanan and his Advisory Committee are wrong! They have miscalculated the dose from ^{203}Hg ; they have misjudged the importance of the relative dose between the two isotopes; and, most important of all, they are pushing an isotope which does not have equal efficacy in scanning.

Three "typical" estimates of the kidney dose from ^{203}Hg -chlormerodrin are quoted in the letter (1-3). Two of these (1,3) are truly typical of the dose estimates found in the literature, but the third (2) reports a dose of 223 rads per millicurie of ^{203}Hg -chlormerodrin. An examination of the document quoted shows no such kidney dose. The tables list a kidney cortex dose of 146 rads and a kidney medulla dose of 77 rads. The sum of these two numbers is curiously close to 223. Mr. Buchanan and

his Advisory Committee need to do a little homework on the basic principles of radiation dosimetry. Presumably when the indoor temperature in Washington is 70° and the outdoor temperature is 80° the effective temperature in Mr. Buchanan's office is 150° . In any case, even the original, unembellished data in this ORNL progress report are in error because of wrong assumptions in the biological data. The authors have since issued a corrected report calculating the kidney cortex dose at 75 rads per millicurie in good agreement with most other estimates. This correction was available many months before the circulation of the AEC letter with its "typical" dose of 223 rads per millicurie.

The ratio of ^{203}Hg to ^{197}Hg dose is accurately quoted in the letter as about 8 to 1. This refers to dose over total decay. Since the dose from either isotope is well below any measurable effects, it is difficult to judge the relative harm to the patient, but this damage is more likely to be related to dose rate than to total dose. Because of the relative half-lives, 90% of the ^{197}Hg dose is delivered during the first week and 25% of the ^{203}Hg dose. This makes the ratio for the highest one-week dose only about twice as high with ^{203}Hg on a microcurie for microcurie basis. It is usual to administer 50% more ^{197}Hg than ^{203}Hg . This brings the comparable dose rates very close indeed.

Finally, there is the very obvious question of the diagnostic quality of scans done with ^{197}Hg . Mr. Buchanan refers us to these same three reports