A COMPARISON OF DIFFERENTIAL AND INTEGRAL SCANS

Teruo Nagai and Takeshi A. Iinuma

National Institute of Radiological Sciences, Chiba, Japan

We have recently compared the results of organ visualization by conventional "integral" scanning methods with those obtained with a new scanning technique called "differential" scanning.

In many situations it is important to know the precise relationships of organ size and scanning image, particularly in thyroid, liver and brain scanning. Many factors, such as collimator resolution, levels of background cutoff and film response to light, influence the size of the image in conventional scanning. For this reason, conventional scanning with either analog or digital display is limited to only semiquantitative estimates of organ size.

In spite of the fact that much information is contained in the scanning image, human eyes are rather inefficient in extracting all the useful information from the image. Therefore, image-manipulation techniques are necessary to help one recognize and evaluate such complex patterns as scanning images.

"Differential" scanning is one of the image-manipulation techniques in which the rate of change in density is computed from conventional scanning data and is displayed in a two-dimensional mode. As a result, the edge and contour of an organ are demonstrated more clearly because changes in counting rates are usually larger near the edge of the organ. In contrast to "differential" scanning, the conventional scanning technique can be thought of as "integral" display.

To obtain the "differential" scan, the digital scanning data from the thyroid phantom described previously (*1*) were used as the "integral" scans. There is a "smoothed" and a "computer-focused" version of the "integral" scans.

The computer program undertook the steps shown in Fig. 1. The "differential" calculation was as follows: the square of the difference in counting rates between two adjacent unit areas (1 mm^2) was obtained in two-dimensional directions, and the four values obtained were summed. The final result was calculated by dividing the sum by the average value of the counting rates in the four neighboring unit areas. The figure that results shows the relative gradient of the four counting rates. The same calculation was performed over the entire scanned area (Fig. 2A).

After the calculation mentioned above, we performed a data smoothing to reduce high-frequency fluctuations in the "differential" scans. Digital-to-analog (d-a) converted displays were then plotted automatically from the numerical data using a line printer with different symbols for increasing density. The computation and plotting was carried out by a Burroughs-5500 digital computer and a Burroughs-B 321 printer. The computer time for the procedure was approximately 10 min.

Fig. 2B shows a d-a converted plot of the "differential" scan calculated from the "computer-focused" data in which "differential" values were divided into six increments of various densities. One can see that the size and contour of the thyroid phantom, shown by an autoradiogram in Fig. 3A, are clearly demonstrated.

For comparison, two "integral" scans (smoothed and computer-focused) of the same phantom are also shown in Fig. 3B and C. In this case, the computer was programmed to seek the highest counting rate on the entire numerical array and then divided counting rates in all unit areas by the highest one to obtain seven logarithmic assignments corresponding to photographic density. From these "integral" patterns it may be difficult to recognize the definite contour of the phantom because levels of background cutoff influence the size of the images.

Fig. 2C shows a transverse digital profile at the line marked a-b on Fig. 3A comparing the "differential" profile with the "integral" one. The distance between the right and left peak represents the size of the phantom because as the right edge of the phantom enters the center of the focus of the honeycomb collimator used, counting rate will increase at a maximum rate and as the left edge leaves the center, counting rate will fall at a maximum rate. The graph shows that the distance between the two peaks is 60 mm.

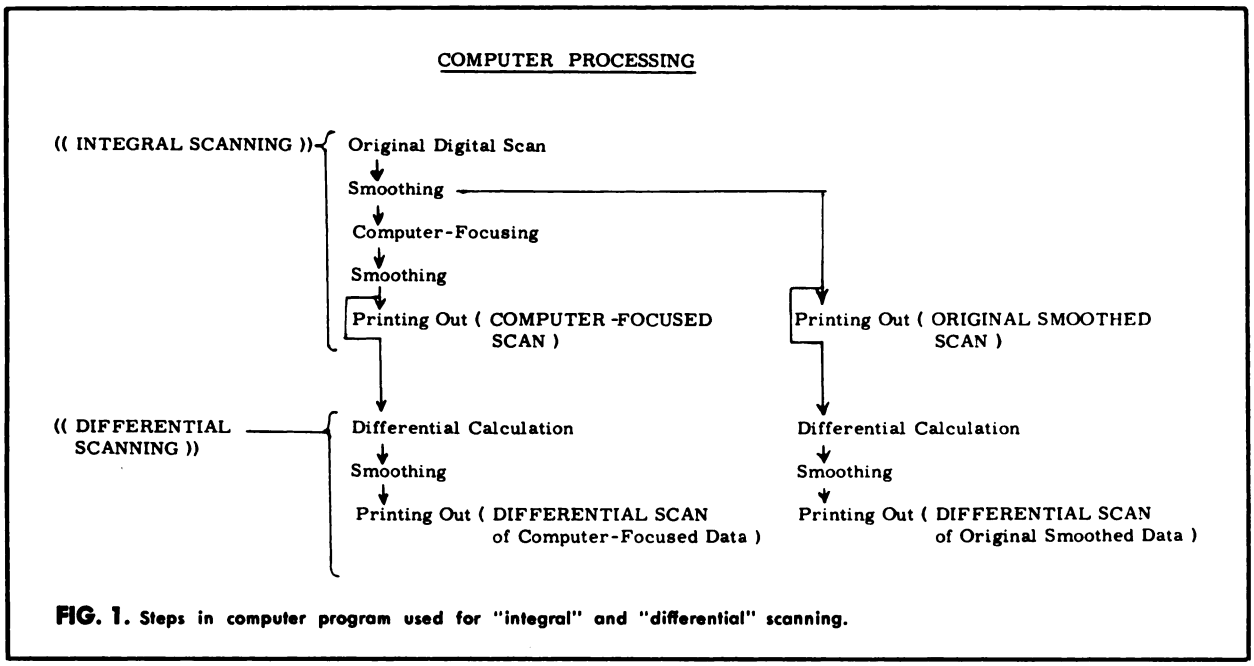

FIG. 1. Steps in computer program used for "integral" and "differential" scanning.

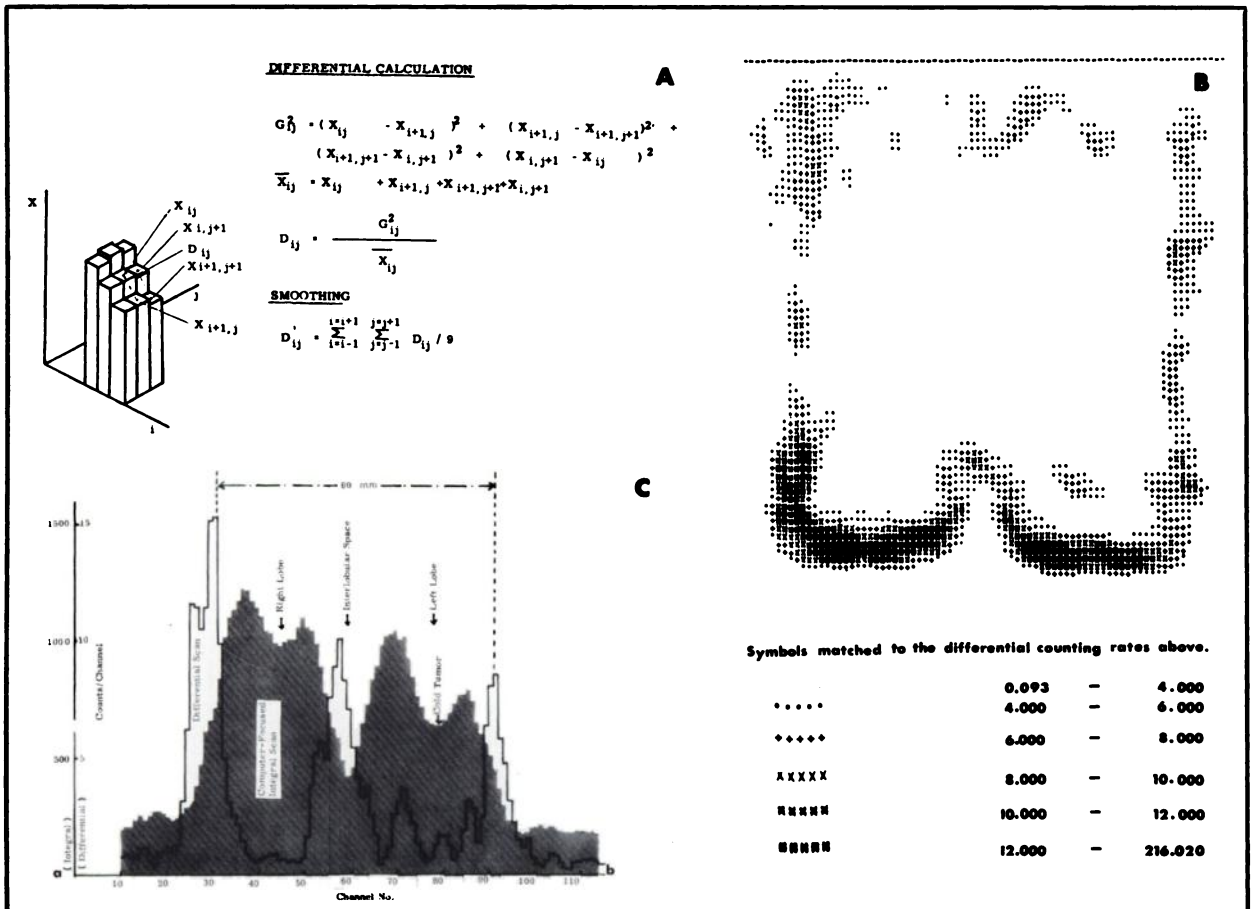

FIG. 2. "Differential" scanning. A shows differential calculation and smoothing. B shows differential scan of computer-focused data. C shows transverse profile obtained at line marked a-b in Fig. 3A.



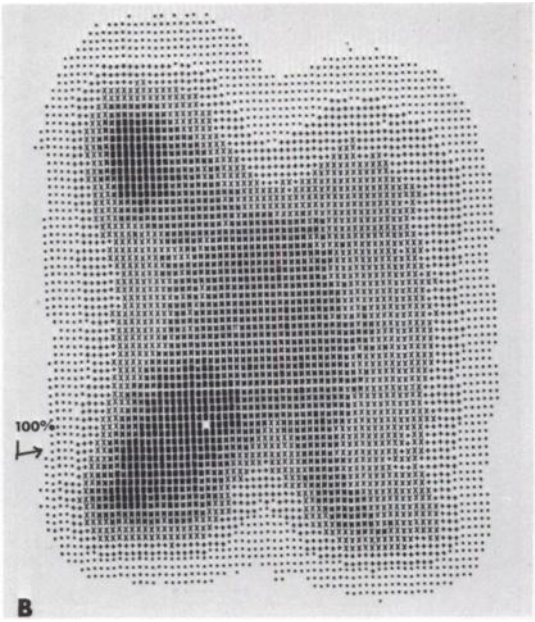

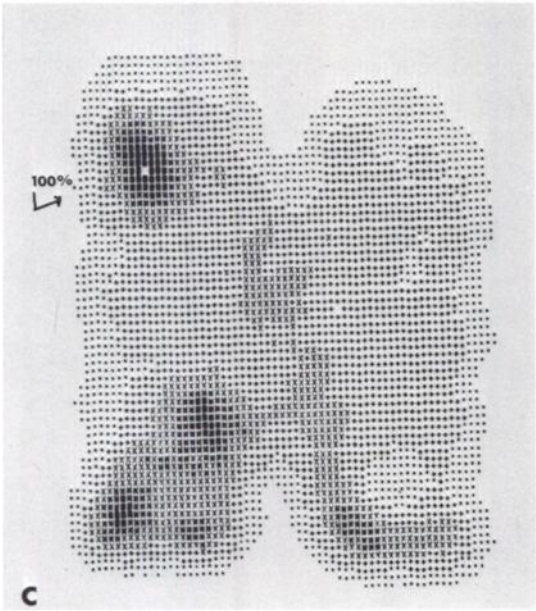

Symbols matched to the counting rates in Figs. 3B and C.

	0.0%	–	35.9%
•••••	35.9%	–	55.3%
+++++	55.3%	–	68.6%
XXXXX	68.6%	–	78.8%
■■■■■	78.8%	–	87.1%
■■■■■	87.1%	–	94.0%
■■■■■	94.0%	–	100.0%

FIG. 3. A: Autoradiogram showing unexpectedly high concentration of activity on perimeter was caused by capillary phenomenon and is shown on phantom. B: Integral scan of thyroid phantom plotted with Burroughs-B 321 printer. C: Computer-focused scan.

Although the "differential" calculation was also applied to the "smoothed" scan, we found that the "computer-focused" scan was more desirable for this technique because the difference in counting rates at the edge was much greater in the latter than in the former.

In our preliminary studies, "differential" scanning seems to have an important application in the precise delineation of organs or hot tumors such as brain, bone tumors and metastatic thyroid cancers. It seems, however, to be less efficient in detecting cold lesions of relatively decreased radioactivity or warm lesions surrounded with tissue containing some radioactivity, because in these cases the "differential" values would be rather small. In some clinical cases contour of an organ displayed by the "differential" technique may not represent the true contour of the organ since organs usually have a rounded peripheral margin and are surrounded by varying levels of radioactivity in the blood and adjacent organs.

Theoretical considerations on this matter and the mathematical background of the "differential" scanning will be published in detail elsewhere.

Although several problems remain to be solved, we believe that the "differential" image together with the conventional "integral" image—preferably a "computer-focused" one—will be helpful in making more accurate diagnosis.

REFERENCE

1. Nagai, T., Iinuma, T. A. and Kida, S.: Computer-focusing for area scans. *J. Nucl. Med.* To be published.