

## Amniotic Fluid Studies by Isotope Dilution and Scanning<sup>1</sup>

Richard P. Spencer, M.D., Ph.D.,<sup>2</sup> Gerald Fishbone, M.D.,  
Clarence D. Davis, M.D.

*New Haven, Connecticut*

Radiolabeled water and electrolytes introduced into the amniotic fluid undergo exchange with the maternal circulation (1). If a substance is utilized that exchanges only slowly, a means is at hand for estimating the amniotic fluid volume and for scanning the amniotic fluid space. A principal reason for slowness in developing this topic has been, of course, concern with entering the amniotic sac. Recent developments in the area termed *fetology* have shown that careful aseptic technique can be used for transabdominal sampling of the amniotic fluid (and even to carry out transfusions on the fetus in utero) without undue risks (2). Once the amniotic sac is entered, it is possible to carry out studies on the volume of the contained fluid by radioisotope dilution, and to scan the amniotic fluid space. Three instances of the procedure, in a pregnant sheep and two pregnant young women, are presented. A brief discussion is given of possible clinical applications.

### METHODS

The patients were not pretreated with stable iodide. The amniotic sac was entered from the skin surface by means of a long sterile needle of 20 gauge. After removal of one milliliter of amniotic fluid, 50  $\mu$ C of <sup>131</sup>I-human serum albumin were introduced in a volume of one milliliter. The syringe was pulled back and forth several times to allow entry of most of the labeled albumin; subsequent

---

<sup>1</sup>Supported by Grants CA06519 and AM09429 from the U.S. Public Health Service.

<sup>2</sup>Departments of Radiology and Obstetrics & Gynecology, Yale University School of Medicine, New Haven, Connecticut.

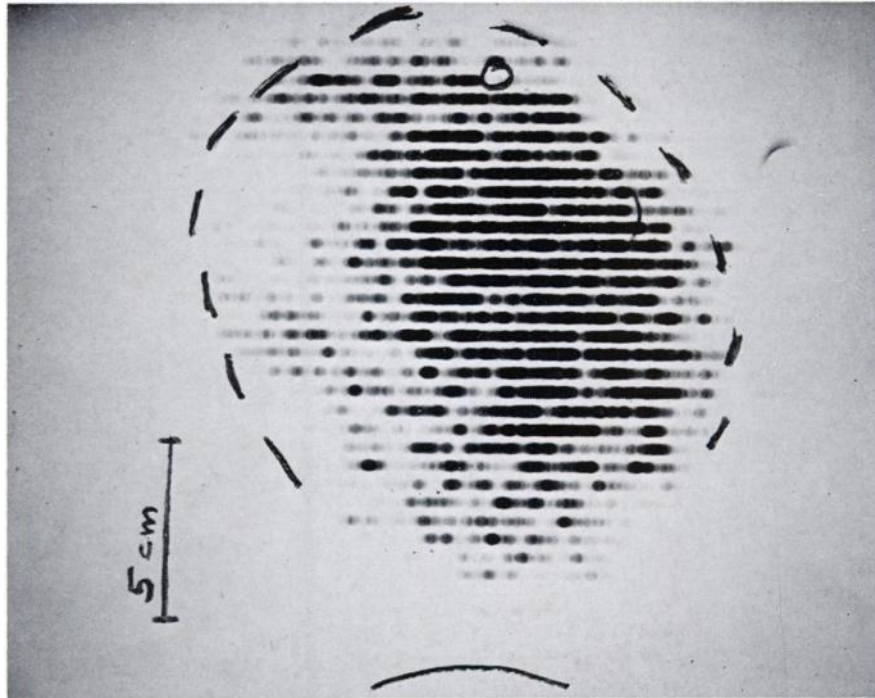


Fig. 1. Amniotic fluid scan in Case 1.

counting of the needle and syringe revealed that less than 0.5% of the original radioactivity remained. The initial study, on a Columbian sheep near term, showed the procedure could be readily carried out and a distinct outline obtained of the amniotic fluid space.

Two young women were studied, during the fourth month of gestation, just before the induction of therapeutic abortion. Anteroposterior scans were performed using a Picker Magnascanner, one hour after introduction of the radioalbumin. From only one patient (Case 1) was it possible to obtain multiple blood and urine samples, as well as a specimen of amniotic fluid 1 and 24 hours after the procedure (the latter just prior to the beginning of labor). The fetus was also monitored after delivery in this case.

#### RESULTS

Amniotic fluid scans are shown in Figures 1 and 2; palpable edges of the uterus are indicated by dotted lines. In the first case, there is a negative defect on the right side, while in Case 2 a similar defect appears at the upper portion of the uterus.

By dilution of the injected radioalbumin, assuming all of it to be within the amniotic fluid at one hour, a volume of 800 ml was calculated for Case 1. Radioactivity in the patient's blood did not exceed two per cent of the injected dose in any sample, using a value of 70 cc blood/kg body weight. The 24 hour urine collection contained about two per cent of the radioactivity introduced into the




Fig. 2. Amniotic fluid scan in Case 2.

amniotic fluid. At 24 hours, assuming the amniotic fluid volume was unchanged from its initial value, a sample revealed 94% of the radioactivity still to be present.

#### DISCUSSION

More experience will be necessary before negative regions on the amniotic fluid scans can be definitively assigned to the placenta or to the fetus. Possible uses of the procedure are in estimating amniotic fluid volume, its distribution, placental localization, and fetal position after engagement. Because of absorption of most of the radiation in the fluid, scanning from several positions may be necessary for precise determination of the fetal position.

Within the first 24 hours after injection, only small amounts of radioactivity had left the amniotic fluid space. There was less than one per cent bound to the fetus, as determined by counting after delivery in Case 1. The exact radiation dose received by the fetus will depend, in part, on such factors as whether it is completely surrounded by amniotic fluid, or is pressing against the uterine wall. Calculation of the radiation dose to objects floating in a radioactive solution can be accomplished by known techniques (3). These initial cases received  $50 \mu\text{C}$  of  $^{131}\text{I}$ -albumin. The count rate on the scanner was higher than necessary to obtain a reliable scan; hence, later studies will be performed with only 10 or 20 microcuries. If delivery occurs within a few hours after the radioalbumin is introduced, radiation dose to the fetus will not be excessive. For purposes of comparison, Table I shows that at one hour there is but little difference between the  $\beta$  radia-

TABLE I  
*Time Following Start of Procedure*

<i>Isotope</i>	<i>1 hour</i>	<i>1 day</i>	<i>Total Decay</i>
<sup>131</sup> I	0.02	0.45	5.6
<sup>125</sup> I*	0.0029	0.069	6.0
<sup>128</sup> I	0.032	0.04	0.04

Beta dose (rads) to fluid following injection of 50  $\mu$ C of the indicated iodine radioisotope into 1,000 ml of amniotic fluid, assuming complete and uniform mixing and deposition of the total beta energy in the fluid.

\*Part of emission treated as a beta ray for these calculations.

tion dose from three iodine radioisotopes, with <sup>125</sup>I, giving a slightly lower radiation exposure than the others [the <sup>125</sup>I emission was partly treated as a beta ray (reference 3, p. 326); the radioiodine isotopes also have  $\gamma$  contributions].

The volume of amniotic fluid can be determined by injecting dyes that leave the fluid space only slowly and then sampling the liquid (4). Such a technique, however, does not offer the possibility of scanning the fluid space in order to detect placental localization or the position of the engaged fetus. If short-lived radioisotopes are used in these studies, or delivery occurs shortly after introduction of the radioisotope, there will be no appreciable radiation of the fetus.

#### SUMMARY

An initial approach to radioisotope scanning of the amniotic fluid space was presented, and possible uses of the procedure discussed.

#### REFERENCES

1. PLENTL, A. A.: The dynamics of the amniotic fluid. *Ann. N.Y. Acad. Sci.* **75**:746-761, 1959.
2. LILEY, A. W.: The use of aminocentesis and fetal transfusion in erythroblastosis fetalis. *Pediatrics* **35**:836-847, 1965.
3. QUIMBY, E. H.; FEITELBERG, S.: Radioactive isotopes in medicine and biology. Basic physics and instrumentation. pp. 115-116. Lea & Febiger. Philadelphia. 1963.
4. ELLIOTT, P. M.; INMAN, W. H. W.: Volume of liquor amnii in normal and abnormal pregnancy. *Lancet.* **2**:835-840, 1961.