

Lung Scanning Following Radioaerosol Inhalation²

G. V. Taplin,¹ N. D. Poe, A. Greenberg

Los Angeles, California

INTRODUCTION

The pulmonary distribution of inhaled radioactive particles and their clearance from the lung were studied exhaustively during the last 20 years to evaluate potential radiation hazards (1). Airborne particles smaller than 1-2 μ are known to be distributed evenly throughout the entire respiratory tract, including the terminal bronchioles and alveoli. Soluble aerosols, such as sodium penicillin, are rapidly absorbed into the blood (2). Insoluble plutonium oxide particles are more slowly removed by the ciliary escalator mechanism and by phagocytosis with subsequent transposition to the hilar lymph nodes (1).

Visualization of the bronchial tree radiographically requires the intratracheal instillation of several grams of radiopaque material. The procedure is known to be hazardous in patients with impaired pulmonary function. Furthermore, bronchography does not permit visualization of the small branches near the lung periphery. Thus, a need exists for a method to determine airway patency in obstructive bronchopulmonary disease when bronchography is contraindicated.

This report describes the development of a safe radioaerosol inhalation procedure and lung scanning technique using commercially available radiopharmaceutical agents in minute quantities and standard respirator-nebulizer equipment. The results of basic studies in dogs and preliminary applications in patients with obstructive bronchopulmonary disease are presented. Radiation exposures to the lungs and contamination of the examining room and personnel can be maintained within permissible limits.

¹From the Laboratory of Nuclear Medicine and Radiation Biology, School of Medicine, University of California at Los Angeles; and the Department of Radiology, Los Angeles County Olive View Hospital, Olive View, Calif.

²These studies were supported by Contract AT(04-1)-GEN-12 between the U.S. Atomic Energy Commission and the University of California at Los Angeles, and by a grant-in-aid from Abbott Laboratories, North Chicago, Illinois.

MATERIALS AND METHODS

Test Agents: Numerous radiopharmaceuticals were aerosolized and administered to dogs by inhalation. These agents included human serum albumin, rose bengal and orthoiodohippurate labeled with ^{131}I and ^{125}I , ^{197}Hg chlormerodrin, colloidal ^{198}Au , silver coated colloidal ^{198}Au and $^{99\text{m}}\text{Tc}$ albumin. The orthoiodohippurate and inorganic sodium iodide were unsatisfactory because they are too rapidly absorbed from the lung. The silver plated ^{198}Au colloidal gold was surprisingly almost completely retained and very slowly removed as compared with colloidal gold and most of the other test materials, which had half-time removal rates ranging between two and six hours.

Autoradiography: Lung autoradiographs were prepared according to the film dipping method used in the Medical Research Center, Brookhaven National Laboratory, Upton-Long Island, New York (3).

Inhalation Studies: In dogs weighing 7 to 19 kg and anesthetized with pentobarbital, the radioaerosol was administered via a cuffed endotracheal tube. This tube is attached to a positive pressure respirator¹ equipped with a nebulizer and exhalation manifold. The exhaust line from the manifold is passed through the filter and the inhalation procedure is carried out in a vented hood (Fig. 1). Three to 4 ml of radioactive solution containing approximately 1 mC of isotope, 10% glycerin and 0.2% tyloxopal² are nebulized in a 30-60 minute period. The animals are then scanned in routine fashion. The effects of posture, complete and partial bronchial obstruction and of experimental pulmonary embolism were studied by serial scanning. Scan findings were then correlated with autopsy results.

Six normal subjects and 75 patients with various lung disorders were examined. A similar respirator-nebulizer with a mouthpiece and exhalation manifold was used.³ The exhalation line runs through a filter and is exhausted through a vented hood or is passed through a window for dilution in the outside atmosphere. Three to 4 ml of the same radioactive solutions used for animals are nebulized and inhaled 10-20 minutes and the patient is scanned in both the prone and supine positions. An intravenous chest scan may be performed immediately after this procedure or the next day. (For combined inhalation and intravenous scans on the same day, radionuclides of widely different gamma energy spectra are used.)

RESULTS

Scans in Dogs: After inhalation little radioactivity is detectable in the trachea or major bronchi. The half-time in the anesthetized dog lung ranges from 6-24 hours being prolonged by deep anesthesia. More soluble substances such as chlormerodrin, which are both absorbed and cleared by ciliary action have shorter half times than those cleared by ciliary action alone, *e.g.* serum albumin.

¹Bennett Model PR-1 Respiration Unit, Santa Monica, California.

²Rohm and Haas Co., Philadelphia, Pennsylvania.

³Bird Mark 7 Respirator, Richmond, California.

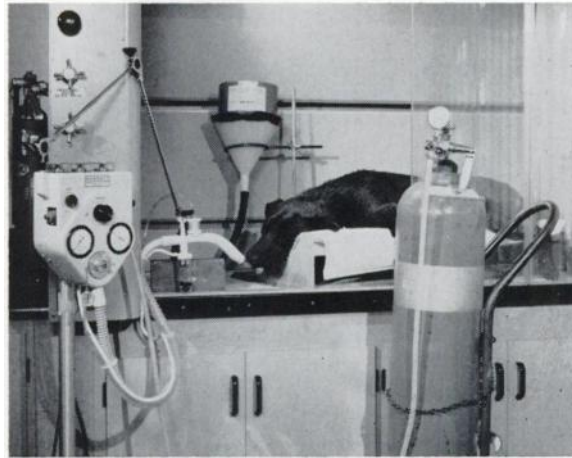


Fig. 1. Photograph showing the positive pressure respirator-nebulizer connected to the cuffed endotracheal tube in the dog and the exhalation line and filter within a ventilated hood.

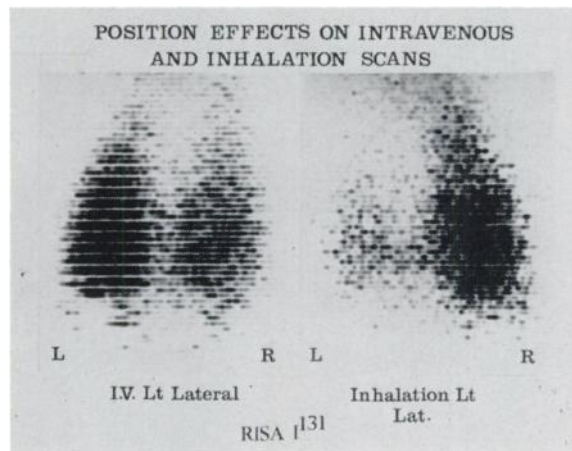


Fig. 2. Position effects on intravenous and inhalation scans.

When animals are inhaled in the lateral position, larger amounts of activity are deposited in the superior lung, although bronchspirometric studies have demonstrated greater ventilation of the inferior or dependent lung (4), (Fig. 2). In complete bronchial obstruction no radioactivity is seen distal to the obstruction (Fig. 3). However, with partial obstruction variable amounts of activity are present distally and the obstruction site itself may appear as an area of increased radiodensity (Fig. 4). Complete obstruction of a *segmental* pulmonary artery produces no detectable change in the inhalation scan in most animals (Fig. 5). In obstruction of major arteries various degrees of impaired deposition occur sequentially within the ischemic lung field when the scans are repeated at frequent intervals during the first month (Fig. 6).

Pulmonary Distribution of Inhaled ^{125}I Albumin Aerosols: The pulmonary distribution of inhaled ^{125}I albumin aerosols was determined in the dog by au-

toradiography of thin histological sections taken shortly after inhalation was completed. Numerous stained lung sections¹ were examined and selected samples are present in the composite (Fig. 7). This study demonstrates that the inhaled particles penetrate to the alveoli where they are readily detectable on the epithelial surface and in the alveolar space. Higher concentrations of radioactivity are found on the mucosal surfaces of the large and small bronchi and bronchioles. No radioactivity is visible within the vascular system and no evidence of phagocytosis was observed in these sections.

Scanning of Patients: The lung scans of individuals who inhaled ^{131}I or ^{198}Au aerosols are very similar to their intravenous scans with ^{131}I macroaggregates, except that variable amounts of radioactivity are seen in the mouth, pharynx and stomach (Fig. 8). With ^{125}I or ^{197}Hg inhalation, the lung scan image frequently is smaller than the intravenous one with ^{131}I because of greater tissue absorption. Half-times of these aerosols in the normal human lung range from two to six hours. In abnormal conditions, the changes on the intravenous

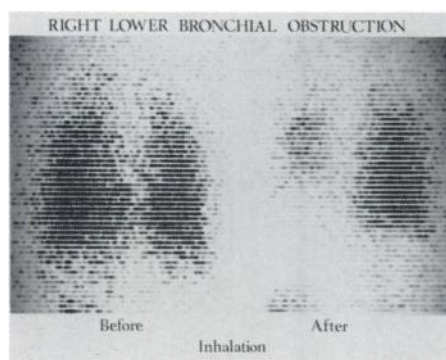


Fig. 3. Dog lung inhalation scans before and after complete bronchial obstruction, right lower lung.

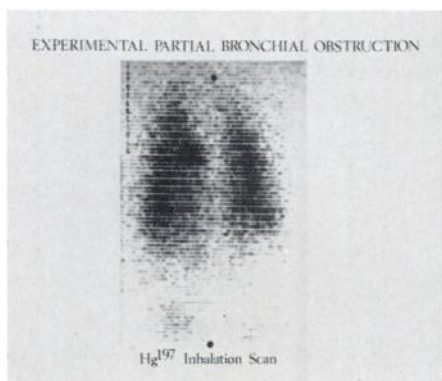


Fig. 4. Dog lung scan following experimental partial obstruction of the left main bronchus.

¹Stained with Dominicus stain through the NTB₃ dipping emulsion (Eastman Kodak Co., Special Products Division, Rochester, N. Y.).

scan are generally reflected in the inhalation scan (Fig. 9). However, in certain conditions distinct differences are found. In bronchiectasis, areas of increased radiodensity may appear on the inhalation scan in regions which are well perfused (Fig. 10). Presumably, these areas of increased radiodensity represent the sites of partial bronchial obstruction.

Calculation of Pulmonary Radiation Exposures: The calculated values for beta plus gamma exposures from various inhaled radioaerosols are shown in Table I. The calculations were based on half-time in the lungs of two hours and for the deposition of $100 \mu\text{C}$ using Quimby's formula (5). To obtain accurate exposure values in individual cases it is necessary to estimate the amount of isotope initially deposited and to measure lung radioactivity subsequently to de-

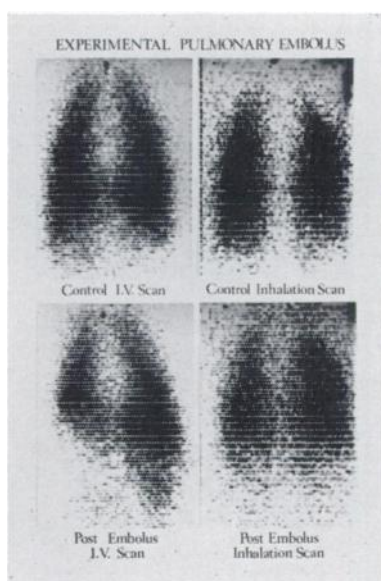


Fig. 5. Dog lung scans (intravenous and aerosol inhalation) before and after experimental pulmonary embolism to the left diaphragmatic lobe.

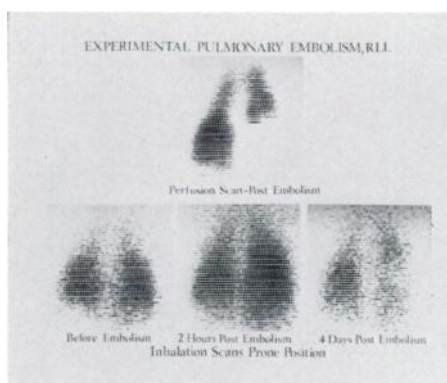


Fig. 6. Dog lung scans (perfusion and inhalation) following experimental embolism of major arteries of the right lower lung.

termine the half-time removal rate. The lung exposure from ^{99m}Tc albumin, in comparison with the other agents, shows that this material gives approximately 20 times less lung exposure than an equivalent dose of ^{198}Au colloid.

DISCUSSION

Lung scanning following radioaerosol inhalation was not developed until recently (6) for lack of special equipment designed for this purpose and for fear of radiation contamination. Hand operated nebulizers require 30-60 minutes to aerosolize 1-2 ml of solution and, most of the dose is deposited in the mouth and pharynx and relatively little in the lungs. Currently available respirator-nebulizer units are not designed to produce radioaerosols from 1-2 ml volumes of high specific activity test solutions. Furthermore, without a closed system to trap the exhaled air, the examination room and personnel would become heavily contaminated. A high flow, low resistance filter with the capacity to retain over 99% of particles greater than 0.3μ in diameter is shown to be quite satisfactory. With this filter, the isotope concentration in the exhausted air is several orders of magnitude below the permissible limits of $4 \times 10^{-8} \mu\text{C/ml}$ (7).

The radioaerosol inhalation and scanning techniques described in this paper are safe, but still relatively inefficient and excessively time consuming. Further study is needed to increase pulmonary retention and to reduce the time for aerosol inhalation.

Suitable Test Agents: Economically, colloidal ^{198}Au is the most suitable agent. It is removed rapidly from the lung mainly by ciliary action and is not

TABLE I

PULMONARY RADIATION EXPOSURES (From Inhaled Radioaerosols)

<u>RADIOISOTOPE COMPOUND</u>	<u>LUNG β AND γ DOSE (Rad)</u>
^{198}Au colloid	0.216
^{131}I albumin or rose bengal	0.134
^{197}Hg chlormerodrin	0.046
^{125}I albumin	0.017
^{99m}Tc albumin	0.011

CALCULATION: (Quimby Formula). Based on 100 μC of isotope deposited and retained for a half time of 2 hours.

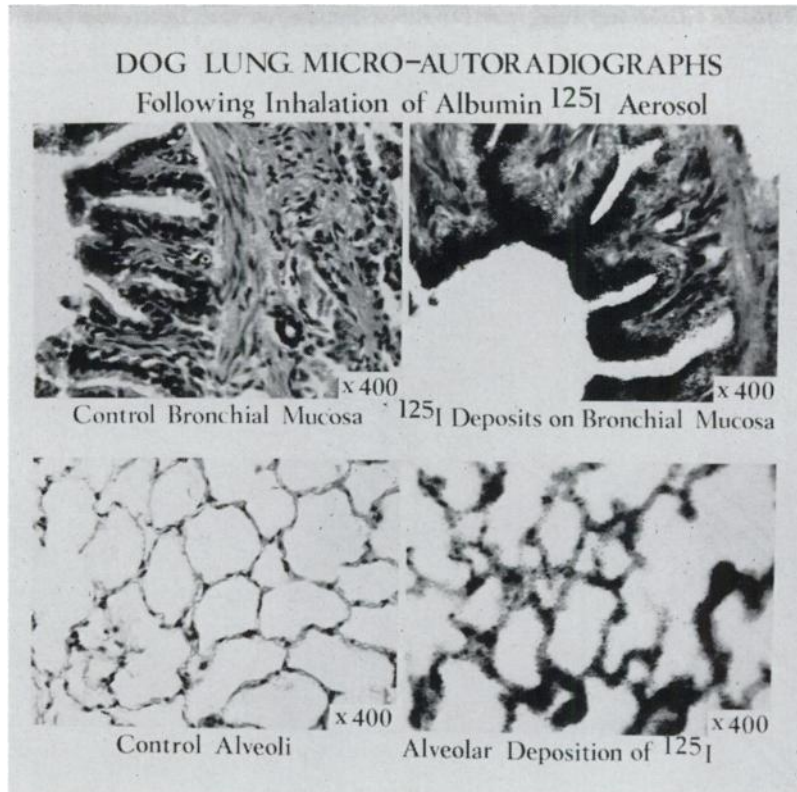


Fig. 7. Dog lung micro-autoradiographs following inhalation of albumin ^{125}I aerosol.

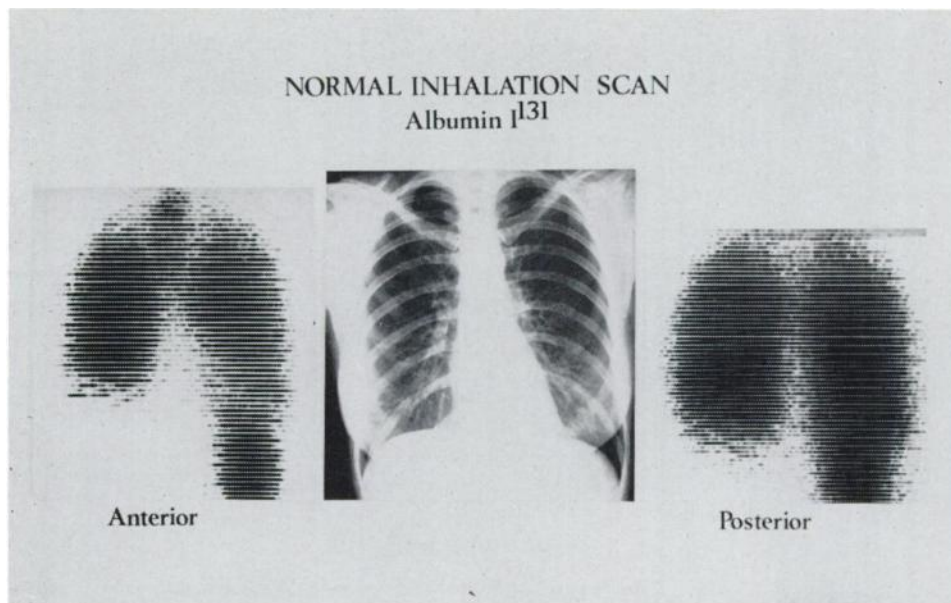


Fig. 8. Normal human inhalation lung scans and chest x-ray.

absorbed from either the lung or the intestine. However, because its energy is so similar to ^{131}I , it cannot be used on the same day with ^{131}I albumin macroaggregates for combined studies of bronchial patency and regional blood flow by lung scanning. For this purpose, aerosols of ^{197}Hg chlormerodrin or $^{99\text{m}}\text{Tc}$ labelled albumin are preferable. The latter gives the least radiation exposure because of its six hour half-life and lack of beta ray emission. With further experience and multiple uses, $^{99\text{m}}\text{Tc}$ albumin is likely to become the agent of choice for this type of lung scanning in the near future.

Significance of the Inhalation Lung Scan Image: Under normal conditions the entire lung field is outlined, indicating the patency of the lower bronchial tree. Complete obstruction of a major bronchus produces absence of radioactivity in the region normally ventilated by this bronchus. However, the amount of radioaerosol deposited in any given portion of the lung is not always proportional to the air flow to that region. Factors other than diffusion, which are involved with aerosols but not with gases, include particle size, sedimentation impaction, concentration of aerosol and the rate of air movement (1). High aerosol concentration in regions of low air flow promote increased deposition by sedimentation. This effect is seen most clearly in animals inhaled in the lateral position. The residual volume of the upper lung is increased; whereas, that of the lower lung is reduced secondary to shifts in abdominal and mediastinal contents and to increased pressure on the lower chest wall. In this position, the tidal volume of the upper lung is reduced although its total volume is in-

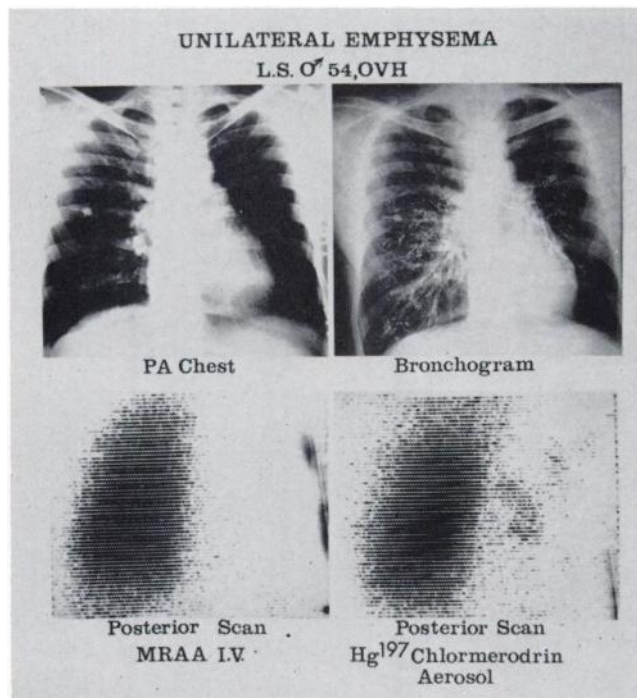


Fig. 9. The chest x-ray, bronchogram and similarity of posterior intravenous and inhalation lung scans in unilateral emphysema.

creased (4). Slow air movement favors deposition by sedimentation in the upper lung.

With partial experimental obstruction from a foreign body the obstruction site usually appears as a small area of increased radioactivity and the region distal to it has less radioactivity than the surrounding normal lung. The increased deposition at the obstruction site is probably related to aerosol impaction due to rapid air flow through the narrowed orifice. In patients with bronchiectasis, areas of increased radiodensity appear in the scan image in regions that conceivably could be points of partial obstruction. These areas clear rapidly as determined by serial scanning, indicating that they are not simply pockets of radioactivity in saccular areas. However, partial obstruction produced by suturing a portion of the bronchus, does not increase the amount of deposition at the obstruction site. Thus at present, there is too little information both experimentally and clinically to evaluate the lung scan image accurately in partial bronchial obstruction.

Embolization of major pulmonary arteries is known to be accompanied frequently by bronchoconstriction and may be followed by atelectasis. Such reactions may represent protective mechanisms for reducing the ventilation of non-perfused lung tissue. Studies of segmental pulmonary embolism in otherwise normal dogs have not shown reduction in aerosol deposition in the avascular areas. However in lobar artery obstruction, a sequence of changes has been observed. In an animal with proved atelectasis of the right diaphragmatic, cardiac and intermediate lobes, following massive embolism, there was an increase in aerosol deposition during the first hour but at four days a marked decrease occurred and finally at 21 days the atelectatic area was completely devoid of radioactivity. Other investigators (8) have shown in dogs with occlusion of the *right* main pulmonary artery, that the minute volume of the opposite *left* lung increases initially to an average near 60% from its control value of 45 per cent.

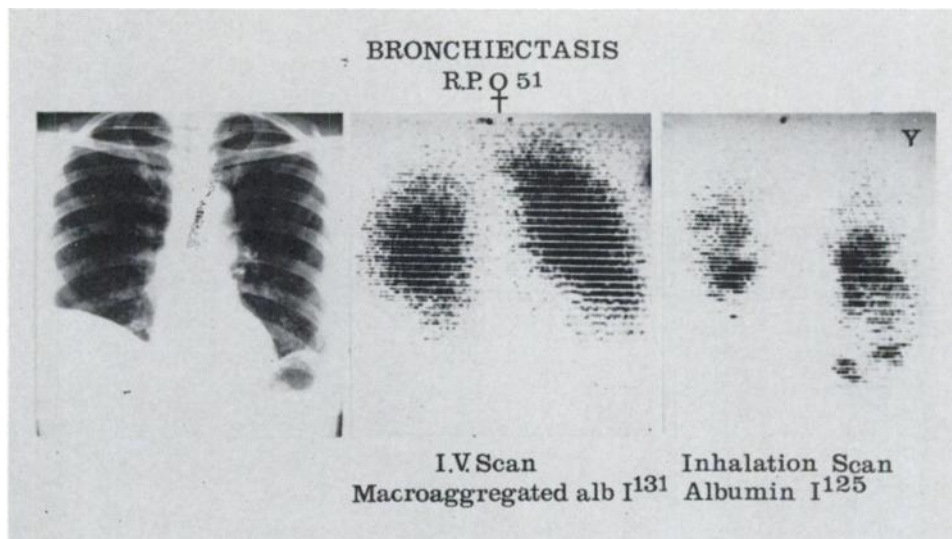


Fig. 10. Chest x-ray and intravenous and inhalation scans in bronchiectasis.

This situation is analogous to that of the *dependent lung* of the animal inhaled in the lateral position, in which there is increased air exchange but reduced aerosol deposition (4). To date, no aerosol inhalation studies have been performed in patients with proved pulmonary embolism. Further clinical and animal experiments are needed to elucidate the mechanisms of aerosol deposition involved in pulmonary embolism.

Other Applications of Inhalation Lung Scanning: Aside from clinical applications, the scanning technique offers a new approach to the study of physiologically and pharmacologically induced changes in bronchial patency and pulmonary air flow. Serial scans of the lung and various organs of excretion can provide qualitative and semi-quantitative information on rates and pathways of clearance of inhaled materials. Scanning offers a unique method for evaluating the pulmonary distribution of medicinal aerosols and the effectiveness of commercial nebulizers.

SUMMARY

The development of a safe technique for visualizing the lower respiratory tract by chest scanning following inhalation of suitable radioaerosols is described. The aerosolization equipment and test agents are readily available. Filtration of the exhaled air and channeling it to a vented hood or to the outside atmosphere prevents contamination of the examining room and personnel. Normally, inhaled radioactive particles smaller than 1-2 μ are evenly distributed throughout the lungs and penetrate to the distal alveoli. Inhalation and intravenous lung scans have nearly identical patterns in normal subjects. The inhalation scan pattern represents the distribution of airborne particles deposited throughout the lower respiratory tract, but the amount of radioactivity in any given portion of the lung is not always proportional to air flow to that region. Aerosol deposition is related to factors other than diffusion, such as particle size, sedimentation, impaction, concentration of aerosol and the rate of air movement. When inhalation is performed with the subject in the lateral position, greater amounts of aerosol are deposited in the superior lung, where ventilation and perfusion are reduced. With partial bronchial obstruction, increased deposition of radioaerosol may occur at the obstruction site and the region beyond usually shows reduced levels of radioactivity. Complete bronchial obstruction is readily detectable in the inhalation scan as an area devoid of radioactivity. A normal lung image indicates patency of the lower respiratory passages.

The radioaerosol inhalation scanning procedure is a useful adjunct to bronchography in the assessment of airway patency. It may be employed safely when bronchography is contraindicated as in patients with impaired pulmonary function. Additional applications of the inhalation scanning procedure are mentioned.

ACKNOWLEDGMENTS

The authors wish to express their appreciation to Mitsue Yamaguchi for preparing the autoradiographs, to Mary Lee Griswold for preparing the macroaggregated albumin supplies, to Linda Callaghan and Jon Bokelman for technical

assistance with the animal studies and to Thomas Darnell for health physics counseling, all of the Laboratory of Nuclear Medicine and Radiation Biology; to Jean Price for technical assistance with the clinical studies at the Los Angeles County Olive View Hospital, to Doralee Laney and her associates of the Inhalation Therapy Section at Olive View Hospital for conducting the radioaerosol inhalation procedure in patients; to Drs. Paul Numerof and Gordon Lindenblad of E. R. Squibb and Sons, to Dr. Howard Glenn of Abbott Laboratories for donating the radioisotopes used in this study.

REFERENCES

1. KORNBERG, H. A., et al: *Effects of Inhaled Radioactive Particles*, Report of Subcommittee on Inhalation Hazards, Committee on Pathological Effects of Atomic Radiation, Pub. 848, NAS, NRC, Wash., D. C., 1961.
2. TAPLIN, G. V., BRYAN, F. A., BAURMASH, L., GREENE, W. W., HAYES, E., RALSTON, W., ADOLPH, W.: Relation of particle size to inhalation therapy with micropulverized penicillin preparations, *Ann. Western Med. and Surg.* 4(8):383-390, 1950.
3. ADAMIK, E. R.: Laboratory procedures for tritium autoradiographs (used at Medical Research Center, Brookhaven National Labs., Upton-Long Island, N. Y.), 1961.
4. SVANBERG, L.: Influence of posture on the lung volumes, ventilation and circulation in normals: A spirometric-bronchspirometric investigation, *Scand. J. Clin. Lab. Invest.* 9:1-195 Suppl. 25, 1957.
5. QUIMBY, E. J., FEITELBERG, S.: *Radioactive Isotopes in Medicine and Biology*, Lea and Febiger, Philadelphia, Penn., 1963.
6. TAPLIN, G. V., POE, N. D.: A dual lung scanning technique for evaluation of pulmonary function, *Radiology*, 85:364-368, 1965.
7. California Administrative Code, Title 17, Section 30355, Appendix A, 1962.
8. SEVERINGHAUS, J. W., SWENSON, E. W., FINLEY, T. N., LATEGOLA, M. T., WILLIAMS, J.: Unilateral hypoventilation produced in dogs by occluding one pulmonary artery, *J. Appl. Physiol.* 16(1):53-60, 1961.

**THE INSTITUTE FOR MATERIALS RESEARCH OF THE
NATIONAL BUREAU OF STANDARDS**

Announces the

First IMR International Symposium

"TRACE CHARACTERIZATION—CHEMICAL AND PHYSICAL"

(Present Capabilities and Future Potential)

October 3-7, 1966

**National Bureau of Standards
Gaithersburg, Maryland, U.S.A.**