

Redifferentiation of a RET-Fusion, Radioiodine-Refractory, Differentiated Thyroid Cancer with Selpercatinib: Flip-Flop Between [^{18}F]FDG PET/CT and ^{131}I Posttreatment Scanning

Floriane Barbry^{*1}, Benjamin Chevalier^{*2}, Amandine Beron², Georges Lion², Samuel Boury³, Camille Marciniak⁴, Clio Baillet², Christine Do Cao⁵, and Arnaud Jannin⁵

¹Endocrinology Department, Tourcoing Hospital, Tourcoing, France; ²Nuclear Medicine Department, Lille University Hospital, Lille, France; ³Radiology Department, Lille University Hospital, Lille, France; ⁴Endocrine Surgery Department, Lille University Hospital, Lille, France; and ⁵Endocrinology Department, Lille University Hospital, Lille, France

A 29-y-old woman requiring total thyroidectomy with lymph node dissection for a stage pT3(m)N1bMxR2 solid variant of papillary thyroid cancer had, near the left recurrent vagal nerve, a 16 × 10 × 8 mm cervical tumor residue deemed unresectable by expert surgeons. After hormone withdrawal, she received 3.7 GBq of ^{131}I . Although a posttreatment scan showed no iodine uptake, [^{18}F]FDG PET/CT revealed pathologic uptake in the tumor residue, indicating radioiodine refractoriness (Figs. 1A and 1B). An *NCOA4-RET* fusion transcript was identified.

Eight months later, the tumor size remained unchanged but the patient complained of dysphonia. Local and national ENDOCAN-TUTHYREF tumor boards suggested another radioiodine treatment after redifferentiation with a RET-selective inhibitor. Selpercatinib—obtained through compassionate access from Lilly, France—was administered for 6 wk. After levothyroxine withdrawal to optimize ^{131}I uptake and residency, 3.7 GBq of radioiodine were delivered on day 35. Contrary to previous findings, [^{18}F]FDG PET/CT showed no significant abnormality, whereas post-radioactive iodine scanning revealed intense uptake in the residual cervical tumor and mild, diffuse uptake in the lungs suggestive of infradiologic metastatic disease (Figs. 1C and 1D). Eight months after redifferentiation, the thyroglobulin level was undetectable (vs. 6.94 ng/mL before selpercatinib treatment), dysphonia resolved, and further imaging indicated no abnormality.

Redifferentiation-facilitated radioactive iodine therapy is emerging as a new option in treating radioactive iodine–refractory thyroid cancer, particularly with BRAF (B-Raf protooncogene) and MEK (mitogen-activated protein kinase kinase) inhibitors (1). Selpercatinib has shown significant antitumor properties, with few observations of its use for redifferentiation (2,3). This case confirms the feasibility and efficacy of redifferentiation in RET fusion-positive thyroid cancer, achieving curative outcomes with the possibility to preserve the recurrent vagal nerve that would have been sacrificed in the case of surgery. We also report here, for the first time to our knowledge, a strategy using short sequential RET inhibition followed by radioiodine administration in line with an approved redifferentiation protocol with BRAF-MEK inhibitors. Such a schedule contrasts with

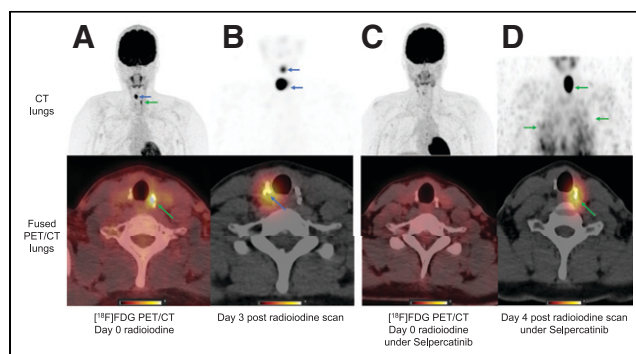


FIGURE 1. During first radioiodine treatment, [^{18}F]FDG PET/CT scan showed hypermetabolism in left cervical region due to tumor residue (green arrows) (A), and postradioiodine scan revealed right laterocervical (blue arrows) fixations with no uptake at tumor site (B). During second radioiodine treatment with selpercatinib, [^{18}F]FDG PET/CT scan (C) and postradioiodine (D) scan showed [^{18}F]FDG-negative, radioiodine-positive neck residue and metastatic miliary lung disease (green arrows).

previous similar experiences consisting mainly of radioiodine therapy given after a long period of selpercatinib treatment.

Our findings also suggest that selpercatinib can be safely administered with hormone withdrawal instead of recombinant human thyroid-stimulating hormone, enhancing radioiodine efficacy and unmasking miliary lung disease.

DISCLOSURE

No potential conflict of interest relevant to this article was reported. The ENDOCAN-TUTHYREF network approved this work, and the patient gave written informed consent.

REFERENCES

- Nostrand DV. Redifferentiation and/or enhancement of radioiodine uptake for ^{131}I therapy: a review of the literature. *J Nucl Med.* 2022;63:2712–2712.
- Groussin L, Bessière L, Arrondeau J, et al. Selpercatinib-enhanced radioiodine uptake in RET-rearranged thyroid cancer [letter]. *Thyroid.* 2021;31:1603–1604.
- Toro-Tobon D, Morris JC, Hilger C, Peskey C, Durski JM, Ryder M. Clinical outcomes of radioactive iodine redifferentiation therapy in previously iodine refractory differentiated thyroid cancers. *Thyroid.* 2024;34:70–81.

Received Aug. 25, 2024; revision accepted Jan. 6, 2025.
For correspondence or reprints, contact Arnaud Jannin (arnaud.jannin@chu-lille.fr).
^{*}Contributed equally to this work.
Published online Jan. 16, 2025.
COPYRIGHT © 2025 by the Society of Nuclear Medicine and Molecular Imaging.
DOI: 10.2967/jnumed.124.268539