

Long-Term Clinical and Neuronuclear Imaging Sequelae of Cancer Therapy, Trauma, and Brain Injury

April Alcantara¹, Gholam R. Berenji^{1,2}, Carole S. Scherling³, Beata Durcanova¹, Daniel Diaz-Aguilar¹, and Daniel H.S. Silverman¹

¹Department of Molecular and Medical Pharmacology, David Geffen School of Medicine at UCLA, Los Angeles, California;

²Department of Radiology, VA Greater Los Angeles Healthcare System, Los Angeles, California; and ³Department of Psychological Science, Belmont University, Nashville, Tennessee

Learning Objectives: On successful completion of this activity, participants should be able to (1) describe clinical features and therapeutic approaches in the evaluation and management of cancer- and chemotherapy-related cognitive impairment (CRCI), posttraumatic stress disorder (PTSD), and traumatic brain injury (TBI); (2) discuss the role of neuroimaging in contributing to understanding of relationships between clinical features of CRCI, PTSD, and TBI, with aspects of underlying regional cerebral function; and (3) identify which brain processes are most consistently shown to be affected in CRCI, PTSD, and TBI.

Financial Disclosure: Dr. Berenji is a board member/officer/trustee for ABNM, SNMMI, and the Correlative Imaging Council; an employee of VA Greater Los Angeles; an investigator for Siemens, GE Healthcare, and Endocyte; and a meeting participant/lecturer for SNMMI and CANM. The authors of this article have indicated no other relevant relationships that could be perceived as a real or apparent conflict of interest.

CME Credit: SNMMI is accredited by the Accreditation Council for Continuing Medical Education (ACCME) to sponsor continuing education for physicians. SNMMI designates each *JNM* continuing education article for a maximum of 2.0 AMA PRA Category 1 Credits. Physicians should claim only credit commensurate with the extent of their participation in the activity. For CE credit, SAM, and other credit types, participants can access this activity through the SNMMI website (<http://www.snmmilearningcenter.org>) through December 2022.

Neuronuclear imaging has been used for several decades in the study of primary neurodegenerative conditions, such as dementia and parkinsonian syndromes, both for research and for clinical purposes. There has been a relative paucity of applications of neuronuclear imaging to evaluate nonneurodegenerative conditions that can also have long-term effects on cognition and function. This article summarizes clinical and imaging aspects of 3 such conditions that have garnered considerable attention in recent years: cancer- and chemotherapy-related cognitive impairment, posttraumatic stress disorder, and traumatic brain injury. Further, we describe current research using neuroimaging tools aimed to better understand the relationships between the clinical presentations and brain structure and function in these conditions.

Key Words: neuroimaging; cancer; chemotherapy; posttraumatic; PTSD; chronic traumatic brain injury

J Nucl Med 2019; 60:1682–1690
DOI: 10.2967/jnumed.119.237578

Although an extensive body of literature exists describing neuronuclear imaging studies of the long-term cognitive effects of primary neurodegenerative disease on the human brain, corresponding publications focused on nonneurodegenerative conditions are relatively sparse. The main purpose of the present paper is to review the literature concerning 3 such conditions: changes in cerebral function associated with cancer and chemotherapy (often referred to as chemobrain in the lay literature), posttraumatic stress disorder (PTSD),

and traumatic brain injury (TBI). Clinical aspects of evaluation and therapy are presented in some detail to provide context to the neuronuclear imaging findings reviewed for each condition—most often through PET along with some SPECT studies of the brain, and given additional breadth through related functional MRI findings—as well as to stimulate future studies with heightened cognizance of current diagnostic and therapeutic limitations.

CANCER PATIENTS AND THE POSTCHEMOTHERAPY STATE: NEUROPSYCHOLOGY

In the United States, approximately 16 million people have a history of cancer (1), and cancer- and chemotherapy-related cognitive impairment (CRCI) has frequently been reported by cancer patients after concluding treatment, with variable posttherapy duration of deficits ranging from months to years (2,3). The burden of CRCI has been increasing along with improved survival rates, with up to 35% of chemotherapy patients now experiencing long-term cognitive sequelae (4).

Across cognitive studies, changes in memory and executive function are commonly reported (5). Some impairment may occur before treatment, and in addition to chemotherapy, factors such as surgery, anesthesia, and concurrent endocrine or radiation interventions may also contribute to deficits. Generally, affected patients after chemotherapy report expending more effort to complete tasks, especially when facing multiple tasks in high-stress situations, and may have difficulty with concentration, attention, thought processing, working memory, recall, word finding, reasoning, and problem solving, as well as fatigue and mood dysregulation. Comparisons of typical neuropsychologic features of CRCI with those of PTSD or physical trauma are summarized in Figure 1.

Neuropsychologic evaluations include both verbal and written tests, with alternate test forms used for repeat administrations. Though magnitudes of neuropsychologic deficits are not always well correlated with patients' global impression of their deficits, a direct correlation specifically with patient memory and problem-solving

Received Oct. 2, 2018; revision accepted Oct. 4, 2019.
For correspondence or reprints contact: Daniel H. Silverman, UCLA School of Medicine, AR-144, MC694215, Los Angeles, CA 90095.
E-mail: dsilver@ucla.edu
Published online Oct. 10, 2019.
COPYRIGHT © 2019 by the Society of Nuclear Medicine and Molecular Imaging.

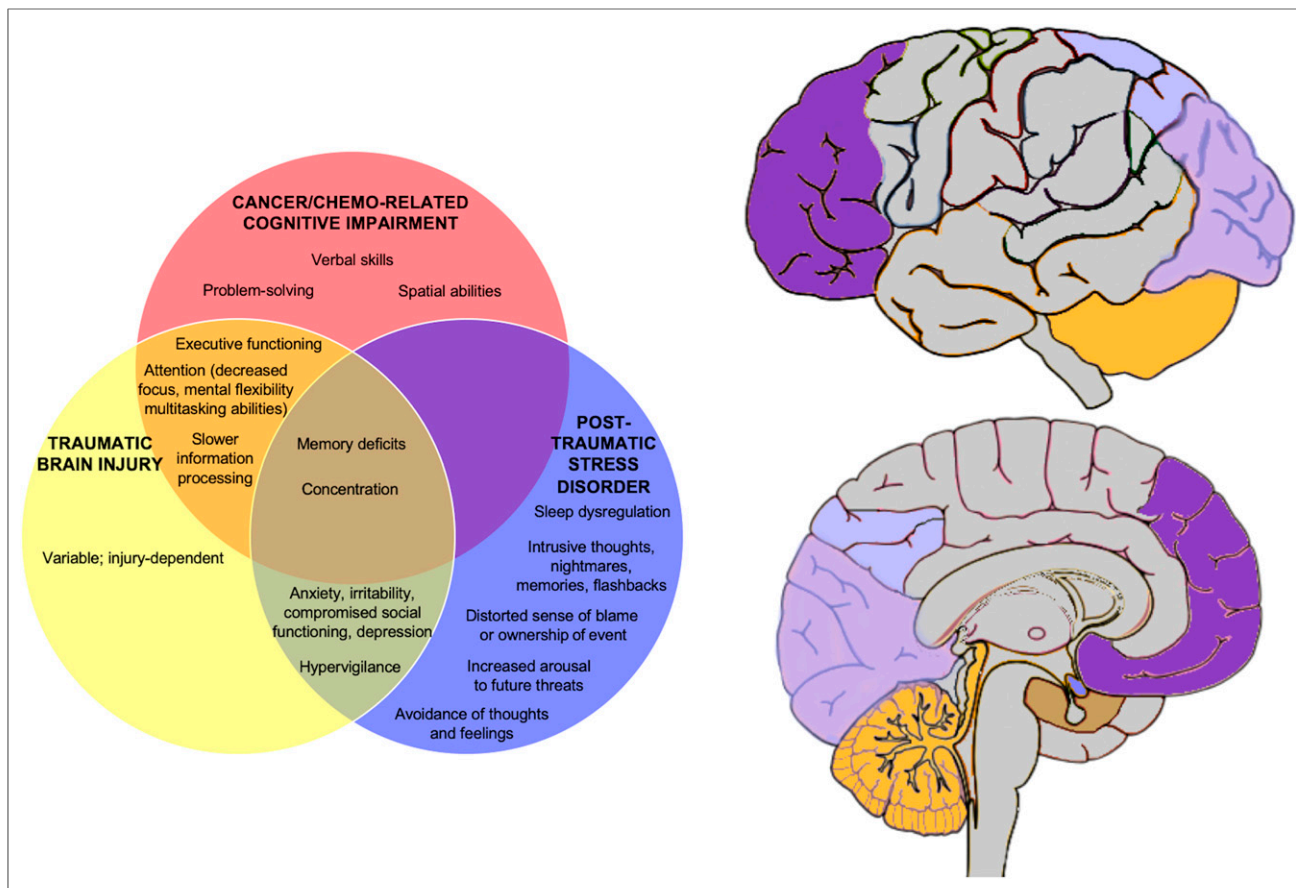


FIGURE 1. Venn diagram describing key clinical features. Brain slices on right show corresponding brain regions implicated in these disorders. Areas in darker shades occur most consistently in the literature. Although not depicted because of their internal location, basal ganglia structures have also been implicated in several CRCI and PTSD studies.

complaints has been demonstrated (6). Dose-dependent side effects have also been reported, showing a correlation between larger chemotherapy exposure and lower test scores (7).

Treatment protocols for CRCI include implementing stress management practices and establishing accommodations in the home and workplace to compensate for impairments and lessen distress. Medications such as antidepressants, anxiolytics, and hypnotics may help with coexisting and exacerbating problems. Some studies have shown promise in lessening postchemotherapy cognitive decline and fatigue levels with stimulants such as modafinil (8) and methylphenidate (9), and the efficacy of antimentia drugs such as donepezil and memantine is also being explored (10), with the former seeming to be most useful for treating memory-related symptoms. In addition, studies have pointed to cognitive rehabilitation protocols to address specific cognitive sequelae (11), and physical activity (12) and meditation practices (13) may also be used to lessen CRCI.

CRCI: NEUROIMAGING

Although rates of ultimate reversibility of CRCI differ across studies, in part because of differences in the sensitivity and types of cognitive assessments administered, most affected patients appear to normalize within 1 to 2 y. CRCI can nevertheless persist for periods exceeding 1–2 decades, and imaging studies have been performed documenting cerebral alterations across short-term and long-term time frames (Table 1). Although several CRCI neuroimaging

review articles have recently been published, these have focused primarily on MRI modalities (14); none has been previously focused on nuclear medicine imaging. The discussion here will concentrate on the latter, highlighting findings particularly from those studies examining metabolism with ^{18}F -FDG PET, by far the best studied in this field among nuclear medicine modalities.

In the first such investigation (15), both ^{18}F -FDG and ^{15}O -water brain PET studies were performed on healthy control subjects and breast cancer patients previously treated or untreated by chemotherapy. Altered functioning of the prefrontal cortex and cerebellum in patients previously treated with adjuvant therapy, 5–10 y after their last dose of chemotherapy, was found. During a short-term verbal memory task, the inferior and superior frontal gyri and posterior cerebellum displayed increased activity in the treated group. Further, each 3% decline in the ^{18}F -FDG resting metabolic activity of the left inferior frontal gyrus corresponded to a 1-SD decline on delayed recall cognitive performance ($P < 0.0005$), and only for the chemotherapy group. Chemotherapy patients who were also treated with endocrine therapy (tamoxifen) displayed a further reduction of basal ganglia resting metabolism.

Subsequently, Baudino et al. reported altered brain metabolism, first across a variety of hematologic and solid malignancies (16) and then focusing exclusively on lymphoma patients (17). These studies were notable for examining relationships of regional brain metabolism to time since completion of chemotherapy and to number of chemotherapy cycles (Table 1). Both studies highlighted

TABLE 1
Summary of Neuroimaging Findings in CRCI Studies

Study	Imaging	Chemotherapeutic drugs used	Main findings
(15)	¹⁵ O-water PET and ¹⁸ F-FDG PET	Cytotoxic chemotherapy* and tamoxifen therapy*	Increased activation in prefrontal cortex and cerebellum during short-term memory recall task in chemotherapy patients; decreased prefrontal cortex resting metabolism correlating with decreased short-term memory; decreased basal ganglia resting metabolism in tamoxifen + chemotherapy breast cancer patients compared with only chemotherapy or no chemotherapy
(16)	¹⁸ F-FDG PET/CT	Systemic CHT*	Early-high-chemotherapy group had decreased metabolism of prefrontal cortex, white matter, cerebellum, posterior medial cortices, and limbic regions compared with no-chemotherapy group; early-high-chemotherapy group had decreased metabolism of right temporal and prefrontal cortex compared with late-low-chemotherapy group; number of cycles negatively correlated with rate of metabolism in these regions; postchemotherapy time positively correlated with rate of metabolism in these regions
(17)	¹⁸ F-FDG PET/CT	CHT*	Decreased metabolism in prefrontal cortex, cerebellum, medial cortex, and limbic regions in chemotherapy group; metabolism of these regions correlated negatively with number of cycles and positively with postchemotherapy time; poorer performance in many frontal functions in chemotherapy group
(18)	¹⁸ F-FDG PET/CT	ABVD	Increased metabolism in right angular gyrus (Brodmann area 39) and decreased activity in prefrontal cortex bilaterally on interim PET
(19)	¹⁸ F-FDG PET/CT	Intensity-modulated radiation therapy	Decreased metabolism bilaterally in basal ganglia and occipital lobes, even after termination of anticancer therapy; relative metabolic recovery bilaterally in occipital lobes and further bilateral deterioration in basal ganglia; increased right prefrontal cortex metabolism during therapy and at end of therapy
(20)	¹⁸ F-FDG PET	CHT group: conventional standard-dose chemotherapy*; HL patients: hydroxydaunorubicin ABVD; NHL patients: R-CHOP; NHL second-line: CNOP, VACOP, and EPOCH; corticosteroids and immunotherapy	Prefrontal-cerebellar system metabolism decreased in chemotherapy group
(21)	¹⁸ F-FDG PET	Carboplatin/paclitaxel, carboplatin/gemcitabine/bevacizumab, cisplatin/etoposide, cisplatin/gemcitabine, cisplatin/vinorelbine tartrate, pemetrexed, and carboplatin/paclitaxel/bevacizumab	Mean overall metabolic decrease of 22% in all gray matter structures; chemotherapy associated with decreased metabolism in paraventricular and subcortical white matter tracts, corpus callosum, and cerebellar white matter; most profound decreased metabolism in frontal cortex and olfactory gyri bilaterally
(22)	¹⁸ F-FDG PET	Chemotherapy, radiation, and hormone replacement therapy	Bilaterally increased activity in anterior medial temporal, left posterior medial temporal, and cerebellar regions; decrease in Broca area activity after aromatase inhibition therapy; greatest increase in metabolism in right medial temporal lobe
(23)	¹⁸ F-FDG PET	Chemotherapy, chemoradiation therapy, and standard multiagent regimens using cyclophosphamide, methotrexate, and 5-fluorouracil or doxorubicin	Decreased metabolism in orbital frontal regions in breast cancer survivors compared with healthy controls; right substantia nigra most profoundly affected in tamoxifen-treated patients; treated patients showed increased metabolism in left postcentral gyrus and corpus callosum

*Not further detailed.

CHT = chemohormonal therapy; ABVD = doxorubicin, bleomycin, vinblastine, dacarbazine; HL = Hodgkin lymphoma; NHL = non-Hodgkin lymphoma; R-CHOP = rituximab plus cyclophosphamide, hydroxydaunorubicin, vincristine, and prednisone (or prednisolone); CNOP = cyclophosphamide, mitoxantrone, vincristine, and prednisone; VACOP = vincristine, doxorubicin, cyclophosphamide, vincristine sulfate, and prednisone; EPOCH = etoposide phosphate, prednisone, vincristine sulfate, cyclophosphamide, and hydroxydaunorubicin.

changes in the prefrontal cortex, cerebellum, and limbic regions; negative correlations between the number of cycles and metabolic activity; and increased activity with time after the last dose of chemotherapy.

A study focusing on Hodgkin patients by Chiaravalloti et al. (18) used a longitudinal design, acquiring resting ^{18}F -FDG PET studies 1 wk after diagnosis, approximately 2 wk after the first 2 cycles of chemotherapy, and again after 4 additional 1-mo cycles. Bilateral metabolic reductions in the dorsal anterior cingulate, prefrontal cortex, and orbitofrontal cortex were observed after the first 2 cycles. Another longitudinal study, performed by Hsieh et al. (19), examined patients with pharyngeal squamous cell carcinoma who had been treated primarily with chemoradiation. The investigators identified several time-sensitive metabolic alterations, including in the basal ganglia bilaterally (Table 1).

A study by D'Agata et al. (20) analyzing metabolic data from lymphoma patients using a network-based approach found significantly diminished metabolism in an identified prefrontal-cerebellar network; this approach was also capable of distinguishing between groups with 80% accuracy. In a longitudinal study further extending the range of cancers investigated, Horky et al. (21) examined non-small cell lung cancer survivors before and 11 d after platinum-based chemotherapy completion. Resting hypometabolism after chemotherapy was seen diffusely in gray matter structures and most profoundly bilaterally in the frontal lobes.

In another longitudinal study, Hurria et al. (22) studied the effect of aromatase inhibition on outcomes of older breast cancer patients before and after 6 mo of treatment compared with healthy controls, measuring neuropsychologic performance and regional cerebral metabolism in a subset. In addition to hypometabolism near the Broca area in the posterior inferior frontal gyrus, areas of bilateral hypermetabolism in temporal and cerebellar regions were identified in treated subjects. Ponto et al. (23) also studied metabolic alterations in older breast cancer survivors compared with healthy controls, including some who had been concomitantly treated with tamoxifen, and also identified areas of regional hyper- and hypometabolism. Most recently, at the other end of the age spectrum, Shrot et al. used ^{18}F -FDG PET to study children with non-Hodgkin lymphoma, also identifying regions of hyper- and hypometabolism, although other mechanisms of injury might have been involved because all of these patients' central nervous systems had direct substantial exposure to chemotherapy agents through intrathecal administration (24).

As seen from these studies, the prefrontal cortex, a part of the brain critical for executive function, has been the most consistently metabolically affected region in patients with CRCI. Limbic or temporal structures and the cerebellum have been the structures next most often reported to be affected by neuroimaging measures and are known to be important for memory, verbal abilities, and visuospatial functions (25).

Studies of CRCI have involved a broad array of chemotherapy agents and regimens (Table 1), and specific risks and patterns of neuropsychologic deficits by agent or dose remain mostly undetermined (26). Chemotherapy dose-response relationships have been observed, however, when comparing changes in patients with number of doses (7) or with magnitude of dose (27). There are also several agents that have been implicated in more severe changes in brain function, including carmustine, cisplatin, cytarabine, fludarabine, 5-fluorouracil, and methotrexate (28).

Multiple mechanisms could give rise to the observed alterations. These range from direct toxic effects of some chemotherapy agents

(which might be expected with higher penetrance across the blood-brain barrier), oxidative damage, metabolic dysregulation, and triggering of immune system and inflammatory responses, including through cytokine release. The last of these has been directly tied to alterations in brain metabolism. This is of particular interest since elevated circulating cytokine levels can be present for months to years after initial treatment for cancer and are known to be associated with neurotoxic effects. In a systematic examination with respect to several inflammatory markers, those cytokine levels occurring soon after chemotherapy have predicted patterns of brain metabolism occurring even a year later (29). These mechanisms are not necessarily competing but can work in concert, either in parallel or in series. For example, oxidative stress mediated by increasing plasma superoxide levels can in turn trigger release of neurotoxic cytokines capable of penetrating the blood-brain barrier. Moreover, a wide range of chemotherapeutics, including anthracyclines, antimetabolites, and alkylating agents, are known to produce such intermediaries, which helps to explain why multiple classes of chemotherapy agents treating multiple kinds of cancer may lead to such overlapping profiles of cognitive dysfunction and associated patterns of altered brain chemistry.

PTSD: DIAGNOSIS AND THERAPY

PTSD has been conceptualized as a memory persistence disorder, in which patients "relive their trauma in the form of involuntary recollection," with distressing recollections being "vivid" and "long-lasting" (30). The U.S. National Comorbidity Survey Replication found a lifetime prevalence of PTSD of approximately 7% among adult Americans (31). Globally, analysis of the World Mental Health Survey Initiative has found significant differences in the prevalence of PTSD (32). The *Diagnostic and Statistical Manual of Mental Disorders*, fifth edition, criteria for PTSD (33) require the survivor to have been exposed to or threatened by a traumatic event, directly or indirectly. Patients reexperience the events through intrusive thoughts, nightmares, memories, flashbacks, and other traumatic recollections. They often demonstrate a distorted sense of blame concerning the traumatic event, decreased social engagement, increased arousal to future threats, concentration difficulties, irritability, anger, sleep dysregulation, and hypervigilance. To meet the diagnostic criteria, symptoms must persist for at least 1 mo, seriously affects one's ability to function, and be unrelated to drug use or other medical illness (33). PTSD often coincides with other comorbid conditions, such as TBI (34) and depression (35), making it more challenging to diagnose or study the disorder and complicating treatment.

Psychotherapy is the initial basis of treatment for PTSD, and various drug therapies adjunctive to psychotherapy are typically added, though there remains a pressing need for development of new therapies (36). Selective serotonin reuptake inhibitors have shown efficacy in symptomatic relief and decreasing rates of relapse, as have norepinephrine reuptake inhibitors (37). Other drugs used to treat and resolve ancillary symptoms such as intrusion and hyperarousal include α - and β -blockers (38) and, more recently, novel treatments such as ketamine (39). Considered to have strong research support by the American Psychological Association and the U.S. Department of Defense and Department of Veterans Affairs, cognitive processing therapy has been successful in reducing feelings of fear and culpability in PTSD (40). Cognitive processing therapy typically consists of twelve 60- to 90-min sessions that focus on changing the patients' understanding and conceptualization

of their trauma, and recently, intense versions of cognitive processing therapy have demonstrated heightened success and faster recovery (41).

PTSD: NEUROIMAGING

Neuroimaging studies have been directed toward understanding the biochemical mechanisms that underlie the pathophysiology of PTSD. Several brain areas have been implicated by neuroimaging modalities in PTSD, and here we focus on more recent studies making use of 3 neuroimaging modalities, most often functional MRI, but also PET or SPECT.

Neurocircuitry Model of PTSD

The hypothalamic pituitary adrenal axis is primarily responsible for mediating stress responses and controls the level of cortisol circulating in the body (42). Inputs from the amygdala, medial prefrontal cortex, and hippocampus activate the hypothalamic pituitary adrenal axis, and these regions have been widely identified as having altered function or structure in PTSD. Converging lines of evidence from imaging studies indicate that the ventromedial prefrontal cortex

inhibits or modulates the activity of the amygdala and anterior insula, suggesting a basis for understanding relationships between these regions in patients with PTSD (43). Further roles of key brain regions are highlighted below, with additional details described in Table 2.

Amygdala

The amygdala has consistently been demonstrated to show hyperactivity in PTSD, which manifests in an exaggerated response to traumatic or fearful stimuli (44). Recent literature has moved toward understanding subtle differences in amygdala activity, including studying different types of trauma as they pertain to subregions of the amygdala and the amygdala volume (45). In an ¹⁸F-FDG PET study on active-duty treatment-seeking U.S. army soldiers with PTSD who experienced danger-based trauma, decreased metabolism in the left amygdala was associated with PTSD severity. In PTSD patients without danger-based trauma, decreased metabolism in the right amygdala was associated with PTSD severity (46). Recent studies have also explored discrete amygdala subregions involved in encoding of emotional events, including the basolateral subdivision and the centromedial amygdala (Table 2) (47).

TABLE 2
Neuroimaging Findings in PTSD Studies

Study	Imaging	Main findings
(46)	¹⁸ F-FDG PET	Increased metabolism in right amygdala in danger-based trauma vs. control groups; increased metabolism in precuneus in non-danger-based trauma vs. danger group
(47)	Functional MRI	Increased activation of basolateral relative to centromedial amygdala in PTSD group
(48)	¹⁵ O-CO ₂ PET	Decreased regional cerebral blood flow in medial prefrontal cortex in veterans with PTSD during mental imagery of trauma-unrelated stressful personal experiences
(63)	Resting-state functional MRI	Oxytocin decreased amygdala-left ventrolateral prefrontal cortex functional connectivity after trauma script-driven imagery vs. neutral script-driven imagery; oxytocin increased amygdala-insula functional connectivity and decreased amygdala-ventromedial prefrontal cortex functional connectivity in both groups; placebo-treated participants had increased amygdala-left ventrolateral prefrontal cortex functional connectivity after trauma script-driven imagery
(50)	SPECT and ¹⁸ F-FDG PET	Decreased perfusion and metabolism in left hippocampus and basal ganglia in PTSD group; increased cerebellar metabolism in PTSD group
(51)	MRI and ¹⁸ F-AV-45 PET	Slightly decreased superior parietal volume in TBI + PTSD group vs. controls; decreased odds of amyloid positivity based on cortical amyloid SUV ratio in PTSD group vs. controls; no evidence for increased brain amyloid associated with TBI; no evidence for medial temporal lobe atrophy in PTSD or TBI vs. controls
(54)	Functional MRI	Decreased functional connectivity between left ventral anterior insula and anterior cingulate cortex; decreased functional connectivity between right posterior insula and left inferior parietal lobe
(56)	SPECT	Hyperperfused default-mode network in PTSD group; hypoperfused default-mode network in TBI group
(55)	¹¹ C-flumazenil PET and MRI	Increased benzodiazepine receptor binding potential in precuneus and dorsal anterior cingulate cortex in PTSD subjects vs. healthy controls
(57)	¹⁸ F-AV-45 PET	Increased amyloid accumulation in frontal, occipital, and temporal lobes of PTSD group, in white matter of TBI + PTSD group, and in cerebellum and precuneus of TBI group
(59)	Active-task functional MRI	Increased activation of dorsal anterior cingulate cortex, insula, and amygdala in response to trauma-unrelated negative stimuli predicted PTSD persistence after trauma-focused therapy

Medial Prefrontal Cortex

The medial prefrontal cortex has been consistently established as a region involved in emotional regulation, and its failure to inhibit the amygdala in PTSD has been thought to lead to impaired fear extinction. An early study using ^{15}O - CO_2 PET imaging in Vietnam veterans who experienced combat or served as nurses in the combat theater found that veterans with PTSD had lower resting cerebral blood flow in the medial prefrontal cortex than did veterans without PTSD (48), and in general, various neuroimaging studies focusing on the prefrontal cortex of PTSD patients demonstrated hypoactivity in this region.

Hippocampus

Neuronal atrophy and synaptic degeneration in the hippocampus can result from stress and trauma (45). The currently largest neuroimaging study to include a focus on PTSD, “ENIGMA—Enhancing Neuroimaging Genetics through Metaanalysis,” recently found smaller hippocampal volumes in PTSD subjects than in trauma-exposed control subjects (49), an effect that remained highly significant after adjustment for multiple comparisons. Some studies have also reported diminished hippocampal metabolism and cerebral blood flow associated with PTSD; but although PTSD patients can experience cognitive dysfunction and are at increased risk for development of AD, its associated pathology appears to be distinct from AD-related pathology with respect to medial temporal atrophy and amyloid positivity, when compared with suitable control subjects (50,51). Since exposure to traumatic events does not always lead to development of PTSD, it has been postulated that functional and structural abnormalities of the hippocampus may predispose an individual to PTSD (52). At this point, it remains unclear whether decreased volume and activity of the hippocampus precede or follow development of PTSD.

Functional Connectivity

Functional connectivity is operationally defined in PET and functional MRI studies by identifying sets of regions having activity covarying with each other in individual subjects across multiple time points (53). Many studies have examined differences in functional connectivity between the amygdala, medial prefrontal cortex, and hippocampus. One such study suggests that the pathogenesis of PTSD may be associated with increased amygdala connectivity with the medial prefrontal cortex and hippocampus and decreased amygdala connectivity with the inferior medial prefrontal cortex and insula (54).

The default-mode network is defined as a set of brain regions whose activity is highest during the resting state and then decreases together during cerebral stimulation. In several studies, patients with PTSD demonstrate abnormal levels of activity in these regions during the resting and/or stimulated state. Further, ^{11}C -flumazenil PET reveals that patients with PTSD have higher benzodiazepine receptor binding in the dorsal and superior anterior cingulate cortex and precuneus, regions known to play a key role in the default-mode network (55). In brain perfusion SPECT studies of veterans with PTSD, TBI, or both, the default-mode network has been found to distinguish between PTSD, which demonstrates hyperperfusion, and mechanical minor TBI, which demonstrates hypoperfusion (56). However, lack of longitudinal MRI studies and small sample sizes make it difficult to ascertain how soon these findings are present after trauma occurs. Neuropathologic markers that may affect default-mode network activity are also being examined, such as amyloid- β deposition, with voxel-based data suggesting that small focal accumulations of amyloid- β may occur, especially

in the temporal lobes of PTSD patients, despite a lack of significant global cortical amyloid accumulation (57,58).

Imaging Treatment of PTSD

Given that 30%–50% of PTSD patients fail to respond positively to treatment, some studies have investigated the use of neuroimaging to predict treatment outcomes. For example, in a functional MRI study on war veterans with and without PTSD, increased activation in the insula, dorsal anterior cingulate cortex, and amygdala predicted persistence of PTSD symptoms after treatment (59). In terms of monitoring responses, psychotherapy has been shown to increase activity in the prefrontal dorsal anterior cingulate and hippocampus and to reduce amygdala activity (60), whereas ^{15}O -water PET studies of mindfulness-based therapy for combat veterans have pointed to associated increases in anterior cingulate activity, along with decreased insula and precuneus activity (61). Changes in the amygdala, insula, and anterior cingulate cortex may also predict response to psychotherapy, with, for example, a higher baseline amygdala activity corresponding to a worsened treatment response (62). Preliminary studies also suggest that intranasal oxytocin may diminish the amygdala and ventrolateral prefrontal cortical functional connectivity (63).

TBI: NEUROPSYCHOLOGIC EVALUATION AND PROGNOSIS

TBI involves mechanical “traumatically induced physiologic disruption of brain function,” characterized by at least one of the following: loss of consciousness, memory loss for events surrounding the accident, alterations of mental state at the time of the accident, or focal neurologic deficits. In the United States, TBI has an estimated prevalence of approximately 5 million people and an annual incidence of 200 cases per 100,000 people (64), though several epidemiologic studies have noted difficulties in estimating the prevalence and incidence of TBI due to the heterogeneity of age, sex, severity, and methods across studies. In addition, cases of TBI are often not reported by patients or not detected by health-care professionals (65). The 2008 RAND Report found that 7% of troops who served in Afghanistan and Iraq experienced TBI with comorbid PTSD or depression (66). Tests for TBI, including a complex battery such as the Glasgow Coma Scale, assess physical injuries, brain and nerve functioning, level of consciousness, speech, and language, as well as cognitive and neuropsychologic abilities such as thinking, reasoning, problem solving, and memory, ranking these from mild to severe. TBI that is mild, the main focus here, requires any loss of consciousness to be for less than 30 min, a period of memory loss limited to less than 24 h, and a Glasgow Coma Scale score of at least 13 of 15 possible points. Prior studies have found an association between moderate to severe TBI and increased risk of developing dementia. Evidence based on a large, retrospective cohort of veterans indicates that even mild TBI without loss of consciousness may double the risk of dementia diagnosis (67).

Cognitive domains typically affected by mild TBI include attention, memory, executive functioning, and information processing (68). Behavioral and affective changes can further complicate both diagnosis and treatment, including anxiety, irritability, and compromised social functioning, with depression being the most frequent psychiatric diagnosis 1 y after injury.

Treatment of TBI is tailored to patient complaints and the extent of injury. Pharmacologic treatments may aid in alleviating some TBI symptomatology and lowering some commonly associated risks, such as seizures and sleeping dysregulations. Stimulants, such

as methylphenidate, may aid patients in the acute phase regarding concentration, attention, and motor memory and may shorten recovery time. A variety of applied behavioral and cognitive therapies has also been effective for some patients, including physical, occupational, speech, and vocational therapy, as well as psychological counseling, cognitive therapies, and mindfulness training (69).

TBI: NEURONUCLEAR IMAGING

Although imaging is one of the first-line interventions after a head trauma, its application in the postacute and chronic phases of TBI remains controversial. Variability in several factors in TBI pose challenges to interpreting imaging studies. These include mechanism of injury, variable period for manifestation of delayed sequelae, and confounding effects of accompanying factors such as PTSD or substance abuse (70).

Performing a CT or MRI scan can be critical in the acute stages of a head injury to evaluate intracranial bleeding and structural damage. Non-contrast-enhanced CT is the modality of choice in moderate and severe TBI for decisions on whether to admit a patient to the hospital or use surgical intervention. MRI is considered the second imaging modality of choice in moderate and severe TBI, if CT results need clarification. Increased sensitivity in MRI helps to identify brain tissue contusions or further validate negative findings on CT scans. Neither CT nor MRI has been shown to significantly affect evaluation of mild TBI, however, beyond excluding possible structural abnormalities.

Although there has been much interest in evaluating applications of ^{18}F -FDG PET and other neuronuclear imaging modalities in TBI, the clinical utility remains unclear. Some studies report immediate changes in glucose metabolism in whole brain, and patients experiencing a single episode of blunt trauma may have altered patterns, particularly of prefrontal and limbic metabolism, even years later (71). Several other studies have shown abnormally reduced regional metabolism, especially in the cerebellum, in patients with blast-induced TBI. Initial patterns of ^{18}F -FDG PET metabolism, however, may substantially differ even among individuals with very similar mechanisms of injury; such imaging studies may nonetheless lend themselves to intraindividual longitudinal assessments (72).

The recent recognition of the magnitude of the problems of TBI and chronic traumatic encephalopathy, along with their associations with tauopathy, has led to increased exploration with other tracers. Along these lines, ^{18}F -FDDNP, ^{11}C -PBB3, ^{18}F -THK5351, and ^{18}F -flortaucipir (also known as ^{18}F -T807 and ^{18}F -AV1451) have been used in the evaluation of tau deposits in the brain. For example, ^{18}F -flortaucipir has demonstrated multifocal increased uptake in the gray matter-white matter junction, corresponding to the tauopathy that is diagnostic for chronic traumatic encephalopathy (73). Most recently, its uptake has been reported in frontal, parietal, and temporal regions in symptomatic National Football League players, as well as in variable distributions in some patients with single TBI episodes occurring many years before PET (74,75). Further studies in subjects with TBI and chronic traumatic encephalopathy are needed to evaluate these radiotracers, their relationship to the nature and severity of clinical symptoms, and the bases for wide interindividual variability in their uptake patterns.

Other PET imaging studies, examining posttraumatic neuroinflammation or dopaminergic pathway alterations (76,77), are now being evaluated in larger cohorts. In an early study of patients with recurrent head trauma, ^{18}F -FDOPA helped to differentiate posttraumatic

parkinsonism from Parkinson disease (76). Microglial activation in post-TBI subjects has been evaluated by imaging translocator protein ligands in several studies. For example, ^{11}C -PK11195 has demonstrated increased uptake in subcortical structures including the thalami, putamen, and parts of white matter in subjects with chronic single moderate to severe TBI (78). Furthermore, these findings have been replicated in additional studies using the second-generation translocator protein ligands ^{11}C -DPA-713, ^{18}F -DPA-714 (79), and ^{11}C -PBR28 (77).

GENERAL CONSIDERATIONS

There are several issues and limitations that apply broadly across the clinical conditions described here. For example, there are not yet sufficient compelling data to suggest adequate sensitivity or specificity at the individual level to be able to reliably apply the regional brain data in a clinically diagnostic or prognostic manner. Rather, the data have been obtained mostly at the group level to gain some insight on underlying neurologic substrates for the syndromes under study. Relatedly, in general, the findings would not be expected to necessarily be identified through visual image readings of individual brains but rather emerge from either of the 2 kinds of quantitative methods used in the papers discussed—voxel-based and volume-of-interest-based—for which age-matched comparisons are typically applied. Consequently, with respect to who should be imaged and why in a more routine clinical manner, this currently makes the most sense for differentiating these conditions from neurologic changes such as in early stages of neurodegenerative disease (particularly in older patients), for which characteristic findings of more established clinical significance have been extensively documented. The reassurance that can be provided to a CRCI patient that she or he does not have inexorably progressive comorbid Alzheimer disease, for instance, can be valuable, and conversely, identifying signature neuroimaging findings of that disease, leading to initiation of appropriate treatment, may also be useful.

Even the most common neurodegenerative condition, AD, required over 3 decades of study with neuronuclear imaging methods before large databases were prospectively amassed that allowed for systematic, generalizable findings, and so it is with the current phase of our understanding of the conditions considered here. For example, limitations that are common to neuronuclear imaging studies on CRCI include the relatively small sample sizes, the wide variety of chemotherapy agents, the combinations of agents pooled into each analysis (also a necessary function of limited sample sizes), and the inherent difficulty of matching patients with similar cancer histologies and stages who have nevertheless been with and without chemotherapy exposure. Neuroimaging studies on PTSD are typically marked by small sample sizes, psychiatric and other comorbidities, a wide range of types of events leading to PTSD, and confounds related to medications used. Similarly, neuroimaging studies on TBI are often limited by relatively small sample sizes, multiple comorbidities (including PTSD), the lack in most studies of correlative neuropathologic data, and the frequent lack of longitudinal assessments. In many respects, we are still in relatively early stages of understanding the underlying neurobiologic changes in these conditions, along with how they are related to observed clinical manifestations, and imaging-based studies are playing a leading role in contributing to their elucidation. Moving forward, as we gain a deeper understanding of features of these conditions that may be detected and measured through brain imaging, studies will be needed that individually examine large series of regionally quantified

scans, to assess accuracy and incremental value in answering questions clinically pertinent to the treatment and outcomes of patients.

REFERENCES

1. *Cancer Treatment & Survivorship Facts & Figures: 2016–2017*. Atlanta, GA: American Cancer Society; 2016:1–42.
2. de Ruiter MB, Reneman L, Boogerd W, et al. Cerebral hypo-responsiveness and cognitive impairment 10 years after chemotherapy for breast cancer. *Hum Brain Mapp*. 2011;32:1206–1219.
3. Koppelmans V, Breteler MMB, Boogerd W, Seynaeve C, Schagen SB. Late effects of adjuvant chemotherapy for adult onset non-CNS cancer: cognitive impairment, brain structure and risk of dementia. *Crit Rev Oncol Hematol*. 2013;88:87–101.
4. Janelsins MC, Kesler SR, Ahles TA, Morrow GR. Prevalence, mechanisms, and management of cancer-related cognitive impairment. *Int Rev Psychiatry*. 2014; 26:102–113.
5. Scherling CS, Smith A. Opening up the window into “chemobrain”: a neuroimaging review. *Sensors (Basel)*. 2013;13:3169–3203.
6. Ganz PA, Kwan L, Castellon SA, et al. Cognitive complaints after breast cancer treatments: examining the relationship with neuropsychological test performance. *J Natl Cancer Inst*. 2013;105:791–801.
7. Collins B, MacKenzie J, Tasca GA, Scherling C, Smith A. Cognitive effects of chemotherapy in breast cancer patients: a dose–response study. *Psychooncology*. 2013;22:1517–1527.
8. Kohli S, Fisher SG, Tra Y, et al. The effect of modafinil on cognitive function in breast cancer survivors. *Cancer*. 2009;115:2605–2616.
9. Gong S, Sheng P, Jin H, et al. Effect of methylphenidate in patients with cancer-related fatigue: a systematic review and meta-analysis. *PLoS One*. 2014;9:e84391.
10. Karschnia P, Parsons MW, Dietrich J. Pharmacologic management of cognitive impairment induced by cancer therapy. *Lancet Oncol*. 2019;20:e92–e102.
11. Ferguson RJ, McDonald BC, Rocque MA, et al. Development of CBT for chemotherapy-related cognitive change: results of a waitlist control trial. *Psychooncology*. 2012;21:176–186.
12. Fardell JE, Vardy J, Shah JD, Johnston IN. Cognitive impairments caused by oxaliplatin and 5-fluorouracil chemotherapy are ameliorated by physical activity. *Psychopharmacology (Berl)*. 2012;220:183–193.
13. Biegler KA, Chaoul MA, Cohen L. Cancer, cognitive impairment, and meditation. *Acta Oncol*. 2009;48:18–26.
14. Li M, Caeyenberghs K. Longitudinal assessment of chemotherapy-induced changes in brain and cognitive functioning: a systematic review. *Neurosci Biobehav Rev*. 2018;92:304–317.
15. Silverman DH, Dy CJ, Castellon SA, et al. Altered frontocortical, cerebellar, and basal ganglia activity in adjuvant-treated breast cancer survivors 5–10 years after chemotherapy. *Breast Cancer Res Treat*. 2007;103:303–311.
16. Baudino B, D’Agata F, Castellano G, et al. Chemotherapy effects on brain glucose metabolism at rest. Nature Precedings website. <http://precedings.nature.com/documents/5637/version/1>. Published February 11, 2011. Accessed October 11, 2019.
17. Baudino B, D’Agata F, Caroppo P, et al. The chemotherapy long-term effect on cognitive functions and brain metabolism in lymphoma patients. *Q J Nucl Med Mol Imaging*. 2012;56:559–568.
18. Chiaravalloti A, Pagani M, Pietro BD, et al. Is cerebral glucose metabolism affected by chemotherapy in patients with Hodgkin’s lymphoma? *Nucl Med Commun*. 2013;34:57–63.
19. Hsieh T-C, Wu Y-C, Yen K-Y, Chen S-W, Kao C-H. Early changes in brain FDG metabolism during anticancer therapy in patients with pharyngeal cancer. *J Neuroimaging*. 2014;24:266–272.
20. D’Agata F, Costa T, Caroppo P, et al. Multivariate analysis of brain metabolism reveals chemotherapy effects on prefrontal cerebellar system when related to dorsal attention network. *EJNMMI Res*. 2013;3:22.
21. Horky LL, Gerbaudo VH, Zaitsev A, et al. Systemic chemotherapy decreases brain glucose metabolism. *Ann Clin Transl Neurol*. 2014;1:788–798.
22. Hurria A, Patel SK, Mortimer J, et al. The effect of aromatase inhibition on the cognitive function of older patients with breast cancer. *Clin Breast Cancer*. 2014;14: 132–140.
23. Ponto LLB, Menda Y, Magnotta VA, Yamada TH, Denburg NL, Schultz SK. Frontal hypometabolism in elderly breast cancer survivors determined by [¹⁸F]fluorodeoxyglucose (FDG) positron emission tomography (PET): a pilot study. *Int J Geriatr Psychiatry*. 2015;30:587–594.
24. Shrot S, Abebe-Campino G, Toren A, Ben-Haim S, Hoffmann C, Davidson T. Fluorodeoxyglucose detected changes in brain metabolism after chemotherapy in pediatric non-Hodgkin lymphoma. *Pediatr Neurol*. 2019;92:37–42.
25. Kaiser J, Bledowski C, Dietrich J. Neural correlates of chemotherapy-related cognitive impairment. *Cortex*. 2014;54:33–50.
26. Wefel JS, Kesler SR, Noll KR, Schagen SB. Clinical characteristics, pathophysiology, and management of noncentral nervous system cancer-related cognitive impairment in adults. *CA Cancer J Clin*. 2015;65:123–138.
27. van Dam FSAM, Boogerd W, Schagen SB, et al. Impairment of cognitive function in women receiving adjuvant treatment for high-risk breast cancer: high-dose versus standard-dose chemotherapy. *J Natl Cancer Inst*. 1998;90:210–218.
28. Wefel JS, Schagen SB. Chemotherapy-related cognitive dysfunction. *Curr Neurol Neurosci Rep*. 2012;12:267–275.
29. Pomykala KL, Ganz PA, Bower JE, et al. The association between pro-inflammatory cytokines, regional cerebral metabolism, and cognitive complaints following adjuvant chemotherapy for breast cancer. *Brain Imaging Behav*. 2013;7: 511–523.
30. Banich MT, Mackiewicz KL, Depue BE, Whitmer A, Miller GA, Heller W. Cognitive control mechanisms, emotion and memory: a neural perspective with implications for psychopathology. *Neurosci Biobehav Rev*. 2009;33:613–630.
31. Gradus JL. Epidemiology of PTSD. U.S. Department of Veterans Affairs website. <https://www.ptsd.va.gov/professional/treat/essentials/epidemiology.asp>. Accessed October 11, 2019.
32. Atwoli L, Stein DJ, Koenen KC, McLaughlin KA. Epidemiology of posttraumatic stress disorder: prevalence, correlates and consequences. *Curr Opin Psychiatry*. 2015;28:307–311.
33. American Psychiatric Association. *Diagnostic and Statistical Manual of Mental Disorders*. 5th ed. Washington D.C.: American Psychiatric Association; 2013.
34. Mohamed AZ, Cumming P, Götz J, Nasrallah F, for the Department of Defense Alzheimer’s Disease Neuroimaging Initiative. Tauopathy in veterans with long-term posttraumatic stress disorder and traumatic brain injury. *Eur J Nucl Med Mol Imaging*. 2019;46:1139–1151.
35. Rytwinski NK, Scur MD, Feeny NC, Youngstrom EA. The co-occurrence of major depressive disorder among individuals with posttraumatic stress disorder: a meta-analysis. *J Trauma Stress*. 2013;26:299–309.
36. Forbes D, Pedlar D, Adler AB, et al. Treatment of military-related post-traumatic stress disorder: challenges, innovations, and the way forward. *Int Rev Psychiatry*. 2019;31:95–110.
37. Hoskins M, Pearce J, Bethell A, et al. Pharmacotherapy for post-traumatic stress disorder: systematic review and meta-analysis. *Br J Psychiatry*. 2015;206: 93–100.
38. Khachatryan D, Groll D, Booij L, Sepehry AA, Schütz CG. Prazosin for treating sleep disturbances in adults with posttraumatic stress disorder: a systematic review and meta-analysis of randomized controlled trials. *Gen Hosp Psychiatry*. 2016;39:46–52.
39. Liriano F, Hatten C, Schwartz TL. Ketamine as treatment for post-traumatic stress disorder: a review. *Drugs Context*. 2019;8:212305.
40. Asmundson GJG, Thorisdottir AS, Roden-Foreman JW, et al. A meta-analytic review of cognitive processing therapy for adults with posttraumatic stress disorder. *Cogn Behav Ther*. 2019;48:1–14.
41. Murray H, El-Leithy S, Billings J. Intensive cognitive therapy for post-traumatic stress disorder in routine clinical practice: a matched comparison audit. *Br J Clin Psychol*. 2017;56:474–478.
42. Dunlop BW, Wong A. The hypothalamic-pituitary-adrenal axis in PTSD: pathophysiology and treatment interventions. *Prog Neuropsychopharmacol Biol Psychiatry*. 2019;89:361–379.
43. Andrewes DG, Jenkins LM. The role of the amygdala and the ventromedial prefrontal cortex in emotional regulation: implications for post-traumatic stress disorder. *Neuropsychol Rev*. 2019;29:220–243.
44. Im JJ, Namgung E, Choi Y, Kim JY, Rhie SJ, Yoon S. Molecular neuroimaging in posttraumatic stress disorder. *Exp Neurol*. 2016;25:277–295.
45. Henigsberg N, Kalember P, Petrović ZK, Ščević A. Neuroimaging research in posttraumatic stress disorder: focus on amygdala, hippocampus and prefrontal cortex. *Prog Neuropsychopharmacol Biol Psychiatry*. 2019;90:37–42.
46. Ramage AE, Litz BT, Resick PA, et al. Regional cerebral glucose metabolism differentiates danger- and non-danger-based traumas in post-traumatic stress disorder. *Soc Cogn Affect Neurosci*. 2016;11:234–242.
47. Patel R, Girard TA, Pukay-Martin N, Monson C. Preferential recruitment of the basolateral amygdala during memory encoding of negative scenes in posttraumatic stress disorder. *Neurobiol Learn Mem*. 2016;130:170–176.
48. Gold AL, Shin LM, Orr SP, et al. Decreased regional cerebral blood flow in medial prefrontal cortex during trauma-unrelated stressful imagery in Vietnam veterans with post-traumatic stress disorder. *Psychol Med*. 2011;41:2563–2572.
49. Logue MW, van Rooij SJH, Dennis EL, et al. Smaller hippocampal volume in posttraumatic stress disorder: a multisite ENIGMA-PGC study: subcortical volumetry results from posttraumatic stress disorder consortia. *Biol Psychiatry*. 2018;83:244–253.

50. Kim S-Y, Chung Y-K, Kim BS, Lee SJ, Yoon J-K, An Y-S. Resting cerebral glucose metabolism and perfusion patterns in women with posttraumatic stress disorder related to sexual assault. *Psychiatry Res.* 2012;201:214–217.
51. Weiner MW, Harvey D, Hayes J, et al. Effects of traumatic brain injury and posttraumatic stress disorder on development of Alzheimer's disease in Vietnam veterans using the Alzheimer's Disease Neuroimaging Initiative: preliminary report. *Alzheimers Dement (N Y).* 2017;3:177–188.
52. Holzschnieder K, Mulert C. Neuroimaging in anxiety disorders. *Dialogues Clin Neurosci.* 2011;13:453–461.
53. Friston KJ, Frith CD, Liddle PF, Frackowiak RSJ. Functional connectivity: the principal-component analysis of large (PET) data sets. *J Cereb Blood Flow Metab.* 1993;13:5–14.
54. Zhang Y, Xie B, Chen H, Li M, Guo X, Chen H. Disrupted resting-state insular subregions functional connectivity in post-traumatic stress disorder. *Medicine (Baltimore).* 2016;95:e4083.
55. Reuveni I, Nugent AC, Gill J, et al. Altered cerebral benzodiazepine receptor binding in post-traumatic stress disorder. *Transl Psychiatry.* 2018;8:206.
56. Raji CA, Willeumier K, Taylor D, et al. Functional neuroimaging with default mode network regions distinguishes PTSD from TBI in a military veteran population. *Brain Imaging Behav.* 2015;9:527–534.
57. Mohamed AZ, Cumming P, Srour H, et al. Amyloid pathology fingerprint differentiates post-traumatic stress disorder and traumatic brain injury. *Neuroimage Clin.* 2018;19:716–726.
58. Mohamed AZ, Cumming P, Srour H, et al. Corrigendum to 'Amyloid pathology fingerprint differentiates post-traumatic stress disorder and traumatic brain injury' *Neuroimage: CLINICAL.* 19 (2018) 716–726. *Neuroimage Clin.* 2019;22:101829.
59. van Rooij SJH, Kennis M, Vink M, Geuze E. Predicting treatment outcome in PTSD: a longitudinal functional MRI study on trauma-unrelated emotional processing. *Neuropsychopharmacology.* 2016;41:1156–1165.
60. Thomaes K, Dorrepaal E, Draijer N, Jansma EP, Veltman DJ, van Balkom AJ. Can pharmacological and psychological treatment change brain structure and function in PTSD? A systematic review. *J Psychiatr Res.* 2014;50:1–15.
61. Bremner JD, Mishra S, Campanella C, et al. A pilot study of the effects of mindfulness-based stress reduction on post-traumatic stress disorder symptoms and brain responses to traumatic reminders of combat in Operation Enduring Freedom/Operation Iraqi Freedom combat veterans with post-traumatic stress disorder. *Front Psychiatry.* 2017;8:157.
62. Szeszko PR, Yehuda R. Magnetic resonance imaging predictors of psychotherapy treatment response in post-traumatic stress disorder: a role for the salience network. *Psychiatry Res.* 2019;277:52–57.
63. Frijling JL, van Zuiden M, Koch SBJ, Nawijn L, Veltman DJ, Olf M. Intranasal oxytocin affects amygdala functional connectivity after trauma script-driven imagery in distressed recently trauma-exposed individuals. *Neuropsychopharmacology.* 2016;41:1286–1296.
64. Popescu C, Anghelescu A, Daia C, Onose G. Actual data on epidemiological evolution and prevention endeavours regarding traumatic brain injury. *J Med Life.* 2015;8:272–277.
65. Nguyen R, Fiest KM, McChesney J, et al. The international incidence of traumatic brain injury: a systematic review and meta-analysis. *Can J Neurol Sci.* 2016;43:774–785.
66. Tanielian T, Jaycox LH, Adamson DM, et al. *Invisible Wounds of War: Psychological and Cognitive Injuries, Their Consequences, and Services to Assist Recovery.* Santa Monica, CA: RAND Corporation; 2008.
67. Barnes DE, Byers AL, Gardner RC, Seal KH, Boscardin WJ, Yaffe K. Association of mild traumatic brain injury with and without loss of consciousness with dementia in US military veterans. *JAMA Neurol.* 2018;75:1055–1061.
68. Vanderploeg RD, Curtiss G, Belanger HG. Long-term neuropsychological outcomes following mild traumatic brain injury. *J Int Neuropsychol Soc.* 2005;11:228–236.
69. Bédard M, Felteau M, Marshall S, et al. Mindfulness-based cognitive therapy reduces symptoms of depression in people with a traumatic brain injury: results from a randomized controlled trial. *J Head Trauma Rehabil.* 2014;29:E13.
70. DeKosky ST, Ikonovic MD, Gandy S. Traumatic brain injury: football, warfare, and long-term effects. *N Engl J Med.* 2010;363:1293–1296.
71. Komura A, Kawasaki T, Yamada Y, Uzuyama S, Asano Y, Shinoda J. Cerebral glucose metabolism in patients with chronic mental and cognitive sequelae after a single blunt mild traumatic brain injury without visible brain lesions. *J Neurotrauma.* 2019;36:641–649.
72. Mendez MF, Owens EM, Reza Berenji G, Peppers DC, Liang L-J, Licht EA. Mild traumatic brain injury from primary blast vs. blunt forces: post-concussion consequences and functional neuroimaging. *NeuroRehabilitation.* 2013;32:397–407.
73. Dickstein DL, Pullman MY, Fernandez C, et al. Cerebral [¹⁸F]T807/AV1451 retention pattern in clinically probable CTE resembles pathognomonic distribution of CTE tauopathy. *Transl Psychiatry.* 2016;6:e900.
74. Stern RA, Adler CH, Chen K, et al. Tau positron-emission tomography in former National Football League players. *N Engl J Med.* 2019;380:1716–1725.
75. Gorgoraptis N, Li LM, Whittington A, et al. In vivo detection of cerebral tau pathology in long-term survivors of traumatic brain injury. *Sci Transl Med.* 2019;11:508.1–508.14.
76. Turjanski N, Lees AJ, Brooks DJ. Dopaminergic function in patients with posttraumatic parkinsonism: an ¹⁸F-dopa PET study. *Neurology.* 1997;49:183–189.
77. Coughlin JM, Wang Y, Munro CA, et al. Neuroinflammation and brain atrophy in former NFL players: an in vivo multimodal imaging pilot study. *Neurobiol Dis.* 2015;74:58–65.
78. Ramlackhansingh AF, Brooks DJ, Greenwood RJ, et al. Inflammation after trauma: microglial activation and traumatic brain injury. *Ann Neurol.* 2011;70:374–383.
79. Hosomi S, Watabe T, Mori Y, et al. Inflammatory projections after focal brain injury trigger neuronal network disruption: an ¹⁸F-DPA714 PET study in mice. *Neuroimage Clin.* 2018;20:946–954.