

## Experimental Tumor Scanning with Intraarterial Hydrogen Peroxide and $^{131}\text{I}$ HSA

Frederick J. Bonte, M.D., Michael Howett, M.D., G. Ben Carter, M.D.,  
Alvin J. Greenberg, M.D. and Karl T. Dockray, M.D.<sup>1,2</sup>

*Dallas, Texas*

Delineation of the precise volume occupied by a malignant tumor often poses a critical problem to the radiotherapist or surgeon who must deal with it. Except for brain tumors and a few highly specialized neoplasms, such as differentiated thyroid adenocarcinoma, radioisotope scanning had contributed little direct help in this problem. Two recent developments are highly pertinent, however; first is the experimental use of some of the compounds which are deposited in intracranial neoplasms, such as radio-mercury-tagged Chlormerodrin (1) and sodium pertechnetate, in occasionally successful efforts to localize neoplasms outside the central nervous system. The second is the experience of Finney, Collier and their associates (2) with intraarterial hydrogen peroxide and radioiodinated human serum albumin.

In one of a group of patients who was being treated by Mallams (3) with intraarterial hydrogen peroxide to enhance tumor radiosensitivity Finney, *et al* (2) noted the unexpected deposition of  $^{59}\text{Fe}$ , which had been administered for turnover studies, in a known liver neoplasm. These investigators attempted experimental tumor localization in the laboratory and finally in a group of patients, by perfusing the region under study through an arterial catheter with a solution of hydrogen peroxide and a tracer isotope, usually  $^{131}\text{I}$  HSA. Finney, *et al* succeeded in obtaining scan localizations of a number of neoplasms and noted several properties of the scans they had produced: a more favorable target/nontarget ratio obtained at 24 hours than earlier because of the gradual disappearance of tracer from surrounding blood pools; at 48 hours, and later, localization in nonneoplastic processes tended to disappear rapidly, while isotope

---

<sup>1</sup>The Departments of Radiology and Obstetrics and Gynecology, The University of Texas Southwestern Medical School and Parkland Memorial Hospital, Dallas, Texas.

<sup>2</sup>This work was supported in part by USPHS Research Grant No. H-5181 and in part by Grant T-180 from the American Cancer Society, Inc.

incorporated in true malignant neoplasms tended to persist beyond 24 hours. Because of the interesting possibilities raised by this work, we decided to repeat it in a group of patients with proven malignant neoplastic disease.

#### MATERIALS AND METHODS

The patients in the study were 16 adults with abdominal or pelvic neoplasms, fifteen of which had been histologically demonstrated before the scan procedure was undertaken. In order to obviate any central nervous system complications which might attend the liberation of gaseous oxygen from a hydrogen peroxide solution by the catalase present in blood, such as vasospasm or bubble embolism, we decided to test the intraarterial hydrogen peroxide perfusion method exclusively on tumors located below the diaphragm. We later modified this policy still further, and decided not to deliver hydrogen peroxide above the renal arteries. We followed Finney *et al* in the selection of  $^{131}\text{I}$  HSA as the tracer to employ in a test of the hydrogen peroxide method.

Before the scan was undertaken, the patients had been completely studied from the standpoint of history, physical examination, tumor biopsy and pertinent laboratory tests. Among other diagnostic procedures, seven of the patients had had pelvic and abdominal lymphangiograms.

Under local anesthesia a No. 2 Ödman-Ledin opaque catheter was introduced into the abdominal aorta through one of the femoral arteries by the familiar Seldinger percutaneous retrograde technique. The catheter tip was positioned under fluoroscopic control, and in 12 of the 16 patients, arteriograms of the tumor volume were made employing 66.8 percent sodium iothalamate and a rapid sequence filming device. The arteriograms served a two-fold purpose:

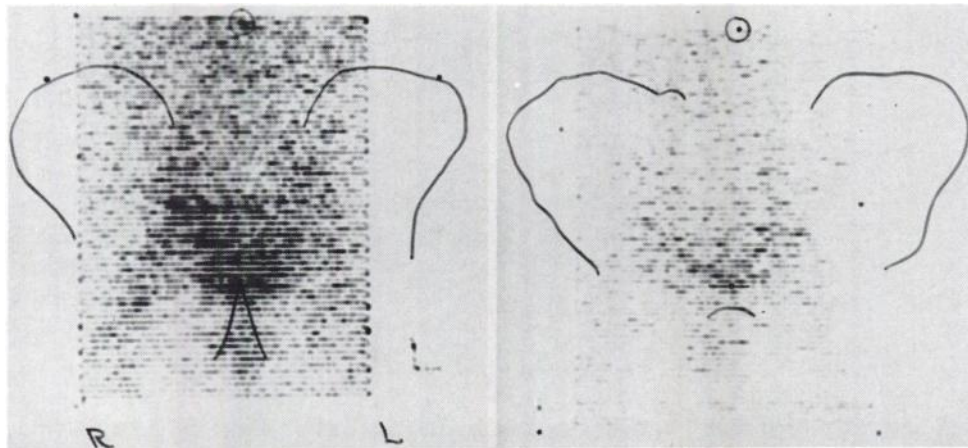


Fig. 1A. Patient C.L. (Table I): Photoscan at 24 hours after perfusion with 0.24 percent  $\text{H}_2\text{O}_2$  and 0.5 mC  $^{131}\text{I}$  HSA. Activity which follows pelvic vessels obliquely upward through lateral pelvis is normal, as is pool of activity in abdomen. Note lower pelvic midline accumulation, probably within uterine fundal stroma. Markers locate umbilicus, iliac crests and symphysis pubis.

Fig. 1B. Scan of C.L. at 48 hours. Note fading uterine stromal pattern, no other localization. These represent normal pelvic scans by this method.

first, to ascertain whether the entire tumor volume was being perfused, and second, to compare tumor arteriography and the isotope scan as diagnostic procedures.

With the arterial catheter properly positioned, perfusion of the tumor and surrounding normal tissue volume was undertaken with a solution of 0.24 percent or 0.48 percent hydrogen peroxide in "Ionosol T"<sup>1</sup> an electrolyte solution in five percent glucose. The perfusate was always made up to contain 25 mgm of Priscoline to minimize vasospasm, which occurred as a very minor complication in only one of the 16 patients. Otherwise, there were no significant complications attributable to catheterization or perfusion.

The volume of interest was perfused at the rate of 5 ml per minute to a total of 100 to 150 ml of the hydrogen peroxide solution, at which time a bolus of tracer, usually 500 to 1000  $\mu\text{C}$  of  $^{131}\text{I}$  HSA, was introduced into the perfusion system. The technique of Finney *et al* was further followed by "flushing" the system with an additional 50 ml of perfusate, once again at the rate of 5 ml per minute. Thus, the total time for perfusion of the tumor volume was from 30 to 45 minutes.

Scans were performed at intervals of from one to 96 hours after perfusion, using a commercial instrument which provided both photoscan and solenoid print records. Little information of value is to be obtained on scans made before 24 hours or after 48 hours, and these are no longer performed.

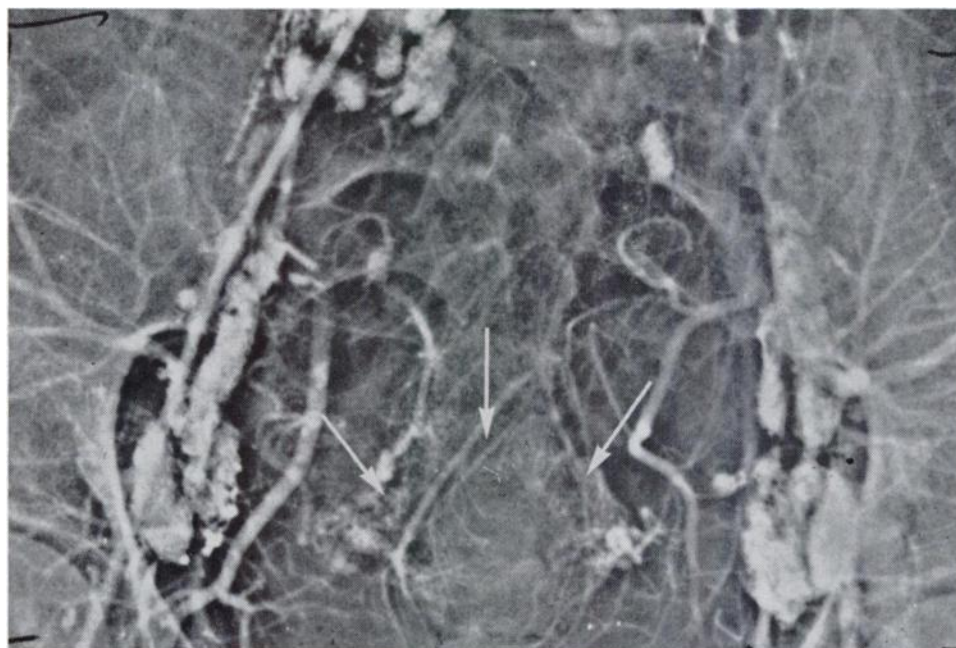

Fig. 2. Late arterial phase pelvic angiogram of patient C.L. (Fig. 1). Arrows demonstrate network of vessels in uterine stroma, thought to be the location of low midline pelvic localization of isotope.

<sup>1</sup>Abbott Laboratories

TABLE I  
CARCINOMA OF CERVIX

Table I. Data on the nine patients of this series known to have carcinoma of the cervix include description of perfusate and tracer, type and International Stage of disease, and scan findings.

<i>Patient—age—sex—race</i>	<i>Perfusate</i>	<i>Tracer</i>	<i>Neoplasia, Site</i>	<i>Scan Findings</i>
H.H. 27 F N	0.24% H <sub>2</sub> O <sub>2</sub> 25 mgm Priscoline	500 uC <sup>131</sup> I HSA	squamous carcinoma of cervix, Stage I	dense uterine pattern 24 hours; fading at 48 hours
C.L. 23 F W	0.24% H <sub>2</sub> O <sub>2</sub> 25 mgm Priscoline	500 uC <sup>131</sup> I HSA	squamous cell carcinoma of cervix, Stage I	dense uterine localization, 24 hours; fading at 4 hours
C.J. 37 F N	0.48% H <sub>2</sub> O <sub>2</sub> 25 mgm Priscoline	1.0 mC <sup>131</sup> I HSA	squamous cell carcinoma of cervix, Stage I	extravasation of tracer on the right. No useful localization
F.C. 23 F N	normal saline 25 mgm Priscoline	500 uC <sup>131</sup> I HSA	squamous cell carcinoma of cervix, Stage I	tion faint uterine localization
F.L. 33 F N	0.48% H <sub>2</sub> O <sub>2</sub> 25 mgm Priscoline	500 uC <sup>131</sup> I HSA	squamous cell carcinoma of cervix, Stage I	24 & 48 hour scans show uterine localization
M.R. 39 F N	0.24% H <sub>2</sub> O <sub>2</sub> 25 mgm Priscoline	500 uC <sup>131</sup> I HSA	mucinous adeno-squamous carcinoma of cervix, Stage II	faint uterine pattern
C.M. 71 F N	0.24% H <sub>2</sub> O <sub>2</sub> 25 mgm Priscoline	500 uC <sup>131</sup> I HSA	squamous cell carcinoma of cervix, Stage III	24 & 48 hour scans show faint uterine localization; ? of pelvic extension on left
M.T. 41 F N	0.24% H <sub>2</sub> O <sub>2</sub> 25 mgm Priscoline	500 uC <sup>131</sup> I HSA	squamous cell carcinoma of cervix, Stage III; myomas	24 hour: uterine localization with extension to left pelvic wall
S.A. 62 F N	0.24% H <sub>2</sub> O <sub>2</sub> 25 mgm Priscoline	500 uC <sup>131</sup> I HSA	squamous carcinoma of cervix, Stage IV; uterine myomas	sizeable pelvic localization ? tumor, ? myomas

## RESULTS

The 16 patients who comprise this study may be divided into two groups as follows:

*Carcinoma of the Cervix*

Nine of our 16 patients were known to have carcinoma of the cervix. Their data are summarized in Table I. In one patient, (C.J.), there was extravasation of tracer at the arterial catheterization site and a satisfactory scan could not be obtained, but there were no local complications of extravasation. In the remaining eight patients all scans were satisfactory, and all showed a common feature, strong selective localization of the tracer isotope in the low pelvic midline (Fig. 1, Case C.L.). Catheterization and rescanning showed that this collection did not represent dissociated radioiodide in the bladder urine. Lateral scans suggested that the activity lay in the general region of the fundus of the uterus, but in the case in Fig. 1, as well as in the other early stage cases in which satisfactory scans were obtained, the scanned volume far exceeded that occupied by the primary neoplasms, some of which were really quite small in extent.

The solution to this problem may begin with the information provided by Fig. 2, which shows a late arterial phase angiogram of patient, C.L., whose scan is seen in Fig. 1. Note the profuse reticulation of tiny vessels throughout the

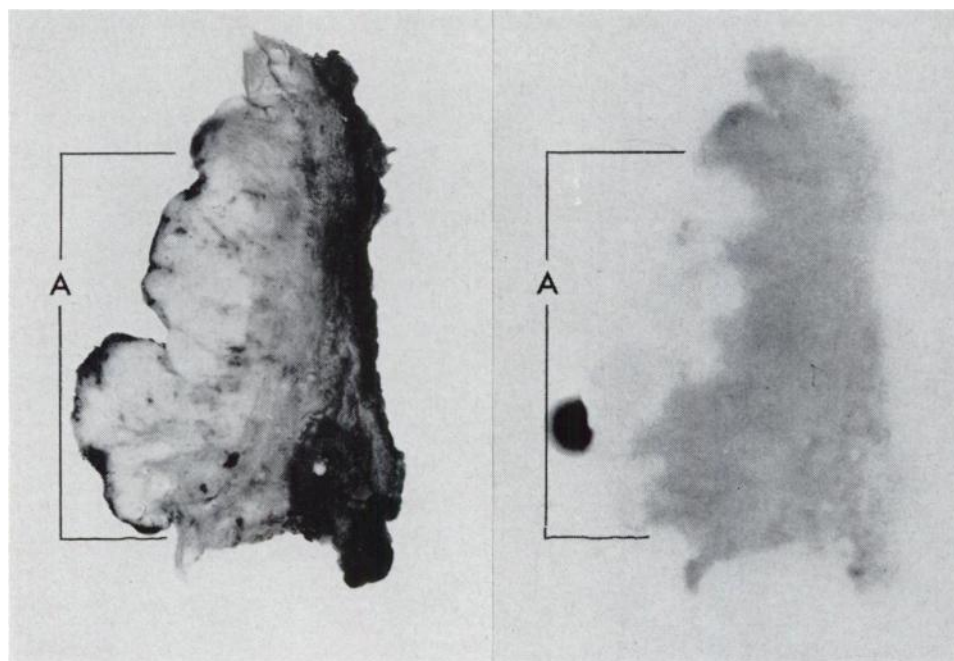


Fig. 3A. Tissue section from Wertheim hysterectomy specimen of patient A.T. (Table II) taken from endocervical canal and lower uterine segment. Area A represents light-colored nodular tumor on epithelial surface. Remainder of section represents stroma and myometrium.

Fig. 3B. Radioautograph of tissue section in Fig. 3A. Note that there is little localization in tumor (area A). Most of isotope present is within the stromal portion of the section.

stroma of the uterine fundus, in the area which corresponds to that of the high specific radioactivity. Since the pattern of pelvic localization of the tracer is still detectable on the scan at 48 hours (Fig. 1), though fading, it seems unlikely that a "blood pool" phenomenon is being detected.

Further evidence as to the nature of this finding is presented by the matching section and radioautograph in Fig. 3. The tissue section is a segment of distal uterine fundus and endocervical canal from the Wertheim hysterectomy specimen removed from patient A.T. (Table II; Scan: Fig. 7B) five days after arterial perfusion. Note that isotope is still concentrated within the specimen at this late time, but note also that the tracer lies principally within the stromal portion of the specimen, with very little of it present in the nodular aggregate of tumor at the mucosal surface (area A). The relatively low concentration of tracer within tumor in this case is unusual, however. Assays of tissue samples removed from surgical specimens from three patients (C.L., C.M., G.W.) have shown selective localization of tracer in tumor over normal tissue in ratios of from 2:1 to 4:1. Also, *in vivo* directional counting of known tumor nodules in patient B.H. revealed counting rate ratios of tumor to non-tumor of 4:1. Therefore, although the tracer is often selectively deposited in the tumor, it sometimes is not. It may also become localized in a few normal tissues, notably the uterine fundus.

Selective localization of  $^{131}\text{I}$  HSA to the stroma of the uterine fundus seems to some extent to be a property of that substance rather than of intraarterial peroxide perfusion. In one instance (case F.C.) a patient with a small cervical cancer underwent perfusion with Ionosol T, Priscoline and  $^{131}\text{I}$  HSA, but no peroxide, using the same volume and flow rate as in those cases in which peroxide was employed. Figure 4 shows a faint but readily perceptible localization under these control circumstances. Prior administration of angiographic contrast material can probably be ruled out as a major cause, since strong stromal patterns were obtained in three patients (Table I: H.H., M.R., S.A.) in whom arteriograms were not performed.




Fig. 4A and B. 24-hour and 48-hour pelvic scans of patient F.C. (Table I) following perfusion with  $^{131}\text{I}$  HSA but no  $\text{H}_2\text{O}_2$ . Note faint pelvic localization, presumably in uterine stroma, which fades rapidly at 48 hours.

TABLE II

## OTHER NEOPLASMS

Table II. Data on seven remaining patients of this series include description of perfusate and tracer together with site, cell type and stage of disease, if known. The scan findings are summarized.

<i>Patient—age—sex—race</i>	<i>Perfusate</i>	<i>Tracer</i>	<i>Neoplasm, Site</i>	<i>Scan Findings</i>
B.R. 64 F N	0.24% $\text{H}_2\text{O}_2$ 25 mgm Priscoline	500 $\mu\text{C}$ $^{131}\text{I}$ HSA	mixed Mullerian sarcoma of fundus recurrent in pelvis and lower abdomen after proef. Ra. and hysterectomy	arteriogram shows lower quadrant retroperitoneal masses. Scan shows poor localization
H.P. 57 M N	0.24% $\text{H}_2\text{O}_2$ 25 mgm Priscoline	500 $\mu\text{C}$ $^{131}\text{I}$ rose bengal	adenocarcinoma of kidney	no localization
G.W. 65 F N	0.24% $\text{H}_2\text{O}_2$ 25 mgm Priscoline	1.0 mC $^{131}\text{I}$ HSA	sarcoma of fundus with extension to pelvic wall	fair pattern at 24 hours; fading at 48 hours
M.D. 47 M W	0.24% $\text{H}_2\text{O}_2$ 25 mgm Priscoline	1.0 mC $^{131}\text{I}$ HSA	neurofibrosarcoma in mesentery ulcerating into bowel lumen. Malignant degeneration in patient with neurofibromatosis	scan does not show localization to mass well demonstrated on arteriogram
A.T. 37 F N	0.24% $\text{H}_2\text{O}_2$ 25 mgm Priscoline	1.0 mC $^{131}\text{I}$ HSA	adenocarcinoma of cervix and fundus, Stage IV	uterine localization and ? localization in large node metastasis shown by lymphangiography
B.H. 55 F W	0.48% $\text{H}_2\text{O}_2$ 25 mgm Priscoline	1.0 mC $^{131}\text{I}$ HSA	adenocarcinoma of fundus recurrent in anterior vaginal wall and posterior pelvis after Ra. and hysterectomy	24 and 48 hour scan: localization in palpable recurrence in posterior pelvis. Strong localization in suburethral nodule
D.C. 44 F W	primary lesion: normal saline + 25 mgm Priscoline pelvic metastasis: 0.48% $\text{H}_2\text{O}_2$ 25 mgm Priscoline	primary tumor: 500 $\mu\text{C}$ $^{131}\text{I}$ HSA pelvic Mx: 500 $\mu\text{C}$ $^{131}\text{I}$ HSA	mucinous adenocarcinoma of stomach with metastasis to right ovary and pelvis	localization in primary tumor and pelvic metastasis. Other tracer in splanchic blood pool and uterus

Although uterine stromal deposition forms a barrier to accurate scan localization of small midline pelvic neoplasms, encouraging results were obtained with more extensive tumors. Figure 5 shows more profuse radioactivity to the left of the pelvic midline than to the right, a finding which matches the known clinical extension of this Stage III squamous cell carcinoma to the left lateral pelvic wall (case M.T.). It is interesting to note that there is little evidence of tracer localization within the large myoma (A, Fig. 5A). Three other voluminous tumors (cases G.M., M.T. and S.A.) showed localization which corresponded generally with tumor extent deduced from bimanual examination.

#### OTHER NEOPLASMS

Table II summarizes results obtained in seven additional patients who had a variety of abdominal or pelvic neoplasms. In three of these (B.R., H.P., M.D.) peroxide scans did not contribute information of diagnostic value. In three (A.T., B.H., D.C.) interesting and probably contributory results were obtained, and one scan (G.W.) gave results of marginal significance.

M.D., a 47-year-old man known to have neurofibromatosis, had developed signs of gastrointestinal disease. An examination of the upper GI tract with BaSO<sub>4</sub> suspension revealed a large ulcer measuring 12×5×4 cm lying within an abdominal mass and communicating with the lumen of the proximal jejunum. Surgical exploration revealed the mass to be of even larger dimensions, and to be situated within the small bowel mesentery. The tumor was identified histologically as a neurogenic sarcoma which had probably arisen from a neurofibroma by malignant degeneration. The operating surgeon placed a ring of metal hemostatic clips about what he thought was the margin of the neoplastic process but he did not attempt to remove it. Retrograde catheter arteriogram (Fig. 6A)

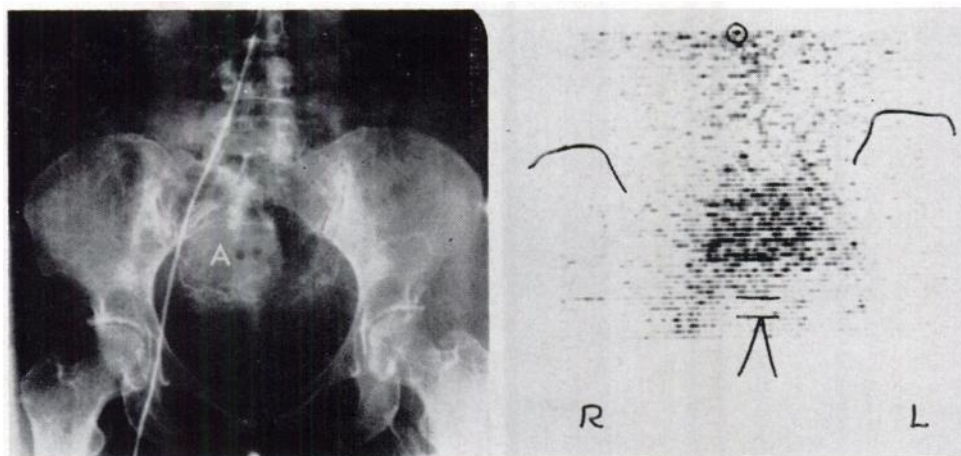


Fig. 5A. Late arterial phase pelvic angiogram of patient M.T. (Table I). Large, relatively avascular mass, A, represents known uterine myoma.

Fig. 5B. 24-hour H<sub>2</sub>O<sub>2</sub>-<sup>131</sup>I HSA pelvic scan of patient M.T. Note isotope localization well to the left of the midline, matching clinical tumor extension to left lateral pelvic wall. Note absence of tracer from large myoma.



shows abnormal tumor vessels extending beyond the visible ring of clips, notably into the left lower quadrant of the abdomen. A scan performed 24 hours after the instillation of 0.24 per cent hydrogen peroxide solution and 1.0 mC of  $^{131}\text{I}$  HSA (Fig. 6B) does not show any sort of diagnostic localization within the known volume of tumor, and instead shows only a pattern compatible with the usual distribution of tracer in the splanchnic blood pool. Whether the results in this case could have been improved by perfusion with 0.48 per cent  $\text{H}_2\text{O}_2$ , as was done in our most recent cases, is problematical.

A.T. was a 37-year-old woman known to have adenocarcinoma which involved cervix and fundus in continuity, but without palpable lateral extension. Lymphangiogram (Fig. 7A), however, showed evidence of replacement of most of the substance of an enlarged node in the upper right common iliac chain and possible involvement of several smaller left upper iliac nodes as well. Scan (Fig. 7B) performed 24 hours after the instillation of 0.48 per cent  $\text{H}_2\text{O}_2$  solution and 1.0 mC  $^{131}\text{I}$  HSA shows an interesting pattern which represents the usual uterine stromal localization, (Fig. 3), with an asymmetrical extension of the scan pattern high in the right pelvis to the region occupied by the suspect lymph node. After preoperative radium application, Wertheim hysterectomy and node dissection revealed involvement of lymph nodes in both iliac chains, as predicted by the lymphangiogram, and in the case of the larger node on the right, probably by the scan as well.

B.H. was a 55-year-old woman who presented with a vaginal recurrence in the form of a suburethral nodule two years after preoperative radium applica-

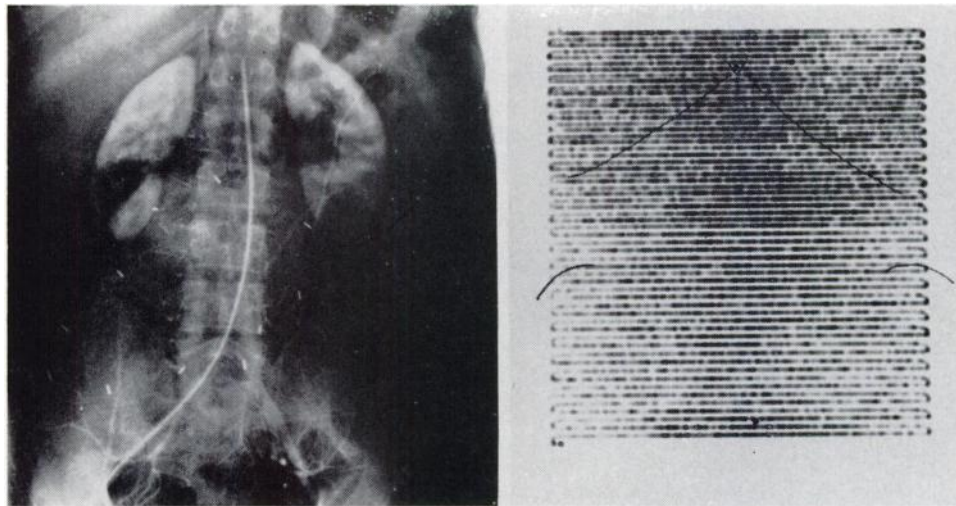


Fig. 6A. Patient M.D. (Table II): Late arterial phase abdominal angiogram shows tumor vessels in region of large neurogenic sarcoma surrounded by oval of metal hemostatic clips. Note extension of tumor vessels and "stain" beyond row of clips into left lower abdominal quadrant.

Fig. 6B. 24-hour abdominal scan of M.D. following perfusion with  $\text{H}_2\text{O}_2$  and  $^{131}\text{I}$  HSA. Normal abdominal pattern without evidence of localization within tumor.

tion and hysterectomy for an adenocarcinoma of the uterine fundus. Scan (Fig. 8) performed after perfusion with 0.48 per cent  $H_2O_2$  and 1.0 mC  $^{131}I$  HSA shows a localization in the lower anterior pelvis which could not represent the uterine fundus, for it had already been removed. There is also localization of isotope in a vertical pattern up the pelvic midline which, on a lateral scan, lies posteriorly at the level of the anterior wall of the rectum. On pelvic examination a deep mass was palpable in this area and was presumed to represent recurrent tumor. Interstitial radium needle implantation was undertaken for management of the anterior vaginal wall nodule, and at the operating table directional counting with a hand scintillation probe revealed a counting rate within the nodule at least four times that of surrounding tissue, which suggests that the nodule accounts for some of the low midline activity. The posterior midline mass was detectable, but little could be decided about its specific activity. In this case, however, incorporation of the tracer within tumor tissue was readily demonstrated.

D.C. was a 44-year-old woman known to have a local recurrence following subtotal gastrectomy for palliation of an inoperable mucinous adenocarcinoma of the stomach two years earlier. In the interim a large pelvic soft tissue metastasis had developed. An experiment was undertaken in which the upper abdominal recurrent primary tumor mass was perfused with a mixture of normal saline, Priscoline and 500  $\mu$ C of  $^{131}I$  HSA, while the pelvic mass was perfused with an 0.48 per cent  $H_2O_2$  solution, Priscoline and 500  $\mu$ C  $^{131}I$  HSA. Figure 9 shows a scan made at 24 hours in which there is evidence of localization both within the primary tumor, (A), and in a large area of the pelvis (B). Within the pelvis some of the activity may be construed to lie within the uterine stroma, but certainly a goodly share of it lies within the known Krukenberg metastasis. It is

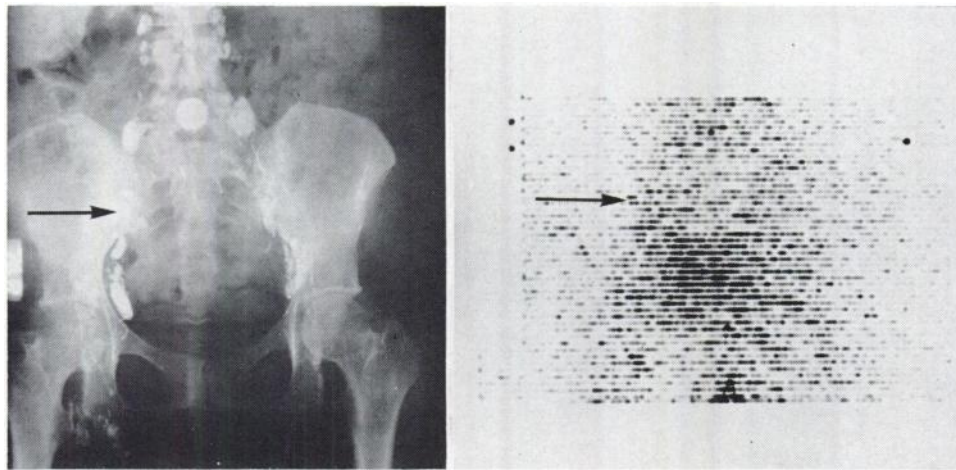


Fig. 7A. Patient A.T. (Table II): Pelvic lymphangiogram shows replacement of almost entire large node in right iliac chain (arrow).

Fig. 7B. Patient A.T., 24-hour scan after  $H_2O_2$  and  $^{131}I$  HSA perfusion. Evidence of usual uterine stromal localization. Note possible extension of isotope pattern to region of abnormal lymph node found at operation to contain metastatic tumor (arrow).

apparent that  $^{131}\text{I}$  HSA was deposited in the primary tumor without preperfusion with  $\text{H}_2\text{O}_2$  solution.

#### DISCUSSION

Various kinds of chemical substances including Chlormerodrin, many B compounds, the pertechnetate ion, and human serum albumin tend to be localized selectively within certain intracranial neoplasms. Some, perhaps all of these substances, may also on occasion be selectively deposited in neoplasms elsewhere in the body. The reason for this deposition is not established, but we believe that it is related to high permeability of the abnormal vessels which nourish malignant tumors. At any rate, some sort of "blood-tissue barrier" appears to have been breached. In fact, it is possible that any molecule of sufficiently small size may traverse the imperfect walls of tumor vessels in a concentration proportional to that in which it is supplied to the tumor circulation. This might account for the great numbers of substances which have been found useful for scanning of neoplasms both within the cranium and outside it. The efficacy of a given sub-

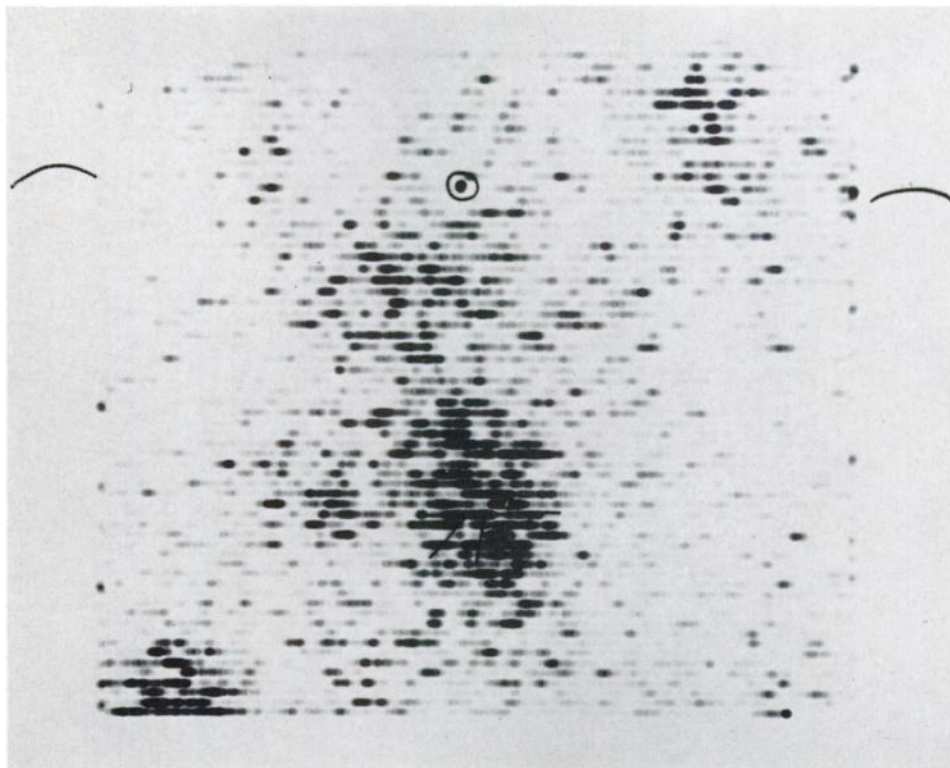


Fig. 8. Patient B.H. (Table II): 24-hour scan following  $\text{H}_2\text{O}_2$  and  $^{131}\text{I}$  HSA arterial perfusion. Note localization in pelvic midline. Uterus was surgically absent. Directional counting, pelvic examination under anesthesia, and lateral scans showed lower localization to be in vaginal wall recurrence and remainder in deep recurrence along anterior rectal wall. Note localization of tracer at injection site in right thigh. Reference marks locate iliac crests and umbilicus.

stance as a tracer would then depend upon the rapidity with which it is removed from blood and surrounding normal tissues, thus providing a favorable tumor/nontumor ratio.

The present study supports the work of Finney, Collier and their associates in showing that arterial perfusion of a tumor with hydrogen peroxide solution, and radioactive iodinated human serum albumin may result in the selective localization of the tracer within the tumor tissue. It would also appear that this phenomenon occurs after intraarterial instillation of serum albumin with or without hydrogen peroxide. However, it may be in part a function of the high concentration at which the tracer agent reaches the tumor by arterial perfusion.

Certain normal tissues, including the stroma of the uterine fundus, show a specific avidity for the serum albumin tracer which complicates the interpretation of this scan test when it is applied to pelvic neoplasms in females. Uterine stromal localization may itself be a property of the uterine stromal vasculature, but the reason is unknown at this time.

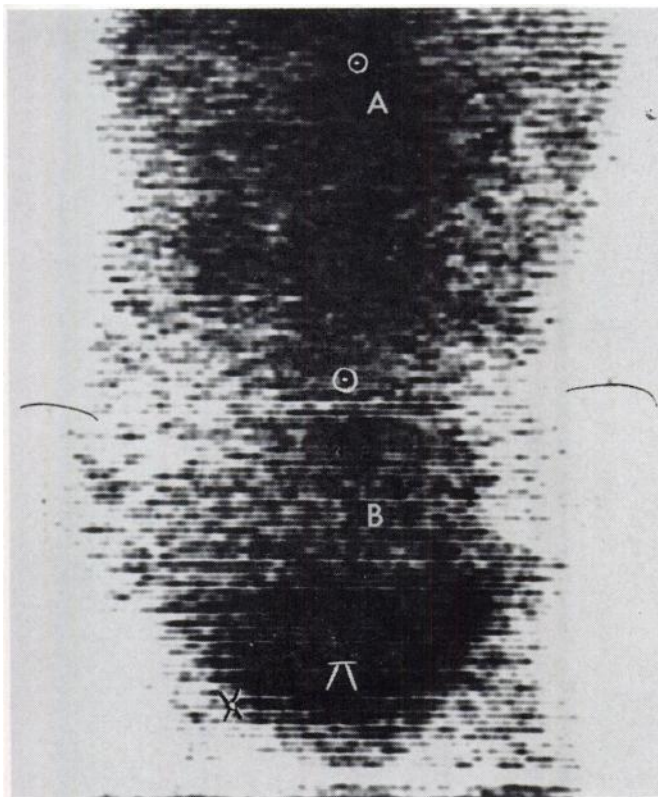


Fig. 9. Patient D.C. (Table II): 24-hour scan after arterial perfusion. Note specific localizations at A, site of known recurrence of primary mucinous adenocarcinoma of stomach, and B, site of known large pelvic soft tissue metastasis. Inferior portion of latter density probably represents uterine stromal localization. Upper reference circle denotes xiphoid process, lower, umbilicus. Other marks for iliac crests, symphysis and right femoral injection site.

Prior administration of hydrogen peroxide may enhance the deposition of albumin tracer, perhaps by further influencing the permeability of tumor vessels, and even the permeability of tumor cell membranes, as Collier has suggested (4).

In any case, arterial perfusion of tumors with tracer substances seems to merit investigation as the basis of a new scanning technique, as does the use of hydrogen peroxide and other agents as adjuvants which might favorably influence the escape of the tracer into the tumor.

## REFERENCES

1. SODEE, D. B., RENNER, R. R., AND DI STEFANO, B.: Photoscanning of Tumor Utilizing Chlormerodrin Mercury 197. *Radiology*, **84**:873, May, 1965.
2. FINNEY, J. W., COLLIER, R. E., BALLA, G. A., TOMME, J. W., WAKLEY, J., RACE, G. J., URSCHEL, H. C., D'ERRICO A. D. AND MALLAMS, J. T.: Preferential Localization of Radioisotopes Malignant Tissues by Regional Oxygenation. *Nature*, **202**:1172, June 20, 1964.
3. MALLAMS, J. T., FINNEY, J. W. AND BALLA, G. A.: The Use of Hydrogen Peroxide as a Source of Oxygen in a Regional Intra-arterial Infusion System. *South. M. J.*, **55**:230, Nov., 1962.
4. COLLIER, R. E. AND MALLAMS, J. T.: Personal Communication.

## ACKNOWLEDGEMENTS

The authors would like to express their gratitude to Drs. J. T. Mallams and R. E. Collier, and to J. W. Finney for their helpful advice on initiating the experimental program described above. They would also like to express thanks to the Department of Clinical Research, Abbott Laboratories, North Chicago, Illinois, for their support of this experimental program, to Miss Margaret Aronson for excellent technical assistance, and to Dr. Jack Flume for his fine radioautographs.

## ODE TO A SCANNER

O little probe, O little probe,  
That moves slow to and fro.  
Your eye sees what man's can not see,  
And it makes him wonder so.  
You find hot spots and cold spots  
That give to us a clue,  
And make the doctors wonder,  
"What are we going to do?"

John R. Stephens, Jr.