^{18}F-FDG PET/CT for Staging and Restaging of Breast Cancer

David Groheux[1], Alexandre Cochet[2], Olivier Humbert[2], Jean-Louis Alberini[3], Elif Hindié[4], and David Mankoff[5]

[1]Department of Nuclear Medicine, Saint-Louis Hospital, Paris, France; [2]Department of Nuclear Medicine, Centre GF Leclerc, Dijon, France; [3]Department of Nuclear Medicine, Institut Curie, Paris, France; [4]Department of Nuclear Medicine, University of Bordeaux, Hôpital Haut-Lévêque CHU, Bordeaux, France; and [5]Department of Radiology, Perelman School of Medicine, University of Pennsylvania, Philadelphia, Pennsylvania

Many studies have pointed out the role of ^{18}F-FDG PET/CT (or ^{18}F-FDG PET) in patients with clinical stage III or II breast cancer. ^{18}F-FDG PET/CT might advantageously replace other staging procedures, such as bone scanning and possibly contrast-enhanced CT of the thorax or abdomen–pelvis. We discuss the findings, locoregional or distant, that can be expected in different categories of breast cancer and their impact on prognosis and management. We also discuss the role of ^{18}F-FDG PET/CT in restaging and how ^{18}F-FDG PET/CT compares with conventional techniques in restaging for patients with suspected disease recurrence. We conclude with some recommendations for clinical practice and future research.

Key Words: ^{18}F-FDG PET/CT; breast cancer; staging; restaging; prognosis

J Nucl Med 2016; 57:17S–26S
DOI: 10.2967/jnumed.115.157859

Accurate staging is important for management decisions in patients with newly diagnosed breast cancer. Several studies have pointed out the lack of utility of PET/CT with ^{18}F-FDG in staging for patients with cancer detected early, that is, tumors of less than or equal to 2–3 cm and no palpable nodes—findings that represent most breast cancer cases (*1–5*). The lower sensitivity of ^{18}F-FDG imaging than of the sentinel node technique in assessing axillary lymph node involvement is well known (*1–3*), and the risk of distant metastases in early-stage cases is low (*4,5*). These factors, combined with the good but finite specificity of ^{18}F-FDG PET/CT, result in a relative abundance of false-positive findings and a paucity of true-positive findings; such findings lead to unwarranted patient anxiety and delay of care with the routine use of ^{18}F-FDG PET/CT for breast cancer detected early.

In contrast, in such high-risk patients as those with inflammatory (T4d) or locally advanced breast cancer (LABC) (*6,7*), the role of ^{18}F-FDG imaging in detecting distant lesions has been highlighted (*8–12*). Recently, several studies pointed out that staging with ^{18}F-FDG PET/CT might be of value not only in patients with locally advanced disease but also in "intermediate-risk" patients (*13–21*)—that is, patients with clinical stage IIB disease (T2N1/T3N0) or higher—with significant diagnostic yield and prognostic information (*18,19*). PET/CT has also shown good performance in restaging for breast cancer patients (*22–35*).

This review assesses the advantages and limits of ^{18}F-FDG PET/CT in initial staging and restaging for breast cancer patients.

REGIONAL AND DISTANT STAGING IN LOCALLY ADVANCED AND INFLAMMATORY BREAST CANCER

LABC is variably defined but usually refers to clinical N2, N3, or T4 disease and typically includes American Joint Committee on Cancer (AJCC) clinical stage IIIA (excluding T3N1), IIIB, and IIIC breast cancer (Table 1) (*6,7*). Within this entity, distinction is made between inflammatory carcinoma (T4d) and noninflammatory LABC. Patients without identified distant metastases usually receive neoadjuvant chemotherapy followed by surgery and radiation therapy as standard treatment.

Detection of Regional Node Involvement Outside Axillary Levels I and II

Axillary node clearance by axillary dissection is usually limited to levels I and II. ^{18}F-FDG uptake suggesting involvement at level III (infraclavicular) or in extraaxillary locoregional nodes (supraclavicular or internal mammary) may have important implications in surgical management and the design of radiation therapy fields (*7*). Correlative CT information (from hybrid PET/CT imaging) is helpful in providing the anatomic location of ^{18}F-FDG–avid lymph nodes (precise position relative to pectoralis minor muscle, clavicle, or intercostal space; Fig. 1) (*36*).

Detection of Distant Metastases

LABC is associated with a high risk of distant metastases (Fig. 2). A pilot study by van der Hoeven et al. of 48 patients with LABC suggested that ^{18}F-FDG PET was helpful in detecting distant metastases not seen with routine investigations (*8*). In a prospective cohort of 117 LABC patients (35 with inflammatory carcinoma and 82 with noninflammatory LABC), Groheux et al. compared a conventional staging approach routinely ordered by clinicians and including bone scanning, chest radiography (or dedicated CT), or liver ultrasound (or contrast-enhanced CT for abdomen–pelvis) with a single session of staging with ^{18}F-FDG PET/CT (*12*). Distant metastases were detected on PET/CT in 43 patients (46% of patients with inflammatory LABC and 33% of those with noninflammatory LABC), whereas conventional imaging detected metastases in only 28 patients. ^{18}F-FDG PET/CT outperformed conventional imaging for bone, distant lymph node, and liver metastases, whereas CT was more sensitive for lung metastases (*12*).

PET efficiently detects supracentimetric pulmonary nodules. However, because of the partial-volume effect and respiratory

Received Jun. 29, 2015; revision accepted Sep. 2, 2015.
For correspondence or reprints contact: David Groheux, Service de Médecine Nucléaire, Hôpital Saint-Louis, 1 Avenue Claude Vellefaux, 75475 Paris Cedex 10, France.
E-mail: dgroheux@yahoo.fr.

TABLE 1
TNM Clinical Stage Grouping for Breast Cancer*

AJCC	TNM			NCCN
Stage I	T1	N0	M0	Primary operable breast cancer
Stage IIA	T0	N1	M0	Primary operable breast cancer
	T1	N1	M0	Primary operable breast cancer
	T2	N0	M0	Primary operable breast cancer
Stage IIB	T2	N1	M0	Primary operable breast cancer
	T3	N0	M0	Primary operable breast cancer
Stage IIIA	T3	N1	M0	Primary operable breast cancer
	T0	N2	M0	Locally advanced breast cancer
	T1	N2	M0	Locally advanced breast cancer
	T2	N2	M0	Locally advanced breast cancer
	T3	N2	M0	Locally advanced breast cancer
Stage IIIB	T4	N0	M0	Locally advanced breast cancer
	T4	N1	M0	Locally advanced breast cancer
	T4	N2	M0	Locally advanced breast cancer
Stage IIIC	Any T	N3	M0	Locally advanced breast cancer
Stage IV	Any T	Any N	M1	Metastatic disease

*According to 7th edition of *AJCC Cancer Staging Manual* (*6*).

movements, PET lacks sensitivity for smaller nodules. Careful scrutiny of CT images from PET/CT can reveal small nodules without ^{18}F-FDG uptake. However, CT performed during free breathing is less efficient than standard diagnostic thoracic CT.

PET is more efficient than CT or bone scintigraphy for depicting lytic or mixed bone metastases and bone marrow lesions but can lack sensitivity for purely sclerotic bone metastases. However, although sclerotic metastases have no ^{18}F-FDG uptake, they show osteocondensation on underlying CT images, so that they can be detected by hybrid PET/CT (*36*). A retrospective study comparing ^{18}F-FDG PET/CT and bone scanning suggested a high concordance; it was rare for bone scintigraphy to diagnose bone involvement not identified by ^{18}F-FDG PET/CT (*37*). These findings need confirmation in a prospective study but were significant enough to lead to the amendment of U.S. National Comprehensive Cancer Network (NCCN) guidelines to suggest that bone scintigraphy may not be necessary if both the PET and the CT components of ^{18}F-FDG PET/CT that are used for staging are able to identify bony metastases (*7*).

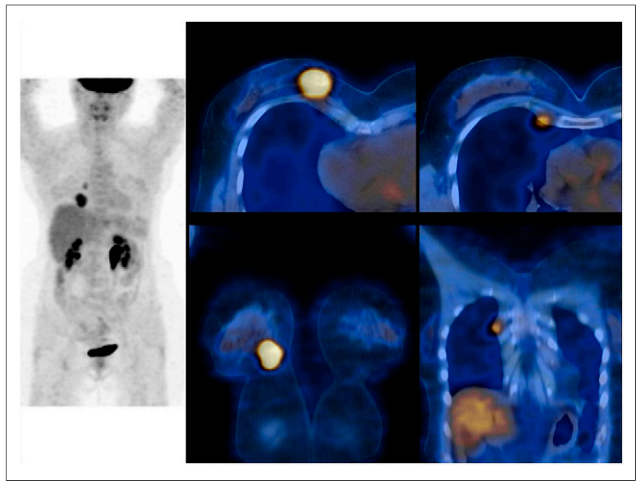

FIGURE 1. Invasive ductal carcinoma of right breast initially classified as T4cN0M0 (on basis of clinical examination, mammography, breast MRI, breast and axilla ultrasound, chest and abdominal CT scans, and bone scanning) in 63-y-old woman. PET/CT shows large breast tumor (SUV_{max} = 5.4) infiltrating skin and pectoral muscle (T4c) and depicts ^{18}F-FDG–avid internal mammary node (SUV_{max} = 2.9) (final classification: T4cN2bM0).

In total, there is evidence that PET/CT can advantageously replace conventional imaging for examining extraaxillary nodes, chest, abdomen, and bone in a single session (*12,17*). PET/CT lacks sensitivity for brain metastases; patients at risk require dedicated imaging.

AT WHICH CLINICAL STAGE SHOULD ^{18}F-FDG PET/CT BE INITIATED?

Between LABC and disease detected early (tumors of <2–3 cm; clinical N0), there are intermediate stages comprising large breast

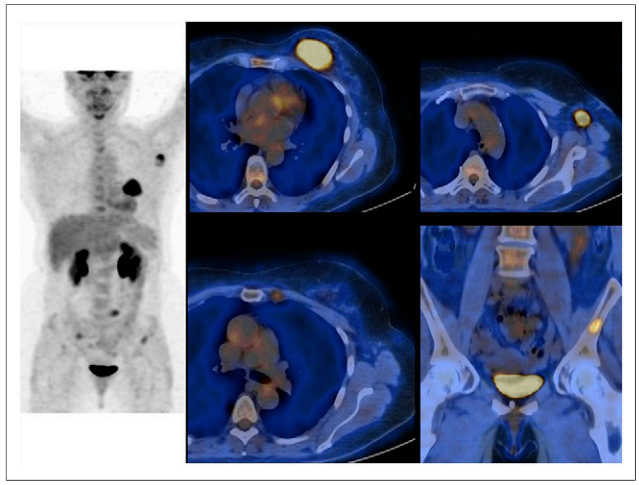

FIGURE 2. Invasive carcinoma of left breast classified as T3N2M0 (stage IIIA) before PET imaging in 62-y-old woman. PET/CT shows primary tumor (SUV_{max} = 7.3) and left axillary lymph node (SUV_{max} = 5.6), internal mammary lymph node (SUV_{max} = 2.1), and bone (SUV_{max} = 3.9) metastases. Classification after PET/CT was T3N3bM1 (stage IV).

TABLE 2
Studies Evaluating ^{18}F-FDG PET/CT for Baseline Staging of Clinical Stage II or III Breast Cancer*

Study	Year	Type of study	Patient recruitment	No. of patients	Conventional imaging (CI)	Results of PET/CT examination (compared with those of CI)	Reference for diagnosis	Conclusion of study
Fuster et al. (*14*)	2008	P	Noninflammatory large BC (≥3 cm)	60	Breast MRI, chest CT, liver US, BS	Sensitivity and specificity to detect LN involvement were 70% and 100%, respectively	Histopathologic confirmation or ≥1 y of follow-up	PET/CT accurately detected unsuspected extraaxillary LN involvement and distant metastases
						Sensitivity and specificity to detect metastases were 100% and 98%, respectively (vs. 60% and 83%, respectively, for CI)		PET/CT accurately ruled out false-positive distant metastases on CI
						Change of BC staging in 42% of patients		
Segaert et al. (*16*)	2010	R	Clinical stage IIB or III BC	70	Chest radiography, liver US, BS	Sensitivity and specificity to detect axillary LN involvement were 62.5% and 100%, respectively (vs. 87.5% and 100%, respectively, for CI)	Histopathologic confirmation or clinical or imaging follow-up	For LABC, PET/CT was superior to CI for detecting internal mammary-chain nodes and metastatic disease but not for axillary staging
						Sensitivity to detect internal mammary LN involvement was 100%		
						7 patients were identified as having distant metastases despite normal CI results		
Koolen et al. (*17*)	2012	P	Clinical stage II or III BC	154	Chest radiography, liver US, BS	Correct stage IV upstaging in 13% of patients	Histopathologic confirmation or additional imaging or follow-up	PET/CT outperformed CI in detection of distant metastases
						Incorrect stage IV upstaging in 3% of patients		
						Change of BC therapeutic management in 8% of patients		
Groheux et al. (*18*)	2012	P	Clinical stage II or III BC	254	Mammography, breast + axilla US, breast MRI ± additional directed radiologic studies	Change of clinical stage in 30% of patients	Histologic confirmation or directed radiologic studies + patient follow-up	Yield of PET/CT in staging of BC was substantial in patients with clinical stage IIB BC or higher
						Upstaging to stage IV in 2% of stage IIA, 11% of stage IIB, 17% of stage IIIA, 36% of stage IIIB, and 47% of clinical stage IIIC BC patients		PET/CT provided powerful prognostic stratification of patients
						Status of M stage on PET/CT and TNBC phenotype were independent predictors of worst survival		

TABLE 2 (Continued)

Study	Year	Type of study	Patient recruitment	No. of patients	Conventional imaging (CI)	Results of PET/CT examination (compared with those of CI)	Reference for diagnosis	Conclusion of study
Cochet et al. (*19*)	2014	P	BC ≥ 2 cm	142	Mammography, breast + chest US ± breast MRI, chest radiography, abdominal US, BS ± abdominal or chest CT	Upstaging in 30% of patients (to stage IV in 8%)	Histopathologic confirmation or additional imaging + patient follow-up	BC staging with PET/CT more accurately stratified prognostic risk than did CI
						Downstaging in 16% of patients		
						Change of BC therapeutic management in 13% of patients		
						Stronger prognostic stratification than CI ($P < 0.0001$)		
Riedl et al. (*20*)	2014	R	≤40 y old with clinical stage I–IIIC BC	134	Mammography, breast US ± breast MRI	Unsuspected extraaxillary LN involvement in 11% of women	Histologic confirmation for patients with upstaging	PET/CT was valuable for baseline staging in young patients with asymptomatic stage IIB and III BC
						Unsuspected metastasis in 15% of women		
						Upstaging to stage IV in 5% of stage I + IIA, 17% of stage IIB, 31% of stage IIIA, and 50% of stage IIIB + IIIC BC patients		
Krammer et al. (*21*)	2015	P	T ≥ T2 or positive LN	101	Mammography, breast + chest US ± breast MRI, chest radiography, abdominal US, BS	Upgrading of N or M stage in 19% of patients	Histopathologic confirmation or additional imaging or follow-up	Compared with CI, PET/CT had relevant impact on baseline staging and therapeutic management of BC
						Change of BC therapeutic management in 11% of patients		

*In the case of several reports by the same team, study with largest number of patients was selected. Studies with only inflammatory breast cancer were not included.

P = prospective; BC = breast cancer; US = ultrasonography; BS = bone scintigraphy; LN = lymph node; R = retrospective.

carcinomas or clinical N1 disease (stage IIA, stage IIB, and the T3N1 category of stage IIIA) (Table 2; Fig. 3). Early studies including both patients with stage II and patients with stage III breast carcinomas showed that PET/CT was helpful for detecting extraaxillary lymph node involvement and distant occult lesions (*13–17*). For example, Fuster et al. studied 60 consecutive patients with large breast cancers (>3 cm). Metastases missed by "conventional" work-up (chest contrast-enhanced CT, liver ultrasonography, and bone scans) were visualized by ^{18}F-FDG PET/CT in 8 patients (*14*). However, the precise clinical stage at which PET/CT could be performed with favorably balanced cost-effectiveness remained unclear from these studies.

More recently, Groheux et al. reported results from a prospective evaluation of 254 patients with breast cancers larger than 2 cm (*18*). The yield from ^{18}F-FDG PET/CT imaging was examined in each of the specific subsets of patients with clinical stage IIA, IIB, IIIA, IIIB, or IIIC breast cancer (based on clinical examination, mammography, breast MRI, and locoregional ultrasonography). ^{18}F-FDG PET/CT

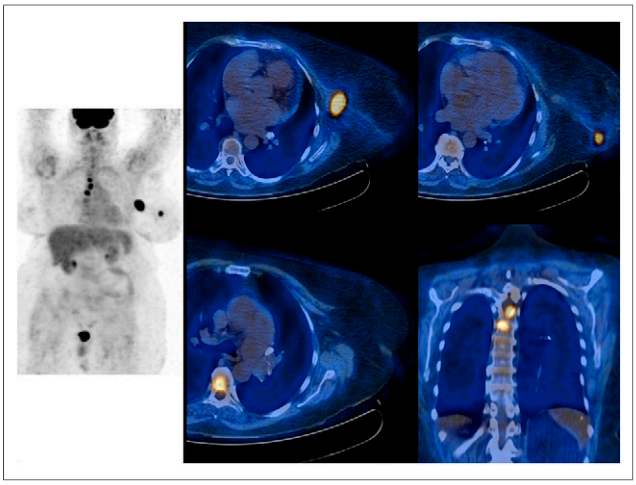

FIGURE 3. Bifocal invasive ductal carcinoma of left breast initially classified T3N0M0 (stage IIB) in 63-y-old woman. PET/CT shows 2 ^{18}F-FDG–avid foci in left breast (SUV_{max} = 9.6 and 6.4) and 3 ^{18}F-FDG–avid bone marrow foci in thoracic spine (T4, T5, and T6). Classification after PET/CT was T3N0M1 (stage IV).

imaging changed the clinical stage in 77 patients (30.3%). It showed unsuspected N3 disease (infra- or supraclavicular or internal mammary nodes) in 40 patients and distant metastases in 53 patients. When the yield was examined by subsets, PET/CT revealed distant metastases in 2.3% of patients with clinical stage IIA disease (1/44), 10.7% of patients with stage IIB disease (6/56), 17.5% of patients with stage IIIA disease (11/63), 36.5% of patients with stage IIIB disease (27/74), and 47.1% of patients with stage IIIC disease (8/17). Stage IIIA was heterogeneous. The rate of distant metastases in patients with T3N1 disease (primary operable) was similar to that in patients with stage IIB disease (T2N1/T3N0). It was much higher in patients with N2 disease and was close to that found in patients with stage IIIB disease (*18*). Two other studies (1 including only breast cancer patients younger than 40 y) also showed that the yield from ^{18}F-FDG PET/CT was high starting in patients with clinical stage IIB disease (*16,20*).

The results of these studies provide supportive evidence for a role of ^{18}F-FDG PET/CT in determining the stage of disease for high- and intermediate-risk patients (clinical stage IIB or higher). Some breast oncology societies have changed their guideline recommendations to include these findings. However, practices differ according to countries. In the United States, current NCCN guidelines do not recommend the systematic use of ^{18}F-FDG PET or PET/CT in breast cancer staging but state that "^{18}F-FDG PET/CT may be helpful in identifying unsuspected regional nodal disease or distant metastases in LABC when used in addition to standard imaging studies" (*7*). In France, the National Cancer Institute recommends work-up for distant sites in the case of T3, T4, or N-positive disease (*38*); ^{18}F-FDG PET/CT as a single procedure is an option (*38*).

PET/CT has no role in patients with clinical stage I breast cancer (clinically node-negative with breast tumors of ≤2 cm), which currently represents most newly diagnosed cases. These patients receive breast surgery with sentinel node biopsy (*2*). PET/CT cannot be used as a substitute for sentinel node biopsy because the spatial resolution of PET instruments precludes the detection of very small nodal metastases (*1–5*). The probability that ^{18}F-FDG PET will detect extraaxillary regional node metastases or distant metastases in early-stage disease is low, and ^{18}F-FDG imaging exposes women to false-positive findings. In a multicenter prospective study of 325 women with operable breast cancer, ^{18}F-FDG PET (without the CT component) suggested distant metastases in 13 patients; metastatic disease was confirmed in 3 patients (0.9%), and the findings were false-positive in 10 patients (3.0%) (*4*). Therefore, the use of PET/CT in such patients is unjustified and exposes women to undue costs and additional anxiety and morbidity associated with false-positive diagnoses (*39*).

In the study by Groheux et al. (*18*), the overall yield from ^{18}F-FDG PET/CT for stage IIA disease was only 4.5% unexpected findings (2.3% distant metastases and 2.3% extraaxillary nodes); these results challenge the use of ^{18}F-FDG PET/CT for stage IIA disease. In that study, stage IIA was represented mainly by T2N0 disease (patients with T1N1 disease, as determined by positive sentinel node biopsy, were not included). These data require confirmation in larger studies.

SHOULD BREAST CANCER BIOLOGY, HISTOLOGY, AND PHENOTYPE BE CONSIDERED FOR BREAST CANCER STAGING?

^{18}F-FDG uptake depends on the histologic and biologic characteristics of the breast tumor. Invasive ductal carcinoma exhibits higher uptake than invasive lobular carcinoma (*40–42*). Invasive tumors with Scarff-Bloom-Richardson grade 3 exhibit higher ^{18}F-FDG uptake than lower-grade tumors (*41,42*). There is also a positive correlation between the tumor proliferation index (Ki-67 expression) and the intensity of ^{18}F-FDG uptake (*41*). SUVs are higher in tumors that are negative for hormone receptors (*41,42*). Triple-negative breast cancer (TNBC; negative for estradiol and progesterone receptors and lacking human epidermal growth factor receptor 2 [HER2] overexpression) is usually highly ^{18}F-FDG–avid (*42,43*).

Recent animal data showed that the molecular determinants of ^{18}F-FDG uptake in breast cancer are complex and multifactorial (*44*). Awareness of the determinants of ^{18}F-FDG uptake by oncologists and nuclear physicians is important because it may influence their clinical use of ^{18}F-FDG PET/CT in breast cancer—based on the sensitivity with which they consider the modality to detect regional and distant disease spread—as well as their interpretation of the imaging results.

In the study by Riedl et al. (*20*), grade and receptor phenotype were found not to be related to distant metastases or extraaxillary lymphadenopathy. In the study by Groheux et al. (*18*), the rates of distant involvement did not differ according to grade or breast cancer phenotype. However, the sites of involvement differed. Patients with TNBC and HER2-positive disease had high proportions of extraskeletal metastases (*18*). N3 disease was more frequent in patients with grade 3 tumors, TNBC, or the HER2-positive phenotype.

Beyond the AJCC clinical stages, further studies are needed to evaluate the yield from PET/CT according to biomarkers of tumor aggressiveness. Given the high proportions of extraskeletal metastases in TNBC and HER2-positive breast cancer (*18*), the association of brain MRI with whole-body (WB) PET/CT should be evaluated for these subtypes. For lobular carcinoma, it is important that PET/CT interpretation be done with the knowledge that this histologic subtype has lower ^{18}F-FDG uptake. Osteosclerotic bone lesions in a patient with lobular carcinoma

TABLE 3
Studies Evaluating ^{18}F-FDG PET/CT for Restaging

Study	Year	Type of study	No. of patients	Patient recruitment	Other diagnostic modalities	Results: Diagnostic performance*	Results: Management impact†	Results: Prognosis	Results: Conclusion
Radan et al. (*23*)	2006	R	46	Suspected recurrence on basis of rising tumor marker levels	ceCT (n = 37)	PET/CT: 27 TP (24 distant, 3 locoregional), 5 FP; Se = 90, Sp = 71, Acc = 83	51		PET/CT had high performance indices and was superior to ceCT for diagnosis of recurrence
						ceCT: Se = 70, Sp = 47, Acc = 59			
Schmidt et al. (*26*)	2008	R	33	Suspected recurrence on basis of clinical (n = 9) or imaging (n = 14) findings or rising tumor marker levels (n = 10)	WB MRI 1.5 T (n = 23) or 3 T (n = 10)	PET/CT: Se = 91, Sp = 90, Acc = 91			PET/CT was superior for locoregional recurrence detection, whereas WB MRI showed excellent performance for detection of distant lesions
						WB MRI: Se = 93, Sp = 86, Acc = 91			
Aukema et al. (*28*)	2010	R	56	Confirmed locoregional recurrence	Chest MRI, CT, or radiography; liver US; bone scanning	PET/CT: Se = 97, Sp = 92, Acc = 95	48		PET/CT played important role in staging for patients with locoregional recurrence, in addition to CIT
						PET/CT revealed additional lesions in 32 patients (57%) that were not visible on CIT in 25 patients (45%)			
Evangelista et al. (*30*)	2011	R	111	Suspected recurrence on basis of clinical (n = 26) or imaging (n = 85) findings	CT, CA 15.3	PET/CT: Se = 81, Sp = 52, Acc = 60	56	PET/CT was independent predictor of disease relapse	PET/CT was more sensitive than CT and CA 15.3 for evaluation of disease relapse
						CT: Se = 72, Sp = 37, Acc = 47			
						CA 15.3: Se = 50, Sp = 69, Acc = 64			
Champion et al. (*31*)	2011	R	228	Suspected recurrence on basis of rising tumor marker levels	Chest radiography, abdominopelvic US, bone scanning (n = 67)	PET/CT: Se = 94, Sp = 85, Acc = 92	54		PET/CT was more sensitive than CIT for detection of recurrence in patients with rising tumor marker levels

TABLE 3 (Continued)

Study	Year	Type of study	No. of patients	Patient recruitment	Other diagnostic modalities	Results: Diagnostic performance*	Results: Management impact†	Results: Prognosis	Results: Conclusion
						CIT: Se = 33, Sp = 100, Acc = 48			
Chang et al. (*33*)	2014	R	140	Suspected recurrence (*n* = 71) or routine follow-up (*n* = 69)		For suspected recurrence: Se = 88, Sp = 87, Acc = 87	49 (suspected recurrence)		PET/CT was useful for early diagnosis of recurrence and might be useful for follow-up in asymptomatic patients
						For routine follow-up: Se = 78, Sp = 92, Acc = 90	10 (follow-up)		
Cochet et al. (*34*)	2014	R	63	Suspected recurrence (*n* = 58) or routine follow-up (*n* = 5)	Chest CT or radiography; abdominopelvic MRI, CT, or US; bone scanning	PET/CT: NPV = 86, PPV = 95	57	PET/CT predicted survival better than did CIT	PET/CT provided incremental information that influenced management and refined prognostic stratification
						CIT: NPV = 54, PPV = 70			
Di Gioia et al. (*35*)	2015	P	44	Suspected recurrence on basis of rising tumor marker levels	WB MRI 1.5 T (*n* = 43)	WB imaging (MRI or PET/CT) accurately detected metastases in 28 patients (64%), including 7 patients with oligometastatic disease, and secondary malignancy in 6 patients (14%)		Survival differed according to subtype	WB imaging was highly effective for early detection of recurrence in asymptomatic patients with confirmed rise in tumor marker levels

*Reported as percentages for sensitivity (Se), specificity (Sp), accuracy (Acc), negative predictive value (NPV), and positive predictive value (PPV).

†Reported as percentages of patients for whom findings had impact on management.

R = retrospective; ceCT = contrast-enhanced CT; TP = true-positive; FP = false-positive; US = ultrasonography; CIT = conventional imaging techniques; CA 15.3 = carcinoma antigen 15.3; P = prospective.

should be considered suspect even when they are not ^{18}F-FDG–avid (*45*).

PROGNOSTIC VALUE OF BASELINE ^{18}F-FDG PET/CT

In the study by Groheux et al., among 189 patients with initial clinical stage IIB or higher and adequate follow-up, disease-specific survival was significantly shorter in the 47 patients found by ^{18}F-FDG PET/CT to have M1 disease than in those with M0 disease (3-y disease-specific survival of 57% vs. 88%; $P < 0.001$) (*18*). In a recent publication, Cochet et al. also emphasized the prognostic value of ^{18}F-FDG PET/CT for patients with clinical stage II or III disease (*19*).

Besides staging, the level of ^{18}F-FDG uptake by a primary tumor also has prognostic value. High ^{18}F-FDG uptake has been associated with a poorer outcome (*10,46,47*). Recently, high baseline tumor SUV_{max} and total lesion glycolysis were associated with shorter event-free survival in patients with estrogen receptor–positive/HER2-negative breast cancer (*47*).

PET/CT IN RESTAGING OF BREAST CARCINOMA

Early detection and precise characterization of the extent of recurrent disease are essential for guiding optimal therapy and prognostication. Locoregional recurrence may benefit from curative treatment based on surgery or radiation therapy, whereas distant metastases usually require palliative systemic therapy (*31*). Breast cancer recurrence can be suggested by clinical symptoms, radiologic findings, or rising levels of tumor markers (carcinoma antigen 15.3 or carcinoembryonic embryonic antigen). In all of these situations, the accuracy of PET/CT has been shown to be high (Table 3).

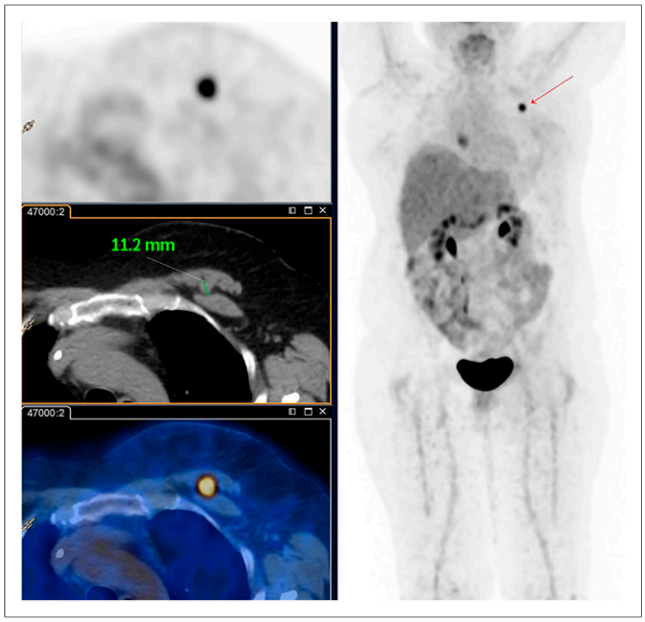

FIGURE 4. TNBC in left breast initially classified as T3N1M0 and treated with neoadjuvant chemotherapy, conservative surgery, and locoregional radiotherapy in 50-y-old woman. Eight months after end of radiotherapy, patient had moderate pain in left chest wall, and ultrasound of axilla showed suspected lesion. PET/CT revealed highly ^{18}F-FDG–avid left interpectoral lymph node (11.2 mm; SUV = 9.4; arrow) but no other abnormal uptake. Biopsy confirmed this isolated locoregional recurrence of TNBC.

Because it allows better discrimination between posttreatment scar or fibrosis and viable tumor tissue, PET/CT is efficient for detecting locoregional recurrence (Fig. 4), especially in the chest wall, axilla, and extraaxillary lymph nodes basins, with better performance than CT or MRI (*26–28*). In the study by Schmidt et al., PET/CT was found to be more sensitive than WB MRI for the detection of lymph node involvement (n = 21 vs. n = 16); however, WB MRI was slightly more sensitive (n = 154 vs. n = 147) for the detection of distant metastases (*26*). Two metaanalyses compared ^{18}F-FDG PET/CT, conventional imaging (ultrasonography, CT, and bone scintigraphy), and MRI for the detection of breast cancer recurrence (*48,49*). PET/CT outperformed PET alone and conventional imaging but not MRI. Compared with conventional imaging, PET/CT provides better prognostic stratification by discriminating patients with locoregional recurrence only from those with distant recurrence (*30,34,35*) and is helpful for downstaging suspected lesions in some situations (*34,50*).

In the specific setting of asymptomatic patients with rising tumor marker levels and negative conventional imaging results, PET/CT has shown strength in detecting recurrence earlier than traditional imaging (*29–31,35,51*). In a metaanalysis of 13 studies, the sensitivity, specificity, and accuracy of PET were 87.8%, 69.3%, and 82.8%, respectively (*51*). PET/CT is also efficient in patients with suspected recurrence but negative tumor marker results (*52*).

Including ^{18}F-FDG PET/CT in the diagnostic algorithm for breast cancer relapse has a major influence on management; after PET/CT, management was modified in 48%–57% of patients with suspected relapse (*23,28–31,33,34*). This impact could be even higher with the development of local control strategies for oligometastatic disease, such as surgery or stereotactic radiotherapy (*53,54*). Among patients with evidence of distant relapse, PET/CT may identify oligometastatic status in a significant proportion (*35*).

Most studies have retrospectively evaluated the incremental role of ^{18}F-FDG PET/CT, in addition to conventional methods, in the diagnostic work-up of breast cancer relapse. Uncertainty remains about its utility as a replacement for conventional work-up rather than as an adjunct to conventional imaging (*49*). The potential roles of combined PET and whole-body MRI and contrast-enhanced PET/MRI are being investigated (*55*).

Although PET/CT offers the opportunity to provide an overview of disease in a single procedure (*22–35*), its use as a first-line method is not recommended in international guidelines. NCCN guidelines recommend that chest CT, abdominopelvic CT or MRI, and bone scanning be performed first; ^{18}F-FDG PET/CT is considered optional and "most helpful in situations where standard staging studies are equivocal or suspicious" (*7*). The European Society for Medical Oncology recommends that "^{18}F-FDG PET/CT can be useful for identifying the site of relapse when traditional methods are equivocal or conflicting" (*56*).

With regard to surveillance, American Society of Clinical Oncology and NCCN guidelines recommend only regular history, physical examination, and mammography for breast cancer routine follow-up (*7,57*). Systematic ^{18}F-FDG PET/CT is not indicated. In a recent study, Chang et al. described a change in planned management in 10% of patients receiving PET/CT for routine follow-up without suspected relapse before imaging (*33*). The role of systematic PET/CT examination in subgroups of patients with a high risk of early relapse should be analyzed in a multicenter prospective study. One such subgroup could be patients who have TNBC but for whom a complete pathologic response was not achieved after neoadjuvant chemotherapy. Of 51 patients with TNBC who had no distant metastases at baseline PET but had residual disease after neoadjuvant chemotherapy, 21 experienced a relapse within a few years (17 developed distant metastases) (*52*).

CONCLUSION

^{18}F-FDG PET/CT is useful for staging locally advanced and inflammatory breast cancer. One advantage of ^{18}F-FDG PET/CT over conventional imaging is that it allows the examination of extraaxillary nodes as well as the chest, abdomen, and bone in a single session. The yield from PET/CT is also substantial in patients with clinical stage IIB (T2N1 and T3N0) and primary operable stage IIIA (T3N1) breast carcinomas; further studies with cost-effectiveness assessments would be helpful. PET is definitely not recommended for the initial assessment of patients with clinical T1N0 breast cancer.

^{18}F-FDG PET/CT is also useful for detecting recurrence and for restaging in breast cancer patients by providing incremental information that can influence management and refine prognostic stratification. Randomized trials comparing ^{18}F-FDG PET/CT and conventional imaging as initial restaging procedures are needed. The interest in ^{18}F-FDG PET/CT will increase with the development of local control strategies for oligometastatic disease.

DISCLOSURE

No potential conflict of interest relevant to this article was reported.

REFERENCES

1. Wahl RL, Siegel BA, Coleman RE, Gatsonis CG. Prospective multicenter study of axillary nodal staging by positron emission tomography in breast cancer: a report of the Staging Breast Cancer with PET Study Group. *J Clin Oncol.* 2004;22: 277–285.
2. Veronesi U, De Cicco C, Galimberti VE, et al. A comparative study on the value of FDG-PET and sentinel node biopsy to identify occult axillary metastases. *Ann Oncol.* 2007;18:473–478.
3. Cooper KL, Harnan S, Meng Y, et al. Positron emission tomography (PET) for assessment of axillary lymph node status in early breast cancer: a systematic review and meta-analysis. *Eur J Surg Oncol.* 2011;37:187–198.
4. Pritchard KI, Julian JA, Holloway CMB, et al. Prospective study of 2-[^{18}F]fluorodeoxyglucose positron emission tomography in the assessment of regional nodal spread of disease in patients with breast cancer: an Ontario Clinical Oncology Group study. *J Clin Oncol.* 2012;30:1274–1279.
5. Jeong YJ, Kang DY, Yoon HJ, Son HJ. Additional value of F-18 FDG PET/CT for initial staging in breast cancer with clinically negative axillary nodes. *Breast Cancer Res Treat.* 2014;145:137–142.
6. Edge SB, Compton CC. The American Joint Committee on Cancer: the 7th edition of the *AJCC Cancer Staging Manual* and the future of TNM. *Ann Surg Oncol.* 2010;17:1471–1474.
7. NCCN clinical practice guidelines in oncology. Breast cancer. Version 3. National Comprehensive Cancer Network website. http://www.nccn.org/professionals/physician_gls/pdf/breast.pdf. 2015. Accessed October 2, 2015.
8. van der Hoeven JJ, Krak NC, Hoekstra OS, et al. ^{18}F-2-fluoro-2-deoxy-D-glucose positron emission tomography in staging of locally advanced breast cancer. *J Clin Oncol.* 2004;22:1253–1259.
9. Carkaci S, Macapinlac HA, Cristofanilli M, et al. Retrospective study of ^{18}F-FDG PET/CT in the diagnosis of inflammatory breast cancer: preliminary data. *J Nucl Med.* 2009;50:231–238.
10. Alberini J-L, Lerebours F, Wartski M, et al. ^{18}F-fluorodeoxyglucose positron emission tomography/computed tomography (FDG-PET/CT) imaging in the staging and prognosis of inflammatory breast cancer. *Cancer.* 2009;115:5038–5047.
11. Walker GV, Niikura N, Yang W, et al. Pretreatment staging positron emission tomography/computed tomography in patients with inflammatory breast cancer influences radiation treatment field designs. *Int J Radiat Oncol Biol Phys.* 2012;83:1381–1386.
12. Groheux D, Giacchetti S, Delord M, et al. ^{18}F-FDG PET/CT in staging patients with locally advanced or inflammatory breast cancer: comparison to conventional staging. *J Nucl Med.* 2013;54:5–11.
13. Groheux D, Moretti J-L, Baillet G, et al. Effect of ^{18}F-FDG PET/CT imaging in patients with clinical stage II and III breast cancer. *Int J Radiat Oncol Biol Phys.* 2008;71:695–704.
14. Fuster D, Duch J, Paredes P, et al. Preoperative staging of large primary breast cancer with [^{18}F]fluorodeoxyglucose positron emission tomography/computed tomography compared with conventional imaging procedures. *J Clin Oncol.* 2008;26:4746–4751.
15. Aukema TS, Straver ME, Peeters MJ, et al. Detection of extra-axillary lymph node involvement with FDG PET/CT in patients with stage II-III breast cancer. *Eur J Cancer.* 2010;46:3205–3210.
16. Segaert I, Mottaghy F, Ceyssens S, et al. Additional value of PET-CT in staging of clinical stage IIB and III breast cancer. *Breast J.* 2010;16:617–624.
17. Koolen BB, Vrancken Peeters MJ, Aukema TS, et al. ^{18}F-FDG PET/CT as a staging procedure in primary stage II and III breast cancer: comparison with conventional imaging techniques. *Breast Cancer Res Treat.* 2012;131:117–126.
18. Groheux D, Hindié E, Delord M, et al. Prognostic impact of ^{18}FDG-PET-CT findings in clinical stage III and IIB breast cancer. *J Natl Cancer Inst.* 2012;104: 1879–1887.
19. Cochet A, Dygai-Cochet I, Riedinger JM, et al. ^{18}F-FDG PET/CT provides powerful prognostic stratification in the primary staging of large breast cancer when compared with conventional explorations. *Eur J Nucl Med Mol Imaging.* 2014;41:428–437.
20. Riedl CC, Slobod E, Jochelson M, et al. Retrospective analysis of ^{18}F-FDG PET/CT for staging asymptomatic breast cancer patients younger than 40 years. *J Nucl Med.* 2014;55:1578–1583.
21. Krammer J, Schnitzer A, Kaiser CG, et al. ^{18}F-FDG PET/CT for initial staging in breast cancer patients: is there a relevant impact on treatment planning compared to conventional staging modalities? *Eur Radiol.* 2015;25:2460–2469.
22. Fueger BJ, Weber WA, Quon A, et al. Performance of 2-deoxy-2-[F-18]fluoro-D-glucose positron emission tomography and integrated PET/CT in restaged breast cancer patients. *Mol Imaging Biol.* 2005;7:369–376.
23. Radan L, Ben-Haim S, Bar-Shalom R, Guralnik L, Israel O. The role of FDG-PET/CT in suspected recurrence of breast cancer. *Cancer.* 2006;107:2545–2551.
24. Haug AR, Schmidt GP, Klingenstein A, et al. F-18-fluoro-2-deoxyglucose positron emission tomography/computed tomography in the follow-up of breast cancer with elevated levels of tumor markers. *J Comput Assist Tomogr.* 2007;31: 629–634.
25. Veit-Haibach P, Antoch G, Beyer T, et al. FDG-PET/CT in restaging of patients with recurrent breast cancer: possible impact on staging and therapy. *Br J Radiol.* 2007;80:508–515.
26. Schmidt GP, Baur-Melnyk A, Haug A, et al. Comprehensive imaging of tumor recurrence in breast cancer patients using whole-body MRI at 1.5 and 3 T compared to FDG-PET-CT. *Eur J Radiol.* 2008;65:47–58.
27. Dirisamer A, Halpern BS, Flöry D, et al. Integrated contrast-enhanced diagnostic whole-body PET/CT as a first-line restaging modality in patients with suspected metastatic recurrence of breast cancer. *Eur J Radiol.* 2010;73: 294–299.
28. Aukema TS, Rutgers EJT, Vogel WV, et al. The role of FDG PET/CT in patients with locoregional breast cancer recurrence: a comparison to conventional imaging techniques. *Eur J Surg Oncol.* 2010;36:387–392.
29. Grassetto G, Fornasiero A, Otello D, et al. ^{18}F-FDG-PET/CT in patients with breast cancer and rising Ca 15-3 with negative conventional imaging: a multicentre study. *Eur J Radiol.* 2011;80:828–833.
30. Evangelista L, Baretta Z, Vinante L, et al. Tumour markers and FDG PET/CT for prediction of disease relapse in patients with breast cancer. *Eur J Nucl Med Mol Imaging.* 2011;38:293–301.
31. Champion L, Brain E, Giraudet A-L, et al. Breast cancer recurrence diagnosis suspected on tumor marker rising: value of whole-body ^{18}FDG-PET/CT imaging and impact on patient management. *Cancer.* 2011;117:1621–1629.
32. Manohar K, Mittal BR, Senthil R, Kashyap R, Bhattacharya A, Singh G. Clinical utility of F-18 FDG PET/CT in recurrent breast carcinoma. *Nucl Med Commun.* 2012;33:591–596.
33. Chang HT, Hu C, Chiu YL, Peng NJ, Liu RS. Role of 2-[^{18}F] fluoro-2-deoxy-D-glucose-positron emission tomography/computed tomography in the post-therapy surveillance of breast cancer. *PLoS One.* 2014;9:e115127.
34. Cochet A, David S, Moodie K, et al. The utility of 18 F-FDG PET/CT for suspected recurrent breast cancer: impact and prognostic stratification. *Cancer Imaging.* 2014;14:13.
35. Di Gioia D, Stieber P, Schmidt GP, Nagel D, Heinemann V, Baur-Melnyk A. Early detection of metastatic disease in asymptomatic breast cancer patients with whole-body imaging and defined tumour marker increase. *Br J Cancer.* 2015;112: 809–818.
36. Groheux D, Espié M, Giacchetti S, Hindié E. Performance of FDG PET/CT in the clinical management of breast cancer. *Radiology.* 2013;266:388–405.
37. Morris PG, Lynch C, Feeney JN, et al. Integrated positron emission tomography/computed tomography may render bone scintigraphy unnecessary to investigate suspected metastatic breast cancer. *J Clin Oncol.* 2010;28:3154–3159.
38. Non-metastatic invasive breast carcinoma: synthesis. French National Cancer Institute website. http://www.e-cancer.fr/Professionnels-de-sante/Recommandations-et-outils-d-aide-a-la-pratique/Cancers-du-sein. Published July 2012. Accessed October 11, 2015.
39. Schnipper LE, Smith TJ, Raghavan D, et al. American Society of Clinical Oncology identifies five key opportunities to improve care and reduce costs: the top five list for oncology. *J Clin Oncol.* 2012;30:1715–1724.
40. Avril N, Rosé CA, Schelling M, et al. Breast imaging with positron emission tomography and fluorine-18 fluorodeoxyglucose: use and limitations. *J Clin Oncol.* 2000;18:3495–3502.
41. Gil-Rendo A, Martínez-Regueira F, Zornoza G, García-Velloso MJ, Beorlegui C, Rodriguez-Spiteri N. Association between [^{18}F]fluorodeoxyglucose uptake and prognostic parameters in breast cancer. *Br J Surg.* 2009;96:166–170.
42. Groheux D, Giacchetti S, Moretti J-L, et al. Correlation of high ^{18}F-FDG uptake to clinical, pathological and biological prognostic factors in breast cancer. *Eur J Nucl Med Mol Imaging.* 2011;38:426–435.
43. Basu S, Chen W, Tchou J, et al. Comparison of triple-negative and estrogen receptor-positive/progesterone receptor-positive/HER2-negative breast carcinoma using quantitative fluorine-18 fluorodeoxyglucose/positron emission tomography imaging parameters: a potentially useful method for disease characterization. *Cancer.* 2008;112:995–1000.

44. Alvarez JV, Belka GK, Pan T-C, et al. Oncogene pathway activation in mammary tumors dictates FDG-PET uptake. *Cancer Res.* 2014;74:7583–7598.
45. Dashevsky BZ, Goldman DA, Parsons M, et al. Appearance of untreated bone metastases from breast cancer on FDG PET/CT: importance of histologic subtype. *Eur J Nucl Med Mol Imaging.* 2015;42:1666–1673.
46. Oshida M, Uno K, Suzuki M, et al. Predicting the prognoses of breast carcinoma patients with positron emission tomography using 2-deoxy-2-fluoro[^{18}F]-D-glucose. *Cancer.* 1998;82:2227–2234.
47. Groheux D, Sanna A, Majdoub M, et al. Baseline tumor ^{18}F-FDG uptake and modifications after 2 cycles of neoadjuvant chemotherapy are prognostic of outcome in ER+/HER2− breast cancer. *J Nucl Med.* 2015;56:824–831.
48. Pan L, Han Y, Sun X, Liu J, Gang H. FDG-PET and other imaging modalities for the evaluation of breast cancer recurrence and metastases: a meta-analysis. *J Cancer Res Clin Oncol.* 2010;136:1007–1022.
49. Pennant M, Takwoingi Y, Pennant L, et al. A systematic review of positron emission tomography (PET) and positron emission tomography/computed tomography (PET/CT) for the diagnosis of breast cancer recurrence. *Health Technol Assess.* 2010;14:1–103.
50. Constantinidou A, Martin A, Sharma B, Johnston SRD. Positron emission tomography/computed tomography in the management of recurrent/metastatic breast cancer: a large retrospective study from the Royal Marsden Hospital. *Ann Oncol.* 2011;22:307–314.
51. Evangelista L, Cervino AR, Ghiotto C, Al-Nahhas A, Rubello D, Muzzio PC. Tumor marker-guided PET in breast cancer patients: a recipe for a perfect wedding—a systematic literature review and meta-analysis. *Clin Nucl Med.* 2012;37:467–474.
52. Groheux D, Giacchetti S, Delord M, et al. Prognostic impact of ^{18}F-FDG PET/CT staging and of pathological response to neoadjuvant chemotherapy in triple-negative breast cancer. *Eur J Nucl Med Mol Imaging.* 2015;42:377–385.
53. Weichselbaum RR, Hellman S. Oligometastases revisited. *Nat Rev Clin Oncol.* 2011;8:378–382.
54. Salama JK, Chmura SJ. The role of surgery and ablative radiotherapy in oligometastatic breast cancer. *Semin Oncol.* 2014;41:790–797.
55. Catalano OA, Nicolai E, Rosen BR, et al. Comparison of CE-FDG-PET/CT with CE-FDG-PET/MR in the evaluation of osseous metastases in breast cancer patients. *Br J Cancer.* 2015;112:1452–1460.
56. Cardoso F, Harbeck N, Fallowfield L, Kyriakides S, Senkus E; ESMO Guidelines Working Group. Locally recurrent or metastatic breast cancer: ESMO clinical practice guidelines for diagnosis, treatment and follow-up. *Ann Oncol.* 2012;23 (suppl 7):vii11–vii19.
57. Khatcheressian JL, Hurley P, Bantug E, et al. Breast cancer follow-up and management after primary treatment: American Society of Clinical Oncology clinical practice guideline update. *J Clin Oncol.* 2013;31:961–965.