
High Diagnostic Value of ^{18}F -FDG PET/CT in Endometrial Cancer: Systematic Review and Meta-Analysis of the Literature

Vikram Rao Bollineni^{1,2}, Sigmund Ytre-Hauge^{3,4}, Oksana Bollineni-Balabay⁵, Helga Birgitte Salvesen^{1,2}, and Ingrid Salvesen Haldorsen^{3,4}

¹Department of Obstetrics and Gynecology, Haukeland University Hospital, Bergen, Norway; ²Center for Cancer Biomarkers, Department of Clinical Science, University of Bergen, Bergen, Norway; ³Department of Radiology, Haukeland University Hospital, Bergen, Norway; ⁴Department of Clinical Medicine, University of Bergen, Bergen, Norway; ⁵Department of Quantitative Economics, School of Business and Economics, Maastricht University, Maastricht, The Netherlands

The aim of this study was to evaluate the diagnostic performance of ^{18}F -FDG PET/CT for the preoperative assessment of lymph node metastases (LNM) in endometrial cancer patients and for the assessment of endometrial cancer recurrence (ECR) after primary surgical treatment. **Methods:** A comprehensive search was performed on Pubmed/MEDLINE databases for studies reporting the diagnostic performance of ^{18}F -FDG PET/CT for assessment of LNM and ECR published up to August 15, 2015. Twenty-one studies (13 for LNM and 8 for ECR) were included in the systematic review and meta-analysis. Pooled estimates of sensitivity, specificity, positive likelihood ratio, negative likelihood ratio, and diagnostic odds ratio of the ^{18}F -FDG PET/CT were calculated along with 95% confidence intervals (CIs). A summary receiver-operating-characteristics curve (SROC) was constructed, and the area under the SROC curve (AUC) was determined along with Q^* index. **Results:** The overall pooled sensitivity, specificity, positive likelihood ratio, negative likelihood ratio, diagnostic odds ratio, and AUC (with 95% CI) of ^{18}F -FDG PET/CT for detection of LNM were 0.72 (95% CI, 0.63–0.80), 0.94 (95% CI, 0.93–0.96), 10.9 (95% CI, 7.9–15.1), 0.36 (95% CI, 0.27–0.48), 39.7 (95% CI, 21.4–73.6), and 0.94 (95% CI, 0.85–0.99), respectively, whereas the corresponding numbers for detection of ECR were 0.95 (95% CI, 0.91–0.98), 0.91 (95% CI, 0.86–0.94), 8.8 (95% CI, 6.0–12.7), 0.08 (95% CI, 0.05–0.15), 171.7 (95% CI, 67.9–434.3), and 0.97 (95% CI, 0.95–0.98), respectively. The overall diagnostic accuracy (Q^* index) in LNM and ECR were 0.88 and 0.93, respectively. **Conclusion:** ^{18}F -FDG PET/CT has an excellent diagnostic performance for detecting LNM preoperatively and disease recurrence postoperatively in endometrial cancer patients.

Key Words: endometrial cancer; FDG; PET and CT

J Nucl Med 2016; 57:879–885

DOI: 10.2967/jnumed.115.170597

Endometrial cancer is the most common gynecologic malignancy in the developed countries (1). The prognosis is traditionally determined by clinical and histopathologic factors—that is, age, histologic type, grade, and stage of disease including assessment of cervical invasion, depth of myometrial invasion, lymph node spread, and distant metastases (2–4). The 5-y overall survival rate is generally favorable, around 80%. However, pelvic lymph node metastases (LNM) represents the most common site for extrauterine disease at primary treatment, and the 5-y survival rate is around 50% for this patient subgroup (5).

Currently, the final staging of endometrial cancer is based on histopathologic findings at primary surgery, which includes abdominal exploration, peritoneal cytology washing from the pelvis, hysterectomy, bilateral salpingo-oophorectomy, and lymphadenectomy in selected patients presumed to have a high risk of disease spread (6–8). Routine systemic pelvic lymphadenectomy for early-stage endometrial cancer disease, although not well defined as a surgical technique, improves detection of LNM, but the procedure showed no survival benefit in 2 randomized clinical trials (9,10). Valid preoperative identification of patients with LNM who may benefit from lymphadenectomy is thus essential if futile surgical staging and unnecessary postoperative staging-related complications are to be minimized. If a noninvasive imaging technique could accurately preclude LNM preoperatively, lymphadenectomy procedures, currently with unproven clinical benefit for survival, could be safely circumvented. Hence, the development of noninvasive imaging methods enabling more accurate preoperative staging of endometrial cancer may facilitate better-tailored surgical decision making based on the selection of appropriate risk groups for LNM.

Conventional diagnostic imaging by transvaginal ultrasound, MRI, and CT provide detailed anatomic information, whereas functional or metabolic tumor characteristics may remain undetected. However, vigorous debate has challenged the use of anatomic assessments solely relying on tumor morphologic information, not taking into account functional tumor characteristics that may prove highly relevant for the clinical phenotype (11–13). In this regard, to better understand the tumor microenvironment, metabolic PET tracers such as ^{18}F -FDG, in combination with CT, can overcome the limitations of morphologic imaging alone, because functional changes possible to detect by ^{18}F -FDG PET/CT often precede morphologic changes detectable by conventional PET MRI or CT (14,15).

Received Dec. 6, 2015; revision accepted Dec. 30, 2015.

For correspondence or reprints contact: Vikram Rao Bollineni, Department of Obstetrics and Gynecology, Haukeland University Hospital, Center for Cancer Biomarkers, Department of Clinical Science, University of Bergen, Bergen, Norway.

E-mail: vikram.bollineni@uib.no

Published online Jan. 28, 2016.

COPYRIGHT © 2016 by the Society of Nuclear Medicine and Molecular Imaging, Inc.

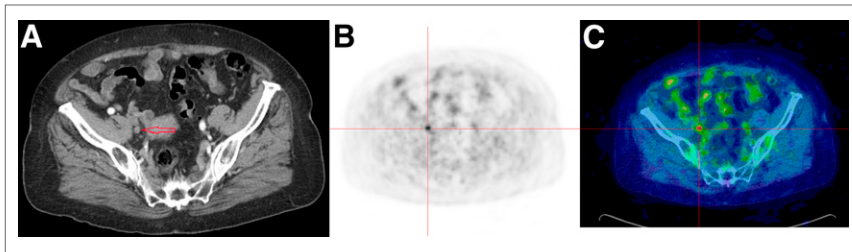


FIGURE 1. An 87-y-old patient with FIGO stage III C1 and endometrioid grade 2. (A) Contrast-enhanced CT depicting nonenlarged lymph node (arrow) close to right internal iliac vessels. (B) PET scan depicting ^{18}F -FDG uptake (red cross hair lines) in region of same pelvic lymph node. (C) Coregistered ^{18}F -FDG PET/CT scan depicting increased ^{18}F -FDG PET uptake (red cross hair lines) corresponding to histologically confirmed metastatic internal iliac lymph node.

^{18}F -FDG PET/CT has long been used successfully for evaluation of several malignancies including endometrial cancer (Fig. 1) (15,16). On the basis of a systematic review, here we report diagnostic indices of ^{18}F -FDG PET/CT for the preoperative prediction of LNM and for the detection of disease recurrence after surgery with curative intent in endometrial cancer patients.

MATERIALS AND METHODS

Search Strategy

Because the study was not conducted on patients, no informed consent or ethical committee approval was needed. To identify all relevant publications, we performed systematic searches in the bibliographic databases PUBMED.com from inception to August 17, 2015. Search terms included controlled terms from Mesh in PUBMED.com using the following: ‘FDG PET’ in combination with ‘Endometrial neoplasms’. The references of the identified articles were also searched for relevant publications.

Selection Process

One physician and 1 statistician reviewed each published article independently to determine the eligibility for inclusion in the meta-

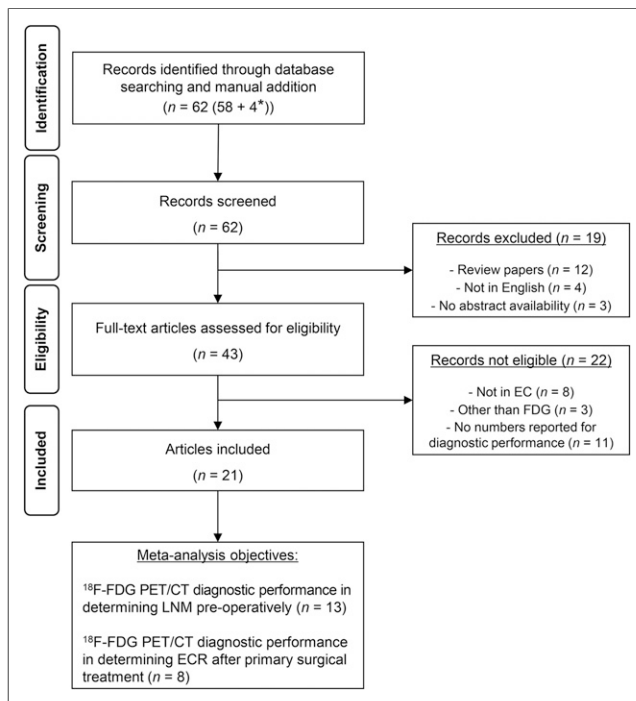


FIGURE 2. Flow chart of selection process of eligible studies.

analysis and to extract information regarding clinical patient data and PET/CT characteristics. From the studies selected, data on first author, year of publication, number of patients included, study design (prospective or retrospective), patient age (mean/median), results from surgical International Federation of Gynecology and Obstetrics (FIGO) staging, percentage with nodal metastases, percentage with endometrioid subtype, ^{18}F -FDG PET/CT technical characteristics, and numbers for diagnostic performance of ^{18}F -FDG PET/CT (i.e., true-negatives, false-negatives, true-positives, false-positives, positive predictive value, and negative predictive value)

were extracted and recorded. Any differences were resolved by consensus.

PET/CT studies that met the following criteria were included: first, studies that reported the diagnostic performance of ^{18}F -FDG PET/CT in detecting LNM preoperatively or disease recurrence in endometrial cancer patients after primary surgery; second, clinical studies that included at least 10 patients; third, studies that applied ^{18}F -FDG as a tracer on a dedicated device and were published after peer review. Studies on animals or in vitro studies, studies not available in full text or not written in English, and nonoriginal articles (e.g., reviews, editorials, letters, legal cases, interviews, case reports) were not evaluated systematically in this review.

Statistical Analysis

We performed standard methods recommended for meta-analysis of diagnostic test evaluations (17). Statistical analyses were performed using Meta-DiSc 1.4 software (developed by the unit of Clinical Biostatistics team of the Ramon y Cajal Hospital in Madrid, Spain) (18). We computed pooled measures for the following test indices of each study: sensitivity, specificity, positive likelihood ratio (PLR), negative likelihood ratio (NLR), and diagnostic odds ratio (DOR). Further, the summary receiver-operating-characteristics curve (SROC) was constructed, and the area under the SROC curve (AUC) was determined.

A random-effects model was used for statistical pooling of the data. Pooled data were presented with 95% confidence intervals (CIs). The CI for diagnostic indices are exact—that is, they are based on the binomial distribution and hence are asymmetric. The I-square index was used to test for heterogeneity between studies. The AUC was calculated to measure the overall diagnostic performance of ^{18}F -FDG PET/CT in detecting the LNM and endometrial cancer recurrence (ECR). The sensitivity and specificity for the single threshold identified for each study were used to plot the SROC curve along with Q^* index representing an overall measure of the test’s discriminatory power.

RESULTS

Literature Search Results

The literature search yielded 58 references in PUBMED.com. In addition, 3 relevant recent articles on LNM in endometrial cancer and 1 in ECR that we were aware of were included in our database. The flow chart of the search and selection process is presented in Figure 2. Of a total of 62 articles, only 21 were eligible according to the criteria. Tables 1 and 2 summarize details for the included endometrial cancer studies of LNM and ECR by ^{18}F -FDG PET/CT imaging, respectively.

Preoperative Detection of LNM

In our meta-analysis of LNM, 13 studies were included, comprising a total of 861 endometrial cancer patients. The overall

TABLE 1
Summary of Clinical ¹⁸F-FDG PET/CT Studies on LNM in Endometrial Cancer

Type	Patients (n)	Median age (y)	FIGO*	Purpose	Results	Conclusions
P (27)	236	65	IA-IVB (79%)	Evaluate value of SUV _{max} as tool in preoperative work-up of EC, with focus on MI, CI, FIGO, risk stratification, LNM.	PB sens 75%, spec 93%, PPV 60%, NPV 96%, and acc 90% for LNM. SUV _{max} significantly higher in high-risk EC (high FIGO, MI > 50%, CI vs. no CI, LNM vs. no LNM) than low-risk EC.	Promise for distinguishing high- from low-risk EC and, indirectly, for determining aggressiveness.
P (25)	129	67	IA-IVB (76%)	Determine value of preoperative EC staging and relate imaging parameters to tumor characteristics.	Sens 85%, spec 92%, PPV 65%, NPV 98%, and acc 91% for LNM. SUV _{max} , MTV, and TLG were significantly related to deep MI, LNM, and high histologic grade.	Preoperative value for LNM detection; parameters relate to tumor aggression and help identify high-risk EC.
NA (37)	106	61	IA-IVB (88%)	Determine clinical value for pelvic LNM detection in EC.	PB sens 97%, spec 69%, PPV 75%, NPV 96%, and acc 93% for LNM.	Preoperative value for LNM detection in EC.
P (28)	76	63	IA-IVB (87%)	Evaluate parameter as predictor of LNM in EC.	Positive correlation: LNM and SUV _{max} ($P = 0.003$), MTV ($P = 0.007$), and TLG ($P = 0.003$) of PT. PB sens 79%, spec 98%, acc 95%, PPV 92%, and NPV 95% for LNM.	Potential for predicting LNM in EC patients.
R (32)	53	58	IA-IVB (83%)	Determine acc for LNM in EC.	PB sens 50%, spec 94%, PPV 40%, and NPV 96% for LNM.	High spec/NPV usefulness to select patients who may benefit from lymphadenectomy, minimizing surgical complication.
P (33)	46	56	I-IV (63%)	Determine clinical value for pelvic LNM detection in EC.	Sens 50% and spec 92% for detecting pelvic LNM.	Possible acc increase for LNM detection and reduction of false-positive results in preoperative EC patients.
P (22)	40	56	IA-IIIC (92%)	Evaluate acc for LNM detection in EC.	PB sens 50%, spec 86%, and acc 77% for LNM.	Preoperative value for LNM detection.
P (34)	37	61	IA-IVB (83%)	Determine acc for LNM detection in high-risk EC.	PB sens 78%, spec 100%, NPV 100%, PPV 93%, and acc 94% for LNM.	Accurate procedure for preoperative evaluation of pelvic LNM.
R (35)	33	54	NA (94%)	Evaluate diagnostic sens vs. MRI alone in EC patients and correlation between SUV _{max} and clinicopathologic tumor characteristics.	PB sens 80%, spec 96%, and acc 94% for LNM. Positive correlation between SUV _{max} of PT and lesion size ($P = 0.001$).	Diagnostic sens superior to CT or MRI alone in PT and LN detection.
R (36)	30	62	IA-IIIC (90%)	Evaluate acc of ¹⁸ F-FDG PET/CT and PET/MR in assessment of LNM in EC.	PB sens 100%, spec 96%, and acc 97% for detecting LNM for both PET/MR and PET/CT. However, acc of PET/MR is superior to PET/CT in tumor staging (80% vs. 60%, $P < 0.04$).	Integrated ¹⁸ F-FDG PET/MR is superior to PET or MRI alone. Value in PT detection and nodal staging in EC patients.
R (37)	30	56	IA-IVB (63%)	Evaluate clinical usefulness for preoperative evaluation in EC.	PB sens 100% and spec 100% for detecting LNM.	Demonstration of high preoperative diagnostic performance in EC patients.
R (38)	26	61	IA-IVB (53%)	Determine clinical value for primary staging of high-risk EC patients.	PB sens 57%, spec 100%, PPV 100%, NPV 86%, and acc 88% for revealing LN involvement. For detecting distant metastases sens was 100%, spec 96%, PPV 87%, NPV 100%, and acc 97%.	Value in distant metastases detection in abdomen and extraabdominal regions with high diagnostic performance.
P (39)	19	66	IA-IVB (75%)	Determine sens and spec of preoperative ¹⁸ F-FDG PET in detecting LNM in EC.	PB sens 67% and spec 94% for preoperative prediction of LNM disease in EC.	Preoperative ¹⁸ F-FDG PET may be helpful with safe omission of lymphadenectomy in selected patients.

*FIGO stage followed by percentage endometrioid.

P = prospective; EC = endometrial cancer; MI = myometrial invasion; CI = cervical invasion; PB = patient-based; sens = sensitivity; spec = specificity; PPV = positive predictive value; NPV = negative predictive value; acc = accuracy; MTV = metabolic tumor volume; TLG = tumor lesion glycolysis; NA = not available; R = retrospective; LN = lymph node.

TABLE 2
Summary of Clinical ¹⁸F-FDG PET/CT Studies on ECR in Endometrial Cancer

Type	Patients (n)	Median age (y)	FIGO*	Purpose	Results	Conclusions
R (40)	127	52	IA-IVB (86%)	Determine feasibility for posttherapy surveillance in EC patients who showed NED.	Sens 100%, spec 88%, PPV 59%, and NPV 100% for detecting ECR in EC showing NED.	Effective detection of early recurrences in patients with EC showing NED after primary treatment.
R (41)	101	56	IA-IVB (NA)	Evaluate acc for identification of suspected ECR.	Sens 89%, spec 93%, PPV 94%, NPV 88%, and acc 91%.	High diagnostic yield in detecting recurrent EC.
R (42)	31	61	IA-IVB (NA)	Determine value of posttreatment imaging compared with CI and CA-125 in EC patients.	Overall sens, spec, and acc were 100%, 96%, and 97%, respectively, whereas for CI corresponding values were 46%, 87%, and 74%, respectively.	Posttreatment imaging is a more clinically useful modality than CI in evaluation of suspected ECR.
R (43)	31	53	IA-IVB (88.5%)	Evaluate acc for identification of suspected ECR after treatment.	Overall PB sens 100%, spec 84%, PPV 100%, NPV 97%, and acc 92%. Significantly better PFS observed in patients with negative PET/CT result than in those with positive PET/CT scan ($P < 0.015$).	Demonstrated high diagnostic indices in detecting ECR.
R (44)	30	59	IA-IVB (90%)	Evaluate diagnostic acc, compared with PET alone, in diagnosis of suspected ECR.	Overall PB sens, spec, and acc were 93%, 93%, and 93% in detecting ECR, whereas with PET alone corresponding values were 80%, 80%, and 80%, respectively.	Diagnostic acc was superior to PET alone in detecting localization of sites of recurrence during follow-up.
R (45)	24	52	IA-IVB (81%)	Evaluate clinical impact of posttreatment imaging in surveillance of EC patients.	Overall sens 100%, spec 94%, PPV 96%, NPV 95%, and acc 100% of PET/CT imaging in detecting recurrence.	Highly effective in determining true recurrence in patients with suspected recurrence. Carries high impact on clinical decisions in most patients.
R (46)	21	62	IA-IVB (67%)	Clinical utility of postoperative ¹⁸ F-FDG PET in ECR.	Sens, spec, and acc were 100%, 88%, and 93%, whereas sens, spec, and acc of combined CI (CT/MRI) were 84%, 85%, and 85%.	Superior to combined CI (CT/MRI) in detecting tumor recurrence.
P (47)	13	59	IB-IIIB (NA)	Determine diagnostic acc in detection of ECR.	Overall sens 93%, spec 100%, PPV 100%, NPV 92%, and acc 90% in detecting ECR.	Carries high diagnostic acc in determining ECR.

*FIGO stage followed by percentage endometrioid.

R = retrospective; EC = endometrial cancer; NED = no evidence of disease; sens = sensitivity; spec = specificity; PPV = positive predictive value; NPV = negative predictive value; NA = not available; acc = accuracy; CI = conventional imaging; PB = patient-based; PFS = progression-free survival; P = prospective.

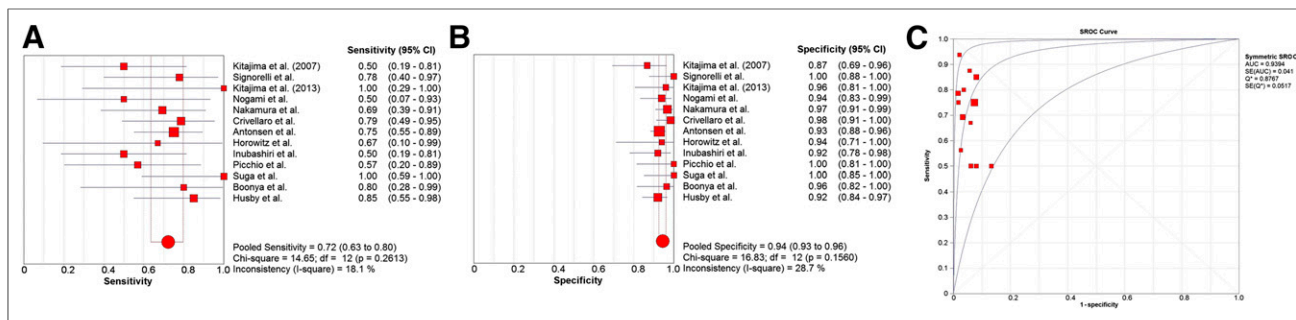


FIGURE 3. LNM: forest plot of sensitivity pooling (A); forest plot of specificity pooling (B); SROC curve (C). Individual study estimates of sensitivity and specificity of ^{18}F -FDG PET/CT for identifying LNM in endometrial cancer. In detection of LNM, ^{18}F -FDG PET/CT has moderate sensitivity of 0.72, high specificity of 0.94, and AUC of 0.94, demonstrating good diagnostic performance.

pooled diagnostic indices of preoperative ^{18}F -FDG PET/CT for detecting LNM are calculated on a patient basis. The pooled sensitivity and specificity values were 0.72 (95% CI, 0.63–0.80) (Fig. 3A) and 0.94 (95% CI, 0.93–0.96) (Fig. 3B), respectively. The pooled PLR was 10.9 (95% CI, 7.9–15.1), the pooled NLR was 0.36 (95% CI, 0.27–0.48), and the DOR was 39.7 (95% CI, 21.4–73.6).

The SROC representing a global summary score for the test performance yielded an AUC of 0.94 and a Q^* value of 0.88 (Fig. 3C), indicating a relatively high level of overall accuracy.

Detection of ECR

In the present meta-analysis for ECR, 8 studies comprising 378 patients have been included. The pooled sensitivity was 0.95 (95% CI, 0.91–0.98) (Fig. 4A), and the pooled specificity was 0.91 (95% CI, 0.86–0.94) (Fig. 4B). The pooled PLR was 8.8 (95% CI, 6.0–12.7), NLR was 0.08 (95% CI, 0.05–0.15), and DOR was 171.7 (95% CI, 67.9–434.3). The SROC curve for the ^{18}F -FDG PET/CT in the detection of ECR yielded an AUC and Q^* values of 0.97 and 0.93 (Fig. 4C), respectively, suggesting that the level of overall accuracy was high.

DISCUSSION

Lymphadenectomy is currently commonly applied for lymph node staging in endometrial carcinoma as part of the surgical FIGO staging systems. However, noninvasive accurate lymph node staging in endometrial cancer by preoperative imaging seems advantageous compared with the more invasive nature of surgical lymph node staging, also with an unproven survival benefit from the procedure (9,10). Similar to other tumors, endometrial cancer has an increased tumor glucose metabolism and glycolysis rate, which makes it suitable for ^{18}F -FDG PET/CT imaging (19–21). The present meta-analysis yields high diagnostic performances of ^{18}F -FDG PET/CT for diagnosing LNM preoperatively. High diagnostic accuracy was also demonstrated for the procedure detecting ECR after primary surgical treatment. A high diagnostic performance clearly supports a role for ^{18}F -FDG PET/CT to enable more accurately tailored primary surgical endometrial cancer treatment and subsequent patient care.

The pooled sensitivity for preoperative detection of LNM by ^{18}F -FDG PET/CT in this meta-analysis was 72%, highlighting that as much as about one fourth of the metastatic lymph nodes are still missed by ^{18}F -FDG PET/CT. One possible explanation for this finding is that ^{18}F -FDG avidity relies on the presence of a sufficient number of malignant cells exhibiting increased glucose

metabolism. Furthermore, the spatial resolution of PET/CT is not good enough to reliably detect small tumors or micrometastatic disease. There is no documented threshold for lymph node size allowing PET/CT to correctly identify metastatic lymph nodes in endometrial cancer, although 1 study reported node-based sensitivities of 17% (4/24) for nodes of 4 mm or smaller, 67% (14/24) for nodes measuring 5–9 mm, and 93% (14/15) for nodes of 10 mm or larger (22). Similar figures with node-based sensitivities of 13%, 67%, and 100% in metastatic lymph nodes of 4 mm or smaller, 5–9 mm, and of 10 mm or larger, respectively, in endometrial cancer were reported in another study (23). It should, however, be kept in mind that although this meta-analysis found the overall sensitivity of ^{18}F -FDG PET/CT to be moderate for the detection of LNM in endometrial cancer, it compares favorably with the reported sensitivities for LNM detection by conventional MRI and CT (24).

A high pooled specificity of 0.94 for metastatic lymph node detection by ^{18}F -FDG PET/CT was found in this study, and it may be argued that this specificity is sufficiently high to safely omit a major surgical procedure in patients with low risk based on results from preoperative endometrial biopsy and preoperative imaging, reducing operative and postsurgical complications and costs (25). Furthermore, the present meta-analysis, showed that ^{18}F -FDG PET/CT has a high PLR (10.9), pinpointing that ^{18}F -FDG PET/CT findings suggesting metastatic lymph nodes are likely to be confirmed at surgical staging. The high diagnostic performance of ^{18}F -FDG PET/CT for detecting endometrial cancer LNM is also justified by a high AUC of 0.94 in this meta-analysis. Interestingly, Kang et al. (26) reported almost identical figures for the diagnostic performance of ^{18}F -FDG PET/CT for detecting LNM in cervical cancer, with a reported sensitivity of 0.73 (95% CI, 0.53–0.87) and specificity of 0.93 (95% CI, 0.86–0.97). Thus, ^{18}F -FDG PET/CT seems to be equally feasible in endometrial and cervical cancer for lymph node staging, and ^{18}F -FDG PET/CT may be particularly justified in endometrial and cervical cancer patients with high risk for disease spread, to identify metastatic lymph nodes preoperatively.

Several recent studies in endometrial cancer have demonstrated that preoperative primary tumor metabolic parameters have been associated with the presence of LNM. In a prospective study, Antonsen et al. (27) found a significantly higher SUV_{max} in patients with LNM than in those with no LNM ($P = 0.04$). Additionally, they found that SUV_{max} was significantly higher in patients with high FIGO stage, myometrial invasion, and cervical invasion. Furthermore, Crivellaro et al. (28) found strong

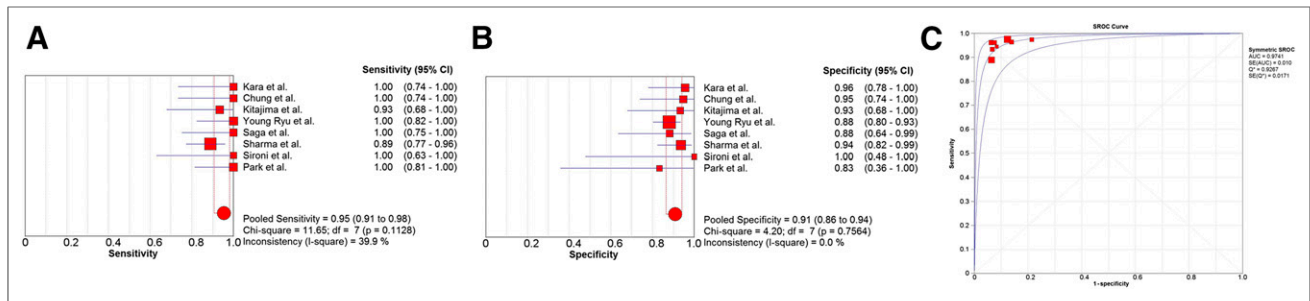


FIGURE 4. ECR: forest plot of sensitivity pooling (A); forest plot of specificity pooling (B); SROC curve (C). Individual study estimates of sensitivity and specificity of ^{18}F -FDG PET/CT for identifying disease recurrence in endometrial cancer. In detection of ECR, ^{18}F -FDG PET/CT has high sensitivity of 0.95, high specificity of 0.91, and AUC of 0.97, demonstrating excellent diagnostic performance.

association between the presence of LNM and metabolic tumor volume in endometrial cancer. Recently, we demonstrated that the preoperative metabolic tumor volume cutoff value of 30 mL yielded sensitivity and specificity of 85% and 76% for LNM, respectively, suggesting that the metabolic tumor volume is a promising marker for LNM (25). In this regard, preoperative ^{18}F -FDG PET/CT imaging of primary endometrial carcinomas may provide an adequate tool for prognostication and LNM detection that facilitate personalized patient care. However, additional prospective studies are required to define optimal cutoff values for predicting LNM based on ^{18}F -FDG PET/CT metabolic parameters. Earlier studies describe measures for SUVs from a single region of interest, which does not represent the overall tumor profile. Therefore, advanced techniques such as the whole tumor voxel-by-voxel analysis may be a preferable approach to reduce operator dependence and capture more relevant and comprehensive measures for tumor microenvironment and heterogeneity.

The pooled sensitivity and specificity of ^{18}F -FDG PET/CT for the detection ECR were 0.95 and 0.91, respectively, with an AUC in ROC analysis of 0.97 (95% CI, 0.95–0.99), all supporting a high level of overall diagnostic accuracy. Again, similar ^{18}F -FDG PET/CT diagnostic performance indices were reported for detecting recurrent uterine cervical carcinomas, with a reported pooled sensitivity, specificity, and AUC of 0.92 (95% CI, 0.91–0.94), 0.84 (95% CI, 0.74–0.91), and 0.95, respectively (29). Thus, ^{18}F -FDG PET/CT seems to perform equally well in the diagnosis of endometrial and cervical cancer recurrences, supporting a promising role for ^{18}F -FDG PET/CT as a diagnostic tool for patients with suspected recurrence.

The findings in this study regarding ^{18}F -FDG PET/CT and ECR must, however, be interpreted with care, considering that the studies report lack of histologic confirmation of all putative metastases based on ^{18}F -FDG PET/CT, and they report variable follow-up of the cases considered nonmetastatic based on ^{18}F -FDG PET/CT. Thus, some of the cases classified as correctly staged for ECR by ^{18}F -FDG PET/CT may have been erroneously classified. This limitation shared by most published studies, including the studies on cervical cancer recurrence, is, however, hard to circumvent, because it seems unethical to perform biopsies of all suspected metastatic lesions in patients due to risk of complications. Furthermore, frequent ^{18}F -FDG PET/CT follow-up scans are very expensive and imply unwanted radiation exposure for the patients.

Because both LNM and ECR studies exhibit interstudy heterogeneity, the SROC curve should be asymmetric (Supple-

mental Fig. 1 [supplemental materials are available at <http://jnm.snmjournals.org>] for both symmetric and asymmetric SROCs). Because all possible curves with the same true odds ratio and different degrees of heterogeneity would pass through the same point on the antidiagonal, the heterogeneity does not affect the Q^* estimate but rather the shape of the curve and its standard errors. Walter et al. (30) noted that the AUC standard errors calculated under the homogeneity assumption provide a good approximation for heterogeneous studies. The approximation may be poor for extremely high DOR values (higher than 20), as is the case in both meta-analyses presented here (37.5 and 171.7 for LNM and recurrence, respectively). However, the bias in the homogeneity-based standard errors is mostly positive, and hence conservative, that is, can be overestimated, but rarely underestimated. Supplemental Figure 1 illustrates that the CIs of the asymmetric SROC are much narrower than those of the symmetric SROC, whereas the difference between the AUC estimates is negligible.

This meta-analysis has several limitations. First, positive result publication bias is a major concern, because nonsignificant or unfavorable study results tend to be discarded. However, we evaluated publication bias in our meta-analysis using funnel plot asymmetry, finding the funnel plots to be symmetric for both sensitivity and specificity pooling, implying no large bias in our study. Second, the current meta-analysis did not include region-by-region or node-by-node evaluation because this was not reported in most studies; however, this could have provided additional information. Third, not all included studies had a prospective study design. Fourth, the gold standard for confirmation of LNM or ECR, being histopathologic examination from biopsies, was not obtained from all the lesions reported in the studies. However, clinical follow-up data and results from renewed diagnostic imaging were recorded, and clinically putative lymph nodes metastases or ECR was used as a gold standard when histologic confirmation was missing.

CONCLUSION

Overall, ^{18}F -FDG PET/CT demonstrated a high diagnostic performance in identifying LNM preoperatively and in detecting recurrence after endometrial carcinoma surgery with curative intent. Larger prospective studies are needed to validate this high diagnostic performance of ^{18}F -FDG PET/CT in endometrial cancer and further assess patient subgroups with particular clinical benefit from applying this advanced imaging procedure.

DISCLOSURE

The costs of publication of this article were defrayed in part by the payment of page charges. Therefore, and solely to indicate this fact, this article is hereby marked “advertisement” in accordance with 18 USC section 1734. This study was supported by funding from the Norwegian Cancer Society. No other potential conflict of interest relevant to this article was reported.

REFERENCES

1. Amant F, Moerman P, Neven P, Timmerman D, Van Limbergen E, Vergote I. Endometrial cancer. *Lancet*. 2005;366:491–505.
2. Dewdney SB, Jiao Z, Roma AA, et al. The prognostic significance of lymphovascular space invasion in laparoscopic versus abdominal hysterectomy for endometrioid endometrial cancer. *Eur J Gynaecol Oncol*. 2014;35:7–10.
3. Larson DM, Connor GP, Broste SK, Krawisz BR, Johnson KK. Prognostic significance of gross myometrial invasion with endometrial cancer. *Obstet Gynecol*. 1996;88:394–398.
4. Uharcek P. Prognostic factors in endometrial carcinoma. *J Obstet Gynaecol Res*. 2008;34:776–783.
5. Lewin SN, Herzog TJ, Barrena Medel NI, et al. Comparative performance of the 2009 international federation of gynecology and obstetrics’ staging system for uterine corpus cancer. *Obstet Gynecol*. 2010;116:1141–1149.
6. Boronow RC, Morrow CP, Creasman WT, et al. Surgical staging in endometrial cancer: clinical-pathologic findings of a prospective study. *Obstet Gynecol*. 1984;63:825–832.
7. Pecorelli S. Revised FIGO staging for carcinoma of the vulva, cervix, and endometrium. *Int J Gynaecol Obstet*. 2009;105:103–104.
8. Rungruang B, Olawaiye AB. Comprehensive surgical staging for endometrial cancer. *Rev Obstet Gynecol*. 2012;5:28–34.
9. Benedetti Panici P, Basile S, Maneschi F, et al. Systematic pelvic lymphadenectomy vs. no lymphadenectomy in early-stage endometrial carcinoma: randomized clinical trial. *J Natl Cancer Inst*. 2008;100:1707–1716.
10. Kitchener H, Swart AM, Qian Q, Amos C, Parmar MK. Efficacy of systematic pelvic lymphadenectomy in endometrial cancer (MRC ASTEC trial): a randomised study. *Lancet*. 2009;373:125–136.
11. Faria SC, Sagebiel T, Devine C, Lal C, Balachandran A, Bhosale P. Imaging in endometrial carcinoma. *Indian J Radiol Imaging*. 2015;25:137–147.
12. Ben-Shachar I, Vitellas KM, Cohn DE. The role of MRI in the conservative management of endometrial cancer. *Gynecol Oncol*. 2004;93:233–237.
13. Connor JP, Andrews JI, Anderson B, Buller RE. Computed tomography in endometrial carcinoma. *Obstet Gynecol*. 2000;95:692–696.
14. Amit A, Schink J, Reiss A, Lowenstein L. PET/CT in gynecologic cancer: present applications and future prospects—a clinician’s perspective. *Obstet Gynecol Clin North Am*. 2011;38:1–21.
15. Tsujikawa T, Tsuchida T, Yoshida Y, et al. Role of PET/CT in gynecological tumors based on the revised FIGO staging classification. *Clin Nucl Med*. 2011;36: e114–118.
16. Nakamura K, Kodama J, Okumura Y, et al. The SUVmax of ¹⁸F-FDG PET correlates with histological grade in endometrial cancer. *Int J Gynecol Cancer*. 2010;20:110–115.
17. Devillé WL, Buntinx F, Bouter LM, et al. Conducting systematic reviews of diagnostic studies: didactic guidelines. *BMC Med Res Methodol*. 2002;2:9.
18. Zamora J, Abraira V, Muriel A, Khan K, Coomarasamy A. Meta-DiSc: a software for meta-analysis of test accuracy data. *BMC Med Res Methodol*. 2006;6:31.
19. Kitajima K, Kita M, Suzuki K, Senda M, Nakamoto Y, Sugimura K. Prognostic significance of SUVmax (maximum standardized uptake value) measured by [¹⁸F] FDG PET/CT in endometrial cancer. *Eur J Nucl Med Mol Imaging*. 2012;39: 840–845.
20. Walentowicz-Sadlecka M, Malkowski B, Walentowicz P, et al. The preoperative maximum standardized uptake value measured by ¹⁸F-FDG PET/CT as an independent prognostic factor of overall survival in endometrial cancer patients. *Biomed Res Int*. 2014;2014:7.
21. Chung HH, Cheon GJ, Kim HS, Kim JW, Park N-H, Song YS. Preoperative PET/CT standardized FDG uptake values of pelvic lymph nodes as a significant prognostic factor in patients with endometrial cancer. *Eur J Nucl Med Mol Imaging*. 2014;41:1793–1799.
22. Kitajima K, Murakami K, Yamasaki E, et al. Accuracy of ¹⁸F-FDG PET/CT in detecting pelvic and paraaortic lymph node metastasis in patients with endometrial cancer. *AJR*. 2008;190:1652–1658.
23. Kitajima K, Murakami K, Yamasaki E, Kaji Y, Sugimura K. Accuracy of integrated FDG-PET/contrast-enhanced CT in detecting pelvic and paraaortic lymph node metastasis in patients with uterine cancer. *Eur Radiol*. 2009;19:1529–1536.
24. Salvesen HB, Haldorsen IS, Trovik J. Markers for individualised therapy in endometrial carcinoma. *Lancet Oncol*. 2012;13:e353–e361.
25. Husby JA, Reitan BC, Biermann M, et al. Metabolic tumor volume on ¹⁸F-FDG PET/CT improves preoperative identification of high-risk endometrial carcinoma patients. *J Nucl Med*. 2015;56:1191–1198.
26. Kang S, Kim S-K, Chung D-C, et al. Diagnostic value of ¹⁸F-FDG PET for evaluation of paraaortic nodal metastasis in patients with cervical carcinoma: a metaanalysis. *J Nucl Med*. 2010;51:360–367.
27. Antonsen SL, Loft A, Fisker R, et al. SUVmax of 18FDG PET/CT as a predictor of high-risk endometrial cancer patients. *Gynecol Oncol*. 2013;129:298–303.
28. Crivellaro C, Signorelli M, Guerra L, et al. Tailoring systematic lymphadenectomy in high-risk clinical early stage endometrial cancer: the role of ¹⁸F-FDG PET/CT. *Gynecol Oncol*. 2013;130:306–311.
29. Ding XP, Feng LML. Diagnosis of recurrent uterine cervical cancer: PET versus PET/CT—a systematic review and meta-analysis. *Arch Gynecol Obstet*. 2014;290: 741–747.
30. Walter SD. Properties of the summary receiver operating characteristic (SROC) curve for diagnostic test data. *Stat Med*. 2002;21:1237–1256.
31. Nakamura K, Hongo A, Kodama J, Hiramatsu Y. The measurement of SUVmax of the primary tumor is predictive of prognosis for patients with endometrial cancer. *Gynecol Oncol*. 2011;123:82–87.
32. Nogami Y, Banno K, Irie H, et al. The efficacy of preoperative positron emission tomography-computed tomography (PET-CT) for detection of lymph node metastasis in cervical and endometrial cancer: clinical and pathological factors influencing it. *Jpn J Clin Oncol*. 2015;45:26–34.
33. Inubashiri E, Hata K, Kanenishi K, et al. Positron emission tomography with the glucose analog [¹⁸F]-fluoro-2-deoxy-D-glucose for evaluating pelvic lymph node metastasis in uterine corpus cancer: comparison with CT and MRI findings. *J Obstet Gynaecol Res*. 2009;35:26–34.
34. Signorelli M, Guerra L, Buda A, et al. Role of the integrated FDG PET/CT in the surgical management of patients with high risk clinical early stage endometrial cancer: detection of pelvic nodal metastases. *Gynecol Oncol*. 2009;115:231–235.
35. Boonya-ussadorn T, Choi WH, Hyun J, Kim SH, Chung SK, Yoo IR. ¹⁸F-FDG PET/CT findings in endometrial cancer patients: the correlation between SUVmax and clinicopathologic features. *J Med Assoc Thai*. 2014;97(suppl 2): S115–S122.
36. Kitajima K, Suenaga Y, Ueno Y, et al. Value of fusion of PET and MRI for staging of endometrial cancer: comparison with ¹⁸F-FDG contrast-enhanced PET/CT and dynamic contrast-enhanced pelvic MRI. *Eur J Radiol*. 2013;82: 1672–1676.
37. Suga T, Nakamoto Y, Saga T, et al. Clinical value of FDG-PET for preoperative evaluation of endometrial cancer. *Ann Nucl Med*. 2011;25:269–275.
38. Picchio M, Mangili G, Samanes Gajate AM, et al. High-grade endometrial cancer: value of [¹⁸F]FDG PET/CT in preoperative staging. *Nucl Med Commun*. 2010;31:506–512.
39. Horowitz NS, Dehdashti F, Herzog TJ, et al. Prospective evaluation of FDG-PET for detecting pelvic and para-aortic lymph node metastasis in uterine corpus cancer. *Gynecol Oncol*. 2004;95:546–551.
40. Ryu S-Y, Kim K, Kim Y, et al. Detection of recurrence by ¹⁸F-FDG PET in patients with endometrial cancer showing no evidence of disease. *J Korean Med Sci*. 2010;25:1029–1033.
41. Sharma P, Kumar R, Singh H, et al. Carcinoma endometrium: role of 18-FDG PET/CT for detection of suspected recurrence. *Clin Nucl Med*. 2012;37:649–655.
42. Ozcan Kara P, Kara T, Kaya B, Kara Gedik G, Sari O. The value of FDG-PET/CT in the post-treatment evaluation of endometrial carcinoma: a comparison of PET/CT findings with conventional imaging and CA 125 as a tumour marker. *Rev Esp Med Nucl Imagen Mol*. 2012;31:257–260.
43. Chung HH, Kang WJ, Kim JW, et al. The clinical impact of [¹⁸F]FDG PET/CT for the management of recurrent endometrial cancer: correlation with clinical and histological findings. *Eur J Nucl Med Mol Imaging*. 2008;35:1081–1088.
44. Kitajima K, Murakami K, Yamasaki E, et al. Performance of FDG-PET/CT in the diagnosis of recurrent endometrial cancer. *Ann Nucl Med*. 2008;22:103–109.
45. Park J-Y, Kim EN, Kim D-Y, et al. Clinical impact of positron emission tomography or positron emission tomography/computed tomography in the posttherapy surveillance of endometrial carcinoma: evaluation of 88 patients. *Int J Gynecol Cancer*. 2008;18:1332–1338.
46. Saga T, Higashi T, Ishimori T, et al. Clinical value of FDG-PET in the follow up of post-operative patients with endometrial cancer. *Ann Nucl Med*. 2003;17:197–203.
47. Sironi S, Picchio M, Landoni C, et al. Post-therapy surveillance of patients with uterine cancers: value of integrated FDG PET/CT in the detection of recurrence. *Eur J Nucl Med Mol Imaging*. 2007;34:472–479.