15-Year Experience of ^{18}F-FDG PET Imaging in Response Assessment and Restaging After Definitive Treatment of Merkel Cell Carcinoma

Keelan Byrne*[1], Shankar Siva*[1,2], Lori Chait[3], Jason Callahan[4], Mathias Bressel[5], Matthew Seel[6], Michael P. MacManus[1,2], and Rodney J. Hicks[2,4]

[1]Department of Radiation Oncology, Peter MacCallum Cancer Centre, Melbourne, Australia; [2]Sir Peter MacCallum Department of Oncology, The University of Melbourne, Melbourne, Australia; [3]University of Notre Dame, Sydney, Australia; [4]Department of Cancer Imaging, Peter MacCallum Cancer Centre, Melbourne, Australia; [5]Department of Biostatistics and Clinical Trials, Peter MacCallum Cancer Centre, Melbourne, Australia; and [6]Department of Radiation Oncology, Waikato Regional Cancer Centre, Hamilton, New Zealand

The objective of this study was to evaluate the utility of ^{18}F-FDG PET in restaging and response assessment of patients who underwent definitive treatment for Merkel cell carcinoma (MCC). **Methods:** A retrospective review of patients undergoing ^{18}F-FDG PET imaging for MCC between January 1997 and October 2010 at the Peter MacCallum Cancer Centre with follow-up until February 2015 was performed. Data analysis was performed on patients who were treated definitively and underwent post-treatment PET imaging performed either as a restaging scan for ongoing monitoring, suspicion of recurrence, or assessment for suitability of salvage treatment or as response assessment within 1–6 mo of treatment. Management plans were recorded prospectively before ^{18}F-FDG PET imaging and compared with post-imaging management to assess the impact of the study as per our previously defined categories: high if the primary treatment modality or intent was changed and medium if the radiotherapy technique or dose was altered. In total, 62 patients were included in the analysis. Thirty-six patients underwent 53 restaging scans, and 37 patients underwent a response-assessment scan. The median follow-up of patients in the restaging group was 5.3 y (95% confidence interval [CI], 4.6–9.4), and it was 5.7 y (95% CI, 4.3–10.8) in the response-assessment group. **Results:** Restaging ^{18}F-FDG PET scans had a high impact in 24 of 53 cases (45%) and a medium impact in 6 of 53 cases (11%). In the response-assessment group, 24 of 37 patients had a complete metabolic response (CMR). Patients without a CMR had a 15% 1-y overall survival (95% CI, 0.04–0.55). Those with a CMR had an 88% 2-y overall survival (95% CI, 0.75–1.00) and a 68% 5-y overall survival (95% CI, 0.49–0.95). The presence of a CMR ($P < 0.001$) and nodal involvement ($P = 0.016$) were statistically significant prognostic factors for overall survival. **Conclusion:** ^{18}F-FDG PET imaging had a high impact on restaging after definitive treatment in patients with MCC. Metabolic response was significantly associated with overall survival. ^{18}F-FDG PET may play an important role in ongoing post-treatment management of MCC.

Key Words: Merkel; ^{18}F-FDG PET; response; post-treatment; salvage

J Nucl Med 2015; 56:1328–1333
DOI: 10.2967/jnumed.115.158261

Merkel cell carcinoma (MCC) is a rare neuroendocrine skin carcinoma with an aggressive nature (*1*), which was first described in 1972 (*2*). Although it is still considered a rare disease, incidence rates have increased 3-fold between 1986 and 2001 in the United States (*3*). MCC predominantly occurs in the Caucasian population and affects elderly patients with a mean age of 75 y at diagnosis (*4*). MCC most commonly presents in ultraviolet-exposed areas of skin, including the head and neck, upper limb, lower limb, and trunk areas (*4*). There is also increasing evidence of a pathogenic association with Merkel polyomavirus, which has been detected in up to 100% of MCC specimens analyzed with advanced techniques (*5*). In Australia, there is, however, a lower incidence of viral positivity in tumors associated with markers of chronic sun damage (*6*).

PET using the radiopharmaceutical ^{18}F-FDG is a functional imaging technique that provides in vivo measurements of metabolic activity in tissues, which gives it the ability to detect and quantify physiologic and biologic processes in the body, particularly in cancer cells. ^{18}F-FDG uptake is high in many cancers, including MCC, compared with adjacent normal tissues, allowing tumors to be imaged with high sensitivity and specificity. As the clinical role of PET has continued to evolve, there has been increasing evidence reporting a strong correlation with metabolic response and prognosis after chemoradiation in malignancy. Our institution has previously reported the powerful prognostic stratification achieved by ^{18}F-FDG PET metabolic response across a range of cancer types (*7–12*).

The evidence regarding the utility of ^{18}F-FDG PET imaging in MCC is quite limited given the rarity of the disease, but a recent meta-analysis and systematic review of the diagnostic performance of ^{18}F-FDG PET in patients with MCC demonstrated both high sensitivity and high specificity (*13*). There are also a lack of data to guide optimal management and post-treatment assessment for MCC. An overall 5-y survival rate of about 60% for all stages of MCC combined has been reported (*3*), and our institution has reported an estimated 45% 5-y rate in patients with stage I–III

Received Apr. 2, 2015; revision accepted Jul. 6, 2015.
For correspondence or reprints contact: Shankar Siva, Peter MacCallum Cancer Centre, Locked Bag 1, A'Beckett St., East Melbourne 3002, Australia.
E-mail: shankar.siva@petermac.org
*Contributed equally to this work as primary authors.
Published online Jul. 9, 2015.

MCC (*14*). Cases of successful salvage have been reported in studies in which patients had locoregional recurrent disease and received multimodality treatment (*15,16*).

The aim of this study was to evaluate the impact of follow-up ^{18}F-FDG PET on ongoing management after definitive treatment of MCC, including identifying patients who are suitable for salvage treatment, and also assessing its prognostic utility in response assessment.

MATERIALS AND METHODS

This study was an independent review board–approved assessment of all patients treated at our institution between January 1997 and October 2010 with a histologic diagnosis of MCC and who underwent follow-up ^{18}F-FDG PET imaging performed after definitive treatment of the primary and any involved nodal basin. The requirement to obtain informed consent was waived by the independent review board. Clinical outcome data were collected until February 2015. The study inclusion criteria required that patients have a histologic diagnosis of MCC and that the follow-up ^{18}F-FDG PET imaging was performed 1 mo or more from completion of primary management. Response-assessment scans were obtained between 1 and 6 mo after definitive treatment of known local or regional disease, with the purpose of evaluating the efficacy of treatment. Restaging scans were obtained more than 7 mo after definitive treatment for either ongoing surveillance, for suspicion of recurrence, or for an assessment of suitability for salvage treatment of confirmed recurrence. Management plans before ^{18}F-FDG PET imaging were collected prospectively and compared with the post-imaging management plans.

PET scans were obtained approximately 1 h after intravenous injection of ^{18}F-FDG. Patients fasted for at least 4 h before imaging. A variety of PET scanners has been used at our institution, which changed with evolving technology. A stand-alone PET scanner (Quest; GE Healthcare) was used until 2001, when hybrid PET/CT scanners were introduced and subsequently used (Discovery LS, Discovery STE, and Discovery 690 [GE Healthcare] and Biograph-64 with TruV [Siemens]). The administered activity of ^{18}F-FDG for patients scanned on the PET scanner was 1.6 MBq/kg, and correction for attenuation was performed with a ^{137}Cs transmission scan using our previously described protocol (*17*). The administered activity for patients scanned on the Discovery LS, STE, 690, and Biograph was 4.8, 4.2, 3.6, and 3.6 MBq/kg, respectively. On all 4 PET/CT scanners, the low-dose CT component of the scan was used for attenuation correction.

Whenever feasible, repeated scans for the same patient used the same scanner. Patients were staged according to guidelines of the American Joint Committee on Cancer (*18*). All clinical parameters were collected retrospectively apart from management plans, which were collected prospectively on the PET scan request. Experienced nuclear medicine specialists reviewed and reported the PET or PET/CT scans. The impact of PET was assessed according to previously published institutional criteria (*11*). A high-impact result was defined as a change of treatment plan (e.g., observation to further treatment) or a change of intent (e.g., curative to palliative). A medium-impact result was defined as no change in the treatment modality but alteration of the radiotherapy planning technique or dose. A low-impact result was defined as no change in treatment modality, technique, or intent. Metabolic response was also scored according to previously published criteria (*11,12*). Pre- and post-treatment ^{18}F-FDG PET scans with attenuation correction were calibrated for analysis of standardized uptake values. Images were also visually coregistered using software supplied with the scanner and examined for response at sites of known disease and for evidence of progression at distant sites. Using a visual assessment and standardized display to provide a consistent intensity of background soft-tissue activity, we scored ^{18}F-FDG PET scans for response. The results were classified into complete metabolic response, partial response, no response, or progressive disease. Scans were interpreted as positive if focal areas of increased ^{18}F-FDG PET uptake were detected for which no physiologic or clinically evident non-neoplastic cause could reasonably explain the increased uptake. A complete metabolic response indicated that there was no detectable residual tumor uptake of ^{18}F-FDG PET or new sites of disease.

There was a total of 102 patients who underwent staging ^{18}F-FDG PET imaging and a histologic diagnosis of MCC between January 1997 and October 2010 at the Peter MacCallum Cancer Centre. This cohort of patients was partially included in our previous study evaluating the impact and prognostic value of pretreatment staging ^{18}F-FDG PET scanning (*19*). For these 102 patients, 53 scans were acquired in 36 patients as restaging or surveillance after definitive treatment and thirty-seven ^{18}F-FDG PET scans were acquired to assess overall response to potentially curative therapy. The median follow-up of patients in the restaging group was 5.3 y (95% confidence interval [CI], 4.6–9.4), whereas it was 5.7 y (95% CI, 4.3–10.8) for the response-assessment group. The general follow-up protocol for a patient with MCC treated with radical intent involved 3 monthly clinical reviews and examination for 2 y followed by 6 monthly clinical reviews for years 3–5 and then annually after that. Further investigations such as imaging and biopsy were performed at the discretion of the clinician.

For the primary objective, the null hypothesis of a true high-impact rate of 10% or less and a medium- or high-impact rate of 25% or less was tested using a 1-sided test for proportions assuming a binomial distribution. Median follow-up was calculated using the reverse Kaplan–Meier method. Overall survival (OS) time was measured from the date of PET response assessment and was described using the Kaplan–Meier product limit method with corresponding 95% CI. The log-rank test was used to evaluate the impact of potential prognostic factors on OS, and a univariate Cox proportional hazards model was used to estimate the hazard ratios. The presence of a positive resection margin, the size of the primary tumor, age, chemotherapy, concomitant surgery, nodal involvement, the presence of a complete metabolic response, and the primary site were used as candidate explanatory variables.

RESULTS

Restaging Scans

Fifty-three ^{18}F-FDG PET scans were undertaken for 36 patients at a time of suspected relapse or to assess ongoing response after definitive treatment of MCC. The restaging patient characteristics are detailed in Table 1. Eleven of the ^{18}F-FDG PET scans were stand-alone PET imaging, and 42 were hybrid PET/CT scans. Eight (14.5%) of the scans identified previously unsuspected nodal disease, and 9 (16.4%) identified unsuspected distant metastases. Fifteen of these 53 scans were routine restaging imaging scans, and 3 of these identified unsuspected distant metastases. The restaging ^{18}F-FDG PET scans had a high impact in 24 of 53 cases (45%), a medium impact in 6 of 53 (11%), and a low impact in 23 of 53 (43%). The other 38 restaging scans were obtained for clinical suspicion of recurrent disease, confirmed local recurrence, or as a response assessment to salvage treatment. Four of the scans obtained for clinical suspicion of disease recurrence (1 due to pain and 3 for examination findings) were negative.

Salvage Cases

Nine patients underwent attempted salvage therapy after development of local or locoregional disease. Four patients were successfully salvaged and remained disease-free at 4, 5, 6, and 11 y, respectively. All 4 patients had a clinical locoregional recurrence, and ^{18}F-FDG PET imaging excluded distant metastases. Of these 4 successful salvage cases, patient 1 developed a local recurrence of a scalp primary

TABLE 1
Restaging Patient Characteristics

Characteristic	*n* or median	% or range
Initial PET stage		
I/II	23	63.9%
III	12	33.3%
IV	1	2.8%
Sex		
Male	18	50%
Female	18	50%
Nodal involvement		
No	23	63.9%
Yes	13	36.1%
Primary size (mm)		
≤20	20	55.6%
21–50	4	11.1%
≥51	0	0%
Insufficient information	12	33.3%
Site		
Head and neck	17	47.2%
Lower limb	14	38.9%
Upper limb or trunk	5	13.9%
Age (y)	69.7 (median)	30.3–92.5

and had surgical excision of the area followed by a parotidectomy and neck dissection for a further locoregional recurrence with an intraparotid nodal metastasis. Patient 2 had a local scar recurrence of a postauricular primary treated by surgery and postoperative radiotherapy. The scar recurrence was surgically excised and has been clear to follow-up. Patient 3 had an in transit popliteal metastasis from a forearm primary successfully treated with definitive radiotherapy receiving a dose of 40 gray in 15 fractions, 5 fractions per week. Patient 4 had a local recurrence of a forearm primary, initially treated with concurrent chemoradiotherapy to the primary tumor and axilla. The recurrence was distal to the previous definitive radiotherapy field and was successfully surgically excised with no adjuvant treatment.

For the patients who had unsuccessful salvage therapy, patient 5 developed a local recurrence in the left supraclavicular fossa after initial radical chemoradiotherapy to the left shoulder followed by salvage radiotherapy to isolated mediastinal nodal disease. Patient 6 had a local, proximal recurrence after excision and radiotherapy of a left thigh MCC. It was re-excised, and further adjuvant radiotherapy was delivered to the re-excision site matching to the previous field and the left inguinal nodes were empirically treated. The patient was diagnosed with widespread visceral metastases 4 mo after salvage treatment. Patient 7 had a left scalp primary, which was excised and treated with adjuvant radiotherapy. This patient subsequently developed a left parotid lymphadenopathy 3 mo after treatment, which was isolated on PET and treated with salvage radiotherapy to the left parotid and cervical area. The patient developed widespread nodal and distant metastasis within 6 mo of salvage treatment. Patients 8 and 9 both had upper limb primaries treated with excision and adjuvant radiotherapy. They developed isolated left and right axillary recurrence, respectively, and both were treated with salvage radiotherapy to the areas. Both patients had a complete response in the salvage area but developed distant metastases within 3 and 5 mo of salvage treatment, respectively. All patients who were not successfully salvaged died within 14 mo of salvage treatment.

Response Assessment

In the response-assessment cohort, 37 patients underwent response-assessment PET scans within the 1- to 6-mo time frame. The median age of patients undergoing response-assessment PET scanning was 70.1 y (range, 29.5–88.2 y). The youngest patient was immunosuppressed. In terms of staging, 8 patients were classified as stage I, 1 as stage II, 27 as stage III, and 1 did not have sufficient information regarding primary tumor size to adequately stage. The mean timing of the response-assessment scan was 3.5 mo after completion of the patient's definitive treatment. The response-assessment patient characteristics are detailed in Table 2. Two patients had sentinel lymph node evaluation as part of their staging, with both procedures being negative. Thirty-six of the 37 patients undergoing therapeutic response assessment had radiotherapy as part of their treatment. Thirty patients had surgical excision of their primary lesion, with 24 of these in combination with adjuvant radiotherapy, and 6 patients had surgery alone. Thirteen patients had chemotherapy as part of their management. Of these 37 patients, 24 had a complete metabolic response (CMR) and 13 had an incomplete metabolic response. Patients who had a CMR on their response assessment had an 88% 2-y OS (95% CI, 0.75–1.00) and a 5-y OS of 68% (95% CI, 0.49–0.95) (Fig. 1). Patients who did not develop a CMR on response-assessment PET imaging had a 15% 1-y OS (95% CI, 0.04–0.55). The presence of a CMR ($P < 0.001$) and nodal involvement ($P = 0.016$) (Fig. 2) were the only statistically

TABLE 2
Response-Assessment Patient Characteristics

Characteristic	*n* or median	% or range
PET stage		
Inadequate information	1	2.7%
I/II	9	24.3%
III	27	73.0%
Sex		
Male	15	40.5%
Female	22	59.5%
Nodal involvement		
Inadequate information	1	2.7%
No	9	24.3%
Yes	27	73.0%
Primary size (mm)		
≤20	21	
21–50	8	
≥51	2	
Unknown	6	
Site		
Head and neck	15	40.5%
Lower limb	13	35.1%
Upper limb or trunk	9	24.3%
Age (y)	70.1 (median)	29.5–88.2

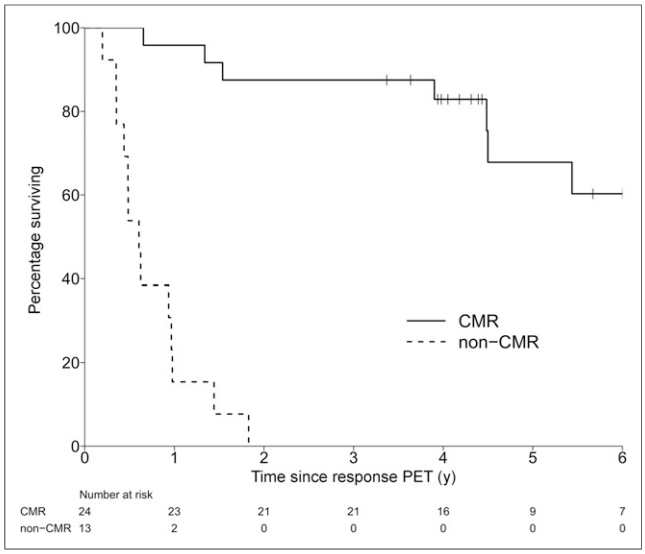

FIGURE 1. OS according to PET response.

significant prognostic factors for OS. Table 3 shows the unifactor analysis of possible prognostic factors for OS for MCC patients who underwent post-therapy response-assessment PET (Table 3).

The analysis of the prognostic value of metabolic response on OS was repeated in the subset of patients with nodal involvement ($n = 27$). Response remained significantly associated with OS in this subset of patients ($P < 0.001$), with a hazard ratio of 15.1 (95% CI, 4.0–56.9). Figure 3 describes the survival curves for this subset analysis. Of the 15 patients who obtained a CMR in their response-assessment PET, 4 patients developed a recurrence of MCC, with 2 of these locoregionally and 2 with distant metastases. The timing of the diagnosis of recurrence in the CMR group ranged from 10.1 to 20.0 mo (mean, 13.3 mo) after completion of definitive treatment (Fig. 3).

DISCUSSION

This study demonstrates the utility of ^{18}F-FDG PET imaging in post-therapy evaluation for MCC. Furthermore, it is one of the first studies to demonstrate the significant prognostic impact of ^{18}F-FDG PET in the post-therapy setting. Although existing literature supports the use of ^{18}F-FDG PET as a diagnostic and staging tool pretreatment (*13,19,20*), there are limited single-institution studies evaluating the utility of ^{18}F-FDG PET imaging after treatment of MCC. A retrospective study from the Dana-Farber/Brigham and Women's Cancer Centre recently demonstrated the importance of using this imaging modality for subsequent management of MCC. In their study, 209 post-therapy ^{18}F-FDG PET scans were obtained in 79 patients. Subsequent management included monitoring response during treatment, restaging after completion of treatment, analyzing suspected recurrence, or using ^{18}F-FDG PET scans for ongoing surveillance. Ninety-eight of 209 (45%) scans acquired identified disease in 42% of patients (33/79). The results from our restaging cohort further support the sensitivity of ^{18}F-FDG PET imaging in MCC and demonstrate the high impact that this imaging modality has on ongoing management of these patients. This is comparable to the high impact ^{18}F-FDG PET imaging has on several more common malignancies evaluated by our institution and others (*10–12,21,22*). Although routine surveillance is generally not recommended in diseases with a low likelihood of relapse, such as non-Hodgkin lymphoma achieving a CMR (*23*), continued post-treatment surveillance with restaging ^{18}F-FDG PET imaging may be important to monitor ongoing response to treatment and to identify, in a timely manner, recurrent disease that may be suitable for salvage treatment in this disease. Importantly, our data show successful salvage treatment in 4 of 9 patients detected on such scans with long-term disease-free follow-up (median, 6.5 y). This is a considerable proportion given the propensity for widespread metastatic disease and generally poor prognosis associated with this aggressive disease.

In our cohort of 102 evaluable patients, 37 response-assessment scans were used to determine the degree of metabolic response in post-treatment. Using the scans in this manner allowed for quantification of the treatment's effectiveness and assessment of the prognostic value of metabolic response on the patient's clinical outcome. Response-assessment scans highlighted both metabolic response and lymph node involvement as important prognostic factors for OS (adjusted $P < 0.001$ and 0.016, respectively). Recent literature has placed an emphasis on sentinel lymph node biopsy for prognostic information and disease-free survival improvement, compared with nodal observation in clinically node negative disease (*24*). The prognostic value of metabolic response of MCC after definitive treatment is a new observation and suggests that ^{18}F-FDG PET scans could be included as part of follow-up regimens to provide patients with a more accurate post-treatment prognosis. Concannon et al. showed the advantage of ^{18}F-FDG PET scanning in comparison to other imaging modalities (*25,26*). They considered previous studies, which used other imaging modalities to detect MCC. CT had relatively poor sensitivity (20%), and the limited field of view of MR imaging restricted the assessment of distant metastasis. They noted that a distinct advantage of ^{18}F-FDG PET was the ability to image the whole body in a single study and the detection of metabolic disease before lymph nodes become clinically evident. Sentinel lymph node biopsy is still, however, important to use in conjunction with ^{18}F-FDG PET, because these scans have been shown to miss nodal micrometastases (*24,27*). The low number of patients who had sentinel node evaluation in the response-assessment group is likely due to a high proportion having clinical lymph node involvement, some of the patients being staged before data showing the benefit of sentinel lymph node sampling and some patients having elective nodal

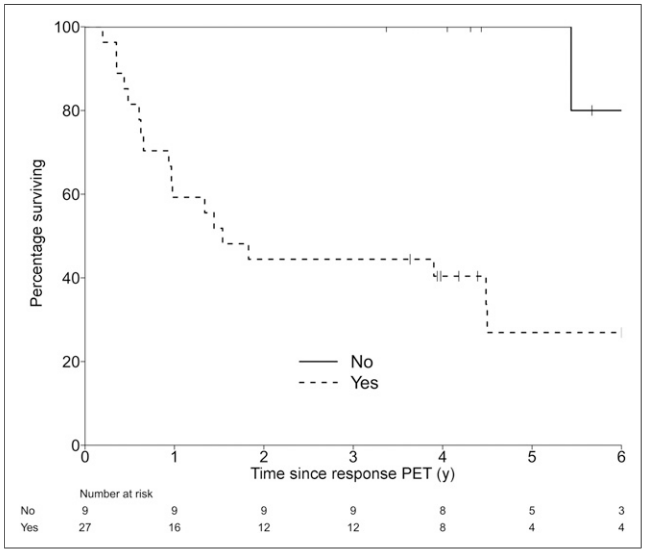

FIGURE 2. OS according to nodal involvement.

TABLE 3
Unifactor Analysis of Possible Prognostic Factors for OS and Analysis Adjusted by Time Between Radiotherapy and PET Assessment

Variable	*n*	2-y OS % (95% CI)	Hazard ratio (95% CI)	*P*	Adjusted hazard ratio (95% CI)	Adjusted *P*
Chemotherapy				0.75		0.94
No	24	54 (38–78)	1		1	
Yes	13	62 (40–95)	0.85 (0.33–2.23)		0.96 (0.35–2.60)	
Concomitant surgery*				0.24		0.28
No	7	43 (18–100)	1		1	
Yes	24	63 (46–85)	0.53 (0.18–1.54)		0.55 (0.19–1.61)	
Nodal involvement†				<0.001		0.016
No	9	100	1		1	
Yes	27	44 (29–68)	10.3 (1.4–77.3)		12.3 (1.6–95.8)	
Size				0.17		0.22
≤2 cm	21	57 (40–83)	1		1	
>2 cm	10	40 (19–86)	1.90 (0.75–4.82)		1.90 (0.68–5.32)	
Site				0.40		0.47
Head and neck	15	53 (33–86)	1		1	
Lower limb	13	77 (57–100)	0.60 (0.21–1.74)		0.65 (0.22–1.91)	
Upper limb/trunk	9	33 (13–84)	1.27 (0.44–3.68)		1.31 (0.45–3.80)	
Positive resection margin				0.17		0.19
No	11	64 (41–100)	1		1	
Yes	19	47 (30–76)	2.08 (0.72–5.98)		2.01 (0.70–5.80)	
Age	37		1.0 (0.97–1.04)	0.92	1.0 (0.97–1.05)	0.73
Metabolic response‡				<0.001		<0.001
CMR	24	88 (75–100)	1		1	
Non-CMR	13	—	25.7 (6.8–96.5)		28.8 (7.1–117.3)	

*Patients treated only with surgery were not considered in this comparison ($n = 6$).
†Only 1 patient without nodal involvement died.
‡OS at 2 y for non-CMR was not possible to be estimated. OS at 1 y for non-CMR patients was 15% (95% CI, 4%–55%).

treatment. In addition, our study showed the importance of ^{18}F-FDG PET scans as a prognostic tool through evaluating the metabolic response of patients after definitive treatment. More trials are needed to confirm the optimal timing and modality of imaging for follow-up of MCC.

The patient cohort characteristics for both restaging and response-assessment groups were consistent with previously published literature in terms of age (median, 69.7 and 70.1 y, respectively), site (head and neck area being the most common site), and the inclusion of patients with and without nodal involvement. However, unlike other epidemiological reports (*4*), there was a slight predilection for female patients over male patients (59.5% vs. 40.5%) in the response-assessment group.

Limitations of this study include the retrospective design, limited patient numbers due to the rarity of the disease, and the range of timing of response-assessment ^{18}F-FDG PET scans. Our starting time point for inclusion for a response-assessment scan was chosen because of previously published prospective data that 1-mo post-treatment ^{18}F-FDG PET imaging can be both highly sensitive and specific for evaluating response to treatment in other solid tumors (*28*). In addition, the long duration of the study period saw the evolution of several ^{18}F-FDG PET acquisition technologies, which may have improved diagnostic sensitivity over time. Furthermore,

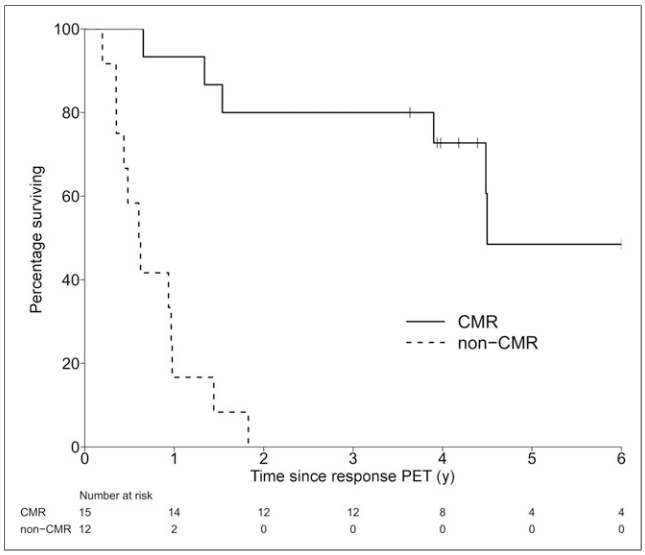

FIGURE 3. OS according to PET response in subset of patients with nodal involvement.

the advanced stage of MCC in the response cohort (73% stage III vs. 24.3% stage I/II) indicates the possibility of referral bias to a tertiary radiotherapy referral institution such as the Peter MacCallum Cancer Centre. Partial outcome data for this cohort of patients have been previously reported in evaluation of the impact and prognostic value of pretreatment staging ^{18}F-FDG PET imaging in MCC patients (*19*).

Further research into the prognostic value of ^{18}F-FDG PET metabolic response should be undertaken to confirm these results in different institutions and patient populations. Future studies may also consider altering the time frame for obtaining response-assessment scans to determine the optimal window for metabolic response assessment. We anticipate the results of the TROG 09.03 (MP 3) trial, which will aim to prospectively assess response to chemoradiotherapy in patients with MCC. This Australian multicenter phase II study will aim to accrue 50 patients and use ^{18}F-FDG PET imaging to assist in staging, planning, and assessing response to treatment at 12 wk after radiotherapy.

CONCLUSION

This study suggests that ^{18}F-FDG PET is a sensitive investigation tool that has significant management impact in the restaging setting and is useful in the evaluation of response to treatment of MCC. In addition to identifying patients who may be suitable for salvage treatment, ^{18}F-FDG PET metabolic response is prognostic for survival.

DISCLOSURE

The costs of publication of this article were defrayed in part by the payment of page charges. Therefore, and solely to indicate this fact, this article is hereby marked "advertisement" in accordance with 18 USC section 1734. No potential conflict of interest relevant to this article was reported.

ACKNOWLEDGMENTS

We thank Joshua Laing and Daphne Jacobs for their assistance in data collection and also Annette Hogg and Elizabeth Drummond for their maintenance of the Peter MacCallum Cancer Centre prospective PET database.

REFERENCES

1. Kokoska ER, Kokoska MS, Collins BT, Stapleton DR, Wade TP. Early aggressive treatment for Merkel cell carcinoma improves outcome. *Am J Surg.* 1997;174:688–693.
2. Toker C. Trabecular carcinoma of the skin. *Arch Dermatol.* 1972;105:107–110.
3. SEER Cancer Statistics Review (CSR) 1975-2012. National Cancer Institute website. http://seer.cancer.gov/csr/1975_2012/. Accessed July 22, 2015.
4. Albores-Saavedra J, Batich K, Chable-Montero F, Sagy N, Schwartz AM, Henson DE. Merkel cell carcinoma demographics, morphology, and survival based on 3870 cases: a population based study. *J Cutan Pathol.* 2010;37:20–27.
5. Rodig SJ, Cheng J, Wardzala J, et al. Improved detection suggests all Merkel cell carcinomas harbor Merkel polyomavirus. *J Clin Invest.* 2012;122:4645–4653.
6. Dabner M, McClure RJ, Harvey NT, et al. Merkel cell polyomavirus and p63 status in Merkel cell carcinoma by immunohistochemistry: Merkel cell polyomavirus positivity is inversely correlated with sun damage, but neither is correlated with outcome. *Pathology.* 2014;46:205–210.
7. Ware RE, Matthews JP, Hicks RJ, et al. Usefulness of fluorine-18 fluorodeoxyglucose positron emission tomography in patients with a residual structural abnormality after definitive treatment for squamous cell carcinoma of the head and neck. *Head Neck.* 2004;26:1008–1017.
8. Duong CP, Hicks RJ, Weih L, et al. FDG-PET status following chemoradiotherapy provides high management impact and powerful prognostic stratification in oesophageal cancer. *Eur J Nucl Med Mol Imaging.* 2006;33:770–778.
9. Kalff V, Duong C, Drummond EG, Matthews JP, Hicks RJ. Findings on ^{18}F-FDG PET scans after neoadjuvant chemoradiation provides prognostic stratification in patients with locally advanced rectal carcinoma subsequently treated by radical surgery. *J Nucl Med.* 2006;47:14–22.
10. Siva S, Herschtal A, Thomas JM, et al. Impact of post-therapy positron emission tomography on prognostic stratification and surveillance after chemoradiotherapy for cervical cancer. *Cancer.* 2011;117:3981–3988.
11. Hicks RJ, Kalff V, MacManus MP, et al. ^{18}F-FDG PET provides high-impact and powerful prognostic stratification in staging newly diagnosed non-small cell lung cancer. *J Nucl Med.* 2001;42:1596–1604.
12. Mac Manus MP, Hicks RJ, Matthews JP, et al. Positron emission tomography is superior to computed tomography scanning for response-assessment after radical radiotherapy or chemoradiotherapy in patients with non-small-cell lung cancer. *J Clin Oncol.* 2003;21:1285–1292.
13. Treglia G, Kakhki VR, Giovanella L, Sadeghi R. Diagnostic performance of fluorine-18-fluorodeoxyglucose positron emission tomography in patients with Merkel cell carcinoma: a systematic review and meta-analysis. *Am J Clin Dermatol.* 2013; 14:437–447.
14. Hui AC, Stillie AL, Seel M, Ainslie J. Merkel cell carcinoma: 27-year experience at the Peter MacCallum Cancer Centre. *Int J Radiat Oncol Biol Phys.* 2011;80:1430–1435.
15. Grotz TE, Tarantola TI, Otley CC, Weaver AL, McGree ME, Jakub JW. Natural history of Merkel cell carcinoma following locoregional recurrence. *Ann Surg Oncol.* 2012;19:2556–2562.
16. Eng TY, Naguib M, Fuller CD, Jones WE III, Herman TS. Treatment of recurrent Merkel cell carcinoma: an analysis of 46 cases. *Am J Clin Oncol.* 2004;27:576–583.
17. Kalff V, Hicks RJ, Ware RE, Greer B, Binns DS, Hogg A. Evaluation of high-risk melanoma: comparison of [^{18}F]FDG PET and high-dose ^{67}Ga SPET. *Eur J Nucl Med Mol Imaging.* 2002;29:506–515.
18. Edge S, Byrd DR, Compton CC, Fritz AG, Greene FL, Trotti A, eds. *AJCC Cancer Staging Manual.* 7th ed. New York, NY: Springer; 2010.
19. Siva S, Byrne K, Seel M, et al. ^{18}F-FDG PET provides high-impact and powerful prognostic stratification in the staging of Merkel cell carcinoma: a 15-year institutional experience. *J Nucl Med.* 2013;54:1223–1229.
20. Hawryluk EB, O'Regan KN, Sheehy N, et al. Positron emission tomography/computed tomography imaging in Merkel cell carcinoma: a study of 270 scans in 97 patients at the Dana-Farber/Brigham and Women's Cancer Center. *J Am Acad Dermatol.* 2013;68:592–599.
21. Jayachandran P, Pai RK, Quon A, et al. Postchemoradiotherapy positron emission tomography predicts pathologic response and survival in patients with esophageal cancer. *Int J Radiat Oncol Biol Phys.* 2012;84:471–477.
22. Capirci C, Rubello D, Pasini F, et al. The role of dual-time combined 18-fluorodeoxyglucose positron emission tomography and computed tomography in the staging and restaging workup of locally advanced rectal cancer, treated with preoperative chemoradiation therapy and radical surgery. *Int J Radiat Oncol Biol Phys.* 2009;74:1461–1469.
23. Cheah CY, Hofman MS, Dickinson M, et al. Limited role for surveillance PET-CT scanning in patients with diffuse large B-cell lymphoma in complete metabolic remission following primary therapy. *Br J Cancer.* 2013;109:312–317.
24. Sadeghi R, Adinehpoor Z, Maleki M, Fallahi B, Giovanella L, Treglia G. Prognostic significance of sentinel lymph node mapping in Merkel cell carcinoma: systematic review and meta-analysis of prognostic studies. *Biomed Res Int.* May 26, 2014 [Epub ahead of print].
25. Anderson SE, Beer KT, Banic A, et al. MRI of Merkel cell carcinoma: histologic correlation and review of the literature. *AJR.* 2005;185:1441–1448.
26. Concannon R, Larcos GS, Veness M. The impact of ^{18}F-FDG PET-CT scanning for staging and management of Merkel cell carcinoma: results from Westmead Hospital, Sydney, Australia. *J Am Acad Dermatol.* 2010;62:76–84.
27. Gupta SG, Wang LC, Penas PF, Gellenthin M, Lee SJ, Nghiem P. Sentinel lymph node biopsy for evaluation and treatment of patients with Merkel cell carcinoma: the Dana-Farber experience and meta-analysis of the literature. *Arch Dermatol.* 2006;142:685–690.
28. Kim SY, Lee SW, Nam SY, et al. The feasibility of ^{18}F-FDG PET scans 1 month after completing radiotherapy of squamous cell carcinoma of the head and neck. *J Nucl Med.* 2007;48:373–378.