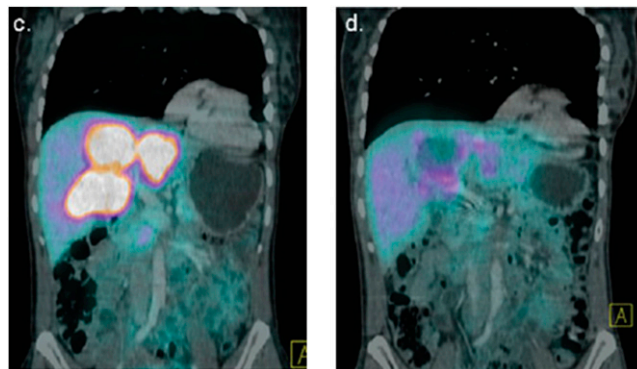


SNM 2012 Image of the Year

The highly anticipated selection of the 2012 SNM Image of the Year was announced on June 12 at the SNM 59th Annual Meeting in Miami, FL. The individual panels that make up the image, from researchers at the European Commission Joint Research Centre Institute for Transuranium Elements (Karlsruhe, Germany) and University Hospital (Heidelberg, Germany), show the effectiveness of peptide receptor α -therapy with ^{213}Bi -DOTATOC for gastroenteropancreatic neuroendocrine tumors (GEP NETs) that do not respond to β -therapy.

A panel of experts selected these images from more than 2,000 presentations at the SNM Annual Meeting. Each year, SNM chooses an image that exemplifies cutting-edge molecular imaging research and that demonstrates the ability of molecular imaging to detect and diagnose disease and to identify the most appropriate therapies. “The images illustrating the effectiveness of ^{213}Bi -DOTATOC for GEP NETs show remarkable results that can be achieved in a clinical setting,” said Peter Herscovitch, MD, chair of the SNM Scientific Program Committee. “This opens up a new door for those patients whose cancer does not respond to traditional chemotherapy.”

Alfred Morgenstern, PhD, project leader of the Alpha-Immunotherapy Project at Karlsruhe, was lead author of the study “Synthesis of ^{213}Bi -DOTATOC for peptide receptor α -therapy of GEP NET patients refractory to β -therapy.” The study described the synthesis of ^{213}Bi -DOTATOC using a microwave-assisted labeling protocol. The research included 17



2012 SNM Image of the Year: Two panels from the 2012 Image of the Year show response of multiple liver lesions at baseline (left) and after (right) therapy with 14 GBq ^{213}Bi -DOTATOC.

patients with GEP NETs who had previously shown resistance to treatment with ^{90}Y - or ^{177}Lu -DOTATOC and who were treated with escalating doses of the peptide receptor α -therapy (1–10–20 GBq). Researchers assessed response with contrast-enhanced sonography, MR imaging, ^{68}Ga -DOTATOC PET/CT, and analysis of tumor markers. In addition, organ toxicities were monitored during and after treatment. Patients tolerated escalating doses well, with no acute kidney, endocrine, or hematologic toxicities. Shrinkage of primary tumors as well as liver and bone metastases was observed.

(Continued from page 22N)

ing therapeutic response and has prognostic value after EBRT.” We need more research in ^{18}F -sodium fluoride, including comparisons with conventional $^{99\text{m}}\text{Tc}$ -MDP bone scanning to assess real value.

Clinical Outcomes: Evidence-Based Medicine

I began by saying that the real challenge today is in getting appropriate data on clinical outcomes to support meaningful evidence-based medicine. One useful approach was presented by Stamm et al. from the University of Alberta (Edmonton, Canada), who reported on “A cost-efficient diagnostic imaging algorithm incorporating ^{123}I -MIBG SPECT/CT for suspected pheochromocytoma” [474]. The authors correlated 24-h fractionated urine metanephrine (FUM) results within 2 mo of SPECT/CT and found that when FUM values were normal, all of the SPECT/CT studies were negative (16/71). Conversely, 87% of patients with a total metanephrine (TM) $\geq 1.7 \mu\text{mol}/24 \text{ h}$ (15/71) had positive SPECT/CT studies. If the TM was $<1.7 \mu\text{mol}/24 \text{ h}$ but one or more of the metanephrine fractions were abnormal (40/71),

only 39%–58% of SPECT/CT studies were positive. Of these, none had a positive SPECT/CT with a negative or benign CT and/or MR (14/71). The group used these data to develop an algorithm that indicated that the average cost could be lowered to \$1,897.94/patient (31 MIBG, 20 CT, 20 MR imaging) with no expected change in accuracy (an imaging cost savings of 42% or \$1,375.91/patient). Their decision tree indicated that patients with clinically suspected pheochromocytoma should be evaluated initially with 24-h FUM. If TM is $\geq 1.7 \mu\text{mol}/24 \text{ h}$, then the patient should be evaluated with ^{123}I -MIBG SPECT/CT. If FUM values are normal, no further imaging is indicated. A CT or MR study should be performed if the TM is $<1.7 \mu\text{mol}/24 \text{ h}$ and one or more of the metanephrine fractions is abnormal. If the CT or MR is normal or benign, no further imaging is required. If abnormal, further evaluation with ^{123}I -MIBG SPECT/CT is indicated. We need to develop more of these types of cost effectiveness studies.

Alan H. Maurer, MD
Temple University School of Medicine
Philadelphia, PA