

^{99m}Tc -HYNIC-TOC Scintigraphy Is Superior to ^{131}I -MIBG Imaging in the Evaluation of Extraadrenal Pheochromocytoma

Libo Chen¹, Fang Li¹, Hongming Zhuang², Hongli Jing¹, Yanrong Du¹, and Zhengpei Zeng³

¹Department of Nuclear Medicine, Peking Union Medical College Hospital, Chinese Academy of Medical Sciences, Beijing, China;

²Department of Radiology, Children's Hospital of Philadelphia, University of Pennsylvania School of Medicine, Philadelphia, Pennsylvania; and

³Department of Endocrinology, Peking Union Medical College Hospital, Chinese Academy of Medical Sciences, Beijing, China

In this investigation, the efficacy of scintigraphy using ^{99m}Tc -labeled hydrazinonicotinyl-Tyr3-octreotide (HYNIC-TOC) in the evaluation of extraadrenal pheochromocytoma was assessed and compared with ^{131}I -labeled metaiodobenzylguanidine (MIBG) imaging. **Methods:** Ninety-seven patients who were suspected of having pheochromocytoma but showed no definite adrenal abnormalities on CT were evaluated by both ^{99m}Tc -HYNIC-TOC scintigraphy and ^{131}I -MIBG imaging. The results were compared with pathology findings or clinical follow-up. **Results:** Of 58 patients proven to be without pheochromocytoma, ^{99m}Tc -HYNIC-TOC and ^{131}I -MIBG imaging excluded 56 and 58 patients, respectively, rendering a specificity of 96.6% for ^{99m}Tc -HYNIC-TOC imaging and 100% for ^{131}I -MIBG imaging. In the evaluation of adrenal pheochromocytoma (14 patients), the sensitivity of ^{99m}Tc -HYNIC-TOC scintigraphy and ^{131}I -MIBG imaging was 50% and 85.7%, respectively. However, in the evaluation of extraadrenal pheochromocytomas (25 patients), the sensitivity of ^{99m}Tc -HYNIC-TOC scintigraphy and ^{131}I -MIBG imaging was 96.0% and 72.0%, respectively. **Conclusion:** ^{99m}Tc -HYNIC-TOC scintigraphy is more sensitive than ^{131}I -MIBG imaging in the detection of extraadrenal pheochromocytomas.

Key Words: extraadrenal pheochromocytoma; ^{99m}Tc -hydrazinonicotinyl-tyr3-octreotide (HYNIC-TOC); metaiodobenzylguanidine (MIBG)

J Nucl Med 2009; 50:397–400

DOI: 10.2967/jnumed.108.058693

Extraadrenal pheochromocytomas arise within the sympathetic nervous system and originate from the neural crest. They can be located in sympathetic ganglions anywhere from the neck to the pelvis. As opposed to the traditional teaching that 10% of all pheochromocytomas are at extra-

adrenal sites, the real incidence of extraadrenal pheochromocytomas is much higher (1,2). Up to 40% of extraadrenal pheochromocytomas can be malignant and may be unexpected at the time of the initial imaging. ^{123}I - or ^{131}I -labeled metaiodobenzylguanidine (MIBG) imaging is the main nuclear medicine modality in the evaluation of pheochromocytoma. However, the sensitivity of ^{131}I -MIBG imaging is significantly lower in the diagnosis of extraadrenal pheochromocytoma than in the diagnosis of adrenal pheochromocytoma (3,4). Somatostatin receptor imaging using ^{111}In -labeled octreotide is also known to have value in the evaluation of pheochromocytoma (5). In addition, ^{68}Ga -labeled DOTA-Tyr3-octreotide (DOTATOC), as a somatostatin analog and a PET tracer, has great potential for accurate diagnosis of a variety of neuroendocrine tumors (6–8) because of the superior resolution and quantitative ability of modern PET and PET/CT scanners. However, experience with ^{68}Ga -DOTATOC in the evaluation of pheochromocytoma is still limited. Recently, ^{99m}Tc -labeled octreotides have also been used in the evaluation of several different types of malignancies (9–11). It was reported that ^{99m}Tc -hydrazinonicotinyl-Tyr3-octreotide (HYNIC-TOC) achieved higher tumor-to-normal-tissue ratios than did ^{111}In -labeled octreotide and, therefore, had higher sensitivity than did ^{111}In -labeled octreotide as an imaging agent for the localization of somatostatin receptor-expressing tumors (12). In this investigation, the efficacy of ^{99m}Tc -labeled octreotide HYNIC-TOC scintigraphy in the detection of both adrenal and extraadrenal pheochromocytoma was assessed and compared with ^{131}I -MIBG imaging.

MATERIALS AND METHODS

Patients

In this retrospective investigation, 1,001 charts of patients with unexplainable hypertension and suspected pheochromocytomas, referred nationwide to our institution, were reviewed. All patients had symptoms such as profuse sweating, tachycardia, and headache. These patients were referred to us for imaging studies evaluating for possible pheochromocytoma. However, only those

Received Sep. 30, 2008; revision accepted Dec. 5, 2008.

For correspondence or reprints contact: Fang Li, Department of Nuclear Medicine, Peking Union Medical College Hospital, Chinese Academy of Medical Sciences, No. 1, Shuaifuyuan, Wangfujing St., Dongcheng District, Beijing, 100730, P.R. China.

E-mail: lifang5502@sohu.com

COPYRIGHT © 2009 by the Society of Nuclear Medicine, Inc.

patients with postsurgical pathologic confirmation of the lesions or those with clinical follow-up for more than 1 y were included in our analysis. In addition, only those patients whose abdominal CT scans (within 4 mo before ^{131}I -MIBG imaging) revealed either no adrenal abnormalities or ambiguous findings underwent both ^{131}I -MIBG imaging and $^{99\text{m}}\text{Tc}$ -HYNIC-TOC scintigraphy. Because our surgeons preferred that at least 2 different imaging modalities be positive before surgery, both ^{131}I -MIBG imaging and $^{99\text{m}}\text{Tc}$ -HYNIC-TOC scintigraphy were generally performed. Those patients with definite adrenal abnormality on CT underwent ^{131}I -MIBG studies but not $^{99\text{m}}\text{Tc}$ -HYNIC-TOC scintigraphy and therefore were not included in our analysis. ^{131}I -MIBG imaging and $^{99\text{m}}\text{Tc}$ -HYNIC-TOC scintigraphy were performed within a 2-wk interval. Ninety-seven patients (53 male and 44 female; age range, 8–75 y) met the criteria to be included in the final analysis. The $^{99\text{m}}\text{Tc}$ -HYNIC-TOC and ^{131}I -MIBG images were interpreted by 2 experienced nuclear medicine physicians who were unaware of other clinical and imaging information. The chart review and image analysis for the patients in this study were approved by the institutional review board.

$^{99\text{m}}\text{Tc}$ -HYNIC-TOC Scintigraphy

$^{99\text{m}}\text{Tc}$ -HYNIC-TOC was synthesized and labeled according to a method published previously (13). Images were also acquired following a published protocol (13). The images were interpreted jointly by 2 experienced nuclear medicine physicians who were aware of neither the histopathologic diagnosis nor the previously reported interpretation of the $^{99\text{m}}\text{Tc}$ -HYNIC-TOC scintigraphy findings.

^{131}I -MIBG Imaging

Each patient was given a potassium perchlorate preparation for 5 d, starting 3 d before the ^{131}I -MIBG administration. Twenty-four hours after intravenous administration of 1.48 MBq of ^{131}I -MIBG per kilogram of body weight, whole-body images were acquired using a dual-head γ -camera with a window setting of 364 keV.

RESULTS

No patients had any complaints related to the $^{99\text{m}}\text{Tc}$ -HYNIC-TOC or ^{131}I -MIBG administration. For all patients in whom pheochromocytoma was ultimately confirmed to be present, both readers correctly interpreted the images as positive for pheochromocytoma. There was no interreader disagreement. The image findings were compared with the final histopathologic diagnosis of the removed tumors after surgery and biopsy ($n = 42$) and clinical follow-up for more than 1 y ($n = 55$).

Patients Without Pheochromocytoma

Fifty-eight patients were proven not to have pheochromocytoma. Among these, $^{99\text{m}}\text{Tc}$ -HYNIC-TOC scintigraphy excluded 56, for a specificity of 96.6% (56/58). Both false-positive interpretations of pheochromocytomas on $^{99\text{m}}\text{Tc}$ -HYNIC-TOC scintigraphy were due to $^{99\text{m}}\text{Tc}$ -HYNIC-TOC uptake by adrenal carcinomas. ^{131}I -MIBG imaging was negative in all 58 patients, for a specificity of 100.0% (58/58).

Patients with Pheochromocytomas

Thirty-nine patients had pheochromocytomas confirmed by either histopathologic examination after surgery and

biopsy ($n = 37$) or clinical follow-up and other studies ($n = 2$). The tumors of 14 patients were in the adrenal glands, whereas 25 patients had extraadrenal lesions. On a per-patient basis, $^{99\text{m}}\text{Tc}$ -HYNIC-TOC scintigraphy identified 31 patients with pheochromocytoma, for a sensitivity of 79.5% (31/39). The sensitivity of ^{131}I -MIBG imaging was 82.1% (32/39), or slightly higher than the sensitivity of $^{99\text{m}}\text{Tc}$ -HYNIC-TOC scintigraphy.

Of the 14 adrenal pheochromocytomas, $^{99\text{m}}\text{Tc}$ -HYNIC-TOC scintigraphy identified only 50% (7/14). In contrast, ^{131}I -MIBG imaging revealed 85.7% (12/14).

Twenty-five patients had extraadrenal pheochromocytomas. Of these 25, 14 had benign extraadrenal pheochromocytomas (all in either the mediastinal or abdominal paraspinal region). Ten of 14 benign extraadrenal lesions were successfully detected by both ^{131}I -MIBG imaging and $^{99\text{m}}\text{Tc}$ -HYNIC-TOC scintigraphy. However, 3 patients with benign extraadrenal pheochromocytomas had negative ^{131}I -MIBG findings but their lesions were successfully detected by $^{99\text{m}}\text{Tc}$ -HYNIC-TOC scintigraphy (Fig. 1). Both ^{131}I -MIBG imaging and $^{99\text{m}}\text{Tc}$ -HYNIC-TOC scintigraphy failed to detect 1 lesion in 1 patient. Therefore, $^{99\text{m}}\text{Tc}$ -HYNIC-TOC scintigraphy offered a sensitivity of 92.9% (13/14) in this clinical setting. In comparison, the sensitivity of ^{131}I -MIBG imaging in the detection of benign extraadrenal pheochromocytoma is lower, at 71.4% (10/14).

Eleven patients had malignant extraadrenal pheochromocytomas. Of these 11, 8 had positive findings on both ^{131}I -MIBG imaging and $^{99\text{m}}\text{Tc}$ -HYNIC-TOC scintigraphy. However, the abnormalities in 3 patients were detected by $^{99\text{m}}\text{Tc}$ -HYNIC-TOC scintigraphy but not ^{131}I -MIBG imaging (Fig. 2). Therefore, for malignant extraadrenal pheochromocytoma, $^{99\text{m}}\text{Tc}$ -HYNIC-TOC scintigraphy had a sensitivity of 100% (11/11) whereas the sensitivity of ^{131}I -MIBG imaging again was lower, at 72.7% (8/11).

For the evaluation of extraadrenal pheochromocytoma, the overall sensitivity of $^{99\text{m}}\text{Tc}$ -HYNIC-TOC scintigraphy is, therefore, 96.0% (24/25), whereas the sensitivity of ^{131}I -MIBG imaging is 72.0% (18/25).

DISCUSSION

Although our results showed that $^{99\text{m}}\text{Tc}$ -HYNIC-TOC scintigraphy is excellent in the detection of extraadrenal lesions, it cannot replace ^{131}I -MIBG imaging in the evaluation of patients with suspected pheochromocytoma. The overwhelming majority of pheochromocytomas are intraadrenal, and $^{99\text{m}}\text{Tc}$ -HYNIC-TOC is less accurate than ^{131}I -MIBG imaging in evaluating intraadrenal lesions. Therefore, most patients should still undergo ^{131}I -MIBG imaging first in the work-up of pheochromocytoma, and the role of $^{99\text{m}}\text{Tc}$ -HYNIC-TOC scintigraphy lies mainly in those patients who have negative or ambiguous results on ^{131}I -MIBG imaging and when an extraadrenal pheochromocytoma is suspected.

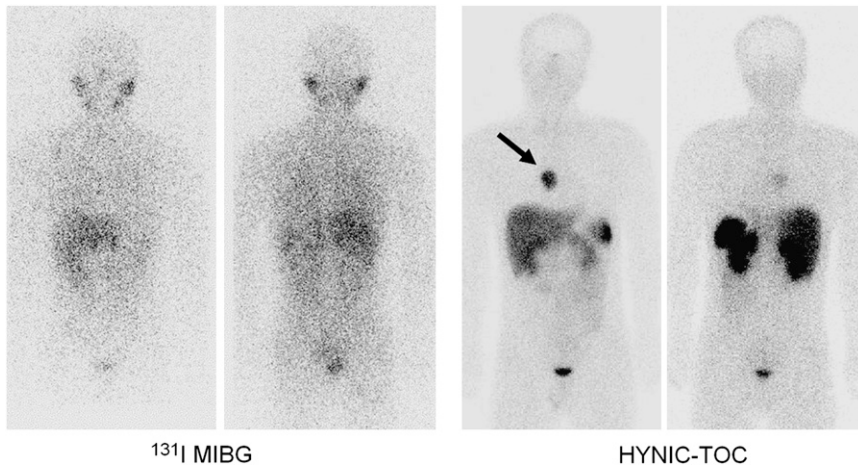


FIGURE 1. A woman presented with dizziness, palpitation, and perspiration. Pheochromocytoma was suspected, and her urine catecholamine level was elevated. However, abdominal CT from an outside institution had no abnormal findings. ^{131}I -MIBG imaging was unrevealing. In contrast, $^{99\text{m}}\text{Tc}$ -HYNIC-TOC scintigraphy identified abnormal activity in mediastinum (arrow), which was surgically removed and histopathologically proven to be pheochromocytoma.

It is unclear why $^{99\text{m}}\text{Tc}$ -HYNIC-TOC is superior to ^{131}I -MIBG in the detection of extraadrenal pheochromocytoma. These 2 tracers are very different in their mechanism of uptake by cells. $^{99\text{m}}\text{Tc}$ -HYNIC-TOC is a somatostatin analog binding to receptors, whereas ^{131}I -MIBG is a guanethidine analog that is sequestered mainly in the storage granules of chromaffin cells. Cellular ^{131}I -MIBG uptake is driven both by saturable active type I uptake and by passive diffusion (14). A subsequent active uptake mechanism, different from the transmembrane uptake mechanism, is responsible for the translocation of intracellular ^{131}I -MIBG into the storage granules (15). It is well known that ^{131}I -MIBG uptake by the tumor can significantly be affected by large ranges of medications (16). Therefore, for those individuals who cannot follow prescan instructions to stop related medicines, the sensitivity of ^{131}I -MIBG imaging may be decreased. Extraadrenal pheochromocytoma may be malignant in up to 40% of cases (2,17). Malignant pheochromocytoma may undergo tumor dedifferentiation, with loss of specific neurotransmitter transporters (18). The result is an inability to accumulate these isotopes and a consequent lack of localization, that is, decreased sensitivity in ^{131}I -MIBG imaging (5). Physiologic cardiac uptake of ^{131}I -MIBG (19) can be significant, making it difficult to

use ^{131}I -MIBG to evaluate superimposed malignancy in the mediastinum. In contrast, because of the absence of any physiologic cardiac uptake of $^{99\text{m}}\text{Tc}$ -HYNIC-TOC, pheochromocytoma in the mediastinal or pericardial regions can be more easily recognized by $^{99\text{m}}\text{Tc}$ -HYNIC-TOC scintigraphy than by ^{131}I -MIBG imaging (20).

There are many advantages to a technetium-based tracer in nuclear medicine. These include a frequently lower radiation dose to the patient; an optimal 140-keV energy peak, which results in better images; and a shorter procedure (a few hours for $^{99\text{m}}\text{Tc}$ -HYNIC-TOC scintigraphy, as opposed to more than 1 d for MIBG imaging). In addition, the quality of SPECT images is excellent when technetium is used but is often less than optimal when other tracers are used. Furthermore, $^{99\text{m}}\text{Tc}$ is easily available, and $^{99\text{m}}\text{Tc}$ -HYNIC-TOC can be prepared in any nuclear medicine service equipped with trained personnel—factors that are potentially cost-saving.

One drawback of our investigation was its retrospective nature. Unintended bias in patient selection is difficult to avoid in a retrospective study. Most pheochromocytomas are in the adrenal glands. However, in our study, only a small portion of the patients had adrenal lesions, because in many patients with adrenal pheochromocytoma, the disease

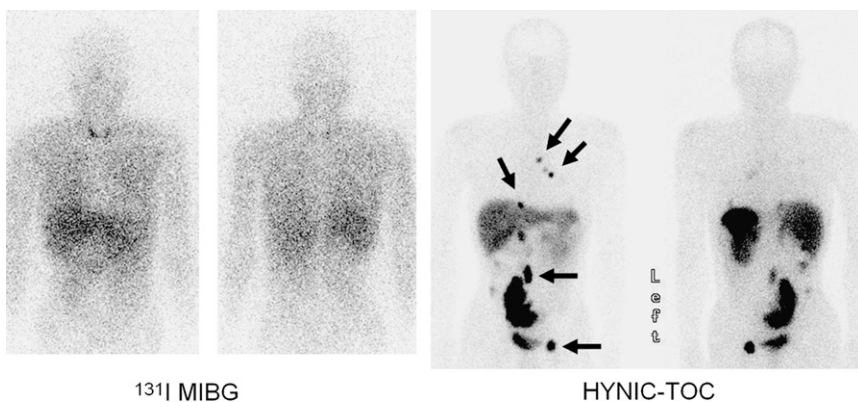


FIGURE 2. A 58-y-old man had pheochromocytoma 10 y ago, and the primary tumor had been successfully removed surgically. One year before patient underwent ^{131}I -MIBG imaging and $^{99\text{m}}\text{Tc}$ -HYNIC-TOC scintigraphy, groin pain had developed. ^{131}I -MIBG imaging did not reveal any abnormalities except for mildly increased activity in thyroid bed, which was attributed to unlabeled free ^{131}I . However, subsequent $^{99\text{m}}\text{Tc}$ -HYNIC-TOC scintigraphy demonstrated many foci of intense activity (arrows), indicating metastatic malignant pheochromocytomas, as confirmed by biopsy.

can be detected by CT. However, when pheochromocytoma is suspected at our institution, only those patients without a definite adrenal abnormality or with ambiguous results on CT are further imaged by both ^{131}I -MIBG imaging and $^{99\text{m}}\text{Tc}$ -HYNIC-TOC scintigraphy, significantly reducing the number of the patients with adrenal pheochromocytoma in our final analysis. It is conceivable that if all patients suspected of having pheochromocytoma had been included in the final analysis without CT preselection, the accuracy of $^{99\text{m}}\text{Tc}$ -HYNIC-TOC scintigraphy and ^{131}I -MIBG imaging would have been different from what we presented.

$^{99\text{m}}\text{Tc}$ -HYNIC-TOC can show increased accumulation in other types of tumors, as was also seen in our study. The positive findings on two $^{99\text{m}}\text{Tc}$ -HYNIC-TOC scans were later proven to be due to adrenal carcinomas. Therefore, in our final analysis, the findings in these 2 cases were treated as false-positive. However, from a patient-care point of view, the results of these two $^{99\text{m}}\text{Tc}$ -HYNIC-TOC scans should be regarded as true-positive because the findings were crucial to subsequent patient management.

CONCLUSION

Our preliminary results indicate that ^{131}I -MIBG imaging remains the method of choice in the evaluation of adrenal pheochromocytoma. However, $^{99\text{m}}\text{Tc}$ -HYNIC-TOC scintigraphy is superior to ^{131}I -MIBG imaging in the evaluation of extraadrenal pheochromocytomas. Larger prospective studies are necessary for validation of our findings.

REFERENCES

- Whalen RK, Althausen AF, Daniels GH. Extra-adrenal pheochromocytoma. *J Urol*. 1992;147:1–10.
- Disick GI, Palese MA. Extra-adrenal pheochromocytoma: diagnosis and management. *Curr Urol Rep*. 2007;8:83–88.
- Bhatia KS, Ismail MM, Sahdev A, et al. ^{123}I -metaiodobenzylguanidine (MIBG) scintigraphy for the detection of adrenal and extra-adrenal pheochromocytomas: CT and MRI correlation. *Clin Endocrinol (Oxf)*. 2008;69:181–188.
- Jalil ND, Pattou FN, Combemale F, et al. Effectiveness and limits of preoperative imaging studies for the localisation of pheochromocytomas and paragangliomas: a review of 282 cases. French Association of Surgery (AFC), and The French Association of Endocrine Surgeons (AFCE). *Eur J Surg*. 1998;164:23–28.
- van der Harst E, de Herder WW, Bruining HA, et al. [^{123}I]metaiodobenzylguanidine and [^{111}In]octreotide uptake in benign and malignant pheochromocytomas. *J Clin Endocrinol Metab*. 2001;86:685–693.
- Gabriel M, Decristoforo C, Kendler D, et al. ^{68}Ga -DOTA-Tyr3-octreotide PET in neuroendocrine tumors: comparison with somatostatin receptor scintigraphy and CT. *J Nucl Med*. 2007;48:508–518.
- Henze M, Schuhmacher J, Hipp P, et al. PET imaging of somatostatin receptors using [^{68}Ga]DOTA-D-Phe1-Tyr3-octreotide: first results in patients with meningiomas. *J Nucl Med*. 2001;42:1053–1056.
- Hofmann M, Maecke H, Borner R, et al. Biokinetics and imaging with the somatostatin receptor PET radioligand ^{68}Ga -DOTATOC: preliminary data. *Eur J Nucl Med*. 2001;28:1751–1757.
- Parisella M, D'Alessandria C, van de Bossche B, et al. $^{99\text{m}}\text{Tc}$ -EDDA/HYNIC-TOC in the management of medullary thyroid carcinoma. *Cancer Biother Radiopharm*. 2004;19:211–217.
- Plachinska A, Mikolajczak R, Kozak J, Rzeszutek K, Kusmierek J. Differential diagnosis of solitary pulmonary nodules based on $^{99\text{m}}\text{Tc}$ -EDDA/HYNIC-TOC scintigraphy: the effect of tumour size on the optimal method of image assessment. *Eur J Nucl Med Mol Imaging*. 2006;33:1041–1047.
- Decristoforo C, Maina T, Nock B, Gabriel M, Cordopatis P, Moncayo R. $^{99\text{m}}\text{Tc}$ -Demotate 1: first data in tumour patients—results of a pilot/phase I study. *Eur J Nucl Med Mol Imaging*. 2003;30:1211–1219.
- Gabriel M, Decristoforo C, Donnemiller E, et al. An inpatient comparison of $^{99\text{m}}\text{Tc}$ -EDDA/HYNIC-TOC with ^{111}In -DTPA-octreotide for diagnosis of somatostatin receptor-expressing tumors. *J Nucl Med*. 2003;44:708–716.
- Decristoforo C, Melendez-Alafort L, Sosabowski JK, Mather SJ. $^{99\text{m}}\text{Tc}$ -HYNIC-[Tyr3]-octreotide for imaging somatostatin-receptor-positive tumors: preclinical evaluation and comparison with ^{111}In -octreotide. *J Nucl Med*. 2000;41:1114–1119.
- Jaques S Jr, Tobes MC, Sisson JC. Sodium dependency of uptake of norepinephrine and m-iodobenzylguanidine into cultured human pheochromocytoma cells: evidence for uptake-one. *Cancer Res*. 1987;47:3920–3928.
- Sisson JC, Wieland DM, Sherman P, Mangner TJ, Tobes MC, Jacques S Jr. Metaiodobenzylguanidine as an index of the adrenergic nervous system integrity and function. *J Nucl Med*. 1987;28:1620–1624.
- Solanki KK, Bomanji J, Moyes J, Mather SJ, Trainer PJ, Britton KE. A pharmacological guide to medicines which interfere with the biodistribution of radiolabelled meta-iodobenzylguanidine (MIBG). *Nucl Med Commun*. 1992;13:513–521.
- de Herder WW, Kwakkeboom DJ, Valkema R, et al. Neuroendocrine tumors and somatostatin: imaging techniques. *J Endocrinol Invest*. 2005;28(suppl)132–136.
- Ramachandran B, Houben K, Rozenberg YY, Haigh JR, Varpetian A, Howard BD. Differential expression of transporters for norepinephrine and glutamate in wild type, variant, and WNT1-expressing PC12 cells. *J Biol Chem*. 1993;268:23891–23897.
- Chen W, Botvinick EH, Alavi A, et al. Age-related decrease in cardiopulmonary adrenergic neuronal function in children as assessed by I-123 metaiodobenzylguanidine imaging. *J Nucl Cardiol*. 2008;15:73–79.
- Chen L, Li F, Zhuang H, Jing H, Du Y, Zeng Z. Cardiac pheochromocytomas detected by Tc-99m-hydrazinonicotinyl-Tyr3-octreotide (HYNIC-TOC) scintigraphy. *Clin Nucl Med*. 2007;32:182–185.