

## The Response of Disseminated Reticulum Cell Sarcoma To The Intravenous Injection of Colloidal Radioactive Gold<sup>1</sup>

Philip Rubin, M.D.<sup>2</sup> and Seymour H. Levitt, M.D.<sup>3</sup>

*Rochester, New York and Oklahoma City*

Reticulum cell sarcoma in its disseminated form is a disease of grave prognosis. It is unrelenting in its progression, and remission is rare. Although external irradiation can control some local manifestations, it is ineffective in the management of widespread visceral involvement. Chemotherapeutic agents as nitrogen mustard and cortisone derivatives are of palliative value but are short-lived in regard to their beneficial effects. They are helpful only sporadically, if at all.

It is because of this poor overall prognosis in the disseminated form of disease and inadequate response to the usual therapeutic agents that efforts have been made to find some other method of control. The use of radioisotopes in the treatment of diseases of the lymphoid system was first attempted with the use of  $P^{32}$  in the late 1930's and early 1940's (5, 15, 18, 19, 22). The rationale for this use was the relatively high concentration of  $P^{32}$  by rapidly metabolizing tissues such as bone marrow, liver and neoplastic cells. The subsequent irradiation obtained in the absorbing cells would lead to the irradiation of the tissue in question with relative safety to other parts of the body.

Despite initial early enthusiasm the use of the isotopes was abandoned in the treatment of lymphomas by most investigators. The reason for this was the limited response both symptomatically and objectively despite bone marrow depressing doses (5, 22).

Colloidal radiomanganese followed by colloidal radiogold were the next isotopes used by a number of investigators in the treatment of disease of the lymphoid macrophage system. Sheppard (28) initially reported on the use of colloid radiogold in the treatment of lymphomas. The rationale for its use was that the colloidal radioisotopes localized in the lymphoid macrophage system (9) and could therefore theoretically give a desired selective radiation effect in diseases of this system.

Specifically it was found that 60 to 90 per cent of the intravenously injected radiogold was firmly retained in the liver. It was phagocytized there by the reticulo-endothelial cells and thus distributed grossly in a uniform manner throughout the liver (2, 23, 27, 28). The remainder of the colloidal isotope was reported to be distributed about equally in spleen and bone marrow in the reticulo-endothelial cells.

<sup>1</sup>Presented at the Nuclear Society Meeting, Montreal, Canada, June, 1963.

<sup>2</sup>Chief, Division of Radiation Therapy and Radioisotopes, Strong Memorial Hospital, University of Rochester Medical Center, Rochester, New York.

<sup>3</sup>Chief, Department of Radiation Therapy, University of Oklahoma Medical Center, Oklahoma City, Oklahoma.

Because of this selective absorption, intravenous colloidal gold was used in the experimental treatment of leukemias, lymphomas and metastatic disease of the liver, with expectation of a selective radiation effect (9, 28). This agent was initially used intravenously for metastatic disease to the liver with little success. Interest in its use in diffuse reticulum cell sarcoma arose with the thought that there might be selective absorption by the tumor cells due to their reticulo-endothelial origin.

#### PRESENT SERIES

The course of diffuse reticulum cell sarcoma is invariably rapid and downhill. In reviewing the charts of eighteen cases eligible for five year survival, it is noted that the survival for Stage II or Stage III forms of this disease is virtually nil (Table I).

Of the two patients with disseminated disease treated in this manner, one has survived over five years (our only Stage II or III survivor). This unusual result warrants further analysis.

*Case I.* J.A. is a 47 year old male who presented with the following chronology:

*July, 1954:* The patient was initially seen because of pain in the right shoulder of three months' duration. Physical examination revealed a 1½ to 2 cm right epitrochlear node. No other evidence of disease was noted. A biopsy was taken of the involved node and was diagnosed as reticulum cell sarcoma. There was no further treatment.

*April, 1955:* While in Los Angeles, California the patient developed pain and swelling of the right arm which was thought to be due to lymphatic obstruction secondary to reticulum cell sarcoma. X-ray showed questionable subperiosteal bone reaction. He received 1918 r air to the right shoulder and 1087 r air to the right arm (280 KV) with a resultant decrease in swelling and pain.

*Aug., 1957:* The patient was readmitted to Strong Memorial Hospital with a brief history of cough, dyspnea and recurrent epigastric distress. Physical examination revealed an enlarged liver 4 FB below the right costal margin. No lymphadenopathy was noted. Chest x-ray (Fig. 1) revealed a mediastinal mass.

TABLE I  
5 YEAR SURVIVAL

<i>Reticulum Diffuse Cell Ca.</i>	<i>No. Treated</i>	<i>No.</i>	<i>%</i>
Stage I	3	2	66.0
Stage II	4	0	0
Stage III	*11	1	9*
Total	18	3	16.7

Stage I —Grossly limited to one anatomic site

Stage II —Limited to two continuous lymphatic regions

State III—Involvement of two or more distant lymphatic regions

\*Patient treated in Stage III with radioactive colloidal gold intravenously.

Survival in Reticulum Cell Sarcoma, Strong Memorial Hospital (1952-1957).

A GI series again showed a hiatus hernia. The patient received x-ray (280 KV) treatment to the mediastinum. A tumor dose of 1500 r was given in 16 days with symptomatic and objective relief.

*Oct., 1957:* The patient continued to have epigastric distress. He was seen at the New England Deaconess Hospital and treated with 2 MEV x-ray to the epigastrium with the supposition that the pain was due to enlarged celiac nodes. He received 1350 r tumor dose in 10 days with subjective relief.

*March, 1958:* The patient returned with recurrence of epigastric pain. Physical examination revealed the liver to be enlarged 4 FB below the right costal margin and a left upper abdominal mass. GI series (Fig. 2) revealed involvement of the proximal stomach and distal esophagus by a mass. The patient was treated with 1 MEV x-ray to the upper abdomen and received a tumor dose of 2100 r in 28 days. He obtained symptomatic and objective relief from this treatment.

*July, 1958:* The epigastric pain recurred and was more severe. Physical examination revealed the liver to be palpable 8 cm below the right costal margin. Au<sup>198</sup> liver scan showed a liver of abnormal size with diffuse filling defects (Fig. 3 a). A normal scan would occupy 25 to 28 lines.

*July 24, 1958:* The patient was hospitalized and given 50 mc of colloidal Au<sup>198</sup> intravenously. The liver became exquisitely tender in 24 to 48 hours followed by reduction in liver size to 4 cm below the costal margin. Repeat liver scan shows homogeneous distribution of radioactivity (Fig. 3 b) and persistent hepatomegaly

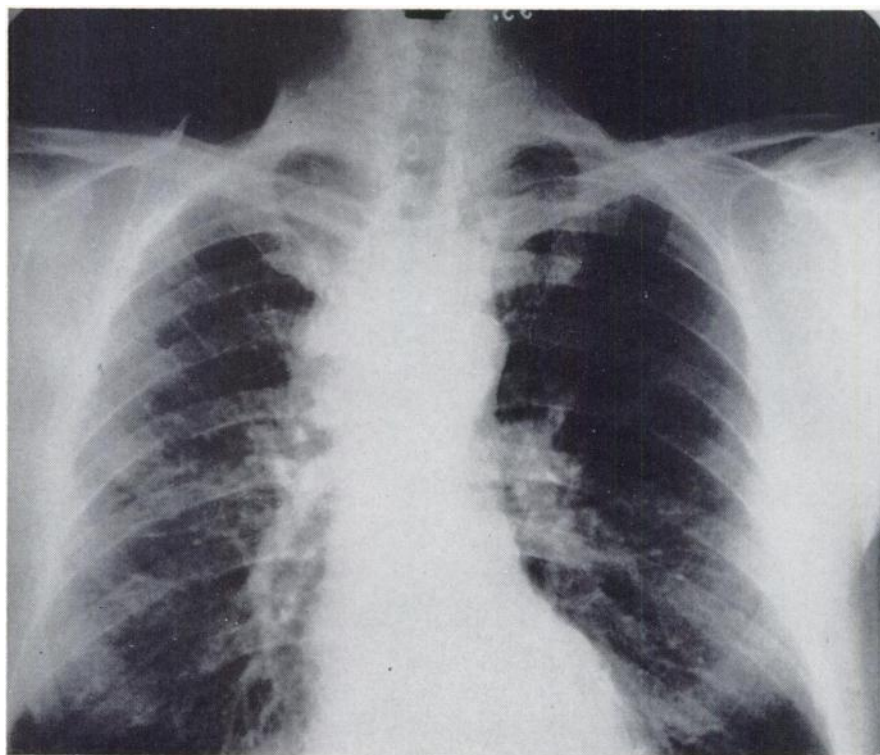


Fig. 1(a). Case I (J.A.): Enlargement of mediastinum with widening to the right side is noted on chest film.

*Aug. 14, 1958:* The patient returned to the emergency room because of prolonged bleeding from his gums following a dental procedure. Physical examination demonstrated widespread petechiae and ecchymosis. Laboratory examination revealed prothrombin time to be 50 per cent (previous to Au<sup>198</sup> Rx it had been 60%). Hgb, wbc and platelets decreased (Fig. 4). Bone marrow was hypocellular. The treatment was supportive. There was a gradual return of the peripheral blood to normal.

*Sept. 5, 1958:* The patient was discharged from the hospital. There has been no evidence of recurrent disease since.

*June, 1963:* Last follow-up visit. The patient is well, free of disease, with a palpable liver 2 FB cm and a normal peripheral blood picture and liver chemistries.

*Comment:* This patient demonstrated a course of reticulum cell sarcoma which was initially Stage I and localized but gradually became generalized with new areas of disease developing rapidly. The disease was most responsive to x-irradiation at all times. At the stage of disease in which radiogold was used, he was apparently progressing toward a terminal phase. The intravenous radiogold has produced a five year remission in this patient. A spontaneous remission at this stage of the disease in our experience is unknown.

Case II. F. J. is a 71 year old male with a past history of cholelithiasis, diverticulosis of the colon and hiatus hernia.

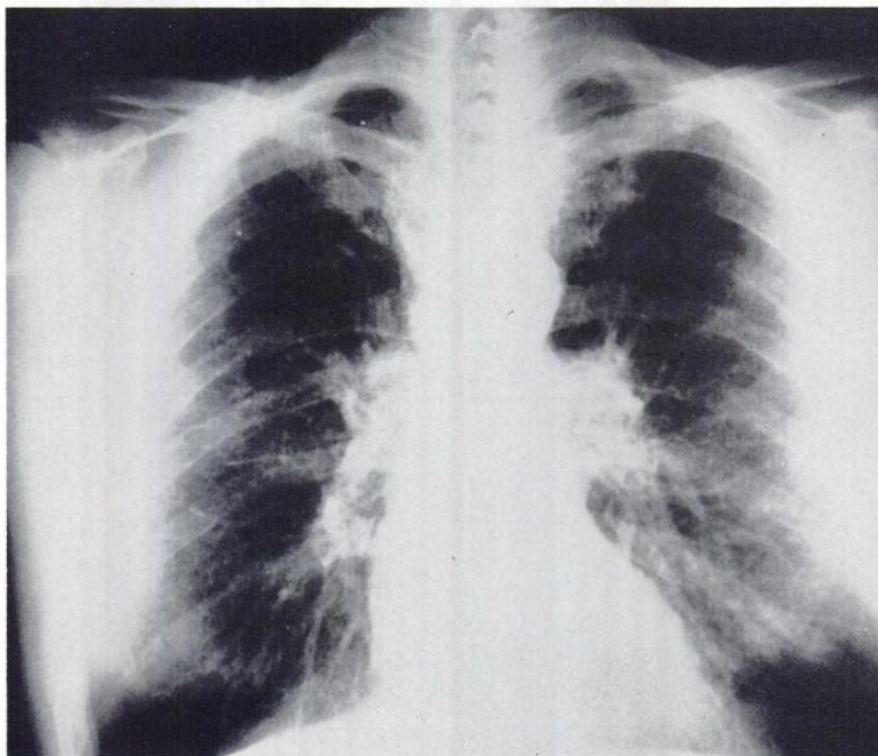
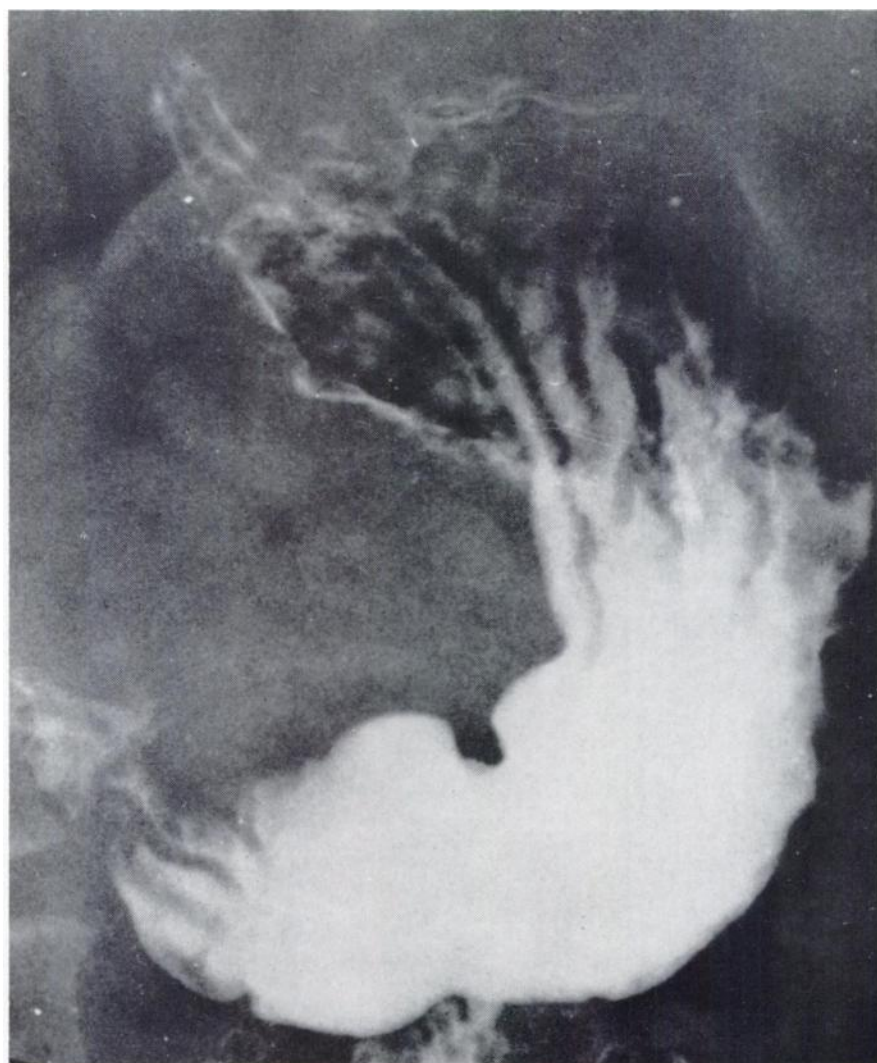


Fig. 1(b). Case I (J.A.): Return of mediastinum to normal following irradiation.

*June 1, 1959:* The patient was seen because of complaints of complete loss of appetite, epigastric pain, nine pound weight loss and development of masses in the right axillary and left supraclavicular areas. Physical examination revealed 2 x 3 cm right axillary and supraclavicular nodes. A biopsy was done of the right supraclavicular mass and diagnosed as reticulum cell sarcoma.

*June 17, 1959:* The patient was treated with 1 MEV x-ray therapy to the axillary, mediastinal and retroperitoneal areas. He received 3151 r tumor dose to the axillary and supraclavicular areas and 2800 r tumor dose to the retroperitoneal area in 30 days. There was approximately 70 per cent regression of the axillary mass.

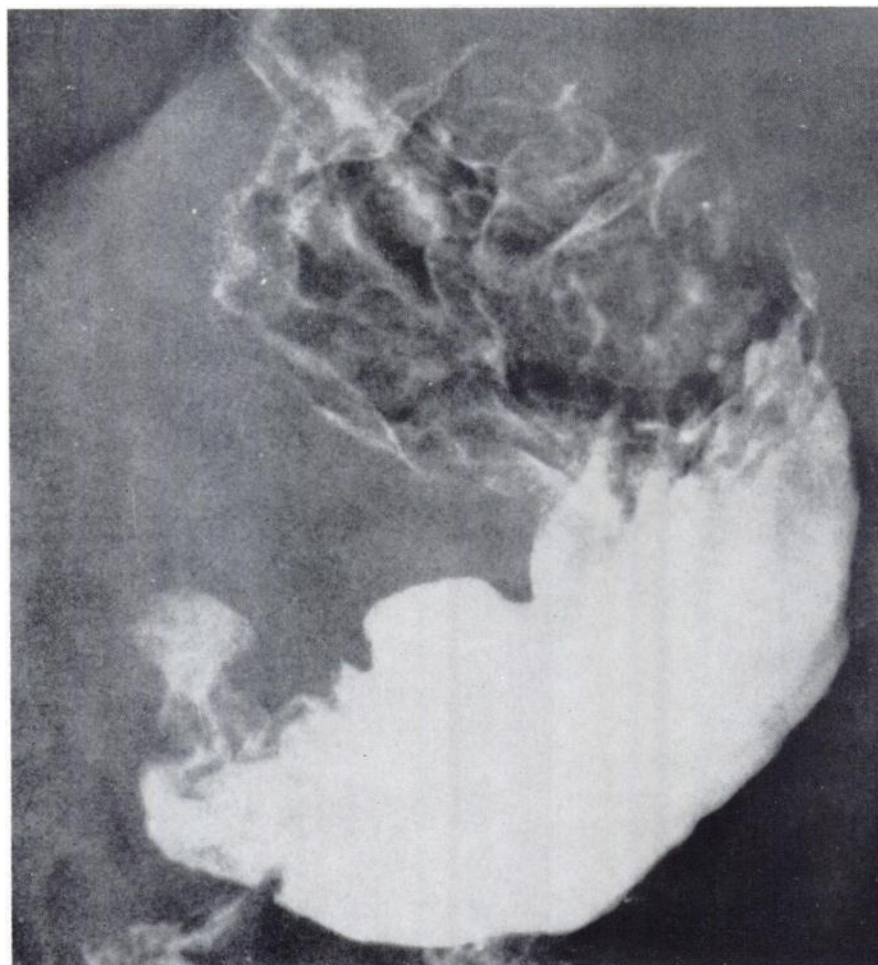


**Fig. 2(a).** Case I (J.A.): Upper GI series six months pretherapy to stomach showing rugal coarsening.

*July 1, 1959:* The patient returned complaining of development of right upper cervical nodes. He received 2000 r skin (280 KV) in 13 days to the involved areas. There was almost complete disappearance of the cervical nodes. During the treatment to the cervical region, the right axillary nodes began to increase in size again. They were retreated to a skin dose of 1400 r skin in 9 days with no evident response.

*Aug. 19, 1959:* Enlarged left inguinal nodes were noted. The left inguinal area was treated to a skin dose of 2000 r skin (280 KV) in one week with only a slight decrease in size.

*Oct., 1959:* Because of a low hemoglobin value found on routine examination, an iliac crest bone marrow biopsy was done. This showed depression of all elements and apparent hypoplasia. The findings were thought to be consistent with, but not diagnostic of reticulum cell sarcoma.



**Fig. 2(b).** Case I (J.A.): Immediately prior to x-ray therapy to stomach showing pattern typical of lymphoma in very thick and irregular rugae in fundus.

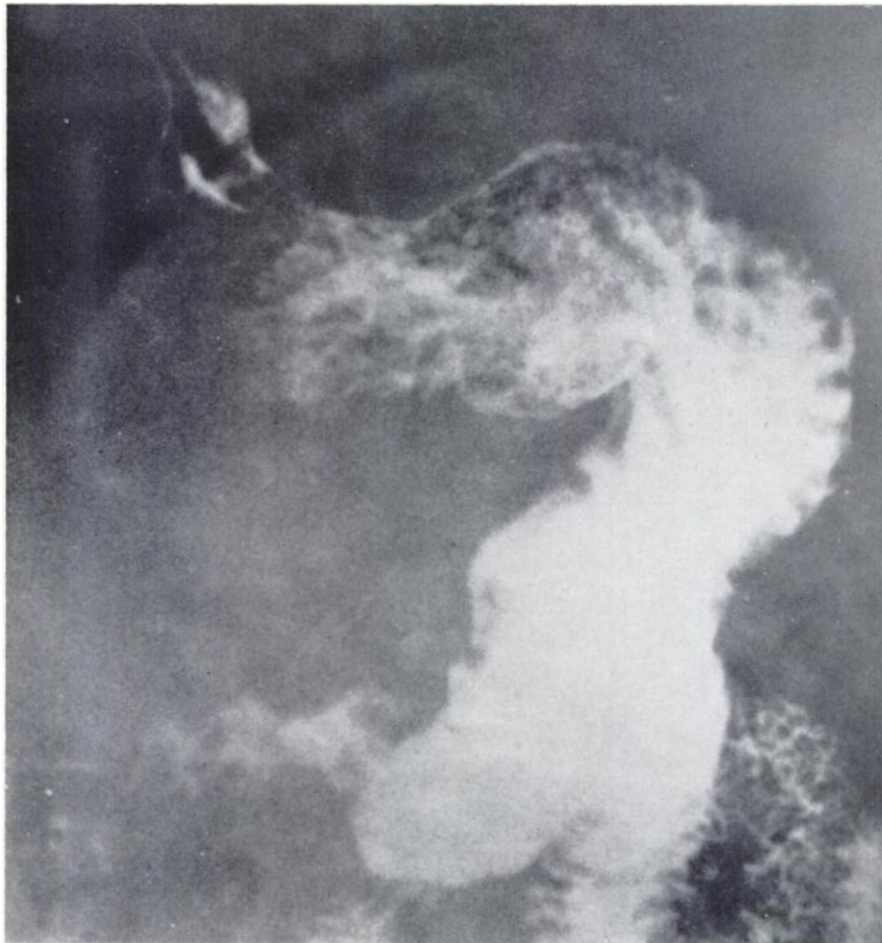*Oct. 15, 1959:* Because of continued and rapid progression of the disease and with the favorable response of J.A. in mind, the patient was treated with 50 mc IV colloidal Au<sup>198</sup>. He was followed closely with blood counts (Fig. 5).

*Oct. 30, 1959:* The patient was readmitted to Strong Memorial Hospital because of progressive thrombocytopenia, anemia and low grade fever. The patient was treated with blood transfusions, steroids, etc.

*Oct. 13, 1959:* The patient expired.

*Autopsy Findings:* Reticulum cell sarcoma of the liver, spleen, lymph nodes, bone marrow and jejunum. The bone marrow was hypoplastic. The spleen showed evidence of necrosis of 75 to 80 per cent of the tumor nodules although the peripheral portions of the nodules tended to be viable. There was a large tumor mass in the liver, the central  $\frac{1}{2}$  of which was scarred tissue. Only one lymph node from the mesentery was sectioned; this showed neither tumor nor radiation effect.

*Comment:* This patient's disease course was more rapid from the onset and



**Fig. 2(c).** Case I (J.A.): One year post x-ray therapy to stomach showing normal pattern of rugae.

the disease process did not respond so well to irradiation as did the previous case. In addition, prior to the injection of the radiogold, his bone marrow showed evidence of depression. It is probable that the colloidal gold added the final insult to an already diseased marrow with the subsequent death.

*Discussion:* Radioactive gold administered intravenously in patients with lymphomas has never been successful in the past. Attempts by Hahn (9,11) more than fifteen years ago in Hodgkin's disease had yielded poor results. The reason for this outcome is the inability of the intravenously injected radiogold to concentrate in normal lymph nodes unlike intralymphatic administration of this colloid (6, 16, 20, 26, 30).

*What is the explanation for the successful outcome in the case (J.A.) of disseminated reticulum cell sarcoma?* The possibilities that present themselves for consideration are:

- (1) Possible specific phagocytic activity by the reticulum sarcoma cells;
- (2) Possible spontaneous remission; or
- (3) Fortuitous distribution of the disease so that it paralleled the distribution of the radiogold.

(1) *Specific Phagocytic Activity by Reticulum Sarcoma Cells:* The possibility that the response in the first case was due to phagocytic activity by the



Fig. 3(a). Case I (J.A.): Liver scan using Rose Bengal I<sup>131</sup> eight days before treatment dose of colloidal gold showing diffuse filling defects. Hepatomegaly at this time is 8 FB cm.



neoplastic cells because of their histocytic origin does not seem likely. External scanning in other cases failed to reveal localization in known sites of adenopathy. The experience of Tristan *et al* (32) showed that although there was an increased concentration of injected colloidal radiogold in Letterer-Siewes disease (reticulo-endotheliosis) as compared to uninvolved tissue, the differential was not great enough to produce a satisfactory response in the diseased tissue. It seems highly unlikely that a direct phagocytic response by the malignant cells is the reason for the favorable response.

(2) *Spontaneous Remission*: Furthermore, it seems unlikely that a spontaneous remission would account for this result since in all of our previous experience, when reticulum cell sarcoma became generalized, the disease has progressed unabated to death. However, this possibility can never be completely excluded.

(3) *Distribution of Disease Paralleling Distribution of Radiogold*: Intravenous radiogold is uniformly distributed throughout the liver and spleen and




Fig. 3(b). Case I (J.A.): Liver scan one week after the intravenous injection of 50 mc colloidal Au 198 showing a normal liver scan with disappearance of diffuse defect pattern. Liver edge is now 4 FB cm.

to a lesser degree in the bone marrow reflecting reticulo-endothelial cellular activity (2, 23). The possibility of treating diffuse microscopic rather than nodular metastatic liver deposits was suggested by Root and others (1, 23) in that the therapeutic usefulness of the  $\beta$ -emission of  $\text{Au}^{198}$  is limited by bone marrow tolerance and doses of 50 millicuries are maximal. With 80% absorption in an enlarged liver 3000 to 4000 gm., the dose is equivalent to 1000 to  $\pm 200$  rads in five days.<sup>1</sup> Thus, for this agent to be effective therapeutically, the neoplastic process must be radiosensitive, microscopic in deposits and diffuse and homogenous. It is postulated that our first patient met these criteria and also fortuitously had his disease distributed in a manner similar to the distribution of the administered radioactive gold.

*What are the hazards of intravenous radioactive gold ( $\text{Au}^{198}$ )?* Both cases point up the possible dangers inherent in the use of intravenous colloidal gold. Liver damage in humans has not been noted to be of consequence in the use of this agent. However, it should be noted that the usual doses of 50 to 100 mc. of the isotope IV have not been exceeded. These doses have been calculated to deliver 1200 to 2500 rads to the whole of the liver weighing 3000 gm. It is entirely feasible that liver damage of a severe nature could be produced by larger doses. Ingold, Bagshaw and Kaplan have shown in a well presented clinico-pathologic presentation that the tolerance dose for the liver resulting in a radiation hepatitis is 3000 r. Animal experimentation in rats (17, 29) and dogs (10) have shown the development of liver damage. Two investigators reported lesions resembling cirrhosis with associated jaundice, ascites and hepatic dysfunction when doses to the liver of 24,000 reps and above were used and particularly when the  $\text{Au}^{198}$  was given in divided doses (10, 17).

Little has been written in the literature concerning what is probably the most serious danger in using intravenous radiogold. Bone marrow depression has primarily occurred in the treatment of leukemia and the cause of anemia in such patients is difficult to determine. Even recent reports have commented that there is a considerable amount of latitude in the allowable dose with "resultant negligible harmful effect on the bone marrow" (12). A small number of cases of bone marrow depression following intracavitary and intratumor injection of radiogold have been noted (3, 23, 25). Much animal experimentation clearly indicates the depressive effects of intravenous colloidal gold and includes the development of leucopenia (33), thrombocytopenia (7, 8, 14) and aplastic anemia (10) depending upon the dose administered.

$W$ (gm)	2000	3000	4000	
$D\beta$	1320	880	660	rads
$D\gamma$	323	248	203	rads
	—	—	—	
D (total)	1643	1128	863	rads

<sup>1</sup>The  $\gamma$  dose is a high proportion of the total dose. The dose calculation is based on the assumption of a spherical volume; where the  $\gamma/\beta$  ratio is low this assumption is relatively unimportant but in this case the  $\gamma$  contribution is almost 25% and so the accuracy of the  $\gamma$  dose may make a significant difference.

Both cases described in this report have shown the depressive bone marrow effect of the intravenous radiogold, one with fatal consequences. One patient not reported treated for liver metastases also showed severe bone marrow depression and eventually died because of uncontrolled hemorrhage. He was one of five cases so treated and the only one to receive a repeat course of 50 mc or a total dose of 100 mc. The charts in Figures 4 and 5 trace the hematologic picture in both patients. F.J. obviously had bone marrow suppression prior to treatment, but J.A. did not. This could help account for the fatal outcome in one as opposed to the other. The problem of bone marrow depression seems to be closely related to the fact that the therapeutic ratio as determined by the dose required for destruction of the diseased cells and the normal proliferating bone

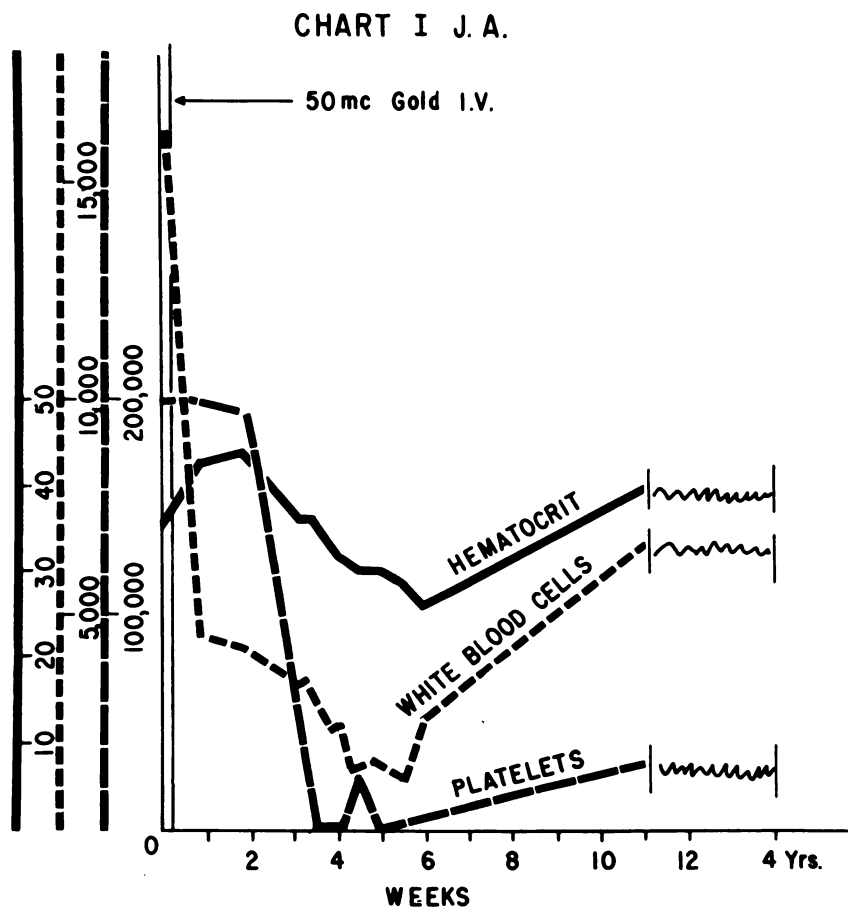


Fig. 4. Case I (J.A.): Graphic illustration of response of peripheral blood following administration of 50 mc. Au<sup>198</sup> intravenously.

marrow is small. In a bone marrow already compromised by neoplastic replacement, the hemopoietic reserve may not be sufficient to overcome the effect of radiation.

## SUMMARY

1. External radiation therapy remains the treatment of choice in localized reticulum cell sarcoma.

2. Intravenous colloidal radiogold may be a useful agent in lymphosarcomas with diffuse minute neoplastic involvement of the liver and spleen, and possibly minimal bone marrow involvement. It is essentially of no use in the treatment of involved lymph nodes or large masses.

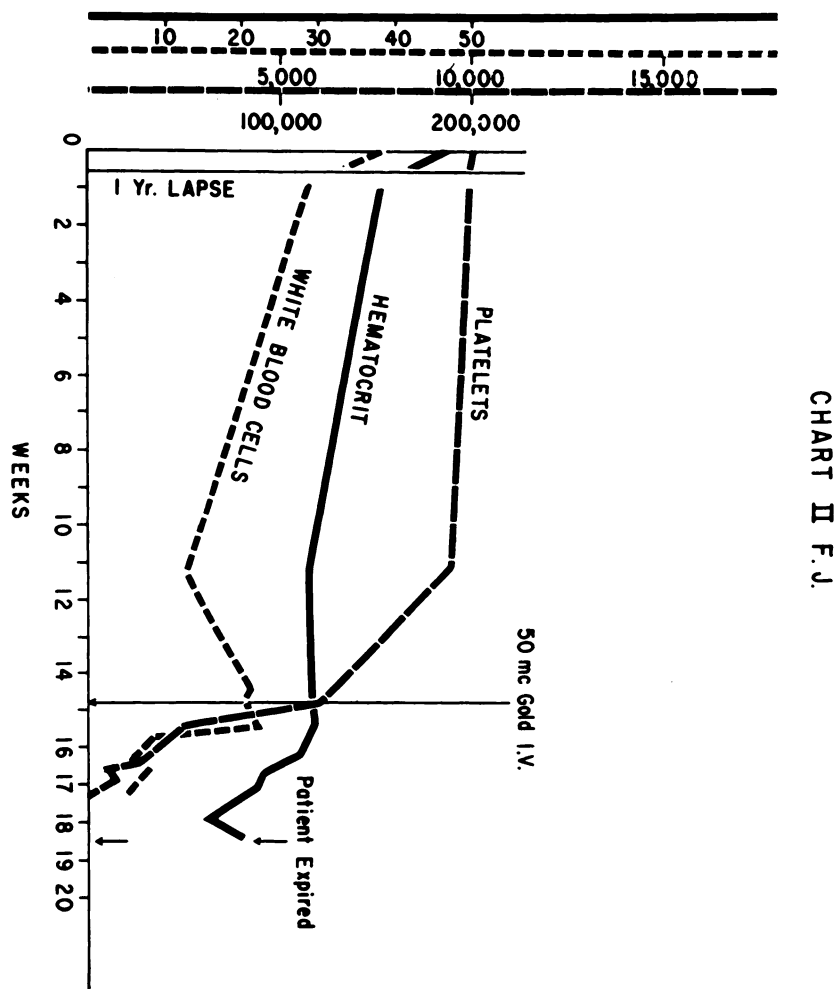


Fig. 5. Case II (F.J.): Graphic illustration of response of peripheral blood to 50 mc.  $Au^{198}$  intravenously.

3. Intravenous colloidal radiogold can produce bone marrow depression and thrombocytopenia which can lead to death. Patients so treated should be carefully followed with complete blood counts including platelet levels. A definite hypoplasia of the bone marrow or anemia is a contraindication for the use of this agent.

4. No more than 50 mc. Au<sup>198</sup> intravenously should be used for treatment of this disease.

## BIBLIOGRAPHY

1. ANDREWS, G. A., KNISELEY, R. M., PALMER, E. L. AND KRETCHMAN, A. L.: In Proc. of the Internat'l. Conf. on Peaceful Uses of Atomic Energy, New York, United Nations, Vol. 10, pp. 122-137, 1956.
2. BARROW, J., TULLIS, J. L. AND CHAMBERS, F. W., JR.: Effect of X-Irradiation and Antihistamine Drugs on the Reticulo-Endothelial System Measured with Colloidal Radiogold, *Amer. J. Physiol.* 164:822, 1951.
3. BEIERWALTES, W. H., JOHNSON, C. P. AND SOLARI, A. J.: *Clinical Uses of Radioisotopes*, W. B. Saunders Co., Philadelphia, 1956.
4. BOTSFORD, T. W., WHEELER, H. B., NEWTON, R. A. AND JACQUES, W. E.: Hypoplasia of Bone Marrow Associated with Radioactive Colloidal Gold Therapy, *J.A.M.A.* 151:788, 1953.
5. CHODOS, R. B. AND ROSS, J. F.: The Use of Radioactive Phosphorus in the Therapy of Leukemia, Polycythemia Vera and Lymphomas: A Report of 10 Years' Experience, *Ann. Int. Med.* 48:956, 1958.
6. CHRISTOPHERSON, W. M. AND BERG, H. F.: A Histopathological Study of Lymph Node Irradiated with Colloidal Au<sup>198</sup>, *Cancer*, 8:1261, 1955.
7. FERGUSON, J. H., ANDREWS, G. A. AND BRUCER, M.: Blood Clotting Studies on Dogs Internally Irradiated with Radiogold, *Proc. Soc. Exper. Biol. and Med.* 80:541, 1952.
8. FLIEDNER, T. AND STODTMEISTER, R.: Zur Knochenmarkwirkung von Radio-Gold (Au<sup>198</sup>), *Strahlentherapie* 101:289, 1956.
9. HAHN, P. F. AND SHEPPARD, C. W.: Selective Radiation Obtained by the Intravenous Administration of Colloidal Radioactive Isotopes in Diseases of the Lymphoid System, *So. Med. J.* 39:558, 1946.
10. HAHN, P. F., JACKSON, M. A. AND GOLDIE, H.: Liver Cirrhosis with Ascites Induced in Dogs by Chronic Massive Hepatic Irradiation with Radioactive Colloidal Gold, *Science*, 114:303, 1951.
11. HAHN, P. F., ed.: *A Manual of Artificial Radioisotope Therapy*, Academic Press Inc., New York, 1951.
12. HAHN, P. F., ed.: *Therapeutic Use of Artificial Radioisotopes*, John Wiley and Sons, Inc., New York, 1956.
13. HAHN, P. F.: Proc. of the Internat'l. Conf. on Peaceful Uses of Atomic Energy, New York, United Nations, Vol. 10, pp. 117-121, 1956.
14. HAHN, P. F., JACKSON, A. H., STAGGERS, F. E., JACKSON, M. A. AND CAROTHERS, E. L.: Acute Radiation Death of Dogs Receiving a Single Massive Dose of Intravenous Radioactive Gold, *Amer. J. Roent.* 75:1139, 1956.
15. KENNEY, J. M., MARINELLI, L. D. AND CRAVER, L. F.: The Treatment of Lymphosarcoma with Radioactive Phosphorus: A Preliminary Report, *Amer. J. Roent.* 47:217, 1942.
16. KNUTSSON, F. AND NORIN, T.: Localization and Effect of Injected Radioactive Gold in the Treatment of Malignant Tumors. 2., *Acta Path. et Microbiol. Scand.* 38:447, 1956.
17. KOLETSKY, S. AND GUSTAFSON, G.: Liver Damage in Rats from Colloidal Gold, *Lab. Invest.* 1:312, 1952.
18. LAWRENCE, J. H.: Proc. of the Internat'l. Conf. on Peaceful Uses of Atomic Energy, New York, United Nations, Vol. 10, pp. 142-151, 1956.
19. LAWRENCE, J. H. AND DONALD, W. G., JR.: Giant Follicular Lymphoblastoma: Its Treatment with Radioisotopes, *Ann. Int. Med.* 49:1, 1958.

20. MELLGREN, J., KNUTSSON, F. AND NORIN, T.: Localization and Effect of Injected Radioactive Colloidal Gold ( $Au^{198}$ ) in the Treatment of Malignant Tumors. 1., *Acta. Path. et Microbiol. Scand.* 34:393, 1954.
21. Recommendations of the Internat'l. Commission on Radiological Protection, ICRP Publication 2, Pergamon Press, N. Y., 1959.
22. REINHARD, E. H., MOORE, C. V., BIERBAUM, O. S. AND MOORE, S.: Radioactive Phosphorus as a Therapeutic Agent. A Review of the Literature and Analysis of the Various Blood Dyscrasias, Lymphomas and Other Malignant Neoplastic Diseases, *J. Lab. and Clin. Med.* 31:107, 1946.
23. ROOT, S. W., ANDREWS, G. A., KNISELEY, R. M. AND TYOR, M. P.: The Distribution and Radiation Effects of Intravenously Administered Colloidal  $Au^{198}$  in Man, *Cancer*, 7:856, 1954.
24. ROSENBERG, S. A., DIAMOND, H. B., JASLOWITZ, B. AND CARVER, L. F.: Lymphosarcoma, A Review of 1269 Cases, *Med.* 40:31, 1961.
25. SCHOOLMAN, H. M. AND SCHWARTZ, S. P.: Aplastic Anemia Secondary to Intravenous Therapy with Radiogold: Report of a Case, *J.A.M.A.* 160:461, 1956.
26. SEAMAN, W. B. AND POWERS, W. F.: Studies on the Distribution of Radioactive Colloidal Gold in Regional Lymph Nodes Containing Cancer, *Cancer* 8:1044, 1955.
27. SHEPPARD, C. W., WELLS, E. B., HAHN, P. F. AND GOODELL, J. P. B.: Studies of the Distribution of Intravenously Administered Colloidal Sols of Manganese Dioxide and Gold in Human Beings and Dogs Using Radioactive Isotopes, *J. Lab. and Clin. Med.* 32:274, 1947.
28. SHEPPARD, C. W., GOODELL, J. P. B. AND HAHN, P. F.: Colloidal Gold Containing the Radioactive Isotope  $Au^{198}$  in the Selective Internal Radiation Therapy of Diseases of the Lymphoid System, *J. Lab. and Clin. Med.* 32:1437, 1947.
29. STERNBRIDGE, V. A., KNISELEY, R. M. AND GIBBS, W.: Autoradiographic Distribution of Intravenous Colloidal Gold ( $AU^{198}$ ) in the Rat, *Lab. Invest.* 2:349, 1953.
30. THOMAS, C. G., JR.: Lymphatic Dissemination of Radiogold in the Presence of Lymph Node Metastases, *Surg., Gynec. and Obst.* 103:51, 1956.
31. TOCANTINS, L. M.: Progress in Hematology, Vol. 1, Grune and Stratton, New York, 1956, p. 151.
32. TRISTAN, T. A., RAVENTOS, A. AND CHAMBERLAIN, R. H.: Disseminated Histiocytosis X (Letterer-Sirwes Disease) Treated Unsuccessfully with Radioactive Colloidal Gold, *Cancer* 9:831, 1956.
33. WHEELER, B., JACKSON, M. A. AND HAHN, P. F.: Hematology of the Dog Following Intravenous Administration of Radioactive Colloidal Gold, *Amer. J. Physiol.* 166:323, 1951.