

Early Diagnosis of Metastatic Bone Cancer By Photoscanning With Strontium-85^{1,2}

N. David Charkes, M.D. and David M. Sklaroff, M.D.

Philadelphia

INTRODUCTION

Radiologic detection of metastatic tumor to bone depends in part upon the calcium content of bone. Inasmuch as 30-50 per cent of bone calcium must be altered before radiologic changes become apparent (1,2), it is clear that difficulties will be encountered in the early diagnosis of metastatic cancer to bone by means of x-ray examination alone.

Since the first reports of the use of gallium-72 to demonstrate areas of osteogenesis (3,4), interest in the use of radioisotopes for the detection of metastatic cancer to bone has increased. A comprehensive review of the clinical application of Ca-72 was given by Brucer and associates in 1953 (5), and subsequently other gamma-emitting radionuclides have been studied (6,7,8). Most recent work has centered on radiocalcium-47 (1.31 MeV) and radiostrontium-85 (.513 MeV), although Fluorine-18 (8) has also been employed successfully for bone tumor detection. There are several disadvantages to Ca-47 as a scanning agent: (1) its high-energy gamma necessitates the use of heavy shielding (9) not present in commercial scanners, and (2) high specific-activity Ca-47 is costly and is contaminated with Ca-45. Strontium-85 is more favorable as a scanning agent inasmuch as its gamma ray is readily collimated with existing equipment, and since it is reactor produced, its cost is not excessive.

The metabolism of strontium by bone is similar to that of calcium, although quantitative differences of considerable magnitude do occur in renal and gastrointestinal handling of the two elements (10,11). A considerable body of literature has accumulated concerning strontium metabolism in animals with regard to the problem of Sr-90 fallout, and much information is now available in man as well.

¹Presented at the 10th Annual Meeting, Society Nuclear Medicine, Montreal, Canada, June 27, 1963.

²From the Department of Radiology (Nuclear Medicine and Radiation Therapy), Albert Einstein Medical Center, Northern Division, Philadelphia, Pennsylvania.

The kinetics of strontium metabolism have been studied extensively by Bauer *et al.* (12), by Spencer (11,13) and by others (10,14), and abundant evidence is at hand which confirms the value of this nuclide as a tracer of calcium in human bone metabolism.

Calcium-47 has been shown to accumulate in areas of bone metastases in amounts greater than in normal bone (6,7,15) even prior to observable roentgenographic changes. Gynning *et al.* have confirmed these findings and have shown that Sr-⁸⁵ can also be demonstrated to localize to a greater extent in

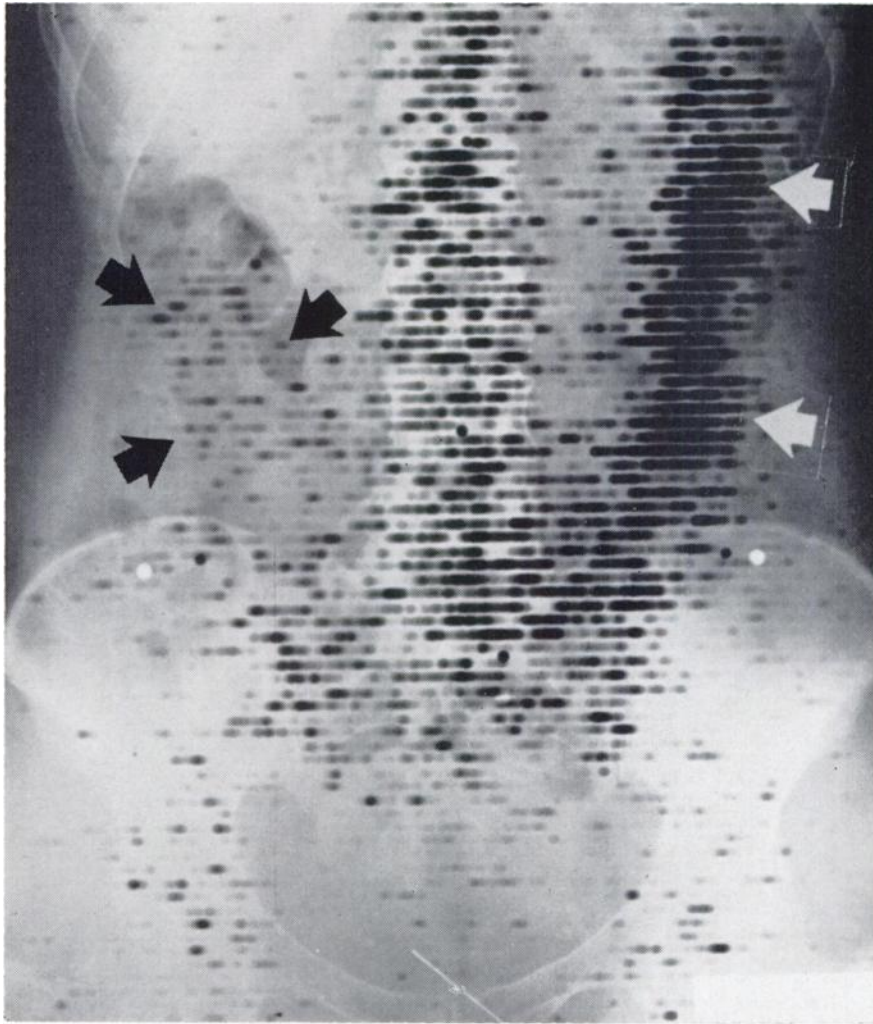

Fig. 1 This 36 year old female had an abdomino-perineal resection and colostomy 11 months previously for adenocarcinoma of the rectum, and recently developed back pain. X-rays were negative. Note Sr⁸⁵ deposition in vertebral column, sacrum, sacroiliac joints, acetabula, femoral heads, and colon (arrows). This pattern of distribution is normal. Scanned 4 days following 50 μ c of Sr⁸⁵

tumor-laden bone than in normal osseous tissue, even when x-rays of the involved part are apparently normal (16). It is known that radiostrontium accumulates to a considerable degree in osteogenic sarcoma and Ewing's tumor as well (17). Fleming and his associates were the first to utilize the photoscanning technique for the display of strontium deposition in human bone (18). Subsequently, Corey *et al.* have described a scanning method which utilizes a scaler with digital print-out rather than a count rate meter with digital and/or analog display on a photoscan (19). Sklaroff and Charkes have recently described the use of

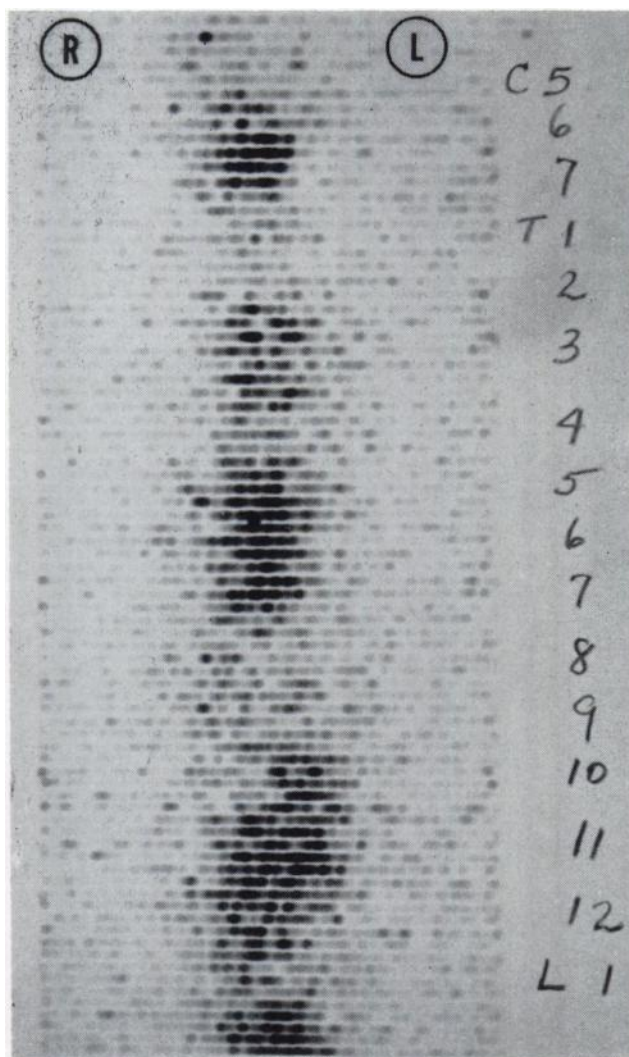


Fig. 2 Scan of dorsal spine of 42 year old female with history of radical mastectomy for carcinoma and pathologic fracture of left ischium. Note markedly increased Sr^{85} deposition in C-6, 7; T-3,5,6,7,10 through L-2. Patient had no pain and roentgenograms were negative at time of scan. Back pain later developed and responded to x-ray therapy.

the photoscan for the detection of metastatic cancer to bone and have demonstrated that early lesions (prior to observable roentgenographic changes) can be detected by this method (20). Existing commercial equipment was utilized, and bone biopsies were obtained in several cases to establish the validity of the technique.

The present report describes the use of the Sr-⁸⁵ photoscan for the detection of bone metastases in 90 patients with proven cancer and with suspected or demonstrable bone metastases. In many instances, confirmed by bone biopsy, the scan revealed areas of tumor-laden bone although roentgenograms of the same parts were interpreted as normal.

METHOD

Strontium-85 was obtained from Oak Ridge¹ in the form of the nitrate, with specific activity of 2,720 mc/gm or greater. Purity was greater than 98 per cent, with less than 1 per cent Sr-⁸⁹. Sr-⁸⁵ has a half-life of 64 days and decays by electron capture to Rubidium-85, emitting a single gamma photon of 0.513 MeV in the process. There is no associated particulate emission, and the internal conversion coefficient is less than 1 per cent. As a result, the radiation dose to bone from a 50 μ c dose is primarily from the gamma photons in bone. We have calculated this dose to be approximately 0.80 rads, and the whole body dose 0.34 rads.

We have employed the Picker Magnascanner exclusively for these studies. This instrument is equipped with a 3 \times 2 inch sodium iodide (TA) crystal, 19-hole focusing collimator, and pulse height analyzer.

Background cut-off level is determined by positioning the probe over a non-osseous portion of the body, such as the loin, and the activity of a normal joint (*e.g.*, sacroiliac) establishes the maximum count level. Impulses between these limits are appropriately enhanced. These settings assure visualization of normal radiostrontium distribution, on which tumor "hot-spots" are engrafted.

Display is both on Teledeltos paper and on clear x-ray film (photoscan). It is more convenient to read the photoscan but both read-out methods are employed for diagnosis.

Fifty microcuries of Sr-⁸⁵ are administered intravenously and the patient is scanned in 24-48 hours. This allows up to fifty per cent of the body strontium content, which has not been deposited in bone, to be excreted by the kidneys and bowel (7,10,21) and therefore lowers the background activity. Satisfactory scans may be performed within 45 minutes of injection, however (21), because of the rapid accretion rate of bone (14,21). Prior to scanning the pelvis or lumbar spine thorough bowel cleansing with laxatives and enemas is mandatory. Even with these precautions, count rates over areas of active osteogenesis are well below 1000 cpm, and frequently are no greater than 50 per cent of background (200-400 cpm). It is, therefore, necessary to employ slow scanning speeds (10 to 16 cm/min) in order to achieve satisfactory scans. Localization roentgenograms are obtained by use of orthoradiograms at a 6-foot distance.

¹Through E. R. Squibb & Sons, Inc.

TABLE I
CORRELATION OF SR-⁸⁵ SCAN AND ROENTGENOGRAM

<i>Roentgenogram</i>	<i>Sr-⁸⁵ Scan</i>	
	<i>Pos.</i>	<i>Neg.</i>
Positive	35	4
Negative	11	40

RESULTS

To date, 90 patients with proven cancer and suspected or proven bone metastases have been scanned with Sr-⁸⁵. With the dose employed, 50 μ c, osteogenic activity can normally be demonstrated in the vertebral column, the ends of long bones, and in certain joints such as the sacro-iliac articulation, the acetabulum, and the glenoid fossa (Fig. 1). An appreciation of the pattern of normal Sr-⁸⁵ localization is therefore necessary in order to evaluate abnormal isotope accumulation.

In 35 patients, both the x-ray and the scan were positive for tumor infiltration (Table I). In most patients there was close correspondence between the two techniques, but in certain instances the scan appeared to demonstrate more extensive disease than was apparent on x-ray (Fig. 2). Bone biopsies of 12 of these patients all revealed the presence of tumor in the areas found to be positive on the scan. It is therefore apparent that the Sr-⁸⁵ scan is capable of detecting metastatic cancer to bone prior to observable roentgenographic changes.

TABLE II
CORRELATION OF SR-⁸⁵ CONTENT OF BONE WITH PHOTOSCAN

<i>Patient</i>	<i>Site of Primary</i>	<i>Time to Biopsy (days)</i>	<i>Scan</i>	<i>Histo-pathology*</i>	<i>Sr-⁸⁵ Content of Bone</i>	
					<i>mμc/gm**</i>	<i>% Administered Dose x 10³/gm</i>
Ad	Breast	11	+	Tumor	15.0-77.6	34.5-178.0
Go	Eosinoph. Granuloma	6	+	Tumor	6.88	36.7
Sh	Breast	6	+	Tumor	9.14	20.0
Ni	Colon	13	+	Tumor	4.82	11.1
Le	Colon	9	+	Tumor	2.09	4.6
We	Lung	7	Neg.	Tumor	0.99	2.1
Zo	Colon	4	Neg.	Neg.	0.67	1.4

*All tumors same as primary

**At time of biopsy

In 11 patients the scan was positive and the roentgenogram negative. Bone biopsies in four of these patients also revealed the presence of metastatic cancer in each case (Figs. 3, 4).

In 40 patients with negative roentgenograms but with pain suspected of being due to metastatic cancer, the Sr-⁸⁵ scan did not reveal abnormal isotope distribution. Bone biopsy was obtained in one of these patients.

In six patients the scan failed to reveal lesions that could be demonstrated roentgenographically. Five of these six patients had bone biopsies performed. Three of these cases were reticulum cell sarcoma, one metastatic carcinoma of the breast, and one anaplastic carcinoma of the lung. The sixth patient, who was not biopsied, had had cancer of the breast with metastases to other parts of the body.

In seven of the 14 patients in this series who underwent bone biopsy, specimens of bone and tumor were available for determination of Sr-⁸⁵ content (Table II). In patients in whom the scan was positive, at least .002 μ c of Sr-⁸⁵ per gram of bone was deposited, which amounted to 0.0046 per cent of the administered dose

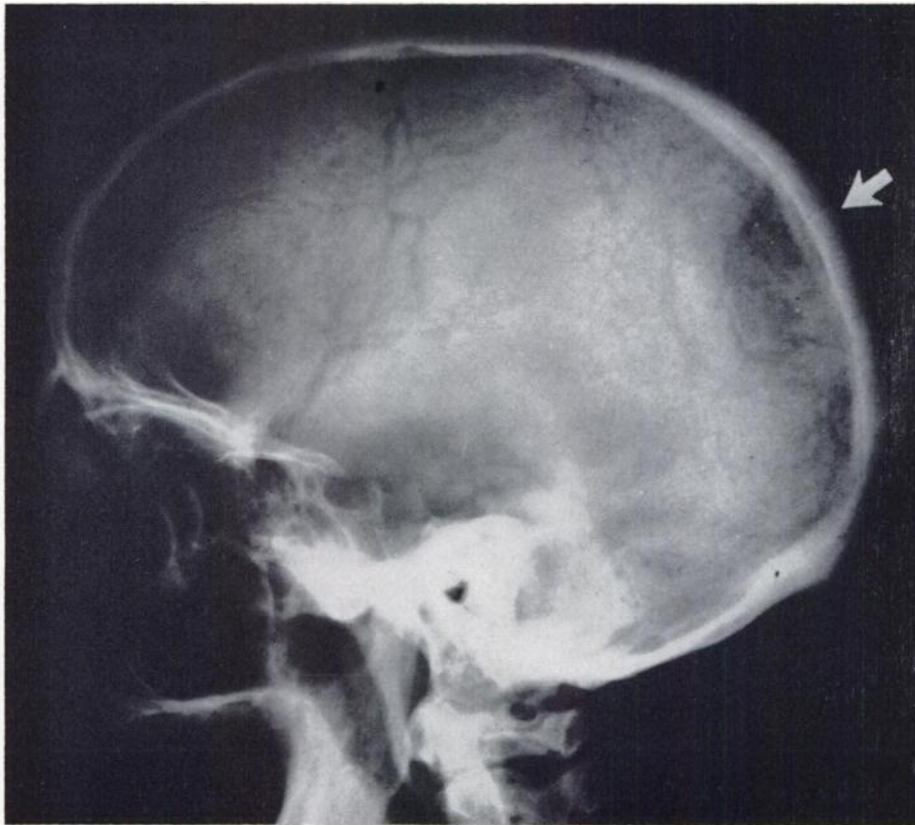


Fig. 3a. Skull film of 57 year old male who noted a mass in left occipital area. Biopsy revealed a meningioma, and roentgenogram (above) showed typical but minimal changes characteristic of this tumor (arrow).

per gram of bone. In one patient multiple biopsies were taken, and levels up to $40\times$ this concentration were found. In another patient, with a small osteolytic rib lesion due to metastatic anaplastic carcinoma of the lung and negative scan, the Sr^{85} content of bone was $.001 \mu\text{C}/\text{gm}$, which amounted to .0021 per cent of the administered dose/gm.

One patient with metastatic carcinoma of the colon was evaluated for back pain by means of Sr^{85} photoscanning. A suspicious lesion in or about the right wing of the ilium was noted on scan, and a bone biopsy was obtained. The Sr^{85} content of this bone was less than had been found in any other patient (Table II) and the histopathologic report on this specimen revealed that no tumor cells were seen. Review of the photoscan demonstrated that the cecum overlay the ilium in this area, and a repeat scan revealed that the "lesion" had disappeared. This patient had not been prepared by bowel cleansing prior to scanning, so that fecal strontium had been detected. Subsequently, with the precaution of proper preparation of the patient in every case, this type of problem has been greatly minimized.

In no case where tumor was counted in the absence of bone was any strontium-85 detected (excluding osteogenic sarcoma).

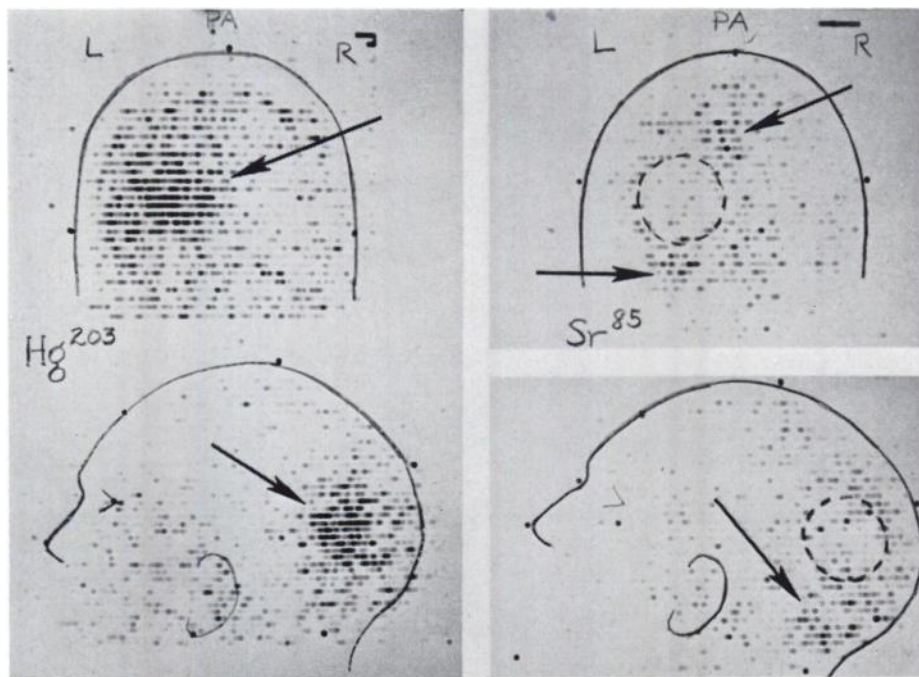


Fig. 3b. Same patient as figure 3a. (left): Scan with Hg^{203} chlormerodrin reveals marked uptake by tumor (arrows). (right): Strontium-85 scan shows extensive uptake by cranial vault in left parieto-occipital area (arrows). Corresponding Hg^{203} chlormerodrin localization has been drawn in with dotted lines. Subsequent neurosurgical exploration confirmed the extensive invasion of bone by the tumor as depicted on the strontium scan.

In order to evaluate the comparable size of tumor lesions on scan and x-ray, a phantom study was undertaken. A veal leg was sawed in a frontal plane, and $\frac{3}{8}$ " holes drilled in one half. Small test tubes containing Sr-⁸⁵ in amounts comparable to those found in certain metastases were inserted in the holes, and the remaining half of the veal leg was replaced in order to simulate normal bone absorption and scatter. The leg was then scanned using settings comparable to those employed clinically, and a roentgenogram was taken (Fig. 5). The results indicated that the scan volumes closely approximated the known diameters of the solutions, and that therefore the resolution of the method was good. This can also be demonstrated clinically, as in the close approximation of a rib scan to a pathologic fracture with callus formation (Fig. 6).

DISCUSSION

The results of this study confirm the reports of other investigators (7, 15, 16,19) that Sr-⁸⁵ is capable of detecting metastatic cancer to bone. The advantages

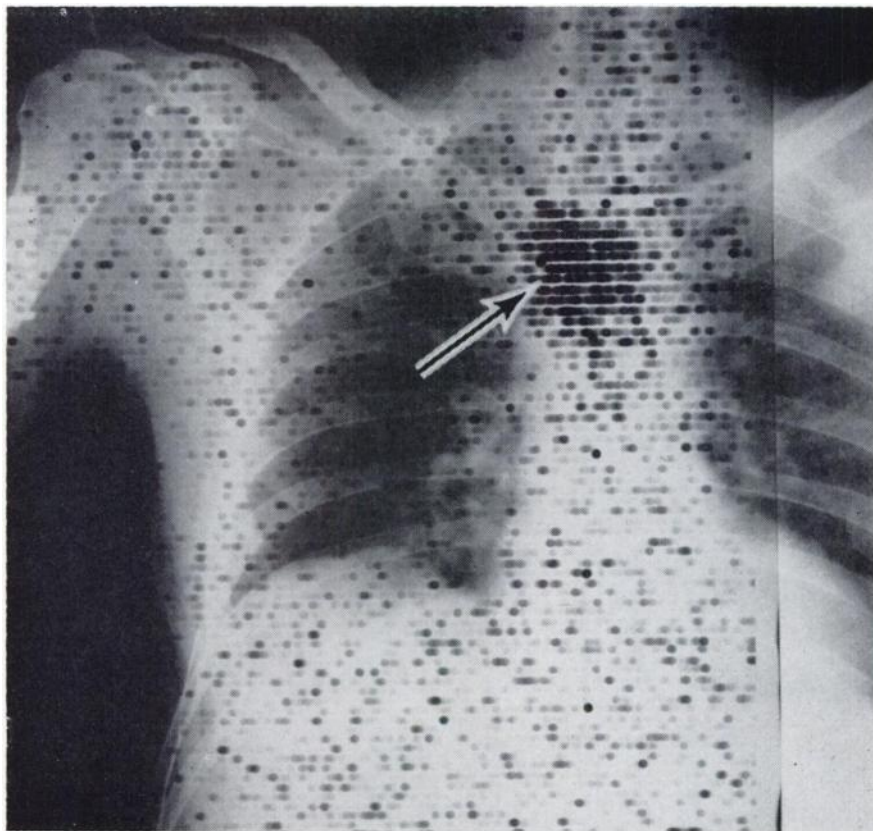


Fig. 4 This 54 year old male underwent colon resection three months previously for carcinoma, and recently developed pain in sternum. Roentgenograms were negative. Sr-⁸⁵ scan shows marked accumulation of isotope in body of sternum (arrow). Bone biopsy revealed metastatic adenocarcinoma. Note slightly increased strontium deposition in right shoulder joint (normal).

of the photoscanning method stem from the method of display, since other types of scanning or external counting (7,15,16,19) are equally successful. Inasmuch as the method we have described utilizes currently available commercial equipment, its applicability is universal.

The bone biopsy method which we have employed to verify histologically abnormalities of Sr^{85} deposition on photoscan lends added weight to the validity of the technique. Previous investigators have relied upon subsequent roentgenographic changes for substantiation (7,16). Although this latter method is of value for long-range studies concerned with evaluation of the technique, we have found the photoscanning method to be of such immediate applicability that it has already become a standard procedure in our institution. Not only is it of value in diagnosis, but the radiation therapist has been able to plan his treatment portals more effectively as a result of this added knowledge concerning tumor location.

Negative scans have been obtained in four patients with positive x-rays and

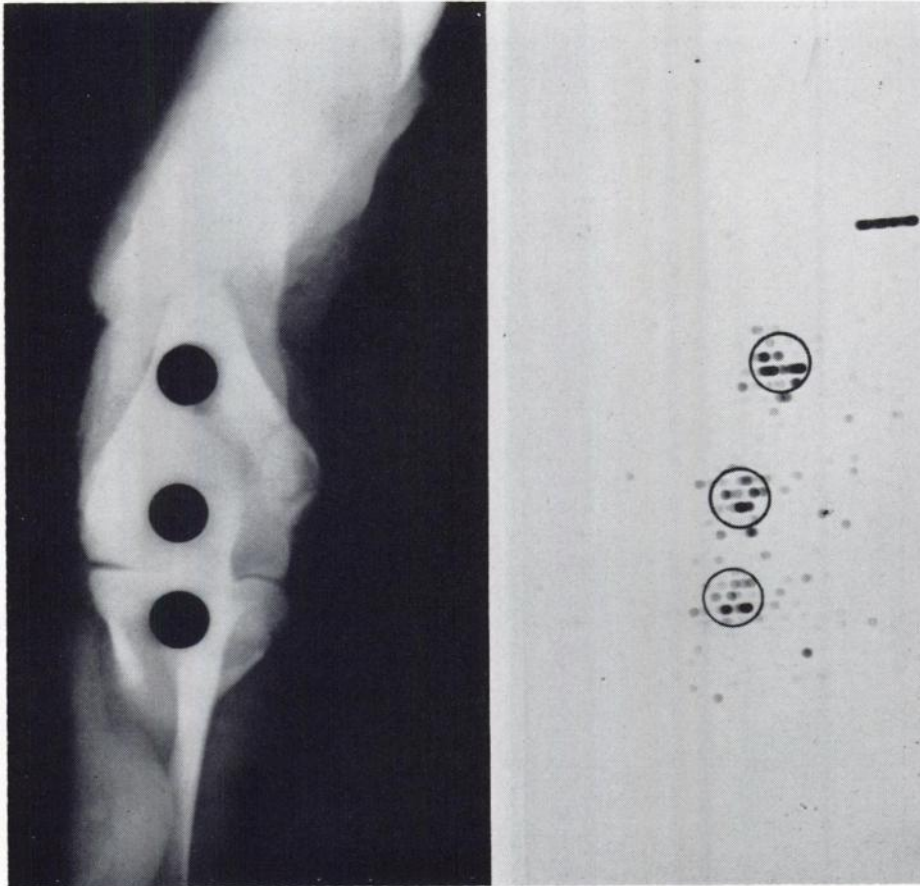


Fig. 5 Roentgenogram (left) of veal leg containing $\frac{3}{8}$ " holes, in which test tubes of Sr^{85} solutions have been placed. (Right). Photoscan of preparation superimposed on test tube outline. Sr^{85} solutions contain (top to bottom): $0.20 \mu\text{c}$ in 5 ml; $0.16 \mu\text{c}$ in 4 ml; and $0.12 \mu\text{c}$ in 3 ml.

in two additional patients with other scan-positive areas. It is of interest that all three of our patients with reticulum cell sarcoma fell into this category. In one other patient, a small, osteolytic rib metastasis was missed, but we have not to date found a negative scan in any area of pathologic fracture with callus formation, whether in a rib or elsewhere. With the dose employed (50 μc) and the line spacing which we routinely use (0.4 cm) it is possible to miss certain small areas such as osteolytic rib metastases unless fracture with callus formation has occurred. Osteoblastic reaction has been noted in wide variety of metastatic tumors and in primary bone tumors as well. Two patients with metastatic thyroid carcinoma to bone had very little osteogenic reaction.

It is of interest that both osteolytic and osteoblastic metastases may give positive scans, although all of our negative scans were obtained in patients with osteolytic lesions. It is apparent that the roentgenogram, which depicts the net local calcium balance, may not reflect increased accretion and resorption when they occur simultaneously. The scan therefore supplements the roentgenogram by depicting areas of augmented osteogenesis, and the combination of the two techniques affords maximum knowledge of local bone metabolism.

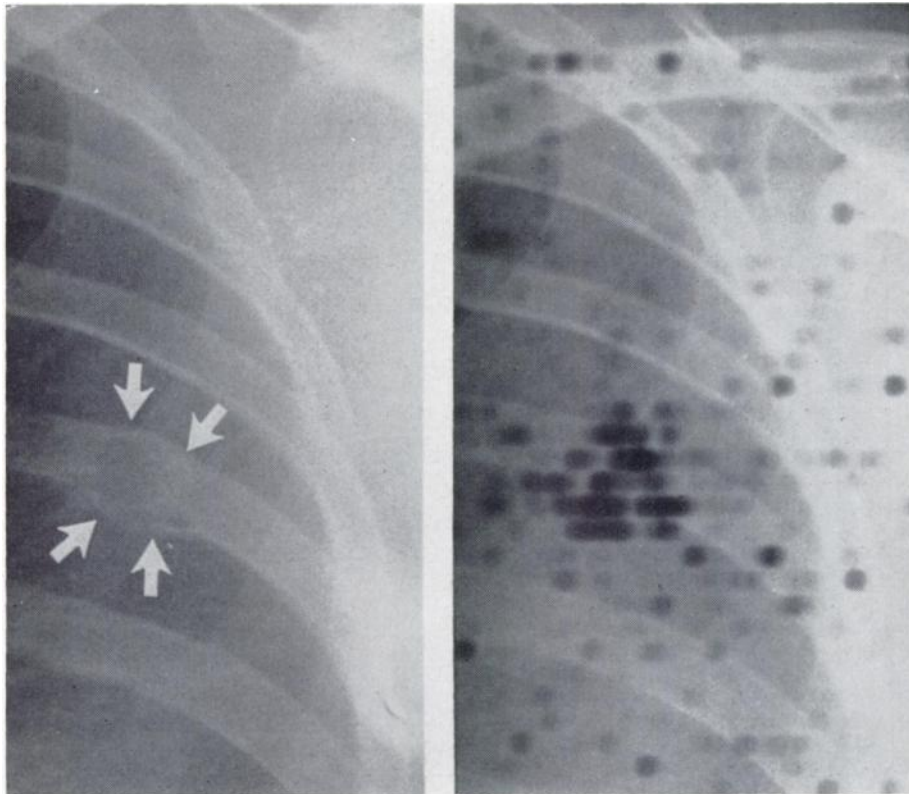


Fig. 6 46 year old female with widespread metastatic breast cancer to bone. (left): Pathologic fracture of left 6th rib with callus formation. (Right): Sr-⁸⁵ scan superimposed on roentgenogram. Note close correspondence of scan volume and that of fracture site.

The bone dose from 50 μc of Sr^{85} has been calculated by Fleming and associates as approximately 2.3 rads. Inasmuch as the bone dose (and the body dose as well) is primarily from the gamma photons (a 13 kev x-ray is also emitted in Sr^{85} decay), it is apparent that estimation of the geometry factor g will play an important role in calculation of the radiation dose. Fleming *et al.* have apparently used a whole-body g of approximately 125. Calculation of the bone dose with estimated values for bone composition given by the International Commission on Radiological Protection (22) gives a radiation dose of 0.80 rads per 50 μc . It is apparent, therefore, that the calculation of Fleming *et al.* represents a maximum dose, whereas ours is a minimum dose.

SUMMARY

Photoscans of bone utilizing 50 μc of strontium-85 have been made in 90 patients with cancer, with proven or suspected metastases to bone. In 11 patients the scan was positive and the x-ray negative, and in 75 other patients there was good agreement between the scan and the roentgenogram. The scan, however, frequently showed greater involvement than was apparent on x-ray. These results were confirmed by bone biopsy in 14 patients. Phantom studies were carried out which indicated that there is good correlation between the scan and known isotopic volumes within bone. Bone tissue counts of radiostrontium content were also correlated with biopsy findings and lend further support to the validity of the method.

It is therefore clear that the Sr^{85} photoscanner can detect early metastatic cancer to bone prior to observable roentgenographic changes. Not only have these scans been of value in diagnosis, but they have allowed the radiation therapist to plan treatment portals more effectively.

ADDENDUM

Since this paper was submitted for publication, a negative Sr^{85} scan was obtained in a patient with widespread osteoblastic metastases from breast carcinoma on roentgenogram. The disease was stationary 7 years post-operatively and the patient asymptomatic. No systemic therapy had been administered. Similar findings have been previously reported with calcium-47 (Greenberg, E., in discussion of "Sr-85 and Ca-47 in the Study of Bone" by G.C.H. Bauer, in *Radioisotopes and Bone*, F. C. McLean, P. Lacroix, and A. M. Budy, eds. Philadelphia, 1962, F. A. Davis, p. 102).

ACKNOWLEDGEMENTS

We wish to thank E. R. Squibb & Sons, Inc., for their generous support of this study, through Dr. Paul Numerof.

The technical assistance of Mrs. Tina Helock and Miss Barbara Cravitz is gratefully acknowledged.

BIBLIOGRAPHY

1. BABAIANTZ, L.: Les Osteopathies Arthrophiques. *J. Radiol. Electrol.* **29**:333, 1948.
2. SNAPPER, I.: Bone Diseases in Medcial Practice, 1957, Grune & Stratton, New York and London.
3. DUDLEY, H. C. AND MADDOX, G. E.: Deposition of Radiogallium (Ga-⁷²) in Skeletal Tissue. *J. Pharm. & Experimenatal Ther.* **96**:224, 1949.
4. DUDLEY, H. C., IMRIE, G. W., JR., AND ISTOCK, J. T.: Deposition of Radiogallium (Ga-⁷²) in Proliferating Tissues. *Radiology* **55**:571, 1950.
5. BRUCER, M., ANDREWS, G. A., AND BRUNER, H. D.: A Study of Gallium-72. *Radiology* **61**:534, 1953.
6. COREY, K. R., KENNY, P., GREENBERG, R., PAZIANOS, A., PEARSON, O. H., AND LAUGHLIN, J. S.: The Use of Calcium-47 in Diagnostic Studies of Patients with Bone Lesions. *Am. J. Roentgenol., Rad. Ther., & Nuclear Med.* **85**:955, 1961.
7. BAUER, G. C. H., AND WENDEBERG, B.: External Counting of Ca-⁴⁷ and Sr-⁸⁵ in Studies of Localized Skeletal Lesions in Man. *J. Bone & Joint Surg.* **41B**:558, 1959.
8. BLAU, M., NAGLER, W., AND BENDER, M. A.: Fluorine-18: A New Isotope for Bone Scanning. *J. Nuclear Med.* **3**:322, 1962.
9. LAUGHLIN, J. S., BEATTIE, J. W., COREY, K. R., ISAACSON, A., AND KENNY, P.: Total Body Scanner for High Energy Gamma Rays. *Radiology* **74**:108, 1960.
10. DOW, E. C., AND STANBURY, J. B.: Strontium and Calcium Metabolism in Metabolic Bone Diseases. *J. Clin. Invest.* **39**:885, 1960.
11. SPENCER, H., LASZLO, D., AND BROTHERS, M.: Strontium-85 and Calcium-45 Metabolism in Man. *J. Clin. Invest.* **36**:680, 1957.
12. BAUER, G. C. H., AND RAY, R. D.: Kinetics of Strontium Metabolism in Man. *J. Bone & Joint Surg.* **40A**:171, 1958.
13. COHN, S. H., SPENCER, H., SAMACHSON, J., AND ROBERTSON, J. S.: The Turnover of Strontium-85 in Man as Determined by Whole-Body Counting. *Radiation Res.* **17**:173, 1962.
14. MACDONALD, N. S.: The Radioisotope Osteogram-Kinetic Studies of Skeletal Disorders in Humans. *Clin. Orthopaedics* **17**:154, 1960.
15. BRADY, L. W., CROLL, M. N., STANTON, L., HYMAN, D., AND RUBINS, S.: Evaluation of Calcium-47 in Normal Man and its Use in the Evaluation of Bone Healing Following Radiation Therapy in Metastatic Disease. *Radiology* **78**:286, 1962.
16. GYNNING, I., LANCELAND, P., LINDBERG, S., AND WALDESKOG, B.: Localization with Sr-⁸⁵ of Spinal Metastases in Mammary Cancer and Changes in Uptake after Hormone and Roentgen Therapy. *Acta Radiolog.* **55**:119, 1961.
17. TREADWELL, A. DEG., LOW-BEER, V. A., FRIEDEL, H. L., AND LAWRENCE, J. H.: Metabolic Studies on Neoplasm of Bone with the Aid of Radioactive Strontium. *Am. J. Med. Sci.* **204**:521, 1942.
18. FLEMING, W. H., MCILRAITH, J. D., AND KING, E. R.: Photoscanning of Bone Lesions Utilizing Strontium-85. *Radiology* **77**:635, 1961.
19. COREY, K. R., KENNY, P., GREENBERG, E., AND LAUGHLIN, J. S.: Detection of Bone Metastases in Scanning Studies with Calcium-47 and Strontium-85. *J. Nuclear Med.* **3**:454, 1962.
20. SKLAROFF, D. M., AND CHARKE, N. D.: Studies of Metastatic Bone Lesions with Strontium-85. *Radiology* **80**:270, 1963.
21. CHARKE, N. D., AND SKLAROFF, D. M., unpublished data.
22. Publication #2, International Commission on Radiological Protection, Report of Committee II on Permissible Dose for Internal Radiation. New York, 1959, Pergamon Press.