

Novel Tracers and Their Development for the Imaging of Metastatic Prostate Cancer*

Andrea B. Apolo^{1,2}, Neeta Pandit-Taskar^{3,4}, and Michael J. Morris^{1,2}

¹Genitourinary Oncology Service, Department of Medicine, Memorial Sloan-Kettering Cancer Center, New York, New York;

²Department of Medicine, Weill Medical College of Cornell University, New York, New York; ³Nuclear Medicine Service, Department of Radiology, Memorial Sloan-Kettering Cancer Center, New York, New York; and ⁴Department of Radiology, Weill Medical College of Cornell University, New York, New York

There are presently no accurate methods of imaging prostate cancer metastases to bone. An unprecedented number of novel imaging agents, based on the biology of the disease, are now available for testing. We reviewed contemporary molecular imaging modalities that have been tested in humans with metastatic prostate cancer, with consideration of the studies' adherence to current prostate cancer clinical trial designs. Articles from the years 2002 to 2008 on PET using ¹⁸F-FDG, ¹¹C-choline, ¹⁸F-choline, ¹⁸F-fluoride, ¹¹C-acetate, ¹¹C-methionine, and ¹⁸F-fluoro-5 α -dihydrotestosterone in patients with metastatic prostate cancer were reviewed. Although these studies are encouraging, most focus on the rising population with prostate-specific antigen, and many involve small numbers of patients and do not adhere to consensus criteria for clinical trial designs in prostate cancer. Hence, although many promising agents are available for testing, such studies would benefit from closer collaboration between those in the fields of medical oncology and nuclear medicine.

Key Words: prostate cancer; positron emission tomography; ¹⁸F-fluorodeoxyglucose; ¹¹C-choline; ¹⁸F-fluorocholine; ¹¹C-acetate; ¹¹C-methionine; ¹⁸F-fluoro-5 α -dihydrotestosterone

J Nucl Med 2008; 49:2031–2041

DOI: 10.2967/jnumed.108.050658

In the past several decades, understanding of the molecular biology of prostate cancer has expanded, particularly related to growth despite androgen-reducing agents and the transformation from a tumor cell dependent on prostate stroma to one that participates in bone metabolism (1,2). The identification of biologic targets not only has led to the introduction of novel therapies for prostate cancer but also has opened up new possibilities for imaging the dis-

ease. These biologic targets can be used to characterize underlying molecular biology of the tumor at a lesional level, assess the pharmacodynamics of targeted therapy, and assess clinical responses.

Such new imaging modalities are sorely needed for prostate cancer patients, particularly those with metastatic disease. Between 80% and 90% of prostate cancer patients with metastatic disease have involvement of the axial skeleton (3–6). Although contemporary data show an increasing proportion of soft-tissue lesions in prostate cancer patients with metastatic disease (4,5), bone metastases still continue to represent the predominant manifestation for most patients and the primary cause of morbidity and mortality. However, bone metastases are considered nonmeasurable by the Response Evaluation Criteria in Solid Tumors. The lack of accurate imaging modalities to directly, reproducibly, and effectively delineate bone metastases limits the clinical management of prostate cancer patients and the advancement of new therapies.

It is difficult to introduce and test any new agent in prostate cancer—whether it is a therapeutic drug or a novel tracer—because there is no gold standard imaging modality that can establish whether a drug is having an effect on the cancer, whether a tracer is actually detecting disease, or whether there has been a change in disease. As a result, designing clinical trials for prostate cancer is uniquely challenging (7,8). In addition to the difficulty of imaging prostate cancer, the disease itself has a heterogeneous clinical course, as do its patients, who face significant noncancer-related morbidities as well.

Faced with these challenges, the field has adopted a clinical-states framework for organizing the natural history of disease (Fig. 1). The model highlights the objectives of the intervention rather than the treatment itself. In addition, unlike traditional staging schema based on primary tumor characteristics, nodal status, and metastatic involvement at diagnosis, the model is not fixed but describes the entire disease course.

Leaders in prostate cancer clinical trials have developed state-specific consensus criteria for clinical trials, from eligibility criteria to outcome measures (9–11). These

Received Aug. 9, 2008; revision accepted Oct. 6, 2008.

For correspondence or reprints contact: Michael J. Morris, Genitourinary Oncology Service, 1275 York Ave., New York, NY 10065.

E-mail: morrism@mskcc.org

*NOTE: FOR CE CREDIT, YOU CAN ACCESS THIS ACTIVITY THROUGH THE SNM WEB SITE (http://www.snm.org/ce_online) THROUGH DECEMBER 2009.

No potential conflict of interest relevant to this article was reported.

COPYRIGHT © 2008 by the Society of Nuclear Medicine, Inc.

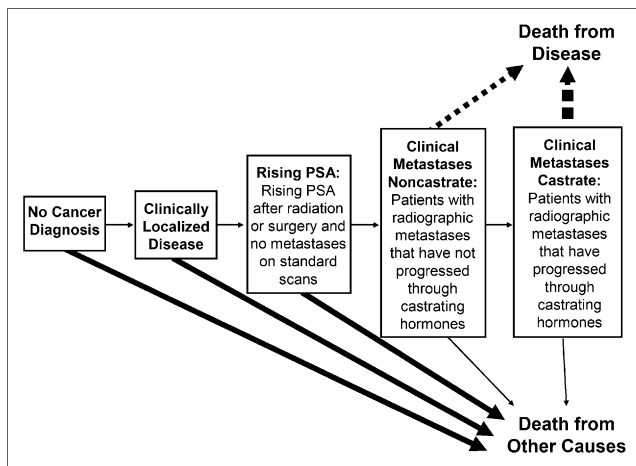


FIGURE 1. Clinical-states model of prostate cancer development and progression to define therapeutic objectives and to assess outcomes (11,41).

criteria, particularly for patients with metastatic disease, serve as guideposts for clinical trial design in order to optimize the likelihood of advancing active agents and abandoning those that fail to meet a predefined level of activity. These criteria represent the present yardstick by which trials are assessed in terms of having a well-defined question, a patient population that is controlled to answer that question, a statistical foundation that ensures that the answer is reliable, an intervention driven by the question, and outcome measures that indicate whether the intervention was effective. However, despite a burgeoning array of novel tracers and imaging agents, the approach to imaging studies has not similarly evolved.

This article reviews the field of nuclear imaging for prostate cancer as it stands today, examining the crucial design issues that define whether the modality, population, statistics, and endpoints support the data. Articles were identified by searching PubMed using the names of the individual tracers and “prostate cancer” as keywords. Articles with either little or no human experience or that were older than 6 y were excluded. In addition, for the sake of maintaining simplicity we omitted studies that were primarily duplicative of others. Of the articles examined, 18 contemporary studies were identified, involving 658 patients. One focused on initial staging, 8 focused on the population with castration-sensitive rising prostate-specific antigen (PSA), 1 on the castration-sensitive metastatic population, 2 on the castration-resistant metastatic population, and 6 on mixed populations. Fifteen were prospective, and 3 were retrospective. Seven trials had 20 or fewer patients.

THE CLINICAL-STATES MODEL AND IMAGING

The clinical-states model of prostate cancer, shown in Figure 1, provides a unified framework for categorizing prostate cancer patients throughout the course of the disease. These states include several categories of patients:

- those who have not yet been diagnosed with cancer but are at risk for it;
- those who have localized disease;
- those who have progressed after either surgery or radiation therapy and have rising PSA but no radiographic evidence of metastatic disease (rising PSA);
- those who have radiographically evident disease that is not resistant to medical or surgical castration (non-castration metastatic); and
- those who have metastatic disease that progresses despite castration (castration-resistant metastatic).

Although the clinical-states model is most frequently applied to therapeutic studies, it segregates patients into discrete populations for all avenues of investigation, whether the intervention is a drug, tracer, or biomarker. For imaging studies, the states define the objective of the imaging modality (Table 1). For patients with no cancer, the aim of an imaging modality is to distinguish cancer from benign tissue in either justifying a biopsy or estimating the risk that cancer will develop. For patients with localized disease, imaging can identify the extent of disease and can allow prognostication based on either disease distribution or the presence of biologic features that PET tracers (for example) may query. For patients (whether castrate or noncastrate) with a rising PSA, the aim is to distinguish whether disease is present in the treated prostate gland or bed or whether metastatic disease is present. For patients with metastatic disease, the aim of the study is to determine, first, whether patients can be selected for a particular therapy on the basis of the underlying biology or whether the presence of certain pathways can predict outcomes; second, to determine the pretreatment extent of disease; and third, to follow posttreatment effects from therapy.

TABLE 1
Goals of Imaging Modalities by Clinical State
in Prostate Cancer

Clinical state	Imaging objective
Initial prostate evaluation (no cancer diagnosis)	Distinguish cancer from benign tissue
Clinically localized disease	Identify extent of both localized and metastatic disease Prognosticate Identify treatment effects
Rising PSA (castration-sensitive and -resistant)	Identify extent of both localized and metastatic disease to guide therapy
Clinical metastases (castration-sensitive and -resistant)	Determine extent of metastatic disease Assess treatment response Identify patients with a particular biologic profile Prognosticate Determine pharmacodynamics of targeted therapy

CONVENTIONAL SINGLE-PHOTON IMAGING

Bone Scintigraphy

In prostate cancer, the most common site of metastatic disease is bone. The traditional imaging study used to image metastatic disease is the radionuclide bone scan. Bone scintigraphy uses ^{99m}Tc -labeled methylene diphosphate that is incorporated into hydroxyapatite, the principal component of bone cortex. However this is a nonspecific agent. Although sites of disease can be detected with high sensitivity, scintigraphy does not allow for direct visualization of tumor, and therefore the size of a lesion seen on a bone scan does not capture the dimensions of the cancer. Anatomic changes may persist long after the viable tumor is no longer present, therefore skewing the early assessment of response to treatment. Also, the flare phenomenon can be seen in up to 20% of patients (12–14). Anatomic imaging such as plain films and CT are similarly nonspecific and are unable to measure true osseous disease and distinguish bone healing from injury due to the presence of sclerosis.

A highly discriminating nomogram can be used to select those patients for bone scanning who are at higher risk and are more likely to show positive findings on the scan. Omitting scans in low-risk patients could substantially reduce the number of scans ordered (15). Although bone scintigraphy is an imperfect, albeit traditional, method for bone disease detection, it can capture objective clinical data with new methodologies. The bone scan index is a reproducible quantitation of active marrow involved with metastatic disease as detected by bone scintigraphy (16). The index can be used to identify patients with distinct prognoses for stratification in clinical trials. Posttreatment changes in bone scan index results may also help predict for survival (17,18).

Targeting of Prostate-Specific Membrane Antigen (PSMA)

ProstaScint (capromab pendetide; EUSA Pharma) consists of an intact murine monoclonal antibody, 7E11-C5.3, to which a linker chelator (GYK-DTPA-HCL) is bound, labeled with ^{111}In . Molecules targeting PSMA hold the potential of being both an imaging modality and a therapeutic agent. PSMA is expressed in almost all prostate cancer cells, from primary to metastatic disease, and appears to be maximally expressed after androgen withdrawal (19–22). PSMA has been used for several treatment strategies, including those involving radioisotope and chemo-conjugated antibodies (23–26). As imaging agents, antibodies can localize to tumor and thereby distinguish noncancer-related abnormalities from tumor-related. The overall sensitivity and specificity of detecting disease using capromab pendetide has varied in reported studies (27–31). These studies demonstrated average sensitivities of 60%, specificities of 70%, positive predictive values of 60%, and negative predictive values of 70%. In a metaanalysis, ^{111}In -labeled capromab pendetide studies in 2,154 patients from

15 institutions were analyzed. The overall sensitivity for detection of tumor in biopsy-proven primary carcinoma was 80%. The sensitivities ranged from 75% to 99% because of significant interreader variability. Ironically, antibody imaging is limited by its ability to detect viable disease. This may be related to the fact that the antibody binds to the intracellular part of PSMA and hence detects only necrotic tissue. J591, an antibody that detects the extracellular domain of PSMA, has been studied. These studies have demonstrated antibody localization to known disease (24,33). However, this antibody has not been extensively studied as an imaging agent.

PET

PET has the potential to be a noninvasive, functional imaging test of choice for detecting new bone and soft-tissue metastasis and for assessing new therapies.

Imaging Using ^{18}F -FDG

^{18}F -FDG PET is the most studied physiologic tracer in prostate cancer. Because uptake of ^{18}F -FDG correlates with PSA levels and PSA velocity, ^{18}F -FDG PET may be used as a measure of tumor metabolism or aggressiveness (34). ^{18}F -FDG has low sensitivity in the primary staging of prostate cancer and poor detection of abdominopelvic nodes because of excretion of tracer in ureters, bladder, and bowel.

Various studies with ^{18}F -FDG PET in patients with metastatic prostate cancer suggest that it does not effectively evaluate undetectable serum PSA but is more effective in staging metastatic prostate cancer in untreated patients who have had an incomplete response to therapy or a rising PSA level despite treatment (35,36). Assessment of extracapsular and nodal involvement in the pelvis and distant metastasis is also limited. In monitoring response to therapy, ^{18}F -FDG PET may be most useful in patients with aggressive or hormone-refractory disease (35,37).

Although several studies are evaluating the use of ^{18}F -FDG in prostate cancer (38), this review focuses on 4 studies of prostate cancer patients as outlined in Table 2. Two of these, by Chang et al. (39) and Schöder et al. (40), are retrospective, whereas the studies of Morris et al. (35,37) are prospective. The 2 retrospective trials focus on patients in the clinical state of rising PSA.

Rising-PSA patients are defined by consensus as those who have received definitive local therapy with radical prostatectomy or radiation therapy or both but now have rising PSA (41). By definition, these patients do not have detectable metastatic disease on standard imaging modalities. The rising-PSA population is an attractive subset of patients to study in diagnostic imaging trials because they represent a population that is potentially curable if managed early. Unfortunately, because these patients have no evidence of disease on routine imaging, there are no standard radiographic correlates by which to assess PET findings.

TABLE 2
Studies of ¹⁸F-FDG Radiologic Tracer in Metastatic Prostate Cancer

Author and year	<i>n</i>	Clinical state	Study	Purpose and endpoint	Statistical method	Conclusion
Schöder et al. (40), 2005	91	Rising PSA	Retrospective	Purpose: disease detection (local, nodal, metastatic) Endpoints: Histopathology Decrease in PSA after irradiation to primary site Lesions assessed with CIM ^a Follow-up CIM	True-positive by binary fashion	True-positive, 31% (28/91)
Morris et al. (37), 2005	22	Metastatic castration-resistant	Prospective	Purpose: outcome measure of treatment Endpoints: Lesions assessed with CIM ^a New lesions on PET Patient followed until POD or death Changes in SUV and PSA with treatment	Data analysis at 0, 4, and 12 wk of treatment Test of discordance	PET and clinical status correlated 4 wk, 91% 12 wk, 94%
Chang et al. (39), 2003	24	Rising PSA	Retrospective	Purpose: disease detection (nodal) Endpoint: histopathology	Sensitivity, specificity	Sensitivity, 75% (12/16) Specificity, 100%
Morris et al. (35), 2002	17	Metastatic castration-sensitive and -resistant	Prospective	Purpose: disease detection (bone, soft tissue) Endpoints: Lesions assessed with CIM ^a Follow-up CIM ^a	Lesion-based matched-pair data	Bone lesion, 71% seen on both PET and BS Soft-tissue lesion, 39% seen on both PET and CT/MRI

CIM = conventional imaging modality; POD = progression of disease; SUV = standardized uptake value; BS = bone scan.

Schöder et al. (40) examined prostate cancer patients with rising PSA using ¹⁸F-FDG PET. Images were interpreted using the following standard of reference for verification: a positive biopsy result, a decrease in PSA after irradiation to the primary site, the development of a detectable lesion in the primary site as seen on follow-up conventional imaging studies, and an increase in lesion size as seen on follow-up imaging or concurrent other imaging studies within 90 d of PET. ¹⁸F-FDG PET was true-positive in 31%. However, the definition of “true-positive” in this study was flawed. First, if a patient has a concurrent standard imaging modality revealing the presence of distant disease, then such a patient does not meet the definition of one who is in the rising-PSA clinical state. Such patients have outright metastatic disease. Also, a posttreatment PSA decline after radiation does not preclude the possibility of undetected metastatic disease and is not a validated endpoint for ruling out systemic disease or survival.

In a retrospective study, Chang et al. (39) selected patients with rising PSA levels to detect metastatic pelvic

lymph nodes after definitive local therapy with radical prostatectomy or radiation therapy. Patients with rising PSA had negative or equivocal results on bone scanning and CT before enrollment. PET findings were correlated with pathologic evaluation from a lymph node dissection, the gold standard for disease confirmation. At the sites of pathologically proven metastases, increased ¹⁸F-FDG uptake suggestive of metastatic disease was found in 12 of 16 (75%) patients.

Morris et al. (35) first examined 17 patients with castration-sensitive and -resistant metastatic disease and found that ¹⁸F-FDG PET can discriminate active osseous disease from scintigraphically quiescent lesions in patients with progressive metastatic prostate cancer. Morris et al. (37) then studied the outcome measures of chemotherapy-treated patients using ¹⁸F-FDG PET in castration-resistant disease and compared these with posttreatment alterations in PSA and standard imaging. Twenty-two patients undergoing chemotherapy for castration-resistant metastatic prostate cancer were studied. Changes in ¹⁸F-FDG PET standardized

uptake value were compared with PSA and standard imaging. After 4 wk of chemotherapy, PET and PSA were in agreement in 86% of cases; in 91% of cases, ^{18}F -FDG PET correctly identified progression. After 12 wk of therapy, PET, PSA, and standard imaging were compared. In 94% of cases, PET correctly identified the clinical status of the patients. In a single imaging modality, ^{18}F -FDG appeared to capture the information usually found in the composite endpoint of PSA, bone scintigraphy, and soft-tissue imaging. These data require validation in a larger dataset but do suggest that ^{18}F -FDG PET, when studied prospectively in well-defined clinical states and in controlled populations, can be used to demonstrate treatment effects (37).

Radiolabeled Phospholipids

Choline is a component of the phosphatidylcholines, a class of phospholipids and a major component of biologic membranes. Malignant tumors show high proliferation and increased metabolism of cell membrane components and, accordingly, an increased uptake of choline (38). Prostate cancer is associated with upregulated choline kinase activity and increased choline uptake. Choline can be labeled with either ^{11}C (^{11}C -choline) or ^{18}F (^{18}F -fluorocholine, or FCH). Table 3 outlines recent studies that evaluated the effectiveness of ^{11}C -choline and ^{18}F -FCH PET in patients with prostate cancer (42–44).

In a prospective study, Scattoni et al. (43) assessed 25 patients with PSA relapse and no evidence of local or bone metastases on conventional imaging who were imaged with ^{11}C -choline PET/CT to identify isolated lymph node metastases. All 25 patients then underwent extensive pelvic lymph node dissection. ^{11}C -choline PET/CT showed abnormal uptake in lymph nodes in 21 patients, and 19 of these instances were confirmed by histopathology. By comparison, CT or MRI revealed abnormal lymph nodes in 12 patients, 8 cases of which were also apparent on PET/CT, whereas the other 4 cases were false-positive findings for which further structural imaging did not provide additional diagnostic value. This study demonstrates a relatively low sensitivity of 64%, attributable to the inability of PET/CT to detect microscopic foci of metastatic prostate cancer.

Rinnab et al. (44) retrospectively evaluated ^{11}C -choline PET/CT detection of nodal recurrence in 50 patients in the presence of rising PSA. The overall sensitivity of PET/CT was 95% based on pathologic evaluation. The study was well designed but studied a small number of patients with mixed treatment histories.

As with other tracers, more attention has been paid to choline as an imaging agent for localized or nodal disease rather than for bone metastases (42–47). Schiavina et al. (45) has recently published a study on ^{11}C -choline PET for preoperative lymph-node staging in intermediate-risk and high-risk prostate cancer and compared ^{11}C -choline PET with 2 currently used clinical staging nomograms. The authors found, on a patient analysis, that the sensitivity and

specificity of correctly recognized cases on PET/CT were 60.0% and 97.6%, respectively, whereas on a lesional analysis, these numbers were 41.4% and 99.8%.

Two studies (Table 3) examined tracer ^{18}F -FCH detection in local, nodal, and bony metastases (48–50). ^{18}F -FCH has the advantage of a half-life of 110 min, as opposed to ^{11}C -choline, which has a half-life of only 20 min (51–54). Urinary excretion of ^{18}F -FCH is comparatively higher than that of ^{11}C -choline, but overall imaging methods are similar between different choline agents.

With ^{18}F -FCH PET/CT, Cimitan et al. (50) examined 100 patients who had previously received treatment for prostate cancer and had a rising, persistent increase in serum PSA, suggestive of local or distant recurrence. Fifty-eight patients with mixed castration-sensitive and -resistant prostate cancer and with variable primary treatment modalities were examined. True-positives were correlated with rebiopsy or imaging studies such as CT, transrectal ultrasonography, bone scanning, radiography of the skeleton, and MRI of the prostate, reflecting the fact that these patients represented a variety of clinical states ranging from rising PSA to metastatic disease. Also, 76% with increased bone lesions in this study were under treatment with hormone therapy. The effects of hormone therapy on ^{18}F -FCH uptake, especially in the skeleton, are of great importance and still under investigation. In this study, ^{18}F -FCH uptake in the skeleton appeared to be highly predictive of bone metastases, but this finding should be interpreted with caution in patients who are being treated with hormone therapy (55).

Using ^{18}F -FCH PET, Schmid et al. (49) studied 19 patients with prostate cancer: 10 with newly diagnosed prostate cancer, 8 suspected of having recurrence with rising PSA, and 1 with osseous metastasis on bone scans. A histopathologic workup of 35 sampled lymph nodes from the group with rising PSA and metastasis confirmed the PET/CT findings in all patients. In the 8 patients with rising PSA and the 1 patient with known metastatic disease, ^{18}F -FCH PET/CT findings were highly suggestive of local recurrence, lymph node metastases, or bone involvement.

It is difficult to draw conclusions from this trial, because the clinical states were highly variable in a small sample size and because there was no formal statistical basis stated for the desired endpoint.

Imaging of Osteoblastic Activity

^{18}F -fluoride is highly sensitive for detecting bone metastases, and uptake in malignant bone lesions reflects the increase in regional blood flow and bone turnover (56). Table 4 shows 2 studies that tested ^{18}F -fluoride in prostate cancer patients. Even-Sapir et al. (48) compared planar bone scintigraphy, bone scan SPECT, ^{18}F -fluoride PET, and ^{18}F -fluoride PET/CT in patients with either localized high-risk or metastatic prostate cancer. The sensitivity and specificity for detection of bone lesions was higher for ^{18}F -fluoride PET/CT (100% and 100%, respectively) than

TABLE 3
Studies of ^{11}C -Choline and ^{18}F -FCH Radiologic Tracer in Prostate Cancer

Author and year	<i>n</i>	Tracer	Clinical state	Study	Purpose and endpoint	Statistical method	Conclusion
Rinnab et al. (70), 2007	50	^{11}C -choline	Rising PSA	Retrospective	Purpose: disease detection (nodal) Endpoint: histopathology	Sensitivity, specificity	Overall sensitivity, 95% (38/40) Specificity, 40% PSA < 2.5 Sensitivity, 91% Specificity, 50%
Scattoni et al. (43), 2007	25	^{11}C -choline	Rising PSA	Prospective	Purpose: disease detection (nodal) Endpoint: histopathology	Lesion-based analysis of sensitivity, specificity	Sensitivity, 64% Specificity, 90%
de Jong et al. (42), 2003	67	^{11}C -choline	Initial staging	Prospective	Purpose: disease detection (nodal) Endpoints: Histopathology Follow-up PSA for 1 y	Sensitivity, specificity	Sensitivity, 80% (12/15) Specificity, 96%
Cimitan et al. (50), 2006	100	^{18}F -FCH	Rising PSA	Prospective	Purpose: disease detection (local, nodal, metastatic) Endpoints: Histopathology Lesions assessed with CIM Follow-up PET/CT	Paired <i>t</i> test	PET was true-positive in 43/53
Schmid et al. (49), 2005	19	^{18}F -FCH	Initial staging Rising PSA Metastatic	Prospective	Purpose: disease detection (local, nodal, metastatic) Endpoints: Lesions assessed with CIM Histopathology	None	Differentiation of BPH from cancerous prostate lesions was not possible

CIM = conventional imaging modality.

for planar bone scanning (70% and 57%, respectively) or bone SPECT (92% and 82%, respectively). ^{18}F -fluoride PET/CT is a highly sensitive and specific modality for the detection of bone metastases in patients with high-risk prostate cancer.

Beheshti et al. (57) compared ^{18}F -FCH and ^{18}F -fluoride imaging in the detection of prostate cancer in 38 men with biopsy-proven prostate cancer of mixed stages, using CT scan findings as a gold standard. Overall, in 321 lesions evaluated, a relatively close agreement was found between the 2 imaging modalities for detection of malignant bone lesions. ^{18}F -fluoride PET/CT demonstrated a higher sensitivity than ^{18}F -FCH PET/CT, but the difference was not statistically significant. The sensitivity and specificity for the detection of bone metastases was 81% and 93% for ^{18}F -fluoride and 74% and 99% for ^{18}F -FCH. ^{18}F -fluoride identified more lesions than ^{18}F -FCH. The authors concluded that ^{18}F -FCH PET/CT may be superior for the early

detection of metastatic bone disease, but in patients with ^{18}F -FCH-negative suggestive sclerotic lesions, a second bone-seeking agent (e.g., ^{18}F -fluoride) is recommended.

Imaging of Fatty Acid Synthesis

It is postulated that metabolic activity in the tumor occurs in a low-oxygen microenvironment, in association with an increased lipid synthesis that accompanies rapid cell growth (58). Prostate cancer itself is associated with an increase in fatty acid synthesis and the overexpression of fatty acid synthase (59). Therefore, a high concentration of ^{11}C -acetate in primary and metastatic lesions has been seen in prostate cancer (59,60). This tracer also has the benefit of not being excreted by the kidneys, making it preferable to ^{18}F -FDG for visualizing pelvic disease. In a preliminary study by Kotzerke et al. (61), uptake of ^{11}C -acetate and ^{11}C -choline radiotracers in prostate cancer or its metastases was nearly identical. Table 5 shows prospective studies of

TABLE 4

Detection of Local, Nodal, and Bony Metastases in Prostate Cancer Using ¹⁸F-Fluoride Radiologic Tracer FCH

Author and year	n	Tracer	Clinical state	Study	Purpose and endpoint	Statistical method	Conclusion
Even-Sapir et al. (48), 2006	44	¹⁸ F-fluoride	Initial staging (25) Metastatic (19)	Prospective	Purpose: disease detection (bone) Endpoints: Lesions assessed with CIM Histopathology Follow-up of CIM Clinical follow-up	Sensitivity, specificity	PET: Sensitivity, 100% Specificity, 62% PET/CT: Sensitivity, 100% Specificity, 100%
Beheshti et al., (57) 2008	38	¹⁸ F-FCH ¹⁸ F-fluoride	Initial staging (17) Metastatic castration-sensitive (21)	Prospective	Purpose: disease detection (bone) Endpoints: Lesions assessed with CT (from PET/CT) Histopathology Follow-up of PET/CT	Lesion-based sensitivity, specificity	¹⁸ F-FCH: Sensitivity, 74% Specificity, 99% ¹⁸ F-fluoride: Sensitivity, 81% Specificity, 93%

CIM = conventional imaging modality.

¹¹C-acetate PET in patients with prostate cancer. All of these studies examined patients who had completed definitive local therapy, and the studies focused on the clinical state of the rising-PSA population. The primary purpose of these studies was to determine the ability of ¹¹C-acetate PET to detect local, nodal, and metastatic disease.

A study by Albrecht et al. (62) examined ¹¹C-acetate PET in order to investigate the diagnostic potential in early detection of prostate cancer recurrence. Once again, these represented a variety of patient populations. Thirty-two prostate cancer patients with early evidence of relapse after initial radiotherapy or radical surgery were examined. In the radiotherapy group, PET showed local recurrences in 14 of 17 patients and 2 equivocal results. Distant disease was observed in 6 patients, and an equivocal result was obtained in 1. PET was positive in 5 of 6 patients with biopsy-proven recurrences, and the result for the remaining patient was equivocal. In the radical surgery group of 15 patients, visual interpretation was positive for local recurrences in 5 patients and equivocal in 4. A PSA decrease after salvage radiotherapy was used as an endpoint in 8 of 14 patients. The PET findings for the 8 patients responding to radiotherapy were positive in 3 and equivocal in 2.

Similarly, Sandblom et al. (63) studied ¹¹C-acetate PET in 20 patients who had undergone radical prostatectomy and had an increasing PSA level measured on 2 consecutive occasions. PET was compared with imaging techniques, physical findings, and tissue rather than with a single well-defined comparator. These included rectal examinations, transrectal ultrasonography, anastomosis biopsies, and imaging with CT or bone scanning. The findings were similarly heterogeneous: pathologic uptake of acetate was

seen in 15 (75%) of the 20 patients. In 8 of these patients, a solitary lesion was found (7 in the prostatic fossa and 1 at the regional lymph nodes). Multiple lesions were found in the remaining 7. False-positive uptake was seen in 3 men (15%). A host of non-prostate-related conditions was also detected, ranging from lung cancer to esophagitis. The authors do not report a correlation with standard studies or whether patients were followed prospectively to establish whether the false-positive findings were simply early detection of disease. No formal statistics were applied in this study.

Amino Acid Transport Imaging

Uptake of ¹¹C-labeled methionine is related to amino acid transport and protein synthesis and may be related to active tumor proliferation. Methionine is rapidly cleared from the blood and is metabolized in both the liver and the pancreas without renal excretion, making it more suitable than ¹⁸F-FDG for imaging pelvic disease. Few studies using ¹¹C-methionine have been conducted on prostate cancer patients; two of these studies are shown in Table 6.

In an older study, from 2002, Nunez et al. (64) compared this tracer with ¹⁸F-FDG in a population with metastatic prostate cancer. The authors found that ¹¹C-methionine was more effective than ¹⁸F-FDG PET for detecting bone metastasis in patients with prostate cancer. They evaluated ¹⁸F-FDG and ¹¹C-methionine PET in 12 patients with newly diagnosed progressive metastatic cancer and compared the scans with conventional imaging. The lesion detection sensitivity for ¹⁸F-FDG PET was 48% (167/348), and for ¹¹C-methionine PET the sensitivity was 72% (251/348), with conventional imaging used as the 100% refer-

TABLE 5
¹¹C-Acetate Tracers in Metastatic Prostate Cancer Patients with Rising PSA

Author and year	n	Tracer	Clinical state	Study	Purpose and endpoint	Statistical method	Conclusion
Sandblom et al. (63), 2006	20	¹¹ C-acetate	Rising PSA	Prospective	Purpose: disease detection (local, nodal, metastatic) Endpoints: Lesions assessed with CIM Histopathology	None	Pathologic uptake, 75%
Wachter et al. (71), 2006	50	¹¹ C-acetate	Rising PSA	Prospective	Purpose: disease detection (local, nodal, metastatic) with retrospective CT/MRI fusion Endpoint: lesions assessed with CIM-histopathology	None	Treatment influence, 28% (14/50)
Albrecht et al. (62), 2007	32	¹¹ C-acetate	Rising PSA	Prospective	Purpose: disease detection (local, nodal, metastatic) using early and late PET Endpoints: Histopathology Decrease in PSA after irradiation to primary site Lesions assessed with CIM	Intercategory variation κ-test	RT group: 5/6 PET + biopsy-proven RP group: 3/8 PET+ responding to RT

CIM = conventional imaging modality; RT = radiotherapy; RP = radical prostatectomy.

ence. The authors hypothesized that the increased sensitivity of ¹¹C-methionine over ¹⁸F-FDG PET resulted from differences in tumor metabolism between patients, differences between metastases in the same patient, and a time-dependent metabolic cascade in metastatic prostate cancer, with initial uptake of ¹¹C-methionine in dormant sites followed by increased uptake of ¹⁸F-FDG during progression of the disease.

¹¹C-methionine PET was also studied by Tóth et al. (65) in a rising-PSA population with negative findings on repeated biopsies; the goal was to improve disease detection for prostate biopsies. The overall detection rate was 46.7% (7/15) in PET-positive patients; the scan was performed only on the prostate region and excluded evaluation of distant disease.

Imaging of Androgen Receptor Expression

¹⁸F-fluoro-5 α -dihydrotestosterone (FDHT) is a radiolabeled analog of dihydrotestosterone, the main androgen receptor ligand. Even in the castrated state, the androgen receptor is still highly functional and plays a major role in tumor growth despite the absence of its ligand dihydrotestosterone (1). Table 7 shows 2 studies that tested ¹⁸F-FDHT in prostate cancer patients. An initial study of ¹⁸F-FDHT and ¹⁸F-FDG in 7 patients with progressive castration-resistant metastatic prostate cancer examined 59 lesions seen on standard imaging studies. Ninety-seven percent of these lesions were seen on ¹⁸F-FDG PET scans; 78% were seen on ¹⁸F-FDHT PET scans (66). Similar results were

reported for a more recent study, in which ¹⁸F-FDHT PET had a sensitivity of 63% and a lesion detection rate of 86%; positive findings occurred in patients with higher PSA levels and, consequently, more metastatic disease (67). Imaging with ¹⁸F-FDHT appears promising in the detection of viable tumors. ¹⁸F-FDHT also appears useful in evaluating clinically progressive metastatic prostate cancer and may be a promising agent in analyzing antigen receptors and their impact on the clinical management of prostate cancer. This agent may be sensitive for detecting tumor response to treatment as well. ¹⁸F-FDHT is now being investigated prospectively to assess therapeutic response in patients with castration and metastatic disease receiving antimicrotubule chemotherapy (68).

FUTURE MODALITIES

One future modality is imaging of amino acid transport with anti-1-amino-3-¹⁸F-fluorocyclobutane-1-carboxylic acid (anti-¹⁸F-FACBC). ¹⁸F-FACBC, initially developed to image brain lesions, is a synthetic L-leucine analog that has shown in vitro uptake within the DU-145 prostate carcinoma cell line and orthotopically implanted prostate tumors in nude rats (69). Compared with ¹⁸F-FDG, ¹⁸F-FACBC shows no significant renal excretion. Schuster et al. (69) studied 15 patients with newly diagnosed and recurrent prostate carcinoma. The presence or absence of disease was correctly identified in 40 of 48 prostate sextants; pelvic nodal status correlated in 7 of 9 patients, with higher uptake seen in

TABLE 6
Clinical Trial Design with ¹¹C-Methionine Tracers in Metastatic Prostate Cancer

Author and year	n	Tracer	Clinical state	Study	Purpose and endpoint	Statistical method	Conclusion
Nunez et al. (64), 2002	12	¹¹ C-methionine and ¹⁸ F-FDG	Metastatic castration-sensitive and -resistant	Prospective	Purpose: disease detection (metastatic) Endpoint: lesions assessed with CIM	Lesion-based sensitivity Paired <i>t</i> -test	¹⁸ F-FDG sensitivity, 48% (167/348) ¹¹ C-methionine sensitivity, 72.1% (251/348)
Tóth et al. (65), 2005	20	¹¹ C-methionine	Rising PSA (with repeated negative biopsies)	Prospective	Purpose: disease detection (local) for prostate biopsy. Endpoints: Lesions assessed with CIM Follow-up CIM	None	Overall detection rate, 46.7% (7/15)

CIM = conventional imaging modality.

malignant than benign lymph nodes in both staging and restaging. This novel tracer is being investigated for imaging prostate carcinoma. More clinical trials with this agent are planned.

CONCLUSION

An unprecedented number of tracers are now available for study in prostate cancer, based on an expanding awareness of the biologic complexity involved. These include metabolic, apoptotic, angiogenic, and other pathways. ¹⁸F-FDG has been studied the most and shows sensitivity in detecting metastatic disease in soft tissue and bone, although the study populations have been mixed. ¹¹C-choline, ¹⁸F-FCH, and ¹¹C-acetate have been studied mostly in the

early detection of prostate cancer. ¹⁸F-flouride offers the potential for detection of bone metastasis, but more studies are needed to evaluate this tracer further. ¹⁸F-FDHT and ¹⁸F-FACBC are the newest imaging modalities under investigation; they show preliminary promise for the detection of metastatic disease.

Although various imaging modalities based on nuclear medicine technology are being explored, several common themes emerge. First, most studies focus on the rising-PSA population. This focus is understandable, given the clinical challenge—to find the site of relapse in these patients with rising PSA. However, this is a difficult niche for new imaging modalities, because it is not known if such techniques have any ability to detect bone, nodal, or

TABLE 7
Clinical Trial Design with ¹⁸F-FDHT Radiologic Tracer in Metastatic Prostate Cancer

Author and year	n	Tracer	Clinical state	Study	Purpose and endpoint	Statistical method	Conclusion
Dehdashti et al. (67), 2005	20	¹⁸ F-FDHT	Metastatic disease	Prospective	Purpose: disease detection (metastatic) Endpoint: lesions assessed with CIM	Lesion- and patient-based sensitivity Paired <i>t</i> test Nonparametric Mann–Whitney test	Patient sensitivity, 63% (12/19) Lesion sensitivity, 86% (24/28) Decrease in tumor ¹⁸ F-FDHT uptake after flutamide
Larson et al. (66), 2004	7	¹⁸ F-FDHT and ¹⁸ F-FDG	Castration metastatic	Prospective	Purpose: disease detection (metastatic) Endpoint: lesions assessed with CIM	Lesion-based detection	¹⁸ F-FDHT PET positive in 78% (46/59) ¹⁸ F-FDG PET positive in 97% (57/59) Decrease in tumor ¹⁸ F-FDHT uptake after testosterone

CIM = conventional imaging modality.

local disease. It may well be easier to ascertain whether an imaging modality detects a specific distribution of disease in patients with metastatic disease rather than in the rising-PSA population.

The second observation is that many of these studies, although they focus on the rising-PSA population, do not follow the definition set out in the consensus criteria. Rising-PSA patients, by definition, are those who do not show findings on standard imaging modalities (9–11). Therefore, to have an endpoint of correlation with findings on standard scans is paradoxical; by definition, these standard scans must have negative results. To fit patients into the standard clinical-states model, one must work backward from standard scans. That is, the clinical state is defined by findings on bone scintigraphy and CT. In addition, most of these studies involve small numbers of patients and have so many subgroups and so many different endpoints that the numbers of each patient type are disturbingly small and inconclusive.

Finally, it is important that studies use uniform assessments performed at regular intervals, to allow comparisons between studies. The same assessments—such as the investigational scan, standard CT scan, and standard bone scan—should be followed longitudinally, so that lesions seen on standard scans but not on PET scans can be verified as either active cancer (false-negative) or benign changes (true-negative). Positive PET findings not seen on standard scans can be defined as either true lesions that emerge as cancer on subsequent standard studies (true-positive) or as false-positive findings.

When studied rigorously, these investigational agents have the ability to transform drug development in prostate cancer. Patients with a predefined biologic profile could be identified. Scans could also be used to assess therapeutic pharmacodynamics, staging, and prognostication. To properly develop such powerful tools, the nuclear medicine community and the prostate cancer clinical trials community are collaborating so that prostate cancer clinical trials can make use of biologic imaging.

ACKNOWLEDGMENT

Funding was provided by NIH/NRSA cancer chemotherapy NIH training grants T-32CA09207 and K23CA102544.

REFERENCES

- Scher HI, Sawyers CL. Biology of progressive, castration-resistant prostate cancer: directed therapies targeting the androgen-receptor signaling axis. *J Clin Oncol*. 2005;23:8253–8261.
- Kingsley LA, Fournier PGJ, Chirgwin JM, Guise TA. Molecular biology of bone metastasis. *Mol Cancer Ther*. 2007;6:2609–2617.
- Scher HI, Morris MJ, Kelly WK, Schwartz LH, Heller G. Prostate cancer clinical trial end points: “RECIST”ing a step backwards. *Clin Cancer Res*. 2005;11:5223–5232.
- Carducci MA, Padley RJ, Breul J, et al. Effect of endothelin-A receptor blockade with atrasentan on tumor progression in men with hormone-refractory prostate cancer: a randomized, phase II, placebo-controlled trial. *J Clin Oncol*. 2003;21:679–689.
- Tannock IF, de Wit R, Berry WR, et al. Docetaxel plus prednisone or mitoxantrone plus prednisone for advanced prostate cancer. *N Engl J Med*. 2004;351:1502–1512.
- Berry W, Dakhil S, Modiano M, Gregurich M, Asmar L. Phase III study of mitoxantrone plus low dose prednisone versus low dose prednisone alone in patients with asymptomatic hormone refractory prostate cancer. *J Urol*. 2002;168:2439–2443.
- Yagoda A. Non-hormonal cytotoxic agents in the treatment of prostatic adenocarcinoma. *Cancer*. 1973;32:1131–1140.
- Tannock IF. Is there evidence that chemotherapy is of benefit to patients with carcinoma of the prostate? *J Clin Oncol*. 1985;3:1013–1021.
- Bubley GJ, Carducci M, Dahut W, et al. Eligibility and response guidelines for phase II clinical trials in androgen-independent prostate cancer: recommendations from the Prostate-Specific Antigen Working Group. *J Clin Oncol*. 1999;17:3461–3467.
- Scher HI, Halabi S, Tannock I, et al. Design and end points of clinical trials for patients with progressive prostate cancer and castrate levels of testosterone: recommendations of the Prostate Cancer Clinical Trials Working Group. *J Clin Oncol*. 2008;26:1148–1159.
- Scher HI, Eisenberger M, D’Amico AV, et al. Eligibility and outcomes reporting guidelines for clinical trials for patients in the state of a rising prostate-specific antigen: recommendations from the Prostate-Specific Antigen Working Group. *J Clin Oncol*. 2004;22:537–556.
- Smith PH, Bono A, Calais da Silva F, et al. Some limitations of the radioisotope bone scan in patients with metastatic prostatic cancer. *Cancer*. 1990;66:1009–1016.
- Johns WD, Garnick MB, Kaplan WD. Leuprolide therapy for prostate cancer: an association with scintigraphic “flare” on bone scan. *Clin Nucl Med*. 1990;15:485–487.
- Pollen JJ, Shlaer WJ. Osteoblastic response to successful treatment of metastatic cancer of the prostate. *AJR*. 1979;132:927–931.
- Dotan ZA, Bianco FJ Jr, Rabbani F, et al. Pattern of prostate-specific antigen (PSA) failure dictates the probability of a positive bone scan in patients with an increasing PSA after radical prostatectomy. *J Clin Oncol*. 2005;23:1962–1968.
- Imbriaco M, Larson SM, Yeung HW, et al. A new parameter for measuring metastatic bone involvement by prostate cancer: the Bone Scan Index. *Clin Cancer Res*. 1998;4:1765–1772.
- Sabbatini P, Larson SM, Kremer A, et al. Prognostic significance of extent of disease in bone in patients with androgen-independent prostate cancer. *J Clin Oncol*. 1999;17:948–957.
- Morris MJ, Jia X, Larson SM, et al. Post-treatment serial bone scan index (BSI) as an outcome measure predicting for survival. In: *2008 Genitourinary Cancers Symposium Proceedings*. Alexandria, VA: ASCO; 2008:189.
- Sweat SD, Pacelli A, Murphy GP, Bostwick DG. Prostate-specific membrane antigen expression is greatest in prostate adenocarcinoma and lymph node metastases. *Urology*. 1998;52:637–640.
- Silver DA, Pellicer I, Fair WR, Heston WD, Cordon-Cardo C. Prostate-specific membrane antigen expression in normal and malignant human tissues. *Clin Cancer Res*. 1997;3:81–85.
- Wright GL Jr, Grob BM, Haley C, et al. Upregulation of prostate-specific membrane antigen after androgen-deprivation therapy. *Urology*. 1996;48:326–334.
- Chang SS, Reuter VE, Heston WD, Bander NH, Grauer LS, Gaudin PB. Five different anti-prostate-specific membrane antigen (PSMA) antibodies confirm PSMA expression in tumor-associated neovasculature. *Cancer Res*. 1999;59:3192–3198.
- Morris MJ, Divgi CR, Pandit-Taskar N, et al. Pilot trial of unlabeled and indium-111-labeled anti-prostate-specific membrane antigen antibody J591 for castrate metastatic prostate cancer. *Clin Cancer Res*. 2005;11:7454–7461.
- Milowsky MI, Nanus DM, Kostakoglu L, Vallabhajosula S, Goldsmith SJ, Bander NH. Phase I trial of yttrium-90-labeled anti-prostate-specific membrane antigen monoclonal antibody J591 for androgen-independent prostate cancer. *J Clin Oncol*. 2004;22:2522–2531.
- Bander NH, Milowsky MI, Nanus DM, et al. Phase I trial of ¹⁷⁷lutetium-labeled J591, a monoclonal antibody to prostate-specific membrane antigen, in patients with androgen-independent prostate cancer. *J Clin Oncol*. 2005;23:4567–4569.
- Galsky MD, Eisenberger M, Moore-Cooper S, et al. Phase I trial of MLN2704 in patients with castrate-metastatic prostate cancer (CMPC). *J Clin Oncol*. 2008;21:47–2154.
- Hinkle GH, Burgers JK, Neal CE, et al. Multicenter radioimmunoscintigraphic evaluation of patients with prostate carcinoma using indium-111 capromab pentetide. *Cancer*. 1998;83:739–747.
- Haseman MK, Reed NL, Rosenthal SA. Monoclonal antibody imaging of occult prostate cancer in patients with elevated prostate-specific antigen: positron emission tomography and biopsy correlation. *Clin Nucl Med*. 1996;21:704–713.
- Texter JH Jr, Neal CE. The role of monoclonal antibody in the management of prostate adenocarcinoma. *J Urol*. 1998;160:2393–2395.

30. Babaian RJ, Sayer J, Podoloff DA, Steelhammer LC, Bhadkamkar VA, Gulfo JV. Radioimmunoscintigraphy of pelvic lymph nodes with 111-indium-labeled monoclonal antibody CYT-356. *J Urol.* 1994;152:1952–1955.
31. Polascik TJ, Manyak M, Haseman M, et al. Comparison of clinical staging algorithms and ¹¹¹indium-capromab pendetide immunoscintigraphy in the prediction of lymph node involvement in high risk prostate carcinoma patients. *Cancer.* 1999;85:1586–1592.
32. Liu H, Moy P, Kim S, et al. Monoclonal antibodies to the extracellular domain of prostate-specific membrane antigen also react with tumor vascular endothelium. *Cancer Res.* 1997;57:3629–3634.
33. Bander NH, Milowsky MI, Nanus DM, Kostakoglu L, Vallabhajosula S, Goldsmith SJ. Phase I trial of ¹⁷⁷lutetium-labeled J591, a monoclonal antibody to prostate-specific membrane antigen, in patients with androgen-independent prostate cancer. *J Clin Oncol.* 2005;23:4591–4601.
34. Seltzer MA, Barbaric Z, Beldegrun A, et al. Comparison of helical computerized tomography, positron emission tomography and monoclonal antibody scans for evaluation of lymph node metastases in patients with prostate specific antigen relapse after treatment for localized prostate cancer. *J Urol.* 1999;162:1322–1328.
35. Morris MJ, Akhurst T, Osman I, et al. Fluorinated deoxyglucose positron emission tomography imaging in progressive metastatic prostate cancer. *Urology.* 2002;59:913–918.
36. Sung J, Espiritu JI, Segall GM, Terris MK. Fluorodeoxyglucose positron emission tomography studies in the diagnosis and staging of clinically advanced prostate cancer. *BJU Int.* 2003;92:24–27.
37. Morris MJ, Akhurst T, Larson SM, et al. Fluorodeoxyglucose positron emission tomography as an outcome measure for castrate metastatic prostate cancer treated with antimicrotubule chemotherapy. *Clin Cancer Res.* 2005;11:3210–3216.
38. Podo F. Tumour phospholipid metabolism. *NMR Biomed.* 1999;12:413–439.
39. Chang CH, Wu HC, Tsai JJ, Shen YY, Changlai SP, Kao A. Detecting metastatic pelvic lymph nodes by ¹⁸F-2-deoxyglucose positron emission tomography in patients with prostate-specific antigen relapse after treatment for localized prostate cancer. *Urol Int.* 2003;70:311–315.
40. Schöder H, Herrmann K, Gonen M, et al. 2-[¹⁸F]fluoro-2-deoxyglucose positron emission tomography for the detection of disease in patients with prostate-specific antigen relapse after radical prostatectomy. *Clin Cancer Res.* 2005;11:4761–4769.
41. Scher HI, Heller G. Clinical states in prostate cancer: towards a dynamic model of disease progression. *Urology.* 2000;55:323–327.
42. de Jong IJ, Pruim J, Elsinga PH, Vaalburg W, Mensink HJ. Preoperative staging of pelvic lymph nodes in prostate cancer by ¹¹C-choline PET. *J Nucl Med.* 2003;44:331–335.
43. Scattoni V, Picchio M, Suardi N, et al. Detection of lymph-node metastases with integrated [¹¹C]choline PET/CT in patients with PSA failure after radical retroperitoneal lymphadenectomy: results confirmed by open pelvic-retroperitoneal lymphadenectomy. *Eur Urol.* 2007;52:423–429.
44. Rinnab L, Mottaghy FM, Blumstein NM, et al. Evaluation of [¹¹C]-choline positron-emission/computed tomography in patients with increasing prostate-specific antigen levels after primary treatment for prostate cancer. *BJU Int.* 2007;100:786–793.
45. Schiavina R, Scattoni V, Castellucci P, et al. ¹¹C-choline positron emission tomography/computerized tomography for preoperative lymph-node staging in intermediate-risk and high-risk prostate cancer: comparison with clinical staging nomograms. *Eur Urol.* 2008;54:392–401.
46. Krause BJ, Souvatzoglou M, Tuncel M, et al. The detection rate of [¹¹C]choline-PET/CT depends on the serum PSA-value in patients with biochemical recurrence of prostate cancer. *Eur J Nucl Med Mol Imaging.* 2008;35:18–23.
47. Schilling D, Schlemmer HP, Wagner PH, et al. Histological verification of ¹¹C-choline-positron emission/computed tomography-positive lymph nodes in patients with biochemical failure after treatment for localized prostate cancer. *BJU Int.* 2008;102:446–451.
48. Even-Sapir E, Metser U, Mishani E, Lievshitz G, Lerman H, Leibovitch I. The detection of bone metastases in patients with high-risk prostate cancer: ^{99m}Tc-MDP planar bone scintigraphy, single- and multi-field-of-view SPECT, ¹⁸F-fluoride PET, and ¹⁸F-fluoride PET/CT. 2006;47:287–297.
49. Schmid DT, John H, Zweifel R, et al. Fluorocholine PET/CT in patients with prostate cancer: initial experience. *Radiology.* 2005;235:623–628.
50. Cimitan M, Bortolus R, Morassut S, et al. [¹⁸F]fluorocholine PET/CT imaging for the detection of recurrent prostate cancer at PSA relapse: experience in 100 consecutive patients. *Eur J Nucl Med Mol Imaging.* 2006;33:1387–1398.
51. Hara T, Kosaka N, Kishi H. Development of ¹⁸F-fluoroethylcholine for cancer imaging with PET: synthesis, biochemistry, and prostate cancer imaging. *J Nucl Med.* 2002;43:187–199.
52. DeGrado TR, Coleman RE, Wang S, et al. Synthesis and evaluation of ¹⁸F-labeled choline as an oncologic tracer for positron emission tomography: initial findings in prostate cancer. *Cancer Res.* 2001;61:110–117.
53. DeGrado TR, Baldwin SW, Wang S, et al. Synthesis and evaluation of ¹⁸F-labeled choline analogs as oncologic PET tracers. *J Nucl Med.* 2001;42:1805–1814.
54. DeGrado TR, Reiman R, Price DT. Pharmacokinetics and radiation dosimetry of ¹⁸F-fluorocholine. *J Nucl Med.* 2002;43:92–96.
55. Beheshti M, Vali R, Langsteger W. [¹⁸F]fluorocholine PET/CT in the assessment of bone metastases in prostate cancer. *Eur J Nucl Med Mol Imaging.* 2007;34:1316–1317.
56. Cook GJ, Fogelman I. The role of positron emission tomography in skeletal disease. *Semin Nucl Med.* 2001;31:50–61.
57. Beheshti M, Vali R, Waldenberger P, et al. Detection of bone metastases in patients with prostate cancer by F-18 fluorocholine and F-18 fluoride PET-CT: a comparative study. *Eur J Nucl Med Mol Imaging.* 2008;35:1766–1774.
58. Armbrrecht JJ, Buxton DB, Schelbert HR. Validation of [¹¹C]acetate as a tracer for noninvasive assessment of oxidative metabolism with positron emission tomography in normal, ischemic, posts ischemic, and hyperemic canine myocardium. *Circulation.* 1990;81:1594–1605.
59. Shreve P. Carbon-11 acetate PET imaging of prostate cancer. *J Nucl Med.* 1999;36:1595–1601.
60. Oyama N, Akino H, Kanamaru H, et al. ¹¹C-acetate PET imaging of prostate cancer. *J Nucl Med.* 2002;43:181–186.
61. Kotzerke J, Volkmer BG, Glatting G, et al. Intraindividual comparison of [¹¹C]acetate and [¹¹C]choline PET for detection of metastases of prostate cancer. *Nuklearmedizin.* 2003;42:25–30.
62. Albrecht S, Buchegger F, Soloviev D, et al. ¹¹C-acetate PET in the early evaluation of prostate cancer recurrence. *Eur J Nucl Med Mol Imaging.* 2007;34:185–196.
63. Sandblom G, Sorensen J, Lundin N, Haggman M, Malmstrom PU. Positron emission tomography with C11-acetate for tumor detection and localization in patients with prostate-specific antigen relapse after radical prostatectomy. *Urology.* 2006;67:996–1000.
64. Nunez R, Macapinlac HA, Yeung HW, et al. Combined ¹⁸F-FDG and ¹¹C-methionine PET scans in patients with newly progressive metastatic prostate cancer. *J Nucl Med.* 2002;43:46–55.
65. Tóth G, Lengyel Z, Balkay L, Salah MA, Trón L, Tóth C. Detection of prostate cancer with ¹¹C-methionine positron emission tomography. *J Urol.* 2005;173:66–69.
66. Larson SM, Morris M, Gunther I, et al. Tumor localization of 16beta-¹⁸F-fluoro-5alpha-dihydrotestosterone versus ¹⁸F-FDG in patients with progressive, metastatic prostate cancer. *J Nucl Med.* 2004;45:366–373.
67. Dehdashti F, Picus J, Michalski JM, et al. Positron tomographic assessment of androgen receptors in prostatic carcinoma. *Eur J Nucl Med Mol Imaging.* 2005;32:344–350.
68. Larson SM, Morris M, Gunther I, et al. Tumor localization of 16{beta}-¹⁸F-fluoro-5{alpha}-dihydrotestosterone versus ¹⁸F-FDG in patients with progressive, metastatic prostate cancer. *J Nucl Med.* 2004;45:366–373.
69. Schuster DM, Votaw JR, Nieh PT, et al. Initial experience with the radiotracer anti-1-amino-3-¹⁸F-fluorocyclobutane-1-carboxylic acid with PET/CT in prostate carcinoma. *J Nucl Med.* 2007;48:56–63.
70. Rinnab L, Mottaghy FM, Blumstein NM, et al. Evaluation of [¹¹C]-choline positron-emission/computed tomography in patients with increasing prostate-specific antigen levels after primary treatment for prostate cancer. 2007;100:786–793.
71. Wachter S, Tomek S, Kurtaran A, et al. ¹¹C-acetate positron emission tomography imaging and image fusion with computed tomography and magnetic resonance imaging in patients with recurrent prostate cancer. *J Clin Oncol.* 2006;24:2513–2519.