
Ursodeoxycholic Acid–Augmented Hepatobiliary Scintigraphy in the Evaluation of Neonatal Jaundice

Ujjal Poddar, DM¹; Anish Bhattacharya, DNB²; Babu R. Thapa, MD¹; Bhagwant R. Mittal, MD²; and Kartar Singh, DM¹

¹Department of Gastroenterology, Postgraduate Institute of Medical Education and Research, Chandigarh, India; and ²Department of Nuclear Medicine, Postgraduate Institute of Medical Education and Research, Chandigarh, India

Early differentiation of extrahepatic biliary atresia from intrahepatic cholestasis is important. Hepatobiliary scintigraphy is an excellent noninvasive investigation for ruling out extrahepatic biliary atresia. This study aimed at identifying the role of ursodeoxycholic acid (UDCA), a choleric agent, in conjunction with hepatobiliary scintigraphy in differentiating extrahepatic biliary atresia from neonatal hepatitis. **Methods:** Fifty-one infants (42 male, 9 female) aged 0.3–5.5 mo (mean, 2.9 mo) presenting with neonatal jaundice underwent ^{99m}Tc-mebrofenin hepatobiliary scintigraphy. For patients who did not show any excretion of tracer into the intestine till 24 h, the study was repeated after oral administration of UDCA (20 mg/kg every 12 h) for 48–72 h. Ultrasonography and, if required, liver biopsy and intraoperative cholangiography were used with clinical data such as stool color and serologic and other etiologic investigations to form a final diagnosis. **Results:** Of 51 patients, 19 showed biliary excretion in the first study, ruling out extrahepatic biliary atresia. Neonatal hepatitis was the final diagnosis in these. Of the remaining 32 patients, 12 nonexcretors converted to excretors after UDCA treatment, whereas 20 still showed no biliary drainage. Four nonexcretors on scintigraphy had a final diagnosis of neonatal hepatitis with galactosemia; the remaining 16 had extrahepatic biliary atresia. The specificity of hepatobiliary scintigraphy in ruling out extrahepatic biliary atresia improved from 54.3% to 88.6% ($P < 0.001$) after UDCA treatment. None of the patients experienced any ill effects from UDCA administration. **Conclusion:** Pretreatment with UDCA significantly improves the specificity of hepatobiliary scintigraphy in ruling out extrahepatic biliary atresia as a cause of prolonged neonatal jaundice.

Key Words: biliary atresia; mebrofenin; ursodeoxycholic acid

J Nucl Med 2004; 45:1488–1492

Early differentiation of extrahepatic biliary atresia from other causes of neonatal cholestasis is important, as early surgical intervention in biliary atresia significantly improves patient outcome (1–3). Hepatobiliary scintigraphy is an

important noninvasive investigation in the diagnostic work-up of the neonatal cholestasis syndrome. However, whereas the sensitivity of this investigation for detecting biliary atresia is high (close to 100%), the specificity has remained at 75%–80% in most of the series reported so far (4). Although some smaller series (5,6) have reported an increase in the accuracy of hepatobiliary scintigraphy after phenobarbital priming, biopsy and intraoperative cholangiography (IOC) were still required for a significant number of patients to establish a final diagnosis (7,8).

Ursodeoxycholic acid (UDCA), a choleric, nontoxic bile acid, has proved safe and useful for the long-term treatment of cholestatic liver diseases in children and for the postoperative management of patients with extrahepatic biliary atresia (9–11). So far, UDCA has been used as a priming agent for hepatobiliary scintigraphy of infants with jaundice in only 1 study (12), which found that specificity increased in the small number of patients (7) studied. We have prospectively studied the role of UDCA as a priming agent before ^{99m}Tc-mebrofenin scintigraphy in a large number of infants with cholestasis, to assess its ability to differentiate biliary atresia from other causes of neonatal jaundice.

MATERIALS AND METHODS

Consecutive infants with neonatal cholestasis admitted in the Pediatric Gastroenterology Unit of our institute from January to December 2002 were included in this study. A baseline scintigraphic study was done initially without medication. No sedation was used, and no restrictions were imposed on feeding the infants either before or during the entire study. Each infant first received an intravenous injection of 37 MBq (1 mCi) of ^{99m}Tc-mebrofenin. Serial static images were then acquired for 500,000 counts per view for up to 6 h on a dual-head γ -camera (Ecam; Siemens) using a low-energy multipurpose collimator, with the patient supine. Delayed anterior and posterior images (5 min per view) were acquired at 24 h. Lateral images were also acquired when required to differentiate intestinal from renal or bladder activity. For patients in whom no intestinal tracer excretion was detected even after 24 h, scintigraphy was repeated after we gave them UDCA (UDILIV; Solve India Ltd.). UDCA was given in a dosage of 20

Received Nov. 6, 2003; revision accepted Mar. 12, 2004.

For correspondence or reprints contact: Anish Bhattacharya, DNB, Department of Nuclear Medicine, PGIMER, Chandigarh, 160 012, India.

E-mail: shalmoli@glide.net.in

mg/kg/d in 2 divided doses (12 h apart) for 48–72 h before the second scan and was continued till the second scan was over. All patients were examined with ultrasonography to assess for the presence of the gallbladder. Liver biopsy and IOC were used for patients in whom no bilioenteric drainage was detected. We made the final diagnosis by considering the results of all these tests, in addition to clinical data and the findings of serologic and other etiologic investigations.

This study was conducted after due approval of the protocol by an interdepartmental review committee.

Results are expressed as mean \pm SD. The χ^2 test and Student *t*-test were used for comparisons, and $P < 0.05$ was taken as significant. The accuracy of a test was calculated as follows: accurately diagnosed cases/performed cases \times 100.

RESULTS

Fifty-one infants (42 male, 9 female) with a mean age of 2.9 mo (range, 0.3–5.5 mo) were studied. Sixteen turned out to have extrahepatic biliary atresia and 35, neonatal hepatitis. The mean age of infants with biliary atresia was higher than that of patients with neonatal hepatitis (3.4 ± 1.5 vs. 2.5 ± 1.3 , $P < 0.05$), but the male-to-female ratio was similar in both groups (4.3:1 vs. 4.8:1, $P =$ not statistically significant). The initial scan itself showed biliary excretion in 19, thus ruling out biliary atresia. These patients received a final diagnosis of neonatal hepatitis. Of the remaining 32 patients, 12 nonexcretors had converted to excretors after treatment with UDCA (Figs. 1–3), whereas 20 still showed no biliary drainage. Four nonexcretors on UDCA-aug-

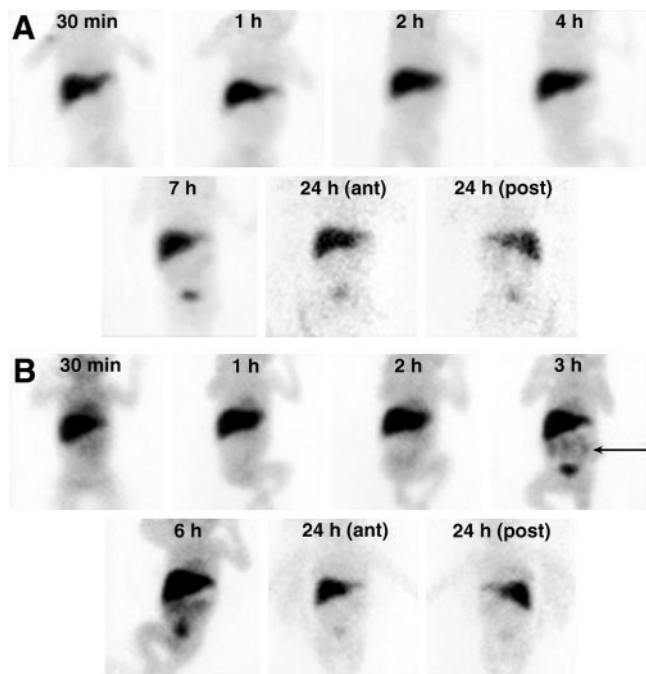


FIGURE 1. ^{99m}Tc -Mebrofenin scintigraphy of 45-d-old infant with neonatal jaundice before (A) and after (B) UDCA premedication. Drainage of tracer into the intestine (arrow) is seen on the post-UDCA study at 5 h and later. ant = anterior; post = posterior.

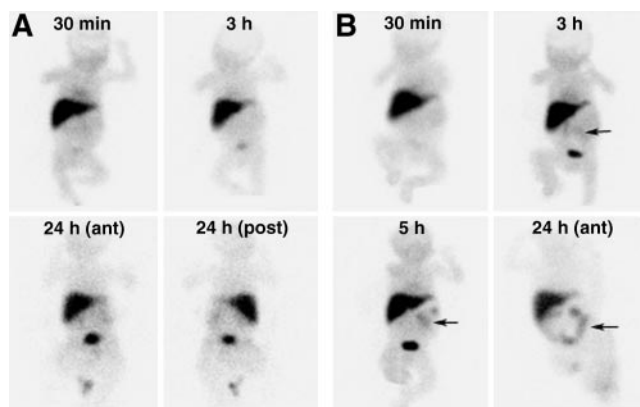


FIGURE 2. (A) Pre-UDCA ^{99m}Tc -mebrofenin hepatobiliary scintigraphy of 2-mo-old infant shows no detectable intestinal clearance of tracer up to 24 h. (B) Post-UDCA study shows intestinal clearance (arrow) by 3 h, which increases at 5 and 24 h. ant = anterior; post = posterior.

mented hepatobiliary scintigraphy were given a final diagnosis of neonatal hepatitis with galactosemia; the remaining 16 had biliary atresia. Hepatobiliary scintigraphy showed a significant increase in specificity—from 54.3% to 88.6% ($P < 0.001$)—in diagnosing biliary atresia after treatment with UDCA. The causes of neonatal hepatitis are given in Table 1. None of the patients experienced any ill effects from UDCA administration. The accuracy of various tests in our study group is given in Table 2.

DISCUSSION

In infants with conjugated hyperbilirubinemia, ultrasonography is still the first investigative test, as it is easily accessible, affordable, and noninvasive. However, although sensitive in the detection of choledochal cysts, ultrasonography is highly operator dependant. In our study, the accuracy of ultrasonography was much lower than that of UDCA-augmented hepatobiliary scintigraphy. Recent stud-

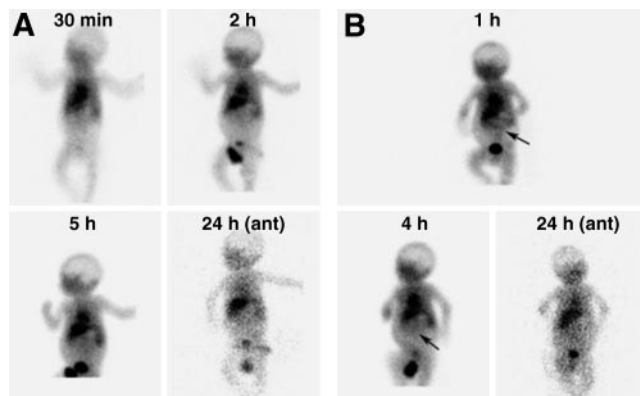


FIGURE 3. (A) In a 40-d-old infant with severe hepatic dysfunction, pre-UDCA ^{99m}Tc -mebrofenin study shows high background activity, with no detectable tracer clearance into the intestine. (B) Post-UDCA study of same infant shows tracer draining into the intestine (arrow) by 1 h. ant = anterior.

TABLE 1
Causes of Neonatal Jaundice in Study Population

Cause	No. of cases (n = 51)
Extrahepatic biliary atresia	16 (31.4%)
Neonatal hepatitis	35 (68.6%)
Galactosemia	08
Sepsis/urinary tract infection	16
Cytomegalovirus	01
Progressive familial intrahepatic cholestasis	01
Idiopathic	09

ies have indicated that the “triangular cord” sign on ultrasonography is specific for extrahepatic biliary atresia (13,14). Serial ultrasonography (after feeding) to estimate change in gallbladder size has also been proposed as a diagnostic method for ruling out extrahepatic biliary atresia. Some studies have also suggested duodenal intubation and aspiration for the presence of bile to establish the patency of the bilioenteric pathway. However, these procedures are invasive and time consuming and do not significantly increase the accuracy of diagnosis. Biopsy or IOC is still recommended in doubtful cases (15,16). Magnetic resonance cholangiography (17), which has only moderate specificity and accuracy in the diagnosis of extrahepatic biliary atresia, is expensive and not easily accessible to many centers. In addition, for adequate image quality in this age group of patients, meticulous patient preparation and sedation are required.

Hepatobiliary scintigraphy has been used in many centers around the world to assess hepatic function and bilioenteric drainage in neonates. Early reports, in the 1980s, suggested that ^{99m}Tc-iminodiacetic acid (IDA) scintigraphy after premedication with phenobarbital was a good noninvasive procedure for the diagnosis of extrahepatic biliary atresia. Phenobarbital is a potent inducer of hepatic enzymes and increases bilirubin conjugation and excretion of bile components, particularly those using the hepatic transport system for organic anions, one of which is IDA-radiolabeled substrates. Through enhancement ^{99m}Tc-IDA tracer uptake and excretion, the compromised liver is better visualized, its function more readily assessed, and the underlying etiology of neonatal jaundice more accurately determined. In an earlier study, Majd et al. described the use of phenobarbital to enhance the excretion of bile. Of 16 patients without excretion, 6 showed excretion after 3–6 d of receiving phenobarbital, 5 mg/kg/d orally in divided doses, to achieve blood levels of 15 mg/dL. The specificity of the investigation increased from 68% to 94% (5).

However, subsequent studies by various groups have had conflicting findings on the utility of phenobarbital premedication. Gerhold et al. reported 91% accuracy, 97% sensitivity, and 82% specificity for scintigraphy in the diagnosis of extrahepatic biliary atresia, without use of phenobarbital premedication (18). Spivak et al., in a small group (28

infants) with neonatal jaundice, demonstrated 100% sensitivity but only 43% specificity using postphenobarbital scintigraphy alone. They recommended inclusion of clinical criteria such as birth weight to improve the specificity of the investigation (19). More recently, in a larger series (86 infants less than 4 mo old), Gilmour et al. showed an improved specificity, 74%, and also suggested that poor liver extraction of tracer is not specific for neonatal hepatitis and that good liver extraction does not exclude neonatal hepatitis either (7).

On the other hand, Ben-Haim et al. suggested that phenobarbital induction may not be needed when ^{99m}Tc-mebrofenin scintigraphy (the technique used in our study) is used. In their study, the time to visualize bowel did not differ between patient groups with and without phenobarbital induction (20). Gupta et al. have reported a false positivity of 36% on hepatobiliary scintigraphy even with phenobarbital premedication. Interestingly, their study showed a significant fall in the number of false-positive findings, from 36% to 18%, on addition of betamethasone (2.2 mg/kg/d for 7 d) to phenobarbital before scintigraphy (21). In a recent study, Charneanrad et al., from Thailand, evaluated a large group of infants (95, with cholestasis) using ^{99m}Tc-diisopropyl IDA imaging. The accuracy of scintigraphy in this study was reported to be 73% after phenobarbital premedication and 100% with no premedication. They concluded that phenobarbital therapy may not be necessary before scintigraphy in the evaluation of neonatal cholestasis and that a delay in diagnosis and surgical treatment of extrahepatic biliary atresia can thus be avoided (22). Hepatobiliary scintigraphy has also been combined with serum γ -glutamyl transferase levels to obtain better results than with scintigraphy alone (23). Other groups have added duodenal aspiration for bile or measurement of radioactive counts in the duodenal juice as additional data to improve the specificity of scintigraphy (15). However, this procedure subjects the patient to an invasive intubation for the duration of the study. Most groups therefore recommend a multidisciplinary approach that includes correlation with clinical information, laboratory findings, and ultrasonography results (gallbladder visualization/triangular cord sign) to improve the specificity and accuracy of this investigation (24).

TABLE 2
Accuracy of Diagnostic Tests in Study Population (n = 51)

Test no.	Test	Accuracy*
1	Abdominal ultrasonography	74.5%
2	Pre-UDCA scintigraphy	68.6% [†]
3	Post-UDCA scintigraphy	92.1% [†]
4	Liver biopsy	100%

*Accuracy = accurately diagnosed cases/performed cases \times 100.
[†]P < 0.001 between tests 2 and 3.

These additional procedures add to the time and expense of diagnosis; however, the overall specificity and accuracy in the event of a nondraining scintigraphic picture remain far from satisfactory. The specificity for the diagnosis of extrahepatic biliary atresia in such instances is low, as was found by our study, in which specificity was only about 54%. The accuracy of a test indicates its effectiveness for the diagnosis of a condition. In our study, among the 3 commonly used tests for neonatal jaundice (ultrasonography of the abdomen, hepatobiliary scintigraphy, and liver biopsy), liver biopsy was the most accurate (100%). Liver biopsy was able to distinguish extrahepatic biliary atresia from neonatal hepatitis in all cases. In a study of 126 jaundiced infants, Lai et al. (15) also showed that the accuracy of liver biopsy was higher than that of scintigraphy or ultrasonography. Intraoperative cholangiography (IOC) is the gold standard in the diagnosis of biliary atresia. However, the rate of negative laparotomy findings without preoperative liver biopsy is much higher than that with preoperative liver biopsy (28% vs. 11%) (25). Biopsy and IOC, both invasive procedures, become essential in such cases to confirm the diagnosis (24). Among the 3 commonly used tests in neonatal cholestasis (ultrasonography, hepatobiliary scintigraphy, and liver biopsy), liver biopsy is the most accurate but most invasive test. In the backdrop of hepatic dysfunction, with a delayed coagulation profile, both these procedures involve a significant risk to the patient.

UDCA is a dihydroxy bile acid with choleric action. It has been used in the postoperative management of infants with biliary atresia (after Kasai's portoenterostomy) and for several months in children with cholestatic liver disease without any side effects (9,10,26,27). The various mechanisms of action of this bile acid include direct cytoprotection, a detergent action on dysfunctional microtubules, immunomodulation, and induction of hyperchloresis (28,29). To date, only 1 study on a small group of infants has used UDCA in conjunction with mebrofenin scintigraphy to improve hepatobiliary drainage in patients with neonatal hepatitis and to differentiate it from extrahepatic biliary atresia (12).

Based on the improved specificity of UDCA-primed hepatobiliary scintigraphy demonstrated by that group, we performed this prospective study. An intrinsic weakness of our study is, of course, that the efficacy of UDCA-augmented hepatobiliary scintigraphy has not been compared with that of phenobarbital as per the currently standard protocol. However, our results do demonstrate a significantly improved sensitivity for the detection of neonatal hepatitis—that is, specificity for ruling out extrahepatic biliary atresia—due to better detection of bilioenteric drainage on ^{99m}Tc-mebrofenin scintigraphy after treatment with UDCA. The increase in specificity from 54.3% to 88.6% ($P < 0.001$) in the post-UDCA study is comparable to the results described by other investigators using phenobarbital premedication alone. The sensitivity of hepatobiliary scin-

tigraphy for detecting extrahepatic biliary atresia (indicated by nonexcretion of the tracer) remained unchanged at 100% both before and after UDCA intervention. None of the patients in our study experienced any ill effects. The duration of UDCA premedication was only 2–3 d, compared with the 5–7 d that all other groups recommend for phenobarbital. In addition, the sedative effects of phenobarbital were completely avoided. No patient sedation or any other special precautions were required for these studies. Feedings were allowed before and during the study and ensured a more conducive environment for both the infants and their parents. By using UDCA-primed scintigraphy in our study, we could avoid invasive and potentially risky procedures such as IOC in a significant number (12/32) of patients.

However, proper quality control measures must be ensured both for preparing the radiotracer and for acquiring and processing the scintigraphic images. In the presence of severe hepatocyte dysfunction, ^{99m}Tc-mebrofenin is excreted through the kidneys, and urinary contamination of the abdominal region should be ruled out when interpreting the scans. In contrast, computerized enhancement of the images may be required to clearly identify the minimal intestinal drainage seen even after UDCA intervention in some instances.

CONCLUSION

UDCA administered orally for 2–3 d before ^{99m}Tc-mebrofenin scintigraphy significantly improves the specificity of this investigation for ruling out extrahepatic biliary atresia and helps avoid unnecessary laparotomy in a significant number of infants presenting with jaundice. However, a prospective, randomized crossover study between phenobarbital and UDCA would be useful for comparing the augmenting efficacy of these 2 drugs with hepatobiliary scintigraphy.

ACKNOWLEDGMENT

The authors gratefully acknowledge Madan Parmar for technical help with the acquisition and processing of the scintigraphic data.

REFERENCES

1. Mieli-Vergani G, Howard ER, Portman B, et al. Late referral for biliary atresia: missed opportunities for effective surgery. *Lancet*. 1989;1(8635):421–423.
2. Miyano T, Fujimoto T, Ohya T, et al. Current concept of the treatment of biliary atresia. *World J Surg*. 1993;17:332–336.
3. Lugo Vicente HL. Biliary atresia: an overview. *Bol Asoc Med P R*. 1995;87:147–153.
4. Nadel HR. Hepatobiliary scintigraphy in children. *Semin Nucl Med*. 1996;26:25–42.
5. Majd M, Reba RC, Altman RP. Effect of phenobarbital on ^{99m}Tc-IDA scintigraphy in the evaluation of neonatal jaundice. *Semin Nucl Med*. 1981;11:194–204.
6. Salvatori M, Valenza V, De Franco A, et al. Hepatobiliary scintigraphy in the study of neonatal hepatic cholestasis. *Radiol Med (Torino)*. 1989;78:638–644.
7. Gilmour SM, Hershkop M, Reifen R, et al. Outcome of hepatobiliary scanning in neonatal hepatitis syndrome. *J Nucl Med*. 1997;38:1279–1282.
8. Burton EM, Babcock DS, Heubi JE, et al. Neonatal jaundice: clinical and ultrasonographic findings. *South Med J*. 1990;83:294–302.
9. Kardorff R, Melter M, Rodeck B, et al. Long-term ursodeoxycholic acid treat-

- ment of cholestatic liver diseases in childhood: clinical and biochemical effects [in German]. *Klin Padiatr.* 1996;208:118–122.
10. Dinler G, Kocak N, Yuce A, et al. Ursodeoxycholic acid therapy in children with cholestatic liver disease. *Turk J Pediatr.* 1999;41:91–98.
 11. Levine A, Maayan A, Shamir R, et al. Parenteral nutrition-associated cholestasis in preterm neonates: evaluation of ursodeoxycholic acid treatment. *J Pediatr Endocrinol Metab.* 1999;12:549–553.
 12. Johnson K, Alton HM, Chapman S. Evaluation of mebrofenin hepatoscintigraphy in neonatal-onset jaundice. *Pediatr Radiol.* 1998;28:937–941.
 13. Kotb MA, Kotb A, Sheba MF, et al. Evaluation of the triangular cord sign in the diagnosis of biliary atresia. *Pediatrics.* 2001;108:416–420.
 14. Park WH, Choi SO, Lee HJ. The ultrasonographic 'triangular cord' coupled with gallbladder images in the diagnostic prediction of biliary atresia from infantile intrahepatic cholestasis. *J Pediatr Surg.* 1999;34:1706–1710.
 15. Lai MW, Chang MH, Hsu SC, et al. Differential diagnosis of extrahepatic biliary atresia from neonatal hepatitis: a prospective study. *J Pediatr Gastroenterol Nutr.* 1994;18:121–127.
 16. Larrosa-Haro A, Caro-Lopez AM, Coello-Ramirez P, et al. Duodenal tube test in the diagnosis of biliary atresia. *J Pediatr Gastroenterol Nutr.* 2001;32:311–315.
 17. Norton KI, Glass RB, Kogan D, et al. MR cholangiography in the evaluation of neonatal cholestasis: initial results. *Radiology.* 2002;222:687–691.
 18. Gerhold JP, Klingensmith WC, Kuni CC, et al. Diagnosis of biliary atresia with radionuclide hepatobiliary imaging. *Radiology.* 1983;146:499–504.
 19. Spivak W, Sarkar S, Winter D, et al. Diagnostic utility of hepatobiliary scintigraphy with Tc99m DISIDA in neonatal cholestasis. *J Pediatr.* 1987;110:855–861.
 20. Ben-Haim S, Seabold JE, Kao SC, et al. Utility of Tc99m mebrofenin scintigraphy in the assessment of neonatal jaundice. *Clin Nucl Med.* 1995;20:153–163.
 21. Gupta DK, Charles AR, Srinivas M, et al. Betamethasone in plus phenobarbitone prior to hepatobiliary scintigraphy increases diagnostic accuracy in infants with jaundice. *Indian J Pediatr.* 2001;68:1039–1041.
 22. Charearnrad P, Chongsrisawat V, Tepmongkol S, et al. The effect of phenobarbital on the accuracy of technetium-99m diisopropyl iminodiacetic acid hepatobiliary scintigraphy in differentiating biliary atresia from neonatal hepatitis syndrome. *J Med Assoc Thai.* 2003;86(suppl 2):S189–S194.
 23. Arora NK, Kohli R, Gupta DK, et al. Hepatic technetium-99m-mebrofenin iminodiacetate scans and serum gamma-glutamyl transpeptidase levels interpreted in series to differentiate between extrahepatic biliary atresia and neonatal hepatitis. *Acta Paediatr.* 2001;90:975–981.
 24. Choi SO, Park WH, Lee HJ. Ultrasonographic "triangular cord": the most definitive finding for noninvasive diagnosis of extrahepatic biliary atresia. *Eur J Pediatr Surg.* 1998;8:12–16.
 25. Yachha SK. Consensus report on neonatal cholestasis syndrome. *Indian Pediatr.* 2000;37:845–851.
 26. Stiehl A. Bile acids in liver diseases: current indications [in German]. *Ther Umsch.* 1995;52:682–686.
 27. Nittono H, Tokita A, Hayashi M, et al. Ursodeoxycholic acid therapy in the treatment of biliary atresia. *Biomed Pharmacother.* 1989;43:37–41.
 28. Jafri S, Pasricha P. Agents used for diarrhea, constipation and inflammatory bowel disease; agents used for biliary and pancreatic disease. In: Hardman JG, Limberd LE, eds. *Goodman and Gilman's the Pharmacological Basis of Therapeutics.* 10th ed. New York, NY: McGraw-Hill; 2001:1037–1055.
 29. Altman DF. Drugs used in gastrointestinal diseases. In: Katzung BG, ed. *Basic and Clinical Pharmacology.* 8th ed. New York, NY: Lange Medical Books/McGraw-Hill; 2001:1064–1075.

