

Is ^{18}F -FDG PET/CT Useful for Imaging and Management of Patients with Suspected Occult Recurrence of Cancer?

Ora Israel, MD^{1,2}; Maya Mor, MD¹; Luda Guralnik, MD³; Nirit Hermoni, MD¹; Diana Gaitini, MD^{2,3}; Rachel Bar-Shalom, MD¹; Zohar Keidar, MD, PhD^{1,2}; and Ron Epelbaum, MD^{2,4}

¹Department of Nuclear Medicine, Rambam Medical Center, Haifa, Israel; ²The B. Rappaport School of Medicine, Technion, Israel Institute of Technology, Haifa, Israel; ³Department of Diagnostic Imaging, Rambam Medical Center, Haifa, Israel; and ⁴Department of Oncology, Rambam Medical Center, Haifa, Israel

Rising serum tumor markers may be associated with negative imaging in the presence of cancer. CT and ^{18}F -FDG PET may yield incongruent results in the assessment of tumor recurrence. The present study evaluates the incremental role of ^{18}F -FDG PET/CT for the diagnosis and management of cancer patients with increasing levels of tumor markers as the sole indicator of potential recurrence after initial successful treatment. **Methods:** Thirty-six cancer patients with increasing levels of tumor markers during follow-up and negative CT underwent ^{18}F -FDG PET/CT, which showed 111 sites of increased tracer uptake. PET/CT was compared with PET results on a site-based analysis for characterization of ^{18}F -FDG foci and on a patient-based analysis for diagnosis of recurrence. The clinical impact of PET/CT on further patient management was evaluated. **Results:** Thirty patients (83%) had recurrence in 85 malignant sites (77%). For the site-based analysis, PET had a sensitivity, specificity, accuracy, positive predictive value, and negative predictive value of 96%, 50%, 85%, 85%, and 82%, respectively, as compared with the performance indices of PET/CT of 100%, 89%, 97%, 97%, and 100%, respectively. There was a statistically significant difference between the specificity ($P < 0.05$) and accuracy ($P < 0.001$) of PET and PET/CT for precise characterization of suspected lesions. For the patient-based analysis, PET had a sensitivity, specificity, and accuracy of 93%, 50%, and 86%, respectively, as compared with PET/CT with values of 93%, 67%, and 89%, respectively ($P =$ not significant). PET/CT was the single modality that directed further management and treatment planning in 12 patients (33%). **Conclusion:** The results of this study indicate that PET/CT may improve the accuracy of occult cancer detection and further lead to management changes in patients with increasing levels of tumor markers as the sole suspicion of recurrent malignancy.

Key Words: PET; PET/CT; cancer recurrence; tumor markers

J Nucl Med 2004; 45:2045–2051

Early detection of tumor recurrence is currently the main clinical application of serum cancer markers (1) in an attempt to diagnose a small tumor load with the potential improved outcome of second-line treatment (2,3). Increasing concentrations of tumor markers may be the earliest indication of recurrent disease after treatment, the possibility of false-positive (FP) results notwithstanding. Further evaluation of cancer patients showing increasing tumor marker serum values during follow-up, however, may be difficult, involving sophisticated technology and invasive procedures, while, at the same time, raising the level of the patients' anxiety.

Diagnosis of recurrent cancer by CT is based on the detection of a new abnormal mass or changes in the size of a known lesion caused by renewed cancer growth (4,5). Diagnosis of recurrent malignancy by PET using ^{18}F -FDG is based on increased utilization of glucose by malignant cells. These 2 imaging modalities do not always yield congruent findings. As previously demonstrated, cancer relapse can be diagnosed by PET months and even years before it becomes evident on conventional, anatomic imaging modalities (5–7). However, diagnosis of early recurrent cancer-induced metabolic changes by PET is impaired by the lack of precise anatomic landmarks and by the presence of increased radiotracer uptake of physiologic or nonmalignant etiology associated with benign and treatment-related conditions and distorted anatomy after surgery (8,9).

PET/CT hybrid imaging, performed using a single device in a single diagnostic session, combines noninvasive structural and metabolic tumor assessment and, therefore, provides precise anatomic localization of areas of increased ^{18}F -FDG uptake (10–12).

The objectives of the present study were to assess whether the fused metabolic and anatomic information provided by PET/CT has an incremental value in the diagnosis and localization of recurrence and in the subsequent clinical management of cancer patients with increasing concentra-

Received Jun. 2, 2004; revision accepted Aug. 12, 2004.
For correspondence or reprints contact: Ora Israel, MD, Department of Nuclear Medicine, Rambam Medical Center, Haifa 35254, Israel.
E-mail: o_israel@rambam.health.gov.il

tions of tumor serum markers and negative conventional imaging performed earlier.

MATERIALS AND METHODS

Patient Population

Forty-one cancer patients referred for ^{18}F -FDG PET/CT between October 2000 and December 2002 in search of occult recurrent cancer were evaluated. The entry criteria for this prospective study included (a) cancer patients during follow-up after treatment for their known primary tumors; (b) normal-range baseline serum tumor marker values after completion of treatment, with subsequent increasing concentrations on serial examinations during routine follow-up; and (c) negative high-resolution, contrast-enhanced CT performed before the present ^{18}F -FDG hybrid imaging. The Institutional Review Board approved the study, and each patient signed a written informed consent form.

Consecutive patients with matching inclusion criteria were included and no power analysis was performed. Five patients were excluded from further analysis because of lack of follow-up data after their PET/CT study. The final study population, therefore, included 36 patients: 19 women and 17 men with a mean age of 61 y (range, 32–84 y). The clinical characteristics of the study population are presented in Table 1. The last CT study was performed within a mean time of 52 d (range, 11–99 d) before the

PET/CT study, without intervening therapeutic interventions. Additional investigations, such as physical examination, endoscopy, ultrasound, and bone scintigraphy, were also negative. The final diagnosis of the presence or absence of recurrent cancer was based on histologic findings obtained during surgery or biopsy, subsequent imaging, and clinical follow-up. Patients were considered to have no evidence of recurrent cancer if they showed a subsequent decrease in tumor marker levels or had a negative clinical and radiologic follow-up of at least 12 mo after their PET/CT examination.

Imaging Technique

The patients were studied by a dedicated PET/CT system (Discovery LS; General Electric Medical Systems). Patients were instructed to fast for 4–6 h before injection of ^{18}F -FDG, except for glucose-free oral hydration. Blood glucose was measured before injection of the tracer to ensure levels of <11 mmol/L. The injected dose of ^{18}F -FDG was 370–444 MBq (10–12 mCi). After injection, patients were kept lying comfortably. No urinary bladder catheterization was performed and oral muscle relaxants were not administered. PET/CT was started 60 min after ^{18}F -FDG injection. No oral and intravenous contrast material was administered for the purpose of the CT.

The PET/CT system is composed of a dedicated PET scanner with a full-ring bismuth germanate detector and a multislice CT (11,12). The protocol of the present study included an initial CT acquisition followed by the PET study. CT parameters used for acquisition included 140 kV, 80 mA, 4-slices helical, 0.5 s per rotation, and pitch of 6:1, with a slice thickness of 4.25 mm, equal to that of the PET. CT images were reconstructed onto a 512×512 matrix. PET was acquired by sequential fields of view, each covering 15 cm during an acquisition time of 5 min. PET acquisition was performed in 2-dimensional mode using a matrix of 128×128 . PET data were reconstructed using ordered-subsets expectation maximization. Data obtained from the CT acquisition were used for low-noise attenuation correction of PET emission data and for fusion of attenuation-corrected PET images with the corresponding CT images.

After completion of PET acquisition, the reconstructed x-ray attenuation-corrected PET images, CT images, and fused images were available for review in axial, coronal, and sagittal planes, and in maximum-intensity-projection 3-dimensional cine mode, using the manufacturer's review station (eNTEGRA; General Electric Medical Systems).

Study Interpretation

Two experienced nuclear medicine physicians who were aware of each patient's clinical history initially interpreted together the stand-alone ^{18}F -FDG PET images with the previously performed high-resolution, contrast-enhanced CT studies available for side-by-side visual comparison and with the knowledge that these studies had been initially reported as negative for the presence of cancer. The presence and localization of any area of increased ^{18}F -FDG uptake was recorded, and each lesion was characterized as benign, malignant, or equivocal. A focus of increased ^{18}F -FDG uptake was defined as benign when related to physiologic biodistribution of ^{18}F -FDG or to a known nonmalignant process. A focal abnormal ^{18}F -FDG activity, of higher intensity than that of surrounding tissues—not related to the physiologic or benign ^{18}F -FDG uptake—was defined as malignant. Any area of increased ^{18}F -FDG uptake that could not be clearly characterized was defined as equivocal.

TABLE 1

Clinical Characteristics of 36 Cancer Patients with Increasing Concentrations of Tumor Markers and Negative CT

Characteristic	Value
Sex (no. of patients)	
Male	17
Female	19
Age (y)	
Mean	61
Range	32–84
Histology of primary tumor (no. of patients)	
Colorectal	21
Breast	7
Lung	4
Pancreas	1
Prostate	1
Ovary	1
Thyroid	1
Time from last treatment (mo)	
Mean	27.6
Range	2–184
Rising levels of tumor markers (no. of patients)	
CEA	25
CA 15-3	5
CA 19-9	4
CA-125	3
MCA	2
PSA	1
Thyroglobulin	1

CEA = carcinoembryonic antigen; CA = carbohydrate antigen; MCA = mucin-like carcinoma-associated antigen; PSA = prostate-specific antigen.

Two experienced radiologists, who were aware of each patient's history and clinical data but unaware of current ^{18}F -FDG PET results, reviewed the previously performed diagnostic CT and the CT component of the PET/CT study. The presence of lesions, previously undiagnosed and only retrospectively detected on the contrast-enhanced, high-resolution CT, or new abnormalities, seen only on the CT component of the PET/CT study, were recorded.

A combined team, including 2 nuclear medicine physicians and 2 radiologists, interpreted the fused PET/CT images in subsequent reading sessions with knowledge of the results of the PET and CT studies. Fused PET/CT data were prospectively recorded using the same criteria as for PET, including characterization and localization of all suspected sites. Disagreements concerning final interpretation were resolved by a majority opinion.

Data Analysis

PET evaluated with side-by-side comparison with previously performed high-resolution, contrast-enhanced CT, and further PET/CT studies, were analyzed and compared for each suspected site and for each patient.

For the site-based analysis, a true-positive (TP) lesion was defined as malignant or equivocal on PET or PET/CT with subsequent confirmed tumor involvement. A FP site was defined as malignant or equivocal on PET or PET/CT with no further evidence of disease. A true-negative (TN) site was defined as benign or physiologic on PET or PET/CT with no further evidence of disease. A false-negative (FN) site was defined as benign or physiologic on PET or PET/CT showing subsequent evidence of malignancy. Differences in lesion definition between PET and fused PET/CT images were documented for each suspected site. The additional value of PET/CT was defined as new information regarding the classification and localization of foci of ^{18}F -FDG uptake, provided by fused images and not previously available from separate PET with side-by-side CT evaluation.

For the patient-based analysis, a patient was defined as TP on the PET or PET/CT study when it showed at least one lesion with further confirmed malignancy. A FP study showed at least one lesion defined as malignant with no evidence of active cancer on further evaluation. A TN study showed only sites defined as benign, or no abnormal findings, and the patient had no further evidence of active cancer. A negative study in a patient who had further evidence of active disease was defined as FN. Studies with no abnormal ^{18}F -FDG foci detected on PET (and therefore on PET/CT as well) were included, as TN or FN, only in the patient-based analysis. Differences in patient categorization between PET and fused PET/CT data for diagnosis of recurrence were documented. The additional value of PET/CT was defined as new information regarding the diagnosis of recurrence, provided by fused images and not previously available from separate PET with side-by-side CT evaluation.

The impact of fused PET/CT images on the management of patients was evaluated, based on information regarding further clinical decisions obtained from patient files and interviews of the treating physicians or patients. Referral of patients for previously unplanned therapeutic modalities based on PET/CT results was recorded.

The sensitivity, specificity, and accuracy were calculated for both the site-based and the patient-based analysis. In addition, the positive predictive value (PPV) and negative predictive value (NPV) were calculated for the site-based analysis. The differences in site- and patient-based analysis of performance indices between

PET and PET/CT were compared using the McNemar test for paired proportions. The differences in treatment decisions prompted by PET and those induced by PET/CT were assessed by χ^2 analysis of contingency tables. A P value < 0.05 was considered as statistically significant.

RESULTS

Of the 36 cancer patients with an increased concentration of tumor serum markers and negative CT who were evaluated, 30 patients (83%) had evidence of malignancy at surgery or biopsy ($n = 14$) or subsequent imaging ($n = 16$). Six patients (17%) showed no further evidence of disease during a follow-up period ranging between 13 and 21 mo. A total of 111 sites of increased ^{18}F -FDG uptake were evaluated in these 36 patients. Malignancy was diagnosed in 85 of the 111 lesions (77%).

Site-Based Performance of PET and PET/CT for Diagnosis of Recurrence

PET interpreted with side-by-side evaluation of CT defined 94 of the 111 sites of increased ^{18}F -FDG uptake as malignant or equivocal (18 equivocal) and 17 as benign. On the basis of PET, there were 80 TP sites, 14 TN, 14 FP, and 3 FN sites, for a sensitivity, specificity, and accuracy of 96%, 50%, and 85%, respectively, and a PPV and NPV of 85% and 82%, respectively. PET/CT analysis defined 86 sites as malignant and 25 as benign. On the basis of PET/CT, there were 83 TP sites, 25 TN, 3 FP, and no FN lesions, for a sensitivity, specificity, and accuracy of 100%, 89%, and 97%, respectively, and a PPV and NPV of 97% and 100%. PET/CT yielded a statistically significant increase in specificity ($P < 0.005$) and accuracy ($P < 0.001$) as compared with PET.

PET/CT changed the classification of 11 sites considered as malignant on PET from FP to TN, including ^{18}F -FDG uptake in vascular calcifications, in inflammatory changes due to the presence of a stent or surgical scar, and physiologic tracer activity in the gastrointestinal tract. PET/CT changed the definition of 3 areas of increased ^{18}F -FDG uptake from FN to TP. These sites, considered as representing physiologic bowel uptake by PET, were precisely characterized as liver metastasis, mesenteric lymph node involvement, and a local colon recurrence.

Three ^{18}F -FDG-avid lesions were FP on both PET and PET/CT. Two of these sites were histologically assessed, including 1 site of benign neurofibromatosis in the thigh and 1 retrocaval anthracotic lymph node. The third site was a single ^{18}F -FDG-avid cervical lymph node in a patient with lung cancer who showed no evidence of malignancy for a follow-up of 21 mo, with a further decreased level of serum tumor markers, and was therefore considered to represent only nonspecific inflammatory changes.

Thirty-two of the 85 malignant lesions (38%) were retrospectively identified on the previously performed diagnostic CT. This included 16 lymph node metastases, 8 liver metastases, and 1 soft-tissue mass in the chest wall, with

TABLE 2

Comparative Analysis of PET and PET/CT Site-Based Performance in 111 Suggestive Lesions in 36 Patients with Suspected Occult Cancer Recurrence Due to Rising Levels of Tumor Markers

Performance	PET	PET/CT
TP (n)	80	83
TN (n)	14	25
FP (n)	14	3
FN (n)	3	—
Sensitivity (%)	96	100
Specificity* (%)	50	89
Accuracy* (%)	85	97
PPV (%)	85	97
NPV (%)	82	100

*P statistically significant for specificity ($P < 0.05$) and accuracy ($P < 0.001$).

diameters ranging between 8 and 20 mm, and 7 bone metastases. New structural abnormalities were observed on the CT component of the hybrid imaging study in 30 sites (35%).

The site-based comparative performance of PET and PET/CT is summarized in Table 2.

Patient-Based Performance of PET and PET/CT for Diagnosis of Recurrence

PET interpreted with side-by-side evaluation of CT defined 28 of the 36 studies as TP, 3 TN, 3 FP, and 2 FN, for a sensitivity of 93%, a specificity of 50%, and an accuracy of 86%. On the basis of PET/CT analysis, there were 28 TP, 4 TN, 2 FP, and 2 FN studies, for a sensitivity of 93%, a specificity of 67%, and an accuracy of 89%. There was no statistically significant difference between the performance indices of PET and PET/CT for the patient-based analysis.

Tumor marker serum levels decreased during follow-up in 4 of the 6 patients with no further evidence of disease. None of the 6 patients showed any suggestive lesions on imaging studies performed during the follow-up period.

PET/CT changed the classification of 1 site considered as malignant on PET from FP to TN. This patient had a single abdominal focus of increased ^{18}F -FDG uptake considered as

suspicious by PET and precisely defined by PET/CT as physiologic bowel activity. The patient showed no evidence of disease for a follow-up of 15 mo (Fig. 1).

The 2 patients defined as FP on both PET and PET/CT included 1 patient with anthracosis in an enlarged retrocaval lymph node and a second patient with nonspecific inflammatory changes in a cervical lymph node. The 2 patients defined as FN by both PET and PET/CT included a local recurrence of prostate cancer diagnosed 6 wk later and 1 patient with breast cancer showing a 7-mm malignant lesion in the second breast 2 mo later.

The patient-based comparative performance of PET and PET/CT is summarized in Table 3.

Clinical Impact of PET/CT on Patient Management

Of the 28 patients with TP PET/CT studies, 9 patients underwent surgery with curative intent, 15 patients were referred for chemotherapy, 3 patients received radiotherapy, and 1 patient was referred for radioiodine treatment. In 12 of the 28 patients (43%), treatment could be planned based only on the incremental diagnostic localization data provided by PET/CT.

Surgery with curative intent was performed in 9 patients with solitary malignant lesions. Eight of these 9 patients were referred for surgery based on the PET/CT diagnosis and precise localization of single tumor foci, including 3 lymph node metastases, 3 local recurrences of colon cancer (Fig. 2), 1 liver metastasis, and 1 second primary gastric cancer. Additional investigations guided by PET/CT findings (colonoscopy or gastroscopy) were performed in 2 of these 8 patients before the tumor resection.

Previously unplanned chemotherapy was administered to 15 patients with disseminated metastatic disease. Two of the 15 patients received chemotherapy after the PET/CT diagnosis of unresectable, extensive disease.

Radiation treatment was administered to 4 patients. One patient with a single bone metastasis received local-field radiotherapy, and ^{131}I treatment was administered to a second patient with metastatic thyroid cancer. PET/CT findings induced changes in the localization and size of radiation fields in 2 patients, including 1 patient with a single bone metastasis and a second patient with a single soft-tissue metastasis, precisely localized by PET/CT. There was a

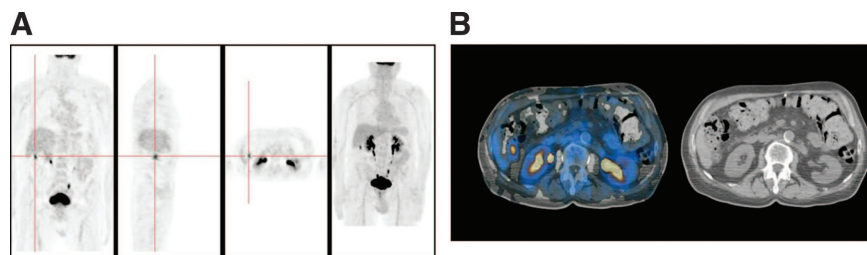


FIGURE 1. An 81-y-old man with cancer of sigmoid colon, after surgery, increasing carcinoembryonic antigen (CEA) serum levels, and a repeated negative CT study. (A) PET shows focal area of increased ^{18}F -FDG uptake in right upper abdomen. (B) Hybrid PET/CT images precisely localized this uptake to colon, consistent with physiologic bowel excretion. Malignancy was excluded and study was reported as normal. Patient had no evidence of recurrence in colon during 15 mo of clinical follow-up.

TABLE 3

Comparative Analysis of PET and PET/CT Patient-Based Performance in 36 Patients with Suspected Occult Cancer Recurrence Due to Rising Levels of Tumor Markers

Performance	PET	PET/CT
TP (n)	28	28
TN (n)	3	4
FP (n)	3	2
FN (n)	2	2
Sensitivity* (%)	93	93
Specificity* (%)	50	67
Accuracy* (%)	86	89

**P* not statistically significant.

statistically significant difference ($P < 0.01$) between the number of patients referred to a different treatment modality based on PET and PET/CT (Table 4).

PET/CT changed the clinical management of 9 of the 21 patients with colon cancer (54%), 2 of the 4 patients with lung cancer (50%), and 1 of the 7 patients with breast cancer (14%).

DISCUSSION

Early detection of tumor recurrence leading to subsequent resection of single malignant foci or to institution of systemic treatment may improve the prognosis of cancer patients (2). Although increasing tumor marker concentrations can precede detection of overt cancer up to 2 y (12–14), serial serum marker level monitoring has not led to a substantial improvement in survival of patients with tumors such as recurrent colorectal cancer (7).

CT is the primary tool of investigation for suspected recurrence due to its widespread availability and relatively low cost. However, the CT size-based criteria for malignancy may be inaccurate estimates of tumor involvement (5,15,16). Up to 50% of patients considered suitable candidates for curative surgery by CT are found to have unresectable, disseminated disease during surgery (4,16). CT is also challenging for differentiating a recurrent tumor from treatment-induced morphologic changes (17,18).

Exploratory laparotomy has a high detection rate for abdominal recurrences (4,19). However, detection of unforeseen neoplastic spread during surgery results in a high percentage of nonresectable tumors. In addition, about 5%–11% of explorations are negative for the presence of active cancer, in spite of elevated levels of serum markers (20).

The alternative strategy of relying only on the clinical observation of patients with increasing concentrations of tumor markers may miss the opportunity to resect limited disease (15). Surgeons, therefore, have emphasized the need for better preoperative identification of this subgroup of patients, who will derive the highest benefit from surgery (21).

^{18}F -FDG PET is a whole-body screening technique that may detect metabolic abnormalities preceding structural changes (11,22,23). PET detected occult recurrent colorectal cancer in up to 67% of patients with elevated carcinoembryonic antigen levels and had a good per-patient performance for diagnosis of recurrent tumors (23–25). This was also confirmed by the high TP rate in the present, more heterogeneous patient population. However, lesion-based performance of PET is less encouraging (26). Sites of recurrent tumor, such as pelvic metastases and diffuse peritoneal involvement, may be missed or falsely reported as physiologic or equivocal FDG uptake (5,24,25). PET, therefore, offers only a partial solution for the diagnostic and therapeutic dilemma of elevated levels of tumor markers and may induce the need for additional confirmatory diagnostic procedures.

PET/CT has been advocated as the tool of the future for the diagnosis of recurrent cancer (19,23,26). Hybrid imaging can precisely localize and improve the characterization of foci of increased ^{18}F -FDG uptake. In the present study population, the availability of simultaneous anatomic CT mapping by PET/CT precisely defined 18 equivocal sites (16%) of increased ^{18}F -FDG uptake as malignant or benign (Figs. 1 and 2). The anatomic location provided by fused images guided subsequent tissue diagnosis and therapeutic procedures in the setting of a small recurrent tumor load (Fig. 2). Although PET alone allowed for the correct diagnosis of recurrence in the majority of patients (83%), the statistically significant improved performance of hybrid im-

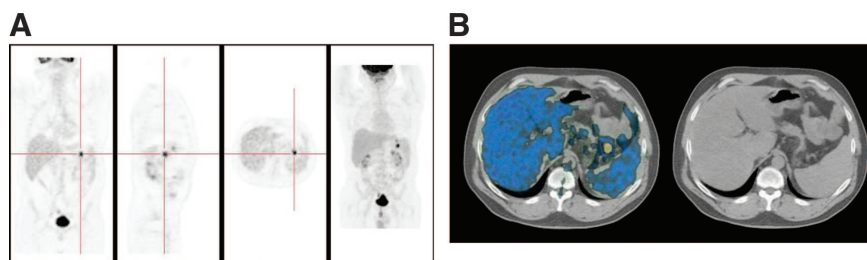


FIGURE 2. A 52-y-old man with colon cancer, after surgery, increasing carcinoembryonic antigen (CEA) serum levels, and a repeated negative CT study. (A) PET shows focal area of abnormal ^{18}F -FDG uptake in left upper abdomen, suggestive of recurrence. (B) Hybrid PET/CT images precisely localized this uptake anterior to tail

of pancreas, medial to spleen. Retrospective evaluation of CT performed 2 mo earlier and examination of CT study performed simultaneously with PET did not reveal any abnormalities. Surgeons used location provided by PET/CT for reexploration of abdomen and recurrent tumor in colon was found.

TABLE 4
Change in Patient Management Based on PET
and PET/CT Results

Referral	Based on PET	Based only on incremental contribution of PET/CT	Total based on PET/CT results
For surgery	1	8	9
For chemotherapy	13	2	15
For radiotherapy	2	2	4
Total	16	12	28

Differences between therapeutic strategy based on PET and PET/CT results were statistically significant ($P < 0.01$).

aging for evaluating individual lesions indicates that PET/CT has an impact on the subsequent management of cancer patients, beyond the diagnosis of recurrence. The precise PET/CT localization and definition of suspicious ^{18}F -FDG foci led to a better assessment of the extent of recurrent disease, with subsequent treatment planned on the basis of the unique information provided by hybrid imaging in one third of the total study population.

The clinical contribution of PET/CT is indicated mainly by the number of patients referred for resection with curative intent. Surgery was performed in 8 patients following PET/CT results, in addition to 1 patient who may have been referred to surgery based only on PET results. Six of these 8 patients were referred for surgery based solely on the results of hybrid imaging, sparing further unnecessary diagnostic procedures.

When PET, a highly sensitive test, indicates the presence of widespread disease, the precise localization of each malignant site is, as a rule, less clinically relevant. Of the present study population, 13 patients were referred for chemotherapy based on PET alone. Administration of chemotherapy to 2 additional patients was enabled by PET/CT-based precise definition of equivocal foci of ^{18}F -FDG uptake as additional malignant lesions and diagnosis of multifocal recurrence.

In the present study radiation therapy planning was modified in 2 patients after the use of PET/CT. The potentially important role of hybrid imaging in this clinical setting cannot be fully appreciated from this small patient sample.

In some of the evaluated patients, the relatively long time interval between the previous CT reported as negative and the current PET/CT study as well as the patient sample with different primary malignancies and a preponderance toward colorectal tumors are limitations of the present study. Including tumors with low metabolic rates, such as prostate cancer, may also induce biases in the study results. The benefit of improved selection criteria and the potential value of a positive PET study at baseline need to be assessed. Further studies with long-term follow-up in large homogeneous patient cohorts with single histologic tumor types

need to follow. These studies will have to clarify whether PET/CT should be used, in the future, as the first step in the evaluation of patients with suspected occult recurrent cancer.

CONCLUSION

The results of present study indicate that hybrid PET/CT plays a potential important role in the early diagnosis and assessment of the extent of relapsed disease in cancer patients with increasing concentrations of serum tumor markers as the single suspicion of recurrence, with a significant clinical impact on further treatment planning in one third of the patient population.

ACKNOWLEDGMENTS

The authors are grateful to Drs. Yodphat Krausz and David Groshar for their many useful suggestions and to Judy Buchanan for preparation of this manuscript. This research was supported in part by a Research Grant from the Israeli Cancer Association.

REFERENCES

- Duffy MJ. Clinical uses of tumor markers: a critical review. *Crit Rev Clin Lab Sci*. 2001;38:225–262.
- Sagar PM, Pemberton JH. Surgical management of locally recurrent rectal cancer. *Br J Surg*. 1996;83:293–304.
- Bakalagos EA, Burak WE, Young DC, et al. Is carcino-embryonic antigen useful in the follow-up management of patients with colorectal liver metastases? *Am J Surg*. 1999;177:2–6.
- Hida JI, Yasutomi M, Shindoh K, et al. Second-look operation for recurrent colorectal cancer based on carcinoembryonic antigen and imaging techniques. *Dis Colon Rectum*. 1996;39:74–79.
- Torizuka T, Nobezawa S, Kanno T, et al. Ovarian cancer recurrence: role for whole-body positron emission tomography using 2-[fluorine-18]-fluoro-2-deoxy-D-glucose. *Eur J Nucl Med*. 2002;29:797–803.
- Spaepen K, Stroobants S, Dupont P, et al. Prognostic value of positron emission tomography (PET) with fluorine-18 fluorodeoxyglucose (^{18}F FDG) after first-line chemotherapy in non-Hodgkin's lymphoma: is ^{18}F FDG-PET a valid alternative to conventional diagnostic methods? *J Clin Oncol*. 2001;19:414–419.
- Hung GU, Shiau YC, Tsai SC, et al. Value of ^{18}F -fluoro-2-deoxyglucose positron emission tomography in the evaluation of recurrent colorectal cancer. *Anticancer Res*. 2001;21:1375–1378.
- Cook GI, Maisey MN, Fogelman I. Normal variants, artifacts and interpretative pitfalls in PET imaging with 18-fluoro-deoxyglucose and carbon-11 methionine. *Eur J Nucl Med*. 1999;26:1363–1378.
- Kostakoglu L, Agreess H, Goldsmith J. Clinical role of FDG PET in evaluation of cancer patients. *Radiographics*. 2003;23:315–340.
- Beyer T, Townsend DW, Brun T, et al. A combined PET/CT scanner for clinical oncology. *J Nucl Med*. 2000;41:1369–1379.
- Bar-Shalom R, Yefremov N, Altman H, et al. The clinical performance of PET/CT in evaluation of cancer: additional value for diagnostic imaging and patient management. *J Nucl Med*. 2003;44:1200–1209.
- Lardinois D, Weder W, Hany TF, et al. Staging of non-small-cell lung cancer with integrated positron-emission tomography and computed tomography. *N Engl J Med*. 2003;348:2500–2507.
- Patt YZ, Podoloff DA, Curley S, et al. Technetium 99m-labeled IMM-4, a monoclonal antibody against carcinoembryonic antigen for imaging of occult recurrent colorectal cancer in patients with rising serum carcinoembryonic antigen levels. *J Clin Oncol*. 1994;12:489–495.
- Mangharak J, Patanachak C, Podhisuwan K, et al. The evaluation of combined scintimammography and tumor markers in breast cancer patients. *Anticancer Res*. 1997;17:1611–1614.
- Arulampalam THA, Costa DC, Loisdou M, et al. Positron emission tomography and colorectal cancer. *Br J Surg*. 2001;88:176–189.
- Bucheri G, Ferrigno D. Serum biomarkers facilitate the recognition of early-stage cancer and may guide the selection of surgical candidates: a study of

- carcinoembryonic antigen and tissue polypeptide antigen in patients with operable non-small cell lung cancer. *J Thorac Cardiovasc Surg.* 2001;122:891–899.
17. Zervos EE, Badgwell BD, Burak WE, et al. Fluorodeoxyglucose positron emission tomography as an adjunct to carcinoembryonic antigen in the management of patients with presumed recurrent colorectal cancer and nondiagnostic radiologic workup. *Surgery.* 2001;130:636–644.
 18. Jadvar H, Fischman AJ. Evaluation of pancreatic carcinoma with FDG PET. *Abdom Imaging.* 2001;26:254–259.
 19. Makhija S, Howden N, Edwards R, et al. Positron emission tomography/computed tomography imaging for the detection of recurrent ovarian and fallopian tube carcinoma: a retrospective review. *Gynecol Oncol.* 2002;85:53–58.
 20. Sijmons EA, Heintz AP. Second look and second surgery: second chance or second best? *Semin Oncol.* 2000;19:54–61.
 21. Wexner SD. Invited critique. *Arch Surg.* 1999;134:311–313.
 22. Flamen P, Hoekstra OS, Homans F, et al. Unexplained rising carcinoembryonic antigen (CEA) in the postoperative surveillance of colorectal cancer: the utility of positron emission tomography (PET). *Eur J Cancer.* 2001;37:862–869.
 23. Kalff V, Hicks RJ, Ware RE, et al. The clinical impact of ¹⁸F-FDG PET in patients with suspected or confirmed recurrence of colorectal cancer: a prospective study. *J Nucl Med.* 2002;43:492–499.
 24. Flanagan FL, Dehdashti F, Ogunbiyi OA, et al. Utility of FDG-PET for investigating unexplained plasma CEA elevation in patients with colorectal cancer. *Ann Surg.* 1998;227:319–323.
 25. Valk PE, Abella-Columna E, Haseman MK, et al. Whole-body PET imaging with ¹⁸F fluorodeoxyglucose in management of recurrent colorectal cancer. *Arch Surg.* 1999;134:503–511.
 26. Czernin J, Phelps ME. Positron emission tomography scanning: current and future applications. *Annu Rev Med.* 2002;53:89–112.

