

---

# Quantitative Measurement of Regional Cerebrovascular Reactivity to Acetazolamide Using $^{123}\text{I}$ -*N*-Isopropyl-*p*-Iodoamphetamine Autoradiography with SPECT: Validation Study Using $\text{H}_2^{15}\text{O}$ with PET

Kuniaki Ogasawara, MD<sup>1,2</sup>; Hiroshi Ito, MD<sup>3</sup>; Masayuki Sasoh, MD<sup>1,2</sup>; Taku Okuguchi, MD<sup>1,2</sup>; Masakazu Kobayashi, MD<sup>1,2</sup>; Hirotsugu Yukawa, MD<sup>1,2</sup>; Kazunori Terasaki, PhD<sup>2</sup>; and Akira Ogawa, MD<sup>1,2</sup>

<sup>1</sup>Department of Neurosurgery, Iwate Medical University, Morioka, Japan; <sup>2</sup>Cyclotron Research Center, Iwate Medical University, Morioka, Japan; and <sup>3</sup>Department of Radiology and Nuclear Medicine, Akita Research Institute of Brain and Blood Vessels, Akita, Japan

A simplified technique using  $^{123}\text{I}$ -*N*-isopropyl-*p*-iodoamphetamine ( $^{123}\text{I}$ -IMP) autoradiography (ARG) with SPECT has been proposed recently for quantifying regional cerebral blood flow (rCBF). To validate the accuracy of  $^{123}\text{I}$ -IMP-ARG for quantifying regional cerebrovascular reactivity (rCVR) to acetazolamide, we compared rCVR determined using  $^{123}\text{I}$ -IMP-ARG with that determined using  $\text{H}_2^{15}\text{O}$  PET. **Methods:** Thirty-nine patients with chronic stenocclusive disease in a unilateral major cerebral artery underwent SPECT and PET studies before and after intravenous administration of acetazolamide. The rCBF images in the 4 conditions in each patient were calculated according to the ARG method. The same standard input function and the same distribution volume of 35 mL/mL were used in the calculation of rCBF images using the  $^{123}\text{I}$ -IMP-ARG method at resting state and with acetazolamide challenge. One large cortical region of interest (ROI) for a unilateral middle cerebral artery territory was bilaterally determined on each standardized summed rCBF image. On the basis of the rCBF values in each ROI, rCVR to acetazolamide was calculated as follows: rCVR (%) =  $([\text{acetazolamide challenge rCBF} - \text{resting rCBF}]/\text{resting rCBF}) \times 100$ . **Results:** Significant correlation was observed between rCVR values obtained using  $^{123}\text{I}$ -IMP-ARG and  $\text{H}_2^{15}\text{O}$  PET methods in the 78 ROIs examined in the 39 patients ( $r = 0.820$ ;  $P < 0.0001$ ). When a rCVR lower than the mean  $- 2$  SD of values obtained in healthy volunteers (18.4% for  $^{123}\text{I}$ -IMP-ARG and 18.2% for  $\text{H}_2^{15}\text{O}$  PET) was defined as reduced, and when the  $\text{H}_2^{15}\text{O}$  PET method was assumed to represent the true determinant of rCVR,  $^{123}\text{I}$ -IMP-ARG was 90% sensitive and 92% specific and displayed an 87% positive predictive value for detecting patients with reduced rCVR. **Conclusion:** These findings demonstrate that  $^{123}\text{I}$ -IMP-ARG methods accurately quan-

tify rCVR and can adequately define subgroups of patients with reduced rCVR.

**Key Words:** cerebral blood flow quantitation; cerebrovascular reactivity; brain SPECT;  $^{123}\text{I}$ -*N*-isopropyl-*p*-iodoamphetamine

**J Nucl Med 2003; 44:520–525**

**E**valuation of the regional cerebrovascular reactivity (rCVR) to a cerebral vasodilatory stimulus is important in the investigation of patients with ischemic cerebrovascular disease. Qualitative or quantitative measurement of regional cerebral blood flow (rCBF) using SPECT with  $^{99\text{m}}\text{Tc}$ -hexamethylpropyleneamine oxime,  $^{99\text{m}}\text{Tc}$ -ethylcysteinate dimer,  $^{123}\text{I}$ -*N*-isopropyl-*p*-iodoamphetamine ( $^{123}\text{I}$ -IMP), or  $^{133}\text{Xe}$  has been widely used for assessing rCVR (1–6). Recent prospective studies have demonstrated that rCVR to acetazolamide determined quantitatively by  $^{133}\text{Xe}$  SPECT can predict the outcome of major cerebral arterial occlusive disease (7,8), whereas Yokota et al. (9) reported a prospective study using qualitative measurement of rCVR to acetazolamide with  $^{123}\text{I}$ -IMP SPECT that failed to find an association between hemodynamic failure and stroke risk. As Yonas et al. (10,11) indicated, qualitative assessment of acetazolamide reactivity is known to have low sensitivity and specificity for detecting patients with a compromised reserve. These authors reported that the positive predictive value of the qualitative methods was 50%. Therefore, the possibility arises that the acetazolamide reactivity of some patients has been incorrectly classified by qualitative analysis.

Recently, a simplified technique known as  $^{123}\text{I}$ -IMP-*autoradiography* (ARG), which requires only 1-point arterial blood sampling and the acquisition of a single static

Received Jul. 25, 2002; revision accepted Oct. 31, 2002.

For correspondence or reprints contact: Kuniaki Ogasawara, MD, Department of Neurosurgery, Iwate Medical University, 19-1 Uchimaru, Morioka, 020-8505 Japan.

E-mail: kuogasa@iwate-med.ac.jp

scan, has been developed to quantify rCBF using  $^{123}\text{I}$ -IMP and SPECT (12,13). The  $^{123}\text{I}$ -IMP-ARG method is based on the 2-compartment model for tracer kinetics. The method uses a standard arterial input calibrated by the radioactivity of a single arterial whole-blood sample, a standard lipophilic fraction of  $^{123}\text{I}$ -IMP in whole blood, and a fixed distribution volume ( $V_d$ ) of  $^{123}\text{I}$ -IMP. Previous studies have demonstrated a good correlation between rCBF at the resting state measured by PET with  $\text{H}_2^{15}\text{O}$  and that measured by the  $^{123}\text{I}$ -IMP-ARG method (12,14).

The aim of this study was to validate the accuracy of the  $^{123}\text{I}$ -IMP-ARG method for quantifying rCVR to acetazolamide. We compared rCVR with acetazolamide determined quantitatively by the  $^{123}\text{I}$ -IMP-ARG method using SPECT with that determined quantitatively by the  $\text{H}_2^{15}\text{O}$  autoradiographic method using PET in patients who had chronic stenocclusive disease in a unilateral major cerebral artery.

## MATERIALS AND METHODS

### Subjects

**Healthy Volunteers.** We studied 14 male and 6 female healthy volunteers between 30 and 68 y old (mean  $\pm$  SD,  $53 \pm 11$  y old) to measure the normal values of rCBF by SPECT or PET. Screening of the health status included a medical review of past history, a physical examination, and neurologic and mental tests. Subjects having a past history of hypertension, diabetes mellitus, atrial fibrillation, or pulmonary disease were excluded. Before the SPECT study or the PET study, brain CT was performed to rule out organic lesions of the brain. Subjects with leukoaraiosis or asymptomatic lacunar infarction were excluded from this study. These healthy volunteers were divided into 2 groups; the first group (7 men, 3 women; mean age,  $52 \pm 12$  y; range, 30–68 y) participated in the SPECT study and the second group (7 men, 3 women; mean age,  $53 \pm 11$  y; range, 35–66 y) participated in the PET study.

**Stroke Patients.** From March 1997 to September 1998, 157 patients with unilateral chronic major cerebral artery stenocclusive disease and a history of minor past strokes or transient ischemic attacks (TIAs) were admitted to our institute for evaluation of rCBF. Of the 157 patients, 39 (27 men, 12 women; mean age,  $62 \pm 12$  y; range, 35–76 y) who underwent both SPECT and PET studies were included in the study. All patients had their last cerebral ischemic event  $>2$  mo before entry into the study. No patient had pulmonary disease. Brain CT or MRI and cerebral angiography were performed before PET and SPECT studies in all patients. No infarction or border zone infarction or lacunar infarction in the basal ganglia or deep white matter was observed in any of the patients. Twenty-two of the 39 patients examined had minor past strokes with definite cerebral infarctions on CT or MRI, and 10 had only TIAs with definite cerebral infarctions. The remaining 7 patients had TIAs without definite cerebral infarctions. Unilateral atherosclerotic vascular lesions were noted on the trunk of the middle cerebral artery (MCA) in 16 patients (10 occlusions, 6 stenoses) and the internal carotid artery (ICA) in 23 patients (13 occlusions, 10 stenoses).

Informed consent was obtained from all participants and the study was approved by our Ethics Committee.

### $^{123}\text{I}$ -IMP SPECT Study

SPECT studies were performed using a ring-type SPECT scanner, a Headtome-SET080 (Shimadzu Corp., Kyoto, Japan), which provides 31 tomographic images simultaneously. The spatial resolution of the scanner with a low-energy, all-purpose collimator was 13-mm full width at half maximum at the center of the field of view, and the slice thickness was 25-mm full width at half maximum at the center of the field of view. Image slices were taken at 5-mm center-to-center spacing parallel to the orbitomeatal line. The images were reconstructed using the weighted-filtered back-projection technique, in which attenuation correction was made by detecting the edge of the object. An attenuation coefficient of  $0.065 \text{ cm}^{-1}$ , a Butterworth filter (cutoff, 0.45 cycle/cm; order, 3), and a ramp filter were used for image reconstruction.

The  $^{123}\text{I}$ -IMP SPECT study was performed as described (12,13). After a 1-min intravenous infusion of 222 MBq of  $^{123}\text{I}$ -IMP (5-mL volume) at a constant rate of 5 mL/min and a 1-min infusion of physiologic saline at the same rate, data acquisition was performed at a midscan time of 30 min after the  $^{123}\text{I}$ -IMP administration for a scan duration of 20 min.

At 10 min after the beginning of the  $^{123}\text{I}$ -IMP infusion, arterial blood (2 mL) was taken from the brachial artery. The whole-blood radioactivity of 1 mL of each blood sample obtained was measured using a well counter that was cross-calibrated to the SPECT scanner. The arterial partial pressures of  $\text{O}_2$  ( $\text{PaO}_2$ ) and  $\text{CO}_2$  ( $\text{PaCO}_2$ ) and the blood pH were also measured in the remaining blood samples using a blood gas tension analyzer.

Two days after the measurement of the rCBF at the resting state, subjects underwent SPECT with acetazolamide challenge. Acetazolamide (1,000 mg; range, 13–19 mg/kg body weight) was given intravenously 10 min before  $^{123}\text{I}$ -IMP administration, and the SPECT study was performed by the same procedure as for the resting state.

All reconstructed SPECT images were corrected for the radioactive decay of  $^{123}\text{I}$  back to the  $^{123}\text{I}$ -IMP injection start time, normalized by the data collection time and cross-calibrated to the well counter system. The rCBF images were calculated according to the  $^{123}\text{I}$ -IMP-ARG method (12). The whole-blood radioactivity counts of the single blood sample were referred to the standard input function. The same standard input function at the resting state was used in the calculation of rCBF with acetazolamide challenge (15). The  $V_d$  value was assumed to be 35 mL/mL in the calculation of rCBF images both at resting state and with acetazolamide challenge (16,17).

### $\text{H}_2^{15}\text{O}$ PET Study

All patients underwent PET 2 d before SPECT at the resting state. We used a 4-ring, 7-slice PET scanner (Headtome-IV; Shimadzu Corp.) with in-plane and axial resolutions of 8 and 10 mm, respectively (18). The PET scanner provides 14 tomographic images with 6.5-mm intervals by the continuous axial motion of the gantry. The image slices were parallel to the orbitomeatal line (same as for the SPECT studies).

Before emission scanning, a transmission scan using a  $^{68}\text{Ga}$ - $^{68}\text{Ge}$  line source was obtained to correct tissue attenuation. The rCBF was calculated using the ARG method with 90-s scanning after an intravenous bolus injection of 1,110 MBq  $\text{H}_2^{15}\text{O}$  (19). Continuous arterial blood sampling and  $\beta$ -ray monitoring with a scintillator were conducted throughout PET scanning using a catheter implanted in the radial artery to obtain the arterial input

function.  $\text{PaO}_2$  and  $\text{PaCO}_2$  and the blood pH were also measured in the same blood samples.

The PET studies at the resting state and with acetazolamide challenge were performed on the same day. Ten minutes after the resting rCBF measurement, acetazolamide (1,000 mg; range, 13–19 mg/kg body weight) was given intravenously. Fifteen minutes later, the rCBF was measured by the same procedure as for the resting state.

Blood pressure was measured by auscultation twice for each CBF measurement. The average values of mean blood pressure in each CBF measurement were used to assess the change in mean blood pressure.

### Data Analysis

All SPECT and PET images obtained were analyzed as follows. Coregistration and anatomic standardization were performed on a  $128 \times 128 \times 60$  matrix ( $2.25 \times 2.25 \times 2.25$  mm) for each rCBF image, using part of a program set within NEUROSTAT (20–22). Slices between the anterior commissure–posterior commissure level (AC–PC level) – 11.25 mm and the AC–PC level + 9 mm of the standardized images, which had nearly identical cortical shapes, were summed for region-of-interest (ROI) analysis. The outer cortical border was automatically drawn on the section, and the inner cortical border was drawn 15.75 mm (7 pixels  $\times$  2.25 mm) further inward. The cortical ribbon was then divided into twelve  $30^\circ$  sectors in a clockwise fashion, and we defined  $30^\circ$  to  $150^\circ$  sectors as the left MCA territory and  $210^\circ$  to  $330^\circ$  sectors as the right MCA territory (Fig. 1). Thus, 1 large cortical ROI for each unilateral hemisphere was determined on each standardized summed rCBF image. Furthermore, the ROI was set bilaterally in all subjects.

On the basis of the rCBF values in each ROI, rCVR to acetazolamide was calculated as follows:  $\text{rCVR} (\%) = (\text{acetazolamide challenge rCBF} - \text{resting rCBF}) / \text{resting rCBF} \times 100$ .

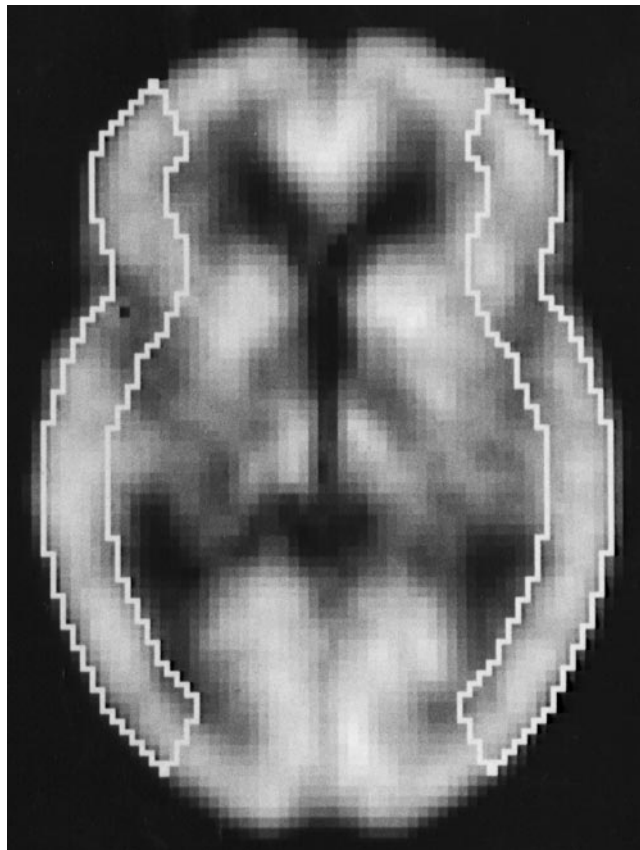
For statistical analysis, the data were expressed as the mean  $\pm$  SD, and differences among the 4 groups were examined by repeated-measures ANOVA. Correlation between various parameters was determined by linear regression analysis. Statistical significance was set at the  $P < 0.05$  level.

### RESULTS

The values of rCBF at the resting state and with acetazolamide challenge and rCVR obtained by the  $^{123}\text{I}$ -IMP-ARG method in 20 ROIs of the first group (10 healthy volunteers) were  $35.9 \pm 4.4$  mL/100 g/min,  $48.7 \pm 5.0$  mL/100 g/min, and  $36.8\% \pm 9.2\%$ , respectively. The same values obtained by the  $\text{H}_2^{15}\text{O}$  PET method in 20 ROIs of the second group (10 healthy volunteers) were  $43.5 \pm 3.1$  mL/100 g/min,  $58.7 \pm 5.8$  mL/100 g/min, and  $34.8\% \pm 8.3\%$ , respectively. For the  $^{123}\text{I}$ -IMP-ARG method and the  $\text{H}_2^{15}\text{O}$  PET method, rCVR in the healthy volunteers was not age dependent.

Table 1 shows the average values of the physiologic variables measured in the 39 patients during SPECT and PET scanning at the resting state and after acetazolamide administration. No significant difference in  $\text{PaO}_2$ ,  $\text{PaCO}_2$ , blood pH, or mean blood pressure was observed among the 4 conditions (repeated-measures ANOVA).

Figure 2 shows comparisons of rCBF values obtained by the  $^{123}\text{I}$ -IMP-ARG method and those by the  $\text{H}_2^{15}\text{O}$  PET



**FIGURE 1.** Regions of interest in image slice standardized and summed using 3-dimensional stereotactic surface projections.

method (resting state and acetazolamide challenge, respectively) in 78 ROIs of 39 patients. In both conditions, the fits to the regression lines were significant ( $P < 0.0001$ ), with the correlation coefficients being 0.808 and 0.872, respectively. In particular, rCBF values obtained by the  $^{123}\text{I}$ -IMP-ARG method were highly consistent with those obtained by the  $\text{H}_2^{15}\text{O}$  PET method in the hypoperfusion areas. However, the rCBF values obtained by the  $^{123}\text{I}$ -IMP-ARG method were underestimated with increase in rCBF. Representative images are shown in Figure 3.

Figure 4 shows comparisons of rCVR values obtained by the  $^{123}\text{I}$ -IMP-ARG method and those by the  $\text{H}_2^{15}\text{O}$  PET method in 78 ROIs of 39 patients. Significant correlation was observed between the 2 methods ( $r = 0.820$ ;  $P < 0.0001$ ). When a rCVR lower than the mean – 2 SD of the values obtained in healthy volunteers (18.4% for the  $^{123}\text{I}$ -IMP-ARG method and 18.2% for the  $\text{H}_2^{15}\text{O}$  PET method, respectively) was defined as reduced, and when the  $\text{H}_2^{15}\text{O}$  PET method was assumed to be the true determinant (or gold standard) of rCVR, 4 of 31 ROIs (13%) in which the  $^{123}\text{I}$ -IMP-ARG method identified reduced rCVR were considered false-positives. The values of rCVR obtained by the  $^{123}\text{I}$ -IMP-ARG method in these 4 ROIs with false-positives were 13.1%–17.8%. No ROIs with rCVR lower than the

**TABLE 1**  
Physiologic Data of 39 Patients Measured During SPECT and PET at Rest and with Acetazolamide Challenge

Parameter	SPECT		PET	
	Rest	ACZ	Rest	ACZ
pH	7.39 ± 0.03	7.40 ± 0.03	7.40 ± 0.04	7.41 ± 0.03
Paco <sub>2</sub> (mm Hg)	41.8 ± 3.0	40.1 ± 2.8	40.6 ± 2.9	39.9 ± 3.1
PaO <sub>2</sub> (mm Hg)	94.1 ± 2.9	95.9 ± 4.3	94.8 ± 3.1	96.8 ± 4.1
Mean blood pressure (mm Hg)	95.1 ± 8.1	96.6 ± 8.2	95.9 ± 7.6	97.1 ± 9.8

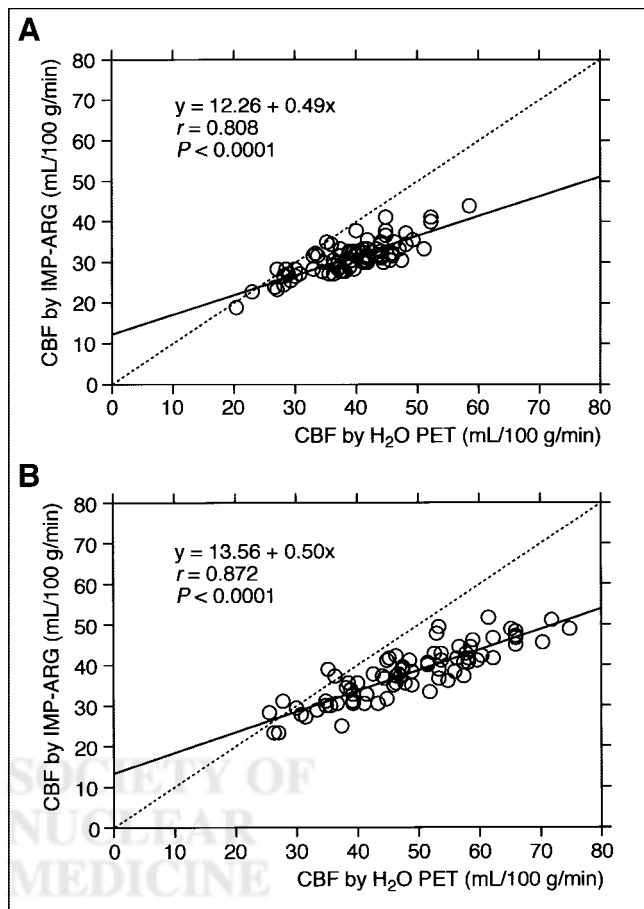
ACZ = acetazolamide; Paco<sub>2</sub> = arterial carbon dioxide tension; Pao<sub>2</sub> = arterial oxygen tension.

mean - 3 SD of the values obtained in healthy volunteers (9.2%) exhibited false-positives. Conversely, the H<sub>2</sub><sup>15</sup>O PET method detected reduced rCVR in 3 of the 47 ROIs (6%) identified as having no reduced rCVR using the <sup>123</sup>I-IMP-ARG method (false-negatives). The values of rCVR obtained by the <sup>123</sup>I-IMP-ARG method in these 3 ROIs with false-negatives were 20.9%–25.5%. No ROIs with rCVR higher than the mean - 1 SD of the values obtained in

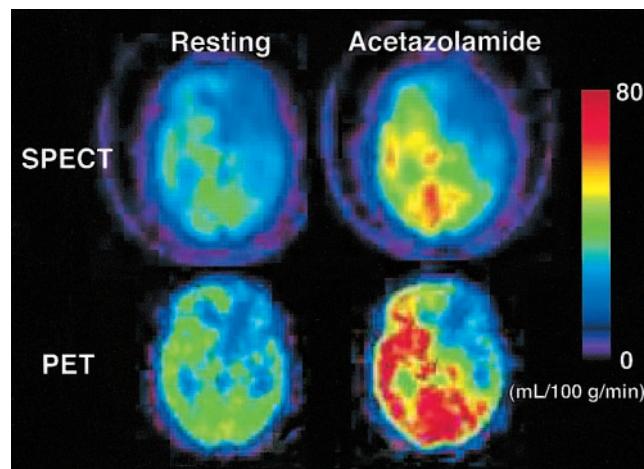
healthy volunteers (27.6%) exhibited false-negative findings. Both analytic approaches obtained identical results in 91% of the ROIs; 35% (27/78 ROIs) were true-positives and 56% (44/78 ROIs) were true-negatives. Sensitivity, specificity, and predictive values were calculated for the <sup>123</sup>I-IMP-ARG method of assessing rCVR. The <sup>123</sup>I-IMP-ARG and H<sub>2</sub><sup>15</sup>O PET methods will identify the same patients as positive 90% of the time (sensitivity). The 2 methods will identify the same patients as negative 92% of the time (specificity). A patient that the <sup>123</sup>I-IMP-ARG method identifies as positive will be positive according to the H<sub>2</sub><sup>15</sup>O PET method 87% of the time (positive predictive value). A patient that the <sup>123</sup>I-IMP-ARG method identifies as negative will be negative according to the H<sub>2</sub><sup>15</sup>O PET method 94% of the time (negative predictive value).

## DISCUSSION

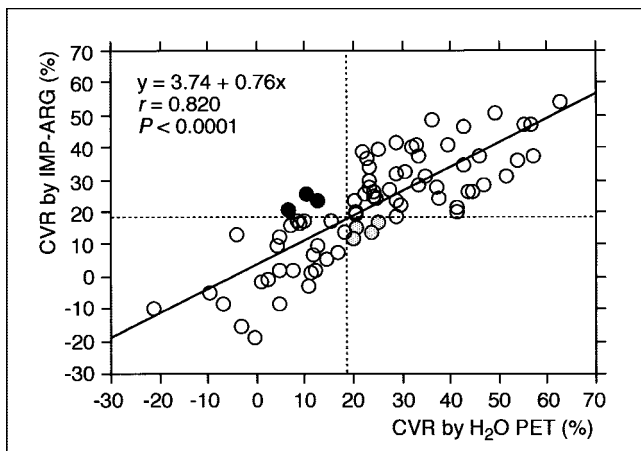
Our findings indicated that the <sup>123</sup>I-IMP-ARG method accurately quantifies rCVR to acetazolamide, with a high correlation ( $r = 0.820$ ) between rCVR values obtained by the <sup>123</sup>I-IMP-ARG method and those obtained by the H<sub>2</sub><sup>15</sup>O



**FIGURE 2.** Correlations of rCBF values calculated by <sup>123</sup>I-IMP-ARG method with those calculated by H<sub>2</sub><sup>15</sup>O PET method. (A) Resting state. (B) Acetazolamide challenge. Significant correlation was observed in both conditions. Dashed straight line denotes line of identity.



**FIGURE 3.** Functional rCBF images calculated by <sup>123</sup>I-IMP-ARG method and those calculated by H<sub>2</sub><sup>15</sup>O PET method. Data were obtained from patient with left ICA occlusion. Same color scale is used to display these 2 quantitative rCBF images. rCBF images obtained by <sup>123</sup>I-IMP-ARG method are reduced in high rCBF areas compared with PET images.



**FIGURE 4.** Correlation of rCVR values calculated by  $^{123}\text{I}$ -IMP-ARG method with those calculated by  $\text{H}_2^{15}\text{O}$  PET method. Significant correlation was observed between these 2 values. Plot of relationship between these 2 values revealed 4 groups of results: (a) those with reduced rCVR (true-positive; ○); (b) those that only  $\text{H}_2^{15}\text{O}$  PET method identified as reduced rCVR (false-negative; ●); (c) those without reduced rCVR (true-negative; ○); and (d) those considered reduced rCVR only by  $^{123}\text{I}$ -IMP-ARG method (false-positive; ⊙). Dashed horizontal and vertical lines denote mean  $- 2$  SD of rCVR values obtained in healthy volunteers by  $^{123}\text{I}$ -IMP-ARG method and by  $\text{H}_2^{15}\text{O}$  PET method, respectively.

PET method. On the other hand, recent prospective studies have demonstrated that rCVR lower than the mean  $- 2$  SD or the 95% confidence limit of the values quantitatively obtained in healthy volunteers using  $^{133}\text{Xe}$  SPECT is significantly associated with an increased risk of stroke recurrence in patients with symptomatic MCA or ICA occlusion (7,8). Therefore, we defined rCVR lower than the mean  $- 2$  SD of the values obtained in healthy volunteers as reduced—that is, being at high risk of stroke recurrence. We also assumed the  $\text{H}_2^{15}\text{O}$  PET method to be the true determinant (or gold standard) of rCVR. As a result, our study showed that the  $^{123}\text{I}$ -IMP-ARG method is 90% sensitive and 92% specific for detecting patients with reduced rCVR. The positive predictive value using the  $^{123}\text{I}$ -IMP-ARG method is 87%, and the negative predictive value is 94%. These findings suggest that the subgroup of patients at increased risk for stroke recurrence can be adequately defined by rCVR quantitatively measured using the  $^{123}\text{I}$ -IMP-ARG method.

This study also showed the high correlation of rCBF values obtained by the  $^{123}\text{I}$ -IMP-ARG method with those obtained by the  $\text{H}_2^{15}\text{O}$  PET method. In particular, the 2 values coincided strongly in the hypoperfusion areas. These findings are noteworthy because correct quantification of rCBF values in the ischemic territories is the greatest clinical problem. On the other hand, the rCBF values obtained by the  $^{123}\text{I}$ -IMP-ARG method were underestimated as rCBF increased, which resulted in the slopes of the linear regression lines being significantly smaller than that of the identity line. This may be due to errors in the SPECT reconstruction, such as imperfect attenuation correction, scatter, and limited

spatial resolution of the scanner (partial-volume effect). Another possible explanation for the systematic underestimation at high flow may be due to the limited first-pass extraction fraction of  $^{123}\text{I}$ -IMP in the brain (23). The use of a fixed  $V_d$  may also be one of the reasons why the rCBF values obtained by the  $^{123}\text{I}$ -IMP-ARG method were underestimated as rCBF increased. Because we performed coregistration and anatomic standardization for each rCBF image, and there was no significant difference in  $\text{PaO}_2$ ,  $\text{Paco}_2$ , blood pH, or mean blood pressure among each study, factors such as misalignment of ROIs and physiologic change in rCBF are unlikely to have contributed to the observed difference in rCBF values between the  $^{123}\text{I}$ -IMP-ARG method and the  $\text{H}_2^{15}\text{O}$  PET method.

This study possesses several limitations regarding the  $^{123}\text{I}$ -IMP-ARG method. First, the method uses the same standard arterial input function both at the resting state and after acetazolamide administration instead of the measurement of arterial radioactivity. Hauge et al. (24) examined the pharmacologic effects on the cerebral and systemic conditions of acetazolamide and concluded that cardiac output and total peripheral resistance were unaltered during acetazolamide loading. Takeuchi et al. (25) also monitored cardiac output and systemic blood pressure during acetazolamide administration in healthy volunteers using an ultrasound Doppler system, with no significant changes observed. Furthermore, Ogura et al. (15) compared the percentage difference in the area under the curve of the estimated from the real arterial input functions between the resting and acetazolamide analyses of 19 cases. No significant difference in the area under the curve was observed between the 2 study groups. The integration period was 40 min, and the standardized input function was calibrated using a single sample at 10 min. Thus, arterial input after acetazolamide administration could be regarded as being the same as that at the resting state. Second, the  $V_d$  was assumed to be the same value (35 mL/mL) at the resting state and after acetazolamide administration. The mean  $V_d$  value of  $^{123}\text{I}$ -IMP for the normal cortex is  $37.5 \pm 3.6$  mL/g and is independent of age and sex (16). In addition, Toyoda et al. (17) demonstrated that the optimal values for  $V_d$  at the resting state and after acetazolamide administration were both in the range of 30–35 mL/mL and the difference between the values at the resting state and after acetazolamide administration was very small. Therefore, the  $V_d$  could be set as the constant value of 35 mL/mL both at the resting state and after acetazolamide administration.

## CONCLUSION

The  $^{123}\text{I}$ -IMP-ARG method can be performed using conventional SPECT scanners (12,14) and does not require frequent arterial blood sampling. This allows the technique to be used much more readily in assessing patients with major cerebral artery occlusive disease in routine clinical practice, although  $^{123}\text{I}$ -IMP is now unavailable in the West

because of the cost. Our study suggests that the ability of the  $^{123}\text{I}$ -IMP-ARG method to detect reduced rCVR is almost identical to that of the  $\text{H}_2^{15}\text{O}$  PET method and that the subgroup of patients at increased risk for stroke recurrence can be adequately defined by rCVR quantitatively measured using the  $^{123}\text{I}$ -IMP-ARG method. Whether extracranial–intracranial arterial bypass surgery, which improves impaired cerebral hemodynamics (26,27), reduces the risk of stroke in this subgroup remains unclear. Preoperative low rCVR quantitatively obtained using SPECT has been shown to be significantly associated with an increased risk of hyperperfusion syndrome after carotid endarterectomy (28,29). Standardization of hemodynamic compromise measurement and further investigation to assess the usefulness of extracranial–intracranial arterial bypass surgery or the risk of hyperperfusion syndrome after carotid endarterectomy would be of great benefit.

## ACKNOWLEDGMENTS

The authors thank Prof. Satoshi Minoshima, University of Washington Medical School, for the use of 3-dimensional stereotactic surface projections (NEUROSTAT) and his helpful suggestions. This work was supported in part by Grants-in-Aid for Advanced Medical Scientific Research by the Ministry of Science, Education, Sports and Culture, Japan.

## REFERENCES

- Burt RW, Witt RM, Cikrit DF, Reddy RV. Carotid artery disease: evaluation with acetazolamide-enhanced Tc-99m HMPAO SPECT. *Radiology*. 1992;182:461–466.
- Hoshi H, Ohnishi T, Jinnouchi S, et al. Cerebral blood flow study in patients with moyamoya disease evaluated by IMP SPECT. *J Nucl Med*. 1994;35:44–50.
- Soricelli A, Postiglione A, Cuocolo A, et al. Effect of adenosine on cerebral blood flow as evaluated by single-photon emission computed tomography in normal subjects and in patients with occlusive carotid disease: a comparison with acetazolamide. *Stroke*. 1995;26:1572–1576.
- Ohnishi T, Yano T, Nakano S, et al. Acetazolamide challenge and technetium-99m-ECD versus iodine-123-IMP SPECT in chronic occlusive cerebrovascular disease. *J Nucl Med*. 1997;38:1463–1467.
- Kikuchi K, Murase K, Miki H, et al. Measurement of cerebral hemodynamics with perfusion-weighted MR imaging: comparison with pre- and post-acetazolamide  $^{133}\text{Xe}$ -SPECT in occlusive carotid disease. *AJNR*. 2001;22:248–254.
- Ozgun HT, Kent Walsh T, Masaryk A, et al. Correlation of cerebrovascular reserve as measured by acetazolamide-challenged SPECT with angiographic flow patterns and intra- or extracranial arterial stenosis. *AJNR*. 2001;22:928–936.
- Kuroda S, Houkin K, Kamiyama H, Mitsumori K, Iwasaki Y, Abe H. Long-term prognosis of medically treated patients with internal carotid or middle cerebral artery occlusion: can acetazolamide test predict it? *Stroke*. 2001;32:2110–2116.
- Ogasawara K, Ogawa A, Yoshimoto T. Cerebrovascular reactivity to acetazolamide and outcome in patients with symptomatic internal carotid or middle cerebral artery occlusion: a xenon-133 single-photon emission computed tomography study. *Stroke*. 2002;33:1857–1862.
- Yokota C, Hasegawa Y, Minematsu K, Yamaguchi T. Effect of acetazolamide reactivity and long-term outcome in patients with major cerebral artery occlusive diseases. *Stroke*. 1998;29:640–644.

- Yonas H, Pindzola RR, Meltzer CC, Sasser H. Qualitative versus quantitative assessment of cerebrovascular reserves. *Neurosurgery*. 1998;42:1005–1012.
- Yonas H, Pindzola RR. Effect of acetazolamide reactivity and long-term outcome in patients with major cerebral artery occlusive diseases. *Stroke*. 1998;29:1742–1744.
- Iida H, Itoh H, Nakazawa M, et al. Quantitative mapping of regional cerebral blood flow using iodine-123-IMP and SPECT. *J Nucl Med*. 1994;35:2019–2030.
- Iida H, Itoh H, Bloomfield PM, et al. A clinical method to quantitate cerebral blood flow using a rotating gamma camera and iodine-123 iodoamphetamine with one blood sampling. *Eur J Nucl Med*. 1994;21:1072–1084.
- Iida H, Akutsu T, Endo K, et al. A multicenter validation of regional cerebral blood flow quantitation using [ $^{123}\text{I}$ ]iodoamphetamine and single photon emission computed tomography. *J Cereb Blood Flow Metab*. 1996;16:781–793.
- Ogura T, Takikawa S, Saito H, Nakazawa M, Shidahara M, Iida H. Validation and optimization of the use of standardized arterial input function in N-isopropyl- $^{123}\text{I}$ iodoamphetamine cerebral blood flow SPECT. *Kaku Igaku*. 1999;36:879–890.
- Hatazawa J, Iida H, Shimosegawa E, Sato T, Murakami M, Miura Y. Regional cerebral blood flow measurement with iodine-123-IMP autoradiography: normal values, reproducibility and sensitivity to hypoperfusion. *J Nucl Med*. 1997;38:1102–1108.
- Toyoda H, Nishizawa S, Shiozaki T, Ueno M, Konishi J. A simplified double-injection method to quantify cerebral blood flow and vascular reserve using iodine-123 IMP-SPECT. *Ann Nucl Med*. 2002;16:127–135.
- Iida H, Miura S, Kanno I, Murakami M, Takahashi K, Uemura K. Design and evaluation of Headtome-IV: a whole-body positron emission tomograph. *IEEE Trans Nucl Sci*. 1989;36:1006–1010.
- Kanno I, Iida H, Miura S, et al. A system for cerebral blood flow measurement using an  $\text{H}_2^{15}\text{O}$  autoradiographic method and positron emission tomography. *J Cereb Blood Flow Metab*. 1987;7:143–153.
- Minoshima S, Frey KA, Koeppe RA, Foster NL, Kuhl DE. A diagnostic approach in Alzheimer's disease using three-dimensional stereotactic surface projections of fluorine-18-FDG PET. *J Nucl Med*. 1995;36:1238–1248.
- Minoshima S, Koeppe RA, Fessler JA, et al. Integrated and automated data analysis method for neuronal activation studies using  $^{15}\text{O}$ -water PET. In: Uemura K, Lassen NA, Jones T, Kanno I, eds. *Quantification of Brain Function: Tracer Kinetics and Image Analysis in Brain PET*. Amsterdam, The Netherlands: Excerpta Medica; 1993:409–417.
- Maes F, Collignon A, Vandermeulen D, Marchal G, Suetens P. Multimodality image registration by maximization of mutual information. *IEEE Trans Med Imaging*. 1997;16:187–198.
- Murase K, Tanada S, Inoue T, et al. Measurement of the blood-brain-barrier permeability of I-123 IMP, Tc-99m HMPAO and Tc-99m ECD in the human brain using compartment model analysis and dynamic SPECT [abstract]. *J Nucl Med*. 1995;32(suppl):911P.
- Hauge A, Nicolaysen G, Thoresen M. Acute effects of acetazolamide on cerebral blood flow in man. *Acta Physiol Scand*. 1983;117:233–239.
- Takeuchi R, Matsuda H, Yonekura Y, Sakahara H, Konishi J. Noninvasive quantitative measurements of regional cerebral blood flow using technetium-99m-L-L-ECD SPECT activated with acetazolamide: quantification analysis by equal-volume-split  $^{99m}\text{Tc}$ -ECD consecutive SPECT method. *J Cereb Blood Flow Metab*. 1997;17:1020–1032.
- Samson Y, Baron JC, Boussier MG, et al. Effects of extra-intracranial arterial bypass on cerebral blood flow and oxygen metabolism in humans. *Stroke*. 1985;16:609–616.
- Schmiedek P, Piepgras A, Leinsinger G, Kirsch CM, Einhuyl K. Improvement of cerebrovascular reserve capacity by EC-IC arterial bypass surgery in patients with ICA occlusion and hemodynamic cerebral ischemia. *J Neurosurg*. 1994;81:236–244.
- Hosoda K, Kawaguchi T, Shibata Y, et al. Cerebral vasoreactivity and internal carotid artery flow help to identify patients at risk for hyperperfusion after carotid endarterectomy. *Stroke*. 2001;32:1567–1573.
- Yoshimoto T, Houkin K, Kuroda S, Abe H, Kashiwaba T. Low cerebral blood flow and perfusion reserve induce hyperperfusion after surgical revascularization: case reports and analysis of cerebral hemodynamics. *Surg Neurol*. 1997;48:132–139.