

Heterotopic Ossification*

Dia Shehab, MD¹; Abdelhamid H. Elgazzar, MD²; and B. David Collier, MD²

¹Department of Medicine, Faculty of Medicine, Kuwait University, Safat, Kuwait; and ²Department of Nuclear Medicine, Faculty of Medicine, Kuwait University, Safat, Kuwait

Heterotopic ossification (HO) is the presence of bone in soft tissue where bone normally does not exist. The acquired form of HO most frequently is seen with either musculoskeletal trauma, spinal cord injury, or central nervous system injury. For example, patients who have recently undergone total hip arthroplasty or have paraplegia after spinal cord injury are at risk for HO. The fever, swelling, erythema, and occasional joint tenderness seen in early HO can be difficult to distinguish from cellulitis, osteomyelitis, or thrombophlebitis. Bone scanning and other imaging tests frequently are used to distinguish between these diagnostic possibilities. As treatment or prophylaxis for HO, either a nonsteroidal antiinflammatory drug (such as indomethacin), a diphosphonate (such as ethane-1-hydroxy-1,1-diphosphate), or local radiation therapy is recommended. Before therapy begins, bone scanning may be requested to confirm the diagnosis of HO. In addition, surgical resection of HO is used to preserve joint mobility; however, HO is likely to recur and possibly progress if resection is undertaken before the lesion has become mature. With a view toward avoiding recurrent HO and other operative complications, serial quantitative bone scans are used as an aid to time surgical intervention.

Key Words: heterotopic bone formation; heterotopic ossification; bone scintigraphy; spinal cord trauma; total hip arthroplasty; head injury; indomethacin; diphosphonates

J Nucl Med 2002; 43:346–353

Heterotopic ossification (HO), also known as heterotopic bone formation, is the presence of bone in soft tissue where bone normally does not exist. This condition should not be confused with metastatic calcification—such as may be seen with hypercalcemia—and dystrophic calcification, which occurs in morbid tissues such as tumor. HO was first described in 1883 by Reidel, and in 1918 Dejerne and Ceillier reported that HO frequently occurred among soldiers who had experienced spinal cord trauma as combatants in World War I (1). For clinicians treating such patients, the fever, swelling, erythema, and decreased joint

motion typically seen in early HO may closely mimic the presentation of cellulitis, osteomyelitis, or thrombophlebitis (2–5). HO can even be confused with the bone-forming tumors osteosarcoma and osteochondroma (5,6). To resolve such diagnostic uncertainty, clinicians often request bone scanning and other imaging studies for patients at risk of HO. Although the various presentations of HO have been recognized for many years—and numerous methods of diagnosis and treatment applied—complete knowledge of the etiology of HO and fully successful prevention or treatment of this condition remain elusive. With particular emphasis on the use of bone scanning for diagnosis and treatment planning, this article reviews current concepts of classification, etiology, pathophysiology, diagnosis, and treatment of HO.

CLASSIFICATION AND INCIDENCE OF HO

There are 2 versions of HO. By far the most common is the acquired form. In the acquired form, HO usually either is precipitated by trauma (such as fracture, total hip arthroplasty [THA], or direct muscular trauma) or has a neurogenic cause (such as spinal cord injury or central nervous system injury). In addition, there is the rare hereditary form known as myositis ossificans progressiva, which is briefly discussed near the end of this article.

The more common, acquired form of HO may occur after virtually any type of musculoskeletal trauma (3,7–14). For example, HO may occur after orthopedic procedures such as hip, knee, shoulder, or elbow arthroplasty; fractures; joint dislocations; or soft-tissue trauma, with the musculus quadriceps femoris and musculus brachialis often involved (11). HO includes the specific posttraumatic variant myositis ossificans, in which patients often have soft-tissue ossification at sites of trauma adjacent to long bones. Less commonly encountered sites of posttraumatic HO are abdominal incisions, wounds, the kidneys, the uterus, the corpora cavernosa, and the gastrointestinal tract (15–17). The other common traumatic form of HO occurs after injury to the nervous system (usually without direct trauma to the soft tissues, where bone formation will occur) and is therefore known as posttraumatic neurogenic HO. HO often occurs among patients with recent spinal cord injury, frequently an adolescent or young adult of either sex: HO develops only in sites distal to the level of the spinal cord injury. Closed

Received Jun. 22, 2001; revision accepted Dec. 3, 2001.

For correspondence or reprints contact: Abdelhamid H. Elgazzar, MD, Department of Nuclear Medicine, Faculty of Medicine, Kuwait University, P.O. Box 24923, 13110 Safat, Kuwait.

E-mail: aelgazzar@hsc.kuniv.edu.kw

*NOTE: FOR CE CREDIT, YOU CAN ACCESS THIS ACTIVITY THROUGH THE SNM WEB SITE (http://www.snm.org/education/ce_online.html) UNTIL MARCH 2003.

head injuries, strokes, and brain tumors also may lead to HO (7,18–22). Notable, but less often encountered in most clinical practices, are cases of HO after burns, sickle cell anemia, hemophilia, tetanus, poliomyelitis, multiple sclerosis, and toxic epidermal necrolysis (23). Finally, some cases of idiopathic HO occur without a recognized precipitating condition.

The incidence of acquired HO varies greatly from one patient population to another. Among patients with spinal cord injury, the incidence ranges from 20% to 30%, and once HO develops there is up to a 35% chance that the patient will eventually have significantly limited joint motion (24). Among patients with closed head injury, HO develops in 10%–20%, and in 10% of these patients with HO, limitations in joint motion will develop (7). The incidence of HO after THA ranges from 0.6% to 90%, although most studies agree that the incidence of HO is approximately 53% in THA (14,25,26). Often, the HO that forms after THA is minor and not clinically significant.

CLINICAL PRESENTATION AND DIFFERENTIAL DIAGNOSIS

The clinical signs and symptoms of HO may appear as early as 3 wk or as late as 12 wk after the musculoskeletal trauma, spinal cord injury, or other precipitating event (27–29). A typical case, such as is frequently encountered in many clinical practices, would be a 25-y-old paraplegic man in whom fever with swelling and erythema develops around a stiffening hip joint 8 wk after a spinal cord injury. In addition to the hip, other commonly involved sites (in decreasing order of frequency) are the knees; the shoulders; the elbows; and even, very rarely, the feet (28,30).

Loss of joint mobility and resulting loss of function are the principal complications of HO (28,31,32). For example, the hip that has HO may fuse or become ankylosed in a flexed position, a deformity that makes care of the paraplegic patient difficult. Other complications of HO include peripheral nerve entrapment and pressure ulcers (33,34). Eighty percent or more of cases of HO run a relatively benign course without any of these complications. In the remaining 10%–20% of cases, significant loss of motion develops, with ankylosis in up to 10% of these (7).

Largely because of the nonspecificity of the patient's signs and symptoms, diagnosis of HO in its initial stages is difficult. Early in the course of the disease, HO may cause pain (if sensation is intact), fever, swelling, erythema, and decreased joint mobility. In this early inflammatory phase, the condition may mimic cellulitis, thrombophlebitis, osteomyelitis, or tumor (2–4,28). Later, reduced range of motion and ankylosis of the joint may occur (32). Clinicians often turn to conventional radiography followed by 3-phase bone scanning to confirm the diagnosis of HO and establish both the extent and the metabolic activity of this ossifying lesion.

PATHOPHYSIOLOGY OF HO

HO is, by definition, the formation of bone within soft tissue. This morbid soft-tissue ossification has a pathogenesis distinct from metastatic and dystrophic soft-tissue calcification. The transformation of primitive cells of mesenchymal origin, present in the connective tissue septa within muscle, into osteogenic cells is thought to be the pathogenesis of HO (35). Chalmers et al. (36) proposed 3 conditions needed for HO: osteogenic precursor cells, inducing agents, and a permissive environment. Urist et al. (35) discovered that demineralized bone matrix could invoke bone formation ectopically and postulated a small (<0.025 μm), hydrophobic bone morphogenetic protein as a causative agent. This protein is apparently capable of changing the development of mesenchymal cells in muscle from fibrous tissue into bone when respiratory and nutritional requirements are also fulfilled (35). It has been postulated that bone morphogenetic protein is liberated from normal bone in response to venous stasis, inflammation, or diseases of connective tissue attachments to bone, conditions that often accompany immobilization or trauma (35). Some investigators proposed the presence of a centrally mediated factor (37,38). The role of prostaglandin E_2 (PGE_2) has recently been suggested as a mediator in the differentiation of the progenitor cells (39). The heterotopic bone may begin some distance from normal bone, later moving toward it (35). Interestingly, experiments have also shown that muscle injury alone will not cause the ectopic ossification, concomitant bone damage also being required (35). Kurer et al. (40) took sera from 4 paraplegic patients with HO and 4 paraplegic patients without HO; the sera were incubated with human osteoblasts in tissue culture, and their metabolic activity was measured quantitatively. These investigators found that the sera of ossifying patients had significantly greater levels of osteoblast-stimulating factors, which may contribute to the pathogenesis of HO. Other contributing factors include hypercalcemia, tissue hypoxia, changes in sympathetic nerve activity, prolonged immobilization, remobilization, and disequilibrium of parathyroid hormone and calcitonin (41,42).

Early in the course of HO, edema with exudative cellular infiltrate is present, followed by fibroblastic proliferation and osteoid formation (5). The distinctive histologic properties of myositis ossificans, which are illustrative of HO as a whole, help the pathologist distinguish myositis ossificans from malignant neoplasms such as parosteal osteosarcoma or osteochondroma. Myositis ossificans shows ossification principally in the periphery, so that an ossified and radiopaque peripheral rim surrounds a nonossified and radiolucent center; the opposite is true of osteosarcoma, a malignant tumor that often forms dense central ossification (43,44). On histologic examination, myositis ossificans shows cellular fibrous proliferation, osteoid, and primitive bone, which, if biopsied too early, may be mistaken for that of osteosarcoma (43). Mature ossified foci may even contain reticuloendothelial cells (45). The periphery of myositis

ossificans shows mature lamellar bone surrounded by a capsule of compressed muscle fibers and fibrous tissue (43).

A radiolucent cleft has been identified radiographically around myositis ossificans lesions, further distinguishing these rapidly appearing and maturing lesions both from osteosarcoma, which maintains an attachment to normal bone, and from osteochondroma, which features an open communication between itself and the medullary cavity of the host bone (35).

The development of HO is extraarticular and occurs outside the joint capsule. Bone forms in the connective tissue between the muscle planes and not within the muscle itself (5). The new bone can be contiguous with the skeleton but generally does not involve the periosteum (5,40). Mature HO shows cancellous bone and mature lamellar bone, vessels, and bone marrow with a minor amount of hematopoiesis (27,42).

LABORATORY DATA

Alkaline phosphatase has been recommended as a useful screening tool for HO (7,46). Alkaline phosphatase levels become abnormal approximately 2 wk after injury. In the typical case of HO, the alkaline phosphatase levels reached approximately 3.5 times the normal value 10 wk after the inciting trauma, before returning to normal at approximately 18 wk (46). Unfortunately, alkaline phosphatase levels cannot be used to draw clinical conclusions about maturity or recurrence of HO: Values may be normal in the presence of active HO (46,47) or may remain elevated for years, calling into question whether maturity has been reached at all (48). Nonetheless, this inexpensive and easily obtained test is frequently used to detect early HO.

Recently, measurement of the 24-h PGE₂ urinary excretion has been recommended as a valuable indicator of early HO. A sudden increase in PGE₂ excretion points to the need for bone scans to qualify the process. The PGE₂-blocking agent indomethacin is effective in slowing the HO disease process, and indomethacin is therefore useful in treating HO (49).

IMAGING STUDIES

The typical radiologic appearance of HO is circumferential ossification with a lucent center (50). However, conventional radiographs usually show the evolution of HO lesions, with a detectable calcific density present only 4–6 wk after the results of the 3-phase bone scan have become positive (46,51).

Conventional radiographs have been used to classify HO that develops after THA (31,52). By reviewing the classification of Schmidt and Hackenbroch (52) (Table 1), one can appreciate the typical patterns of HO involvement about the hip. Note, in particular, that HO often forms in the soft tissues above or below the greater trochanter of the femur. HO may progress to ankylosis with bony bridging from the femur to the pelvis.

TABLE 1

Classification of Schmidt and Hackenbroch (52) for Heterotopic Ossification

Region or grade	Description
Region I	Heterotopic ossifications strictly below tip of greater trochanter
Region II	Heterotopic ossifications below and above tip of greater trochanter
Region III	Heterotopic ossifications strictly above tip of greater trochanter
Grade A	Single or multiple heterotopic ossifications < 10 mm in maximal extent without contact with pelvis or femur
Grade B	Heterotopic ossifications > 10 mm without contact with pelvis but with possible contact with femur; no bridging from femur to proximal part of greater trochanter, with no evidence of ankylosis
Grade C	Ankylosis by means of firm bridging from femur to pelvis

Three-phase bone scintigraphy is the most sensitive imaging modality for early detection of HO (7,27,29,45–47, 53–55). Specifically, flow studies and blood-pool images will detect incipient HO approximately 2.5 wk after injury, with findings on delayed scintigrams becoming positive approximately 1 wk later. Radiography findings will not become positive in HO for at least another 1–4 wk (29,46). Activity on the delayed bone scans usually peaks a few months after injury, after which the intensity of activity on these scans progressively lessens, with a return toward normal at 6–12 mo. Most bone scan findings return to baseline within 12 mo. However, in some cases activity remains slightly elevated even though the underlying HO has become mature (48). During the course of HO, the delayed bone scan may show increased activity even after the flow study and blood-pool images have returned to normal.

Serial bone scans have been used successfully to monitor the metabolic activity of HO and determine the appropriate time for surgical resection, if needed, and to predict postoperative recurrence (8,9,27,29). A technique for serial quantitative bone scanning to assess the maturity of heterotopic ossification—based on the original 1977 report of Tanaka et al. (9)—is presented in the Appendix.

Soft-tissue ossification may be detected at a relatively earlier stage by CT than by standard radiography (56). Although often thought to be a poor choice for evaluating densely calcified bone, MRI also has been used in the evaluation of HO. One study showed that a rim of low signal intensity is the most common finding and is a typical MRI appearance of HO (57).

Tumor, infection, inflammation, and deep venous thrombosis are the major entities from which HO must be distinguished on imaging studies (Fig. 1). The rapid development, histologic makeup, and radiographic configuration of myo-

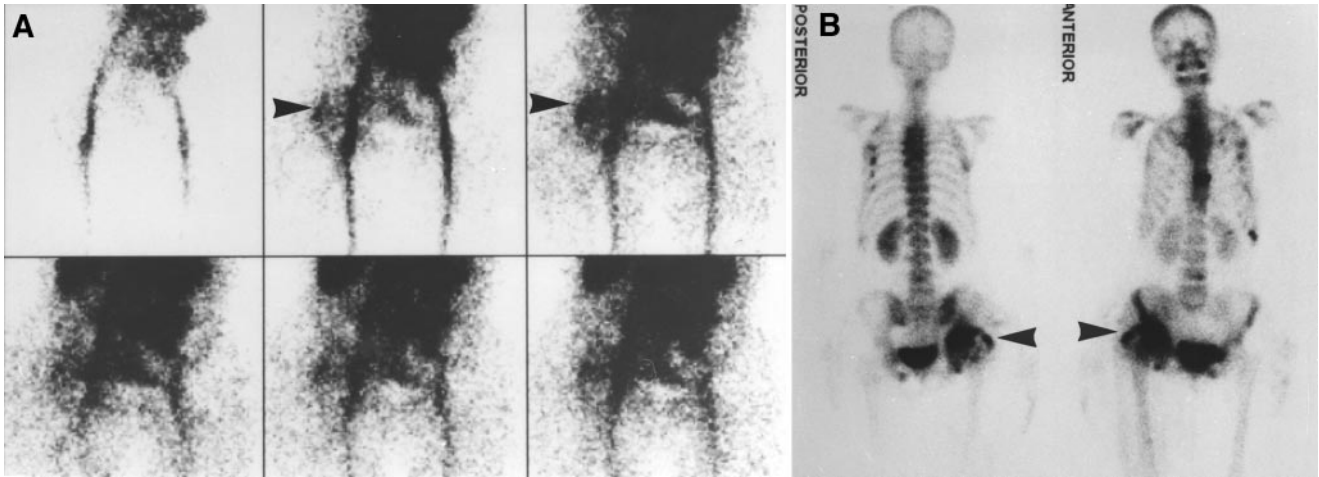


FIGURE 1. Fever, leukocytosis, and elevated alkaline phosphatase developed in 64-y-old woman 2 mo after trauma that had caused fractures of spine, rib, sternum, right knee, and right hip and pelvis. Right acetabular fracture had been repaired surgically immediately after trauma. (A) Flow study shows increased perfusion projecting over soft tissues just lateral to right hip (arrowheads). (B) Delayed bone scan shows increased uptake at same site (arrowheads) and at multiple healing fracture sites. Retrospective review of serial right hip radiographs confirmed presence of HO in soft tissue lateral to right hip joint. Patient recovered, and no other cause for fever was found.

sitis ossification distinguish it from other conditions, including osteosarcoma and osteochondroma. Cellulitis and thrombophlebitis also must often be differentiated, particularly in debilitated patients, and the possibility of external compression by HO should be kept in mind when one is investigating deep venous thrombosis (46,47,58).

Osteomyelitis may represent a more difficult diagnostic challenge, particularly because ^{67}Ga - and, rarely, ^{111}In -labeled white blood cells have been reported to accumulate in areas of immature HO (29,59,60). Thus, when imaging a paraplegic patient, one must be aware that uptake of these infection-avid agents may in fact be caused by unsuspected HO. The uptake of ^{67}Ga by foci of HO undergoing active osteogenesis may be explained by the fact that this radionuclide shares some of the properties of bone-imaging agents. Fortunately, ^{67}Ga uptake in HO is proportional to the uptake of $^{99\text{m}}\text{Tc}$ -diphosphonates, in contrast to the relatively greater ^{67}Ga uptake characteristic of osteomyelitis (59,60). ^{67}Ga uptake might otherwise be mistaken for infection or tumor (Fig. 2). ^{201}Tl also has been reported to accumulate at sites of HO early in the course of the disease, with less intense uptake of this tracer seen at later dates (61).

When interpreting 3-phase bone scans, one may increase diagnostic accuracy by noting the characteristic patterns of HO. The proximal joints typically are involved: hips and femurs, knees, shoulders, and elbows (Fig. 3) (20,28,62). More than a single joint region often is involved, and the condition often is bilateral (e.g., both hips of a paraplegic patient showing intense soft-tissue uptake because of HO). In addition, although commonly seen in patients with spinal cord injury, HO in the region of the knee is seldom present in patients with traumatic brain injury. When HO does affect the knee region, the most common site of involvement is the medial aspect of the joint (28).

TREATMENT OF HO

Complications of HO include peripheral nerve entrapment, pressure ulcers, and functional impairment if joint ankylosis develops (33,34). Therefore, prophylaxis or early treatment of HO is extremely important. Once the diagnosis of early HO is confirmed, passive range-of-motion exercises to maintain joint mobility are recommended (28,41). More aggressive joint manipulation has been suggested (20), although the trauma resulting from this approach carries the risk of inciting further HO (62).

Diphosphonates and nonsteroidal antiinflammatory drugs (such as indomethacin and ibuprofen) have been used for the prophylaxis or treatment of HO (63–68). However, there is no consensus on which drug should be used and when treatment should begin. As for the use of imaging in directing treatment, Orzel and Rudd (46) recommended starting diphosphonates as soon as elevated alkaline phosphatase is noted or imaging studies establish the presence of HO. Garland and Orwin (47), on the other hand, concluded that the efficacy of ethane-1-hydroxy-1,1-diphosphate (EHDP) in preventing or “arresting” HO was not yet established. Nonsteroidal antiinflammatory drugs have successfully been used as prophylaxis for HO among patients undergoing THA (68).

Radiation therapy has also successfully been used to prevent or treat HO (69–73). For example, Coventry and Scanlon (69) reported in 1981 the efficacy of postoperative irradiation in preventing HO after THA in 48 high-risk patients. A prospective, randomized study by Knelles et al. (72) compared 2 groups: one that received indomethacin for 7 d and another that received a single radiation exposure after THA. On the basis of these data, Knelles et al. recommended that indomethacin be used for 7 d as a prophylaxis.

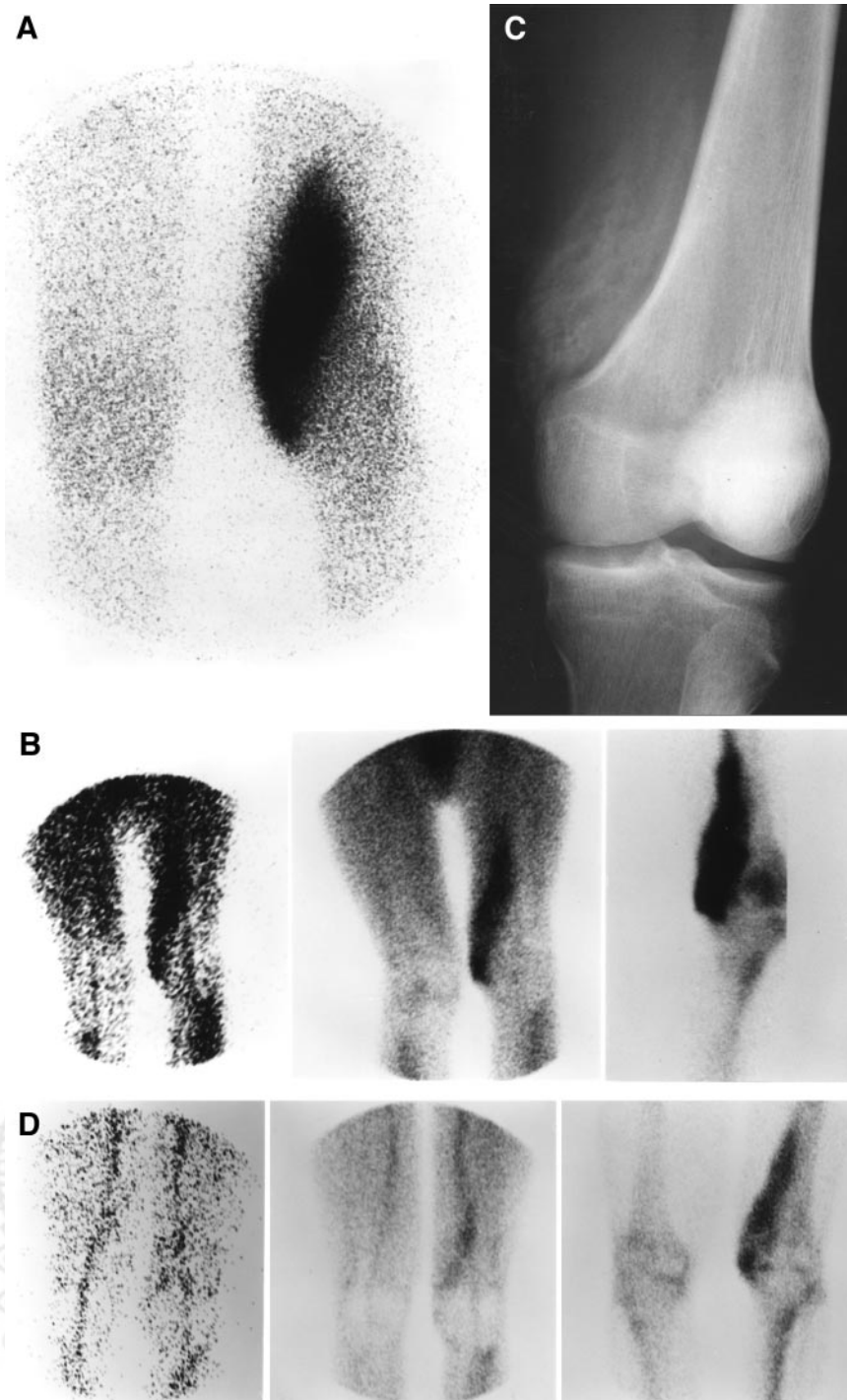


FIGURE 2. Fever (100.5°F) and left knee pain developed in 22-y-old man after closed cranial trauma, raising concern about osteomyelitis or other local infection. Initial radiography findings were normal. (A) ^{67}Ga image shows intense increased uptake in anteromedial aspect of distal left thigh. (B) From left to right, selected flow study images, blood pool images, and delayed bone scan images obtained shortly thereafter show increased flow, hyperemia, and increased uptake, respectively, also in anteromedial aspect of distal left knee. ^{67}Ga uptake is no more intense than is delayed $^{99\text{m}}\text{Tc}$ -MDP uptake, a finding favoring diagnosis of HO. (C) Subsequently obtained radiograph shows HO at this site. (D) Three-phase bone scan 18 mo after injury shows significantly less abnormal activity on (from left to right) flow study images, blood pool images, and delayed bone scan images. (Reprinted with permission of (58).)

laxis against HO for most patients undergoing THA but that a single irradiation of 7 Gy be reserved for those patients in whom HO has developed after a previous operation or who have contraindications to receiving indomethacin.

Planning for surgery performed to increase joint mobility or alter limb position also requires the use of imaging. If surgical resection is delayed until after HO has reached maturity (i.e., until HO becomes less metabolically active and has a decreased rate of bone formation), then both

intraoperative complications, such as hemorrhage, and post-operative recurrence of HO are less likely (29). One approach, which does not require bone scanning, is to delay surgery as long as is practical. In fact, Garland (7) has recommended different schedules for surgical intervention, depending on the etiology of the condition underlying the HO: 6 mo after direct traumatic musculoskeletal injury, 1 y after spinal cord injury, and 1.5 y after traumatic brain injury. However, excessive delay leaves patients at risk of

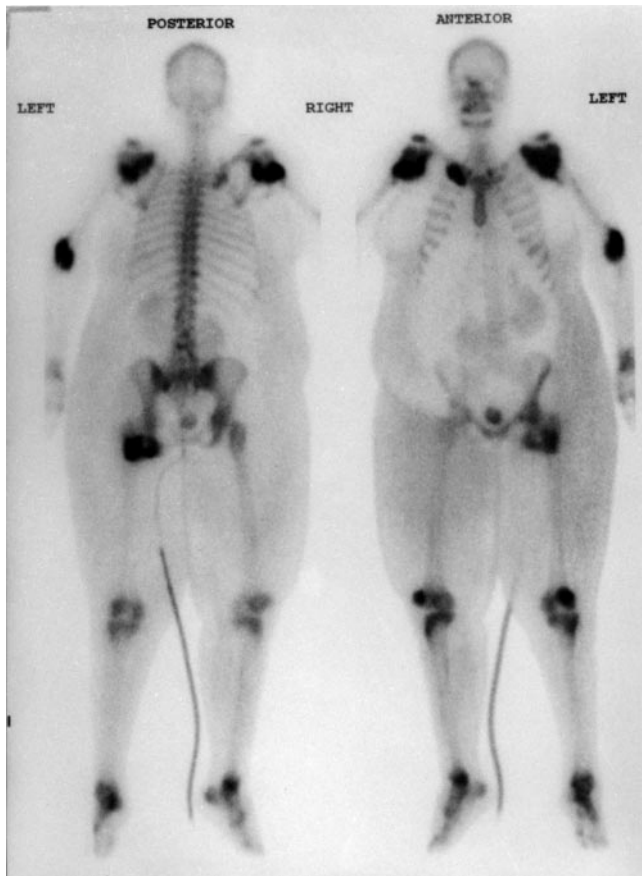

FIGURE 3. In 46-y-old quadriplegic woman, HO developed at multiple sites: both shoulders, left elbow, proximal right clavicle, and left hip. Less intense increased uptake in hands, feet, and knees is caused by arthritis.

the development of joint ankylosis or other complications of HO. Therefore, attempts have been made to stage the maturity of HO on the basis of imaging studies. Unfortunately, accurate indicators of maturity have remained difficult to obtain. Radiographic depictions of maturity, consisting of lesions with distinct margins and well-defined trabeculations, have not proved to be reliable predictors of nonrecurrence of HO after surgery (48). For several investigators (8,9,27), serial preoperative bone scans that quantify the ratio of heterotopic to normal bone activity have successfully predicted both intraoperative complications and postoperative nonrecurrence; a decreasing or stable scintigraphic activity ratio is considered the hallmark of mature HO (Appendix). As HO becomes mature, there also is a significant decrease, often reaching a normal level, in both flow study and blood-pool activity. The ideal candidate for surgical resection of HO will have no joint pain or swelling, a normal alkaline phosphatase level, and a 3-phase bone scan indicating mature HO (Table 2). As for other imaging modalities, CT has identified a low-density material in the soft tissue adjacent to areas of ectopic ossification postulated to be immature unossified connective tissue, the violation of which may be responsible for the serious intraop-

erative bleeding frequently experienced during resection of HO (29). Thus, CT may also become part of the presurgical evaluation of HO patients, indicating areas that should either be avoided or be carefully removed during surgery. In any event, given the severe complications frequently accompanying surgery, as well as the increased likelihood of poor wound healing, cellulitis, and osteomyelitis (and possible recurrence of HO) after surgery in many of these patients, it appears that surgery should be undertaken only if the expected benefits clearly outweigh the risks.

The autosomal dominant, congenital form of HO, myositis ossificans progressiva (also known in the literature as fibrodysplasia ossificans progressiva), is extremely rare (74–83). It is associated with skeletal abnormalities including malformation of the great toes and shortening of digits, as well as other clinical features such as deafness and baldness (74,75,77,79,83). Although symptoms have been reported to develop before patients with this disease are 4 y old, the diagnosis is frequently missed because of misunderstanding of the nature and cause of the soft-tissue ossification present, which has been mistaken for bruising, mumps, and sarcoma (75), and because of initial failure to appreciate the significance of the malformations of the toe and other digits (75,79). Progression to severely impaired joint mobility and ankylosis by early adulthood is the hallmark of this disease. Treatment options are limited: The trauma of surgery may actually aggravate the condition, and medical treatment with diphosphonates to inhibit the crystallization of hydroxyapatite in the bone (7) has not been found to be effective, although such treatment has been used as prophylaxis against recurrence of HO after surgical resection (75).

CONCLUSION

HO presents multiple diagnostic and therapeutic challenges. Although clinically significant HO occurs infrequently, appropriate use of laboratory and imaging data, particularly alkaline phosphatase values, PGE₂, and bone

TABLE 2
Criteria for Recommending Surgical Removal
of Heterotopic Ossification

Criterion	Description
1	Significantly limited range of motion for involved joint (e.g., hip should have <50° range of motion); for most patients, progression to joint ankylosis is most serious complication of heterotopic ossification
2	Absence of local fever, swelling, erythema, or other clinical findings of acute heterotopic ossification
3	Normal serum alkaline phosphatase
4	Return of bone scan findings to normal or near normal; if serial quantitative bone scans are obtained, there should be a sharply decreasing trend followed by steady state for 2–3 mo.

scintigraphy, permits early detection and more successful management of this fascinating yet troublesome ailment. For many patients at risk for HO, either a nonsteroidal antiinflammatory drug (such as indomethacin or EHDP) or local radiation therapy is recommended. Clinicians may request bone scanning to confirm the diagnosis of HO, to determine whether medical treatment is warranted, and to choose the appropriate time for surgical resection of HO.

APPENDIX

Technique for Serial Quantitative Bone Scans to Assess Maturity of HO

The following technique is based on the report of Tanaka et al. (9).

Imaging

- Radiopharmaceutical: 740 MBq (20 mCi) ^{99m}Tc-methylene diphosphonate.
- Imaging time: 3 h after intravenous injection.
- Patient positioning: anterior supine view of hips or other involved regions. Consistent positioning on serial studies is important.
- Data acquisition: 500,000-count images. Use a 256 × 256 matrix for a gamma camera with a 400-mm field of view. For other systems, use a matrix size that will provide approximately 2-mm-wide pixels.

Data Analysis

Using 2 × 2 pixel (approximately 4 × 4 mm) square regions of interest, search over the site of HO for the area of highest activity. When analyzing serial quantitative bone scans, present results as a percentage relative to the most abnormal result in the series. For example, such a serial quantitative data analysis might show uptake ratios for the most active site of HO as follows: 100% at 2 mo, 80% at 3 mo, 83% at 4 mo, 75% at 5 mo, 60% at 6 mo, 35% at 10 mo, and 30% at 12 mo. Instead of using absolute uptake in the form of counts, one may use serial determinations of abnormal uptake relative to a normal skeletal structure (such as the opposite hip).

Recommendations

If the technique is to be used to time surgical resection, obtain a baseline quantitative bone scan as soon as possible after the onset of clinical symptoms of HO. Obtain serial scans at between 1- and 6-mo intervals. More frequent serial scans improve the accuracy of the technique.

Quantitative results depend on consistent technique, particularly with respect to radiopharmaceutical dose, collimation and other imaging parameters, and both patient and gamma camera positioning. Changes in renal function also alter results.

Serial quantitative bone scans that show a sharply decreasing trend followed by a steady state over a 2- to 3-mo period are the most reliable scintigraphic parameter for determining whether HO has reached maturity.

REFERENCES

1. Dejerne A, Ceillier A. Para-osteo-arthropathies des paraplegiques par lesion medullaire; etude clinique et radiographique. *Ann Med*. 1918;5:497.
2. Ragone DJ, Kellerman WC, Bonner FJ. Heterotopic ossification masquerading as deep venous thrombosis in head-injured adult: complications of anticoagulation. *Arch Phys Med Rehabil*. 1986;67:339-341.
3. Venier LH, Ditunno JF. Heterotopic ossification in the paraplegic patient. *Arch Phys Med Rehabil*. 1971;52:475-479.
4. Goldberg MA, Schumacher HR. Heterotopic ossification mimicking acute arthritis after neurologic catastrophes. *Arch Intern Med*. 1977;137:619-621.
5. Jensen LL, Halar E, Little J, Brooke MM. Neurogenic heterotopic ossification. *Am J Phys Med Rehabil*. 1987;66:351-363.
6. Nuovo MA, Norman A, Chumas J, Ackerman LV. Myositis ossificans with atypical clinical, radiographic or pathologic findings. *Skeletal Radiol*. 1992;21:87-101.
7. Garland DE. A clinical perspective on common forms of acquired heterotopic ossification. *Clin Orthop*. 1991;263:13-29.
8. Muheim G, Donath A, Rossier AB. Serial scintigrams in the course of ectopic bone formation in paraplegic patients. *AJR*. 1973;118:865-869.
9. Tanaka T, Rossier AB, Hussey RW, Ahnberg DS, Treves S. Quantitative assessment of para-osteo-arthropathy and its maturation on serial radionuclide bone images. *Radiology*. 1977;123:217-221.
10. Hait G, Boswick JA, Stone NH. Heterotopic bone formation secondary to trauma (myositis ossificans traumatica). *J Trauma*. 1970;10:405-411.
11. Singer BR. Heterotopic ossification. *Br J Hosp Med*. 1993;49:247-255.
12. Rosendahl S, Christoffersen JK, Norgaard M. Para-articular ossification following hip replacement. *Acta Orthop Scand*. 1977;48:400-404.
13. Freeman PA, Lee P, Bryson TW. Total hip joint replacement in osteoarthritis and polyarthritis. *Clin Orthop*. 1973;95:224-230.
14. Thomas BJ. Heterotopic bone formation after total hip arthroplasty. *Orthop Clin North Am*. 1992;23:347-358.
15. Jacobs JE, Birnbaum BA, Siegelman ES. Heterotopic ossification of midline abdominal incisions: CT and MR imaging findings. *AJR*. 1996;166:579-84.
16. Reardon MJ, Tillou A, Mody DR, Reardon PR. Heterotopic calcification in abdominal wounds. *Am J Surg*. 1997;173:145-147.
17. Haque S, Eisen RN, West AB. Heterotopic formation in gastrointestinal tract. *Arch Pathol Lab Med*. 1996;120:666-670.
18. Domanski M. Heterotopic ossification in paraplegia: a clinical study. *J Bone Joint Surg*. 1961;43:125-127.
19. Money RA. Ectopic paraarticular ossification after head injury. *Med J Aust*. 1972;1:125-127.
20. Garland DE, Blum CE, Waters RL. Periarticular heterotopic ossification in head-injured adults: incidence and location. *J Bone Joint Surg Am*. 1980;62:1143-1146.
21. Roberts JB, Pankratz DG. The surgical treatment of heterotopic ossification at the elbow following long-term coma. *J Bone Joint Surg Am*. 1979;61:760-763.
22. Roberts PH. Heterotopic ossification complicating paralysis of intracranial origin. *J Bone Joint Surg Br*. 1968;50:70-77.
23. Gibson CJ, Poduri KR. Heterotopic ossification as a complication of toxic epidermal necrolysis. *Arch Phys Med Rehabil*. 1997;78:774-776.
24. Stover SL, Niemann KM, Tulloss JR. Experience with surgical resection of heterotopic bone in spinal cord injury patients. *Clin Orthop*. 1991;263:71-77.
25. Naraghi FF, DeCoster TA, Moneim MS, Miller RA, Rivero D. Heterotopic ossification. *Orthopedics*. 1996;19:145-151.
26. Thomas BJ, Amstutz HC. Prevention of heterotopic bone formation: clinical experience with diphosphonates. *Hip*. 1987;59-69.
27. Rossier AB, Bussat P, Infante F, et al. Current facts on para-osteoarthropathy (POA). *Paraplegia*. 1973;11:36-78.
28. Wharton GW, Morgan TH. Ankylosis in the paralyzed patient. *J Bone Joint Surg Am*. 1970;52:105-112.
29. Freed JH, Hahn H, Menter R, Dillon T. The use of three-phase bone scan in the early diagnosis of heterotopic ossification (HO) and in the evaluation of Didronel therapy. *Paraplegia*. 1982;20:208-216.
30. Allard MM, Thomas RL, Nicholas RW Jr. Myositis ossificans: an unusual presentation in the foot. *Foot Ankle Int*. 1997;18:39-42.
31. Brooker AF, Bowerman JW, Robinson RA, Riley LH Jr. Ectopic ossification following total hip replacement: incidence and method of classification. *J Bone Joint Surg Am*. 1973;55:1629-1632.
32. Sawyer JR, Myers MA, Rosier RN, Puzas JE. Heterotopic ossification: clinical and cellular aspects. *Calcif Tissue Int*. 1991;49:208-215.
33. Brooke MM, Heard DL, de Lateur BJ, et al. Heterotopic ossification and peripheral nerve entrapment: early diagnosis and excision. *Arch Phys Med Rehabil*. 1991;72:425-429.

34. Hassard GH. Heterotopic bone formation about the hip and unilateral decubitus ulcers in spinal cord injury. *Arch Phys Med Rehabil.* 1975;56:355–358.
35. Urist MR, Nakagawa M, Nakata N, Nogami H. Experimental myositis ossificans: cartilage and bone formation in muscle in response to diffusible bone matrix-derived morphogen. *Arch Pathol Lab Med.* 1978;102:312–316.
36. Chalmers J, Gray DH, Rush J. Observations on the induction of bone in soft tissues. *J Bone Joint Surg Br.* 1975;57:36–45.
37. Craven PL, Urist MR. Osteogenesis by radioisotope labelled cell population in implants of bone matrix under the influence of ionizing radiation. *Clin Orthop.* 1971;76:231–233.
38. Puzas JE, Brand JS, Howard GA, Lio CC, Everts CM. Heterotopic bone formation after operation: a quantitative, histologic and biochemical study. *Surg Forum.* 1984;35:521–523.
39. Ho SSW, Stern PJ, Bruno LP, et al. Pharmacological inhibition of prostaglandin E-2 in bone and its effect on pathological new bone formation in a rat brain model. *Trans Orthop Res Soc.* 1988;13:536.
40. Kurer MH, Khoker MA, Dandona P. Human osteoblast stimulation by sera from paraplegic patients with heterotopic ossification. *Paraplegia.* 1992;30:165–168.
41. Stover SL, Hataway CJ, Zeiger HE. Heterotopic ossification in spinal cord-injured patients. *Arch Phys Med Rehabil.* 1975;56:199–204.
42. Chantraine A, Minaire P. Para-osteo-arthropathies: a new theory and mode of treatment. *Scand J Rehabil Med.* 1981;13:31–37.
43. Resnick D, Niwayama G. Soft tissues. In: Resnick D, Niwayama G, eds. *Diagnosis of Bone and Joint Disorders.* 2nd ed. Philadelphia, PA: W.B. Saunders; 1988:4171–4294.
44. Norman A, Dorfman HD. Juxtacortical circumscribed myositis ossifications: evolution and radiographic features. *Radiology.* 1970;96:301–306.
45. Tyler JL, Derbekyan V, Lisbona R. Early diagnosis of myositis ossificans with Tc-99m diphosphonate imaging. *Clin Nucl Med.* 1984;9:256–258.
46. Orzel JA, Rudd TG. Heterotopic bone formation: clinical, laboratory and imaging correlation. *J Nucl Med.* 1985;26:125–132.
47. Garland DE, Orwin JF. Resection of heterotopic ossification in patients with spinal cord injuries. *Clin Orthop.* 1989;242:169–176.
48. Tibone J, Sakimura I, Nickel VL, Hsu JD. Heterotopic ossification around the hip in spinal cord-injured patients: a long-term follow-up study. *J Bone Joint Surg Am.* 1978;60:769–775.
49. Schurch B, Capaul M, Vallotton MB, Rossier AB. Prostaglandin E₂ measurements: their value in the early diagnosis of heterotopic ossification in spinal cord injury patients. *Arch Phys Med Rehabil.* 1997;78:687–691.
50. Helms CA. “Skeletal don’t touch” lesions. In: Brant WE, Helms CA; eds. *Fundamentals of Diagnostic Radiology.* Baltimore, MD: Williams & Wilkins; 1994:963–975.
51. Mysiw WJ, Tan J, Jackson RD. Heterotopic ossification. *Am J Phys Med Rehabil.* 1993;72:184–187.
52. Schmidt J, Hackenbroch MH. A new classification for heterotopic ossification in total hip arthroplasty considering the surgical approach. *Arch Orthop Trauma Surg.* 1996;115:339–343.
53. Drane WE. Myositis ossificans and the three phase bone scan. *AJR.* 1984;142:179–180.
54. Szabo Z, Ritzl F, Chittima S, Laszlo GA, Neumann C. Bone scintigraphy of myositis ossificans in apallic syndrome. *Eur J Nucl Med.* 1982;7:426–428.
55. Suzuki Y, Hisada K, Takeda M. Demonstration of myositis ossificans by ^{99m}Tc pyrophosphate bone scanning. *Radiology.* 1974;111:663–664.
56. Bressler EL, Marn CS, Gore RM, Hendrix RW. Evaluation of ectopic bone by CT. *AJR.* 1987;148:931–935.
57. De Smet AA, Norris MA, Fisher DR. Magnetic resonance imaging of myositis ossificans: analysis of seven cases. *Skeletal Radiol.* 1992;21:503–507.
58. Nagaraj N, Elgazzar AH, Fernandez-Ulloa M. Heterotopic ossification mimicking infection: scintigraphic evaluation. *Clin Nucl Med.* 1995;20:763–766.
59. Cardaci G, Surveyer I. 67-Ga uptake at sites of heterotopic ossification: a report of three cases. *Nucl Med Commun.* 1992;13:440–444.
60. Vento JA, Sziklas JJ, Spencer RP, Rosenberg RJ. “Reactivation” of Tc-99m MDP uptake in heterotopic bone. *Clin Nucl Med.* 1985;10:206–207.
61. Gungor F, Yazici M, Egehan I, et al. Thallium-201 uptake in myositis ossificans: potential pitfall in diagnosis. *Clin Nucl Med.* 1995;20:259–262.
62. Garland DE, Razza BE, Waters RL. Forceful joint manipulation in head-injured adults with heterotopic ossification. *Clin Orthop.* 1982;169:133–138.
63. Thomas BJ, Amstutz HC. Results of the administration of diphosphonate for the prevention of heterotopic ossification after total hip arthroplasty. *J Bone Joint Surg Am.* 1985;67:400–403.
64. Cella JP, Salvati EA, Sculco TP. Indomethacin for the prevention of heterotopic ossification following total hip arthroplasty: effectiveness, contraindications and adverse effects. *J Arthroplasty.* 1988;3:229–234.
65. Elmsted E, Lindholm TS, Nilsson OS, Tornkvist H. Effect of ibuprofen on heterotopic ossification after hip replacement. *Acta Orthop Scand.* 1985;56:25–27.
66. Freiberg AA, Cantor R, Freiberg RA. The use of aspirin to prevent heterotopic ossification after total hip arthroplasty. *Clin Orthop.* 1991;267:93–96.
67. Kjaersgaard-Andersen P, Ritter MA. Short-term treatment with nonsteroidal antiinflammatory medication to prevent heterotopic bone formation after total hip arthroplasty. *Clin Orthop.* 1992;279:157–162.
68. Neal BC, Rodgers A, Clark T, et al. A systematic survey of 13 randomized trials of non-steroidal anti-inflammatory drugs for the prevention of heterotopic bone formation after major hip surgery. *Acta Orthop Scand.* 2000;71:122–128.
69. Coventry MB, Scanlon PW. The use of radiation to discourage ectopic bone: a nine-year study in surgery about the hip. *J Bone Joint Surg Am.* 1981;63:201–208.
70. Healy WL, Lot TC, DeSimone AA, Rask B, Pfeifer BA. Single-dose irradiation for the prevention of heterotopic ossification after total hip arthroplasty. *J Bone Joint Surg Am.* 1995;77:590–595.
71. Pellegrini VD Jr, Gregoritch SJ. Preoperative irradiation for prevention of heterotopic ossification following total hip arthroplasty. *J Bone Joint Surg Am.* 1996;78:870–881.
72. Knelles D, Barthel T, Karer A, et al. Prevention of heterotopic ossification after total hip replacement: a prospective, randomized study using acetyl salicylic acid, indomethacin and fractional or single dose irradiation. *J Bone Joint Surg Br.* 1997;79:596–602.
73. McAuliffe JA, Wolfson AH. Early excision of heterotopic ossification about the elbow followed by radiation therapy. *J Bone Joint Surg Am.* 1997;79:749–755.
74. Illingworth RS. Myositis ossificans progressiva (Munchmeyer’s disease): brief review with report of two cases treated with corticosteroids and observed for 16 years. *Arch Dis Child.* 1971;46:264–268.
75. Smith R, Russell RG, Woods CG. Myositis ossificans progressiva: clinical features of eight patients and their response to treatment. *J Bone Joint Surg Br.* 1976;58:48–57.
76. Sastri VR, Yadav SS. Myositis ossificans progressiva. *Int Surg.* 1977;62:45–47.
77. Rogers JG, Geho WB. Fibrodysplasia ossificans progressiva: a survey of forty-two cases. *Bone Joint Surg Am.* 1979;61:909–914.
78. Mukherjee PK, Basu B. Myositis ossificans progressiva. *Indian Pediatr.* 1981;18:349–352.
79. Connor JM, Evan DA. Fibrodysplasia ossificans progressiva: the clinical features and natural history of 34 patients. *J Bone Joint Surg Br.* 1982;64:76–83.
80. Cremin B, Connor JM, Beighton P. The radiological spectrum of fibrodysplasia ossificans progressiva. *Clin Radiol.* 1982;33:499–508.
81. Agarwal RP, Verma SK, Garg RK, et al. Myositis ossificans progressiva. *Indian Pediatr.* 1991;28:931–934.
82. Ludman J, Hamilton EB, Eade AW. Deafness in myositis ossificans progressiva. *J Laryngol Otol.* 1968;82:57–63.
83. Elgazzar AH, Kriss VM, Gelfand MJ. Advanced fibrodysplasia ossificans progressiva. *Clin Nucl Med.* 1995;20:519–521.