

---

# Usefulness of Brain SPECT to Evaluate Brain Tolerance and Hemodynamic Changes During Temporary Balloon Occlusion Test and After Permanent Carotid Occlusion

Yoshifumi Sugawara, MD<sup>1</sup>; Takanori Kikuchi, MD<sup>1</sup>; Toshihiro Ueda, MD<sup>2</sup>; Mamoru Nishizaki, MD<sup>2</sup>; Shigeru Nakata, CNMT<sup>1</sup>; Teruhito Mochizuki, MD<sup>1</sup>; and Junpei Ikezoe, MD<sup>1</sup>

<sup>1</sup>Department of Radiology, Ehime University School of Medicine, Ehime, Japan; and <sup>2</sup>Department of Neurological Surgery, Ehime University School of Medicine, Ehime, Japan

---

The purpose of this study was to evaluate the usefulness of SPECT during temporary carotid balloon occlusion testing and to evaluate the changes in regional cerebral blood flow (CBF) and regional cerebral perfusion reserve (CPR) after permanent carotid occlusion. **Methods:** Temporary balloon occlusion testing was performed on 40 patients (24 head and neck tumors, 16 aneurysms). During the balloon occlusion (total time, 30 min), <sup>99m</sup>Tc-ethylcysteinate dimer (ECD) was injected intravenously about 5 min before balloon deflation, followed by SPECT data acquisition. SPECT images were visually evaluated, and the severity of hypoperfusion on the occluded side was classified using 4 grades (normal, mild, moderate, and severe). The count ratio of the occluded side to the contralateral side (L/N ratio) was also analyzed. In 7 patients who subsequently underwent permanent carotid occlusion, CBF and CPR were quantitatively assessed using <sup>133</sup>Xe inhalation dynamic SPECT at rest and after acetazolamide (ACZ) enhancement (CPR was defined as the percentage increase in CBF after ACZ), and the patients were followed up periodically. **Results:** SPECT after temporary occlusion showed moderate or severe hypoperfusion in 12 patients, whereas neurologic deterioration was observed in only 4 patients. The L/N ratios were  $0.96 \pm 0.03$  in normal perfusion (13 patients),  $0.93 \pm 0.03$  in mild hypoperfusion (15 patients),  $0.83 \pm 0.03$  in moderate hypoperfusion (10 patients) and  $0.66 \pm 0.09$  in severe hypoperfusion (2 patients) ( $P < 0.0001$ ). In the 7 patients who underwent permanent carotid occlusion, CPR decreased after surgery ( $35\% \pm 7\%$  vs.  $7\% \pm 14\%$ ,  $P < 0.05$ ), even though the resting CBF did not change ( $54 \pm 8$  mL/100 g/min vs.  $52 \pm 6$  mL/100 g/min, not statistically significant). The steal phenomenon (rCPR < 0%) was observed in 3 patients, 1 of whom experienced transient hemiparesis when blood pressure dropped soon after surgery. On follow-up, the decreased CPR gradually improved and no infarction developed. **Conclusion:** SPECT is useful to detect cerebral hypoperfusion during carotid occlusion. Assessment of CPR is recommended to pre-

dict the potential risk of postsurgical complications and to follow up patients after permanent carotid occlusion.

**Key Words:** balloon occlusion; cerebral blood flow; cerebral perfusion reserve; SPECT; acetazolamide

**J Nucl Med 2002; 43:1616–1623**

---

**I**t may be necessary to sacrifice a carotid artery in the treatment of patients with head and neck tumors or cerebral aneurysms. It is thus essential to evaluate whether the patient can tolerate temporary or permanent carotid occlusion and to predict the potential risk before the surgical procedures. Balloon occlusion testing (BOT) is useful for evaluating whether patients will tolerate temporary or permanent carotid occlusion and has been considered to result in a decrease in postsurgical complications after carotid occlusion (1–3).

Measurement of cerebral blood flow (CBF) has revealed that substantial cerebral hypoperfusion may occur when a patient does not show any neurologic symptoms during BOT and may thus predict the potential risk after carotid occlusion (4–6). Among several methods of CBF studies, SPECT using <sup>99m</sup>Tc-hexamethylpropyleneamine oxime (HMPAO) or <sup>99m</sup>Tc-ethylcysteinate dimer (ECD) has been increasingly applied in conjunction with BOT, because both tracers—<sup>99m</sup>Tc-HMPAO and <sup>99m</sup>Tc-ECD—rapidly distribute in the brain and the image is constant long after injection (7). SPECT images acquired after the completion of BOT might still reflect the CBF distribution during BOT when the tracer was injected.

However, reports have indicated that ischemic events or infarction can occur after permanent carotid occlusion in some patients considered to be tolerant of carotid occlusion by BOT with SPECT (3,4,8,9). Although the cause of these ischemic events seems to be either embolic or hemodynamic, how hemodynamic change may occur after permanent carotid occlusion has not been sufficiently clarified.

---

Received Mar. 15, 2002; revision accepted Jul. 26, 2002.  
For correspondence or reprints contact: Yoshifumi Sugawara, MD, Department of Radiology, Ehime University School of Medicine, Shitsukawa, Shigenobu-cho, Onsen-gun, Ehime 791-0295, Japan.  
E-mail: sugawara@m.ehime-u.ac.jp

In this study, we retrospectively evaluated the results of 40 consecutive initial patients who underwent BOT. The purpose of this study was to evaluate the usefulness of brain SPECT during BOT and to quantitatively evaluate the changes in regional CBF and cerebral perfusion reserve (CPR) in patients who were tolerant of BOT and subsequently underwent permanent carotid occlusion.

## MATERIALS AND METHODS

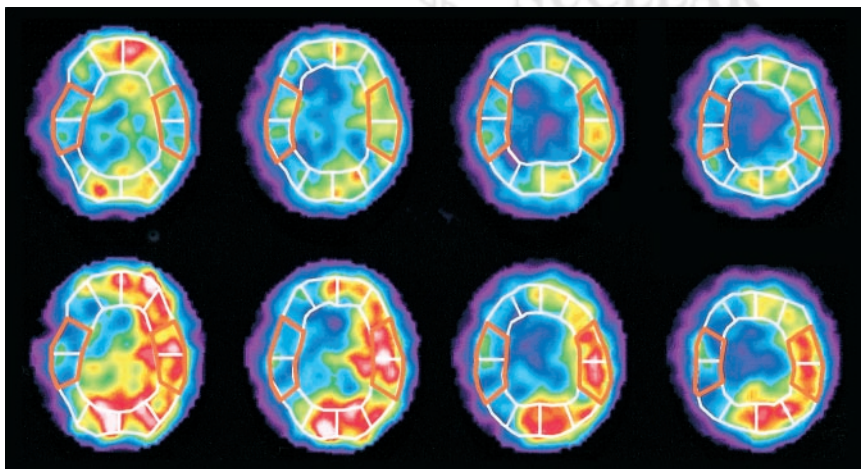
Forty patients, 38 men and 2 women, with head and neck tumors (24 patients) or cerebral aneurysms (16 patients) underwent BOT of the internal carotid artery (ICA) to evaluate brain tolerance to ICA sacrifice. Patient age ranged from 21 to 75 y, with a mean of 56 y. Written informed consent was obtained from all patients or their relatives after a detailed explanation of the test procedures.

BOT proceeded as follows: Before the start of BOT, we performed conventional angiography on 3 or 4 vessels (bilateral internal or common carotid arteries and unilateral or bilateral vertebral arteries) and evaluated the collateral circulation from the circle of Willis. Afterward, a 5-French balloon catheter was placed into the ICA and inflated until contrast medium no longer flowed through the site of balloon occlusion. The patient's neurologic status was continuously evaluated, and when any neurologic symptom was observed the balloon was immediately deflated. If no neurologic symptom was observed, balloon occlusion was continued for a total of 30 min. Approximately 740 MBq (20 mCi) of  $^{99m}\text{Tc}$ -ECD were injected intravenously 5 min before balloon deflation. In other words, the delay between the start of balloon inflation and  $^{99m}\text{Tc}$ -ECD injection was usually 25 min, except for patients with positive symptoms during BOT ( $^{99m}\text{Tc}$ -ECD was injected as soon as possible when patients showed a neurologic symptom). SPECT data were acquired for usually about 30 min after the test was completed.

SPECT with  $^{99m}\text{Tc}$ -ECD was performed using a 4-head gamma camera (SPECT 2000H-40; Hitachi, Tokyo, Japan) equipped with low-energy high-resolution collimators. Data were acquired at 20 s per view, using 64 views and a  $64 \times 64$  matrix, and were reconstructed using Butterworth filtered backprojection with a slice thickness of 4 mm. Attenuation correction was performed by the method of Chang (10). The  $^{99m}\text{Tc}$ -ECD SPECT images during BOT were visually evaluated by 2 experienced nuclear physicians, and the degree of cerebral perfusion in the occluded hemisphere

was classified by consensus reading into 1 of 4 grades: normal (symmetric) perfusion, mild hypoperfusion, moderate hypoperfusion, and severe hypoperfusion. The radioactivity count ratio (L/N ratio) of the lesion (occluded) side to the contralateral normal side was calculated, and the value was compared with the visual classification. Although there are no strict criteria to define the degree of perfusion abnormalities, it is generally accepted that the areas of diminished perfusion are abnormal when the activity is less than 90% of normal (11). In this study, all the areas evaluated as moderate or severe hypoperfusion showed L/N ratios of less than 0.9. We therefore considered patients as being brain tolerant when they had no neurologic symptoms and the L/N ratio was greater than 0.9.

In 7 patients who were tolerant of BOT and subsequently underwent permanent carotid occlusion, quantitative measurements of CBF (in mL/100 g/min) using  $^{133}\text{Xe}$  inhalation methods were performed at rest and after enhancement with 1 g of acetazolamide (ACZ) (Diamox; Japan Wyeth Lederle Ltd., Tokyo, Japan). The CBF measurements were performed before and after permanent carotid occlusion and were repeated periodically during follow-up. Details of the methods of CBF measurement were described in 2 of our previous reports (12,13). In brief, patients inhaled 1.85 GBq of  $^{133}\text{Xe}$  gas and CBF was measured by dynamic SPECT (16 scans with a duration of 20 s each) according to the method of Kanno and Lassen (14). The CBF measurement was performed at rest and 15 min after intravenous injection of 1 g of ACZ. Both on the images at rest and on the images after ACZ, we placed a total of 12 regions of interest on the cerebral cortex approximately corresponding to the territories of the anterior cerebral artery, the middle cerebral artery (MCA), the posterior cerebral artery, and their border zones. In this study, we calculated the mean CBF in the MCA territories on the 4 topographic planes of the basal ganglia through the centrum semiovale (Fig. 1). The CPR was defined as the percentage increase in CBF after ACZ challenging. In our institute, the mean values of CBF and CPR in the MCA territories were  $50.9 \pm 3.9$  mL/100 g/min and  $40.8\% \pm 12.7\%$ , which were obtained from 7 patients with nonruptured aneurysms (mean age,  $59 \pm 8$  y) who had no neurologic deficit and no infarction on CT or MRI (12). According to these normal values, we defined the lower limits of the normal range (mean - 2 SDs) of CBF and CPR as 43 mL/100 g/min and 15%, respectively. The values of CBF and CPR were compared before and after permanent carotid occlusion by means of the Wilcoxon



**FIGURE 1.**  $^{133}\text{Xe}$  CBF images at rest (top row) and after ACZ enhancement (bottom row) with placement of regions of interest. Mean CBF is calculated in MCA territories on 4 slices from basal ganglia through centrum semiovale. CPR is defined as percentage increase in CBF after ACZ enhancement, or  $\text{CPR} = \frac{[\text{CBF [ACZ]} - \text{CBF [rest]}]}{\text{CBF [rest]}} \times 100 (\%)$ .

**TABLE 1**  
Symptoms and SPECT Findings During Balloon Occlusion Test

Symptoms (BOT)	Hypoperfusion findings on <sup>99m</sup> Tc-ECD SPECT				Total
	Normal	Mild	Moderate	Severe	
Absent	11	15	9	1	36
Present	2*	0	1	1	4
Total	13	15	10	2	40

\*<sup>99m</sup>Tc-ECD was injected after balloon deflation.

signed rank test, and *P* values less than 0.05 were considered significant.

## RESULTS

On angiography, cross-flow from the anterior communicating artery was good in 33 patients. In the other 7 patients, cross-flow from the anterior communicating artery was not good, but flow from the posterior communicating artery was good. Only 1 of these 7 patients showed transient symptoms (dysarthria and blindness), but the symptoms promptly disappeared.

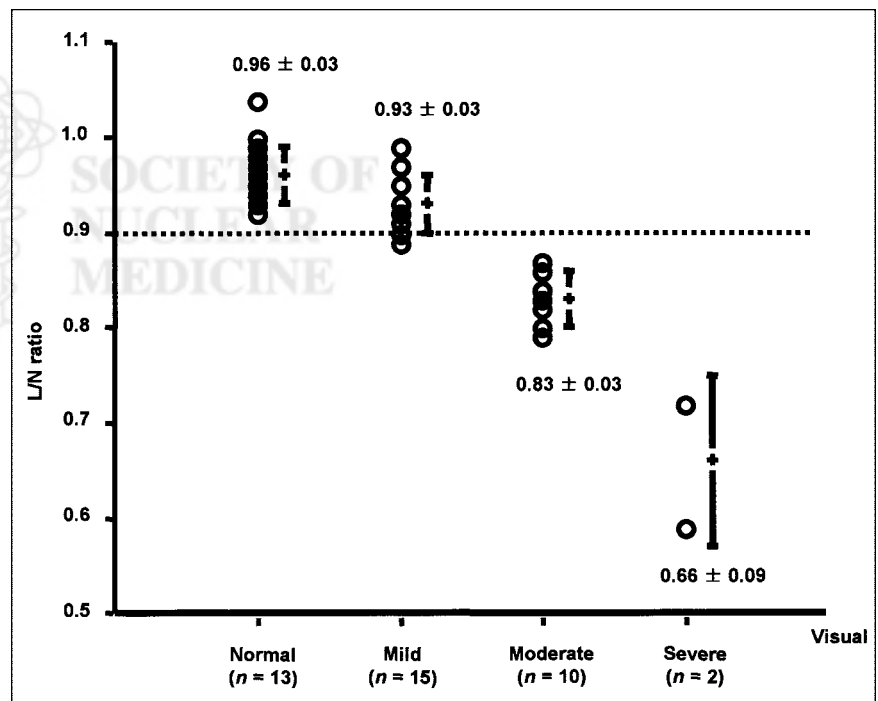
During BOT, neurologic symptoms were observed in only 4 patients, whereas <sup>99m</sup>Tc-ECD SPECT showed moderate or severe hypoperfusion in 10 of 36 patients (28%) who showed no neurologic symptoms during BOT (Table 1). Among the 14 patients with abnormal BOT results (symptom positive in 4 patients, symptom negative but SPECT positive in 10 patients), 9 patients had head and

neck tumors (pharynx, 4; maxillary sinus, 1; ethmoid sinus, 1; brain, 1; neck tumor with unknown origin, 2). The other 5 patients had ICA aneurysms in the carotid siphon, including 1 with an aneurysm of the ICA and ophthalmic artery. The L/N ratios were  $0.96 \pm 0.03$  in normal perfusion (13 patients),  $0.93 \pm 0.03$  in mild hypoperfusion (15 patients),  $0.83 \pm 0.03$  in moderate hypoperfusion (10 patients), and  $0.66 \pm 0.09$  in severe hypoperfusion (2 patients) (*P* < 0.0001; Fig. 2).

Baseline <sup>99m</sup>Tc-ECD SPECT was performed on only 6 patients. Of these 6 patients, only 1 patient with brain tumor showed slightly decreased cerebral perfusion (L/N ratio of 0.9) on the tumor side. Baseline SPECT in the other 5 patients showed normal symmetric perfusion.

If feasible during surgery, preservation of the carotid artery was a priority. Of 21 patients with negative BOT who did not undergo permanent carotid occlusion, 17 patients were successfully treated without carotid sacrifice. Planned surgery was finally refused by the patients and their relatives in 2 instances, and the reconstruction surgeries were performed on 2 patients despite their testing negative. Finally, 7 patients who were tolerant of BOT subsequently underwent permanent carotid occlusion. Clinical information on these 7 patients is summarized in Table 2. In one patient (patient 4), a transient hemiparesis occurred soon after permanent occlusion of the right ICA when blood pressure dropped (Fig. 3). In another patient (patient 5), a small infarction that was probably due to a small thromboembolism was incidentally detected on follow-up MRI. No permanent neurologic deficit was observed in any patient.

The values for CBF and CPR before and after permanent carotid occlusion are shown in Figure 4. The resting CBF



**FIGURE 2.** Comparisons of visual analysis and L/N ratio. Visual interpretation agrees well with L/N ratio. All cases of moderate or severe hypoperfusion show L/N ratios less than 0.9.



**TABLE 2**  
Patients with Permanent Carotid Occlusion

Patient no.	Age	Sex	Disease	Site of occlusion	Treatment	CBF (mL/100 g/min)		CPR (%)		Symptoms (BOT)	Infarction (CT/MRI)
						Before	After	Before	After		
1	64	F	Aneurysm	R ICA	Ligation	54	49	33	-2	Absent	Absent
2	59	F	Aneurysm	R ICA	Balloon occlusion	44	43	36	14	Absent	NA
3	49	F	Aneurysm	R ICA	Balloon occlusion	56	60	39	27	Absent	Absent
4	63	F	Aneurysm	R ICA	Coil embolization	67	56	34	-13	Present*	Absent
5	70	F	Aneurysm	R ICA	Balloon occlusion	44	53	23	-2	Absent	Present†
6	66	M	Aneurysm	R ICA	Balloon occlusion	54	49	48	18	Absent	Absent
7	36	F	Aneurysm	L ICA	Trapping	58	55	34	4	Absent	Absent

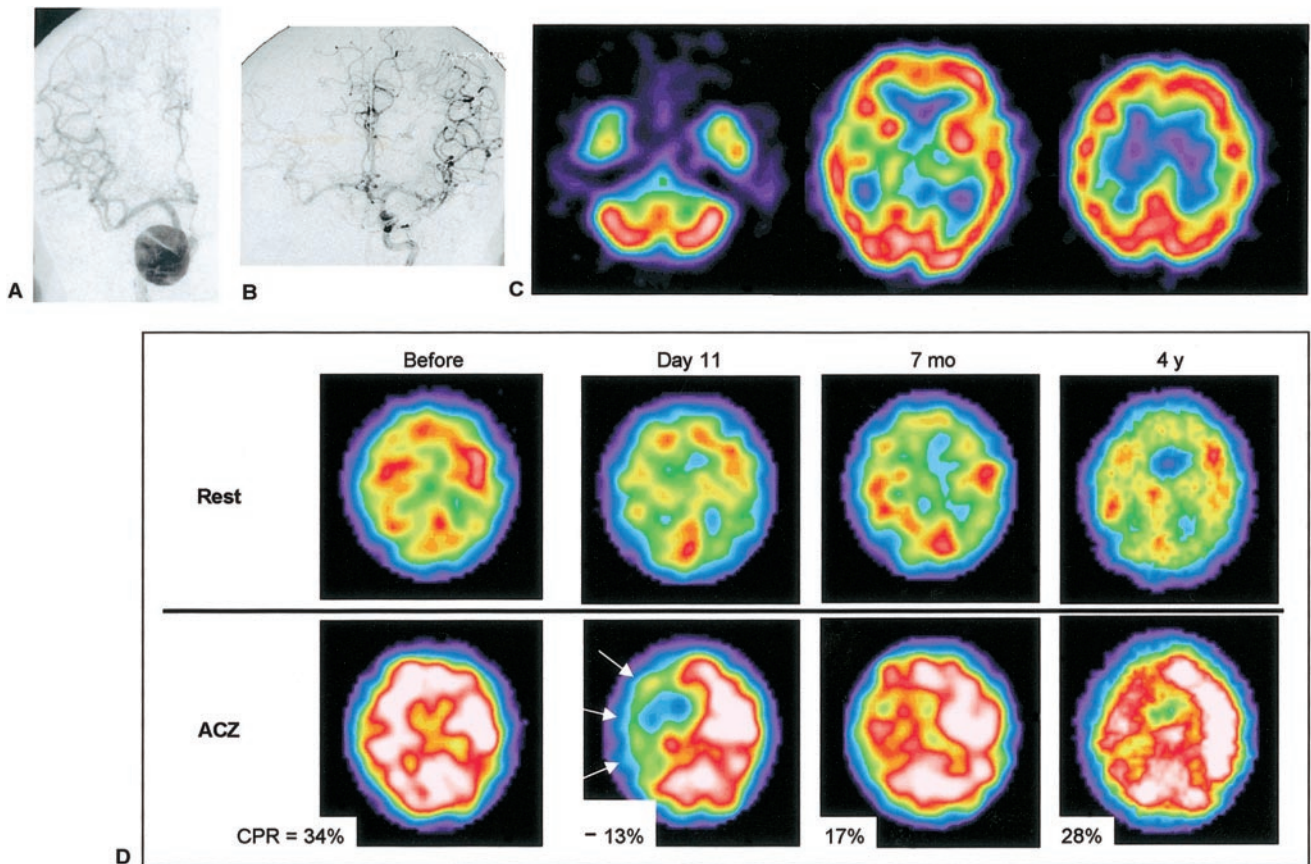
\*Transient left hemiparesis during hypotension.

†Small infarction probably due to thromboembolism.

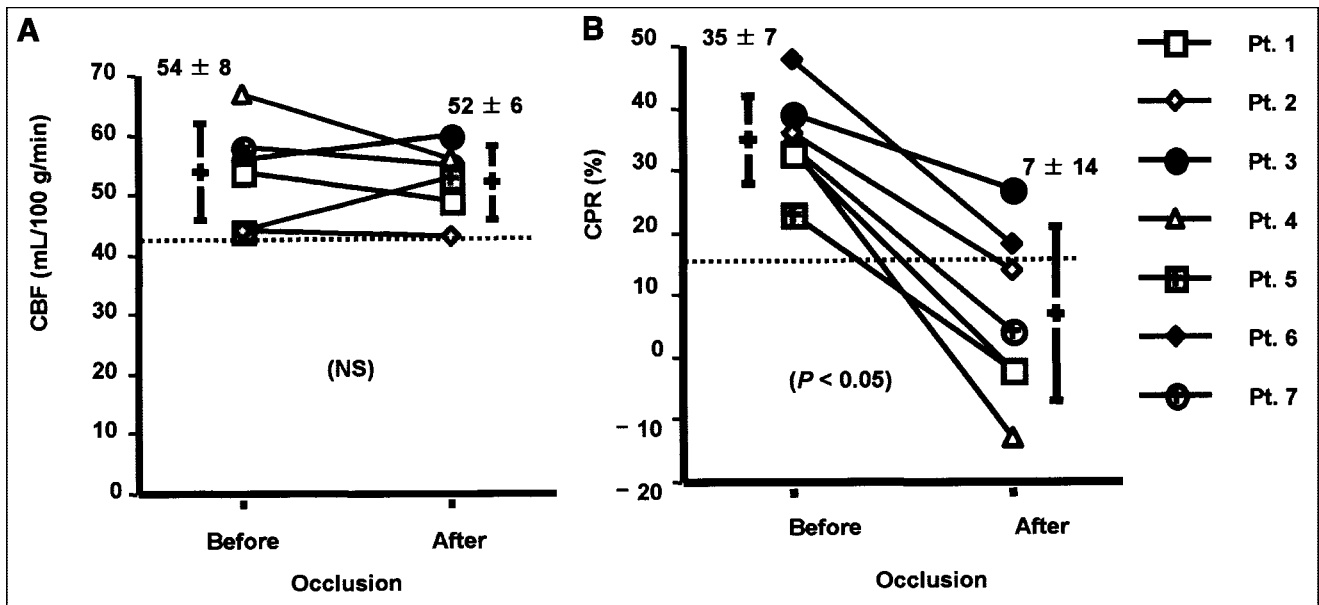
NA = not available.

decreased a little after permanent carotid occlusion (from  $54 \pm 8$  mL/100 g/min to  $52 \pm 6$  mL/100 g/min), and both CBF before occlusion and CBF after occlusion were within the normal range. In contrast, CPR significantly decreased

after permanent carotid occlusion (from  $35\% \pm 7\%$  to  $7\% \pm 14\%$ ,  $P < 0.05$ ). In 5 of 7 patients, CPR decreased below the normal range, and the steal phenomenon ( $rCPR < 0\%$ ) was observed in 3 patients.



**FIGURE 3.** A 63-y-old woman (patient 4) with giant aneurysm of right ICA. (A) Right ICA angiogram shows giant aneurysm in carotid siphon. (B) Left ICA angiogram during BOT of right ICA shows good collateral cross-flow. (C)  $^{99m}\text{Tc}$ -ECD SPECT images demonstrate symmetric cerebral uptake (L/N of 0.96), and no neurologic symptoms were observed. This patient was considered to be tolerant of carotid occlusion. However, after proximal occlusion of right ICA, she showed transient left hemiparesis when her blood pressure dropped. Her hemiparesis disappeared immediately after injection of vasoconstrictor, and no infarction developed. (D)  $^{133}\text{Xe}$ -CBF SPECT revealed normal CBF at rest but decreased CPR in right cerebral hemisphere (mean CPR in right MCA territory was  $-13\%$  on day 11) (arrows). On follow-up, impaired CPR gradually improved.



**FIGURE 4.** Comparisons of CBF and CPR before and after permanent carotid occlusion. (A) CBF changed slightly ( $54 \pm 8$  mL/100 g/min vs.  $52 \pm 6$  mL/100 g/min, not significant (NS)). (B) CPR significantly decreased in all patients after permanent carotid occlusion ( $35\% \pm 7\%$  vs.  $7\% \pm 14\%$ ,  $P < 0.05$ ). In 5 of 7 patients, CPR decreased below normal range (CPR < 15%), and steal phenomenon was observed in 3 patients.

On follow-up, the CBF values varied a little but remained within the normal range. In contrast, the decreased CPR gradually improved on follow-up (until approximately 4 y) after permanent carotid occlusion (Fig. 5).

## DISCUSSION

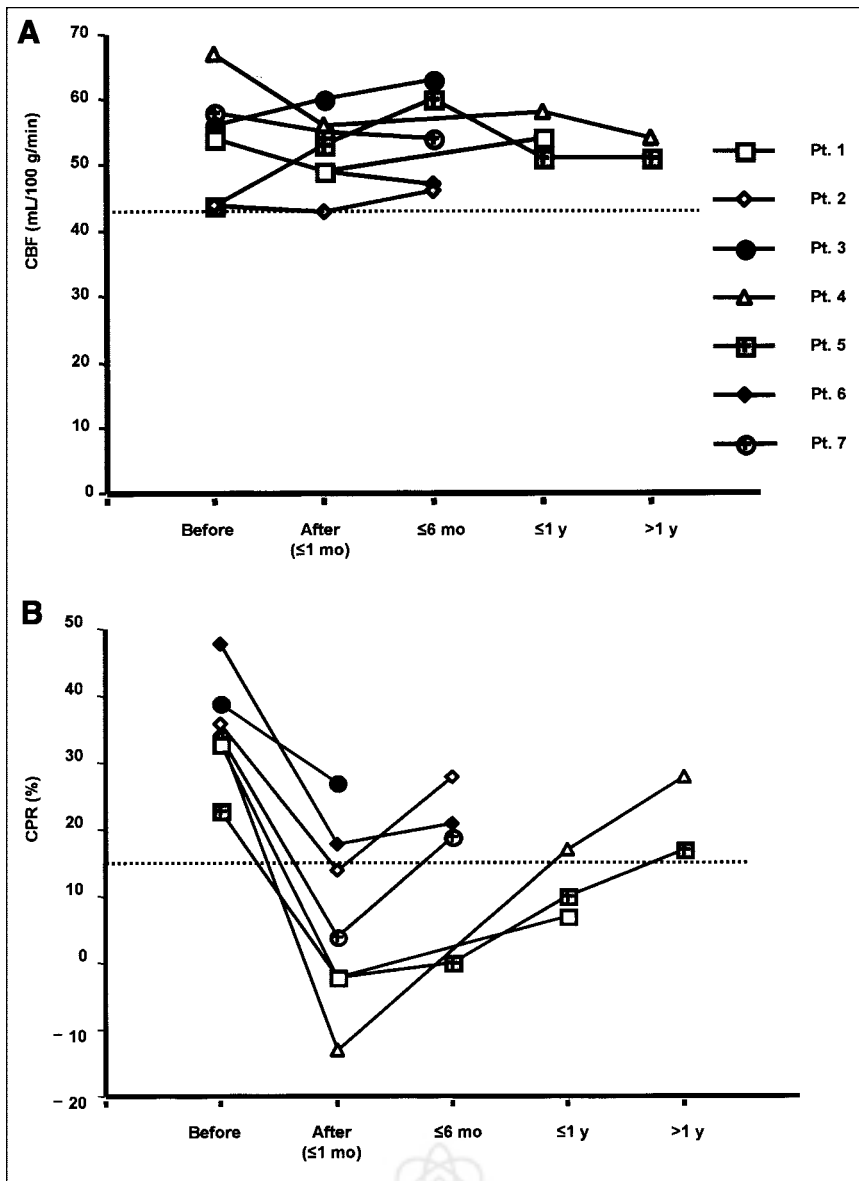
$^{99m}\text{Tc}$ -ECD SPECT was useful for detecting hypoperfusion during BOT. In the current study,  $^{99m}\text{Tc}$ -ECD SPECT showed moderate or severe hypoperfusion in 10 of 36 patients (28%) who showed no neurologic symptoms during BOT. This result is similar to previous findings (5,6). Simonson et al. (5) reported that 5 of 11 asymptomatic patients (45%) had decreased perfusion on  $^{99m}\text{Tc}$ -HMPAO SPECT. Mathews et al. (6) also reported that 9 of 34 patients (26%) showed only perfusion defects on  $^{99m}\text{Tc}$ -HMPAO SPECT. Thus, brain SPECT can depict clinically silent areas of decreased cerebral perfusion associated with asymptomatic BOT.

Previously, Nishioka (15) reported that nonselective occlusion of a carotid artery carried a 30% risk of ischemia of the ipsilateral hemisphere. Inadequate collateral circulation and thromboembolism are thought to be the 2 mechanisms causing ischemic complications (16). Although BOT cannot predict the risk of thromboembolism, which is a significant cause of delayed cerebral ischemia after carotid occlusion (8), inadequate collateral circulation (i.e., a cause of hemodynamic ischemia) should be detected by BOT before permanent occlusion to reduce the risk of ischemic complications. In reviewing the literature, Linskey et al. (3) reported that the risk of ischemic complications was reduced to 13% by selective carotid occlusion using BOT.

Because the distribution of  $^{99m}\text{Tc}$ -labeled CBF tracers ( $^{99m}\text{Tc}$ -HMPAO and  $^{99m}\text{Tc}$ -ECD) in the brain is stable after the first 5 min after injection, SPECT acquisition can be performed after completion of the test (i.e., still keeping a snapshot of the CBF image at the time of injection) (7). In this study, we preferred to use  $^{99m}\text{Tc}$ -ECD rather than  $^{99m}\text{Tc}$ -HMPAO, since the radiochemical purity and the stability of  $^{99m}\text{Tc}$ -ECD are better than those of  $^{99m}\text{Tc}$ -HMPAO after 30 min after the preparation (17,18). The excellent characteristics of  $^{99m}\text{Tc}$ -ECD thus enable injection of the tracer at any time during 30 min of BOT. The tracer could be injected as soon as possible when any symptom developed during BOT, and we could confirm the location and magnitude of CBF reduction during BOT.

Baseline  $^{99m}\text{Tc}$ -ECD SPECT was performed on only 6 patients in the current study. In these 6 patients, baseline SPECT showed normal symmetric perfusion, except for a patient with a brain tumor. Lorberboym et al. (8) also reported that all baseline studies (performed on 15/44 patients in their study) showed normal symmetric perfusion. Thus, although not performed in the current study and seemingly not necessary in all patient, baseline SPECT may be helpful to evaluate how CBF changed from the baseline condition during BOT. We would recommend that baseline SPECT be performed when abnormal perfusion is highly suspected at baseline and when abnormal or unexplainable findings are observed on SPECT during BOT.

Although no definite quantitative criteria are available to define perfusion abnormalities, an interhemispheric difference in activity greater than 10% (i.e., L/N ratio < 0.9) is generally accepted to be asymmetric (8,11). Monsein et al.



**FIGURE 5.** Changes in CBF and CPR on follow-up after permanent carotid occlusion. (A) CBF changed within normal range ( $\text{CBF} \geq 43 \text{ mL}/100 \text{ g}/\text{min}$ ). (B) In contrast, decreased CPR gradually improved after permanent carotid occlusion.

(11) seemed to consider a 10% difference to be of high importance, and symmetric perfusion ( $L/N \text{ ratio} \geq 0.9$ ) during BOT suggested brain tolerance against carotid occlusion. Palestro et al. (19) reported that the negative predictive value of symmetric perfusion ( $L/N \text{ ratio} \geq 0.9$ ) during BOT was 100% in 14 patients who underwent carotid occlusion. When these reports are combined, the predictive value of negative (symmetric) SPECT findings for a satisfactory outcome after permanent carotid occlusion ranges from approximately 80% to 100% (4,11,19–21).

However, as shown in Figure 3, CPR decreased after carotid occlusion even though resting CBF did not change. In these settings, an ischemic event might occur when cerebral perfusion pressure drops. Thus, some patients with normal CBF during BOT may still have a risk of ischemic events after permanent carotid occlusion because of reduced

CPR. In the current study, CPR was reduced in all patients, even though resting CBF was within the normal range after permanent carotid occlusion. Five of 7 patients (71%) showed subnormal CPR ( $<15\%$ ), and 3 of 7 patients (43%) showed the steal phenomenon.

Recently, an additional hypotensive challenge during BOT has been reported to be useful for decreasing the false-negative rate (21–24). Standard et al. (23) reported that 4 of 47 patients (9%) showed neurologic deficits during normotensive BOT, whereas 9 of the remaining 43 patients (21%) showed deficits during hypotensive BOT. The usefulness of the hypotensive challenge is still controversial. Its specificity may be decreased because of the addition of an unknown increased number of false-positive cases. However, the true rate of true-positives or false-positives is unknown, since patients may be successfully treated with-



out carotid sacrifice or patients who test positive may undergo unnecessary revascularization. Despite these limitations, Standard et al. recommended hypotensive challenge during BOT, since the additional morbidity and mortality associated with revascularization procedures are low (3%–5%) and are preferable to the increased morbidity of hemispheric stroke associated with carotid occlusion.

Nishioka (15) reported that 89% of ischemic complications occurred within 96 h after carotid occlusion. In the current analysis, CPR substantially decreased early after permanent carotid occlusion and then gradually improved over several years (Fig. 5). This finding indicates that the risk of hemodynamic ischemia is also higher early after occlusion than late after occlusion. These observations emphasize that we should monitor patients carefully, especially early after carotid occlusion.

Reduced CPR can spontaneously improve on follow-up. Coyle and Panzenbeck (25) reported, for an experimental rat study, that a significant increase in the diameter of the anterior communicating artery occurred 6 wk after ligation of the ipsilateral carotid artery. This finding suggested that collateral circulation can rapidly develop after permanent carotid occlusion. However, little is known about how rapidly collateral circulation develops in humans after carotid occlusion. Widder et al. (26) reported a spontaneous improvement in CO<sub>2</sub> reactivity over 5 y in 64% of patients with carotid occlusion. By semiquantitative analysis (by asymmetric index) using <sup>123</sup>I-iodoamphetamine and ACZ, Hasegawa et al. (27) reported that sequential changes in hemodynamic reserve were observed in patients with major cerebral arterial occlusive disease, and Cao et al. (28) similarly reported that a spontaneous normalization in reduced vasodilatory capacity was observed on follow-up in 8 of 20 patients (40%) with major cerebral arterial occlusive disease. However, Cao et al. reported that reduced CPR was more likely to improve in patients with initially mildly reduced ACZ reactivity and with stenosis but not occlusion. In the current study, however, improvement in reduced CPR was observed in all patients with permanent carotid occlusion on follow-up, although the timing and magnitude of improvement varied widely.

Studies have shown that patients with highly impaired CPR and increased oxygen extraction fraction have an increased risk of developing stroke (29,30). In our study, a transient ischemic complication occurred soon after permanent carotid occlusion in 1 of 3 patients with the steal phenomenon after permanent carotid occlusion. It is important to periodically examine CBF and CPR in patients after permanent carotid occlusion, since the timing and magnitude of improvement in reduced CPR varies among patients.

## CONCLUSION

Brain SPECT is useful for evaluating brain tolerance to carotid occlusion and is sensitive in detecting subclinical hypoperfusion during temporary BOT. Assessment of CPR

is recommended in order to predict the potential risk of hemodynamic ischemia and to follow up patients after permanent carotid occlusion.

## ACKNOWLEDGMENTS

The authors thank the staff of the Departments of Radiology and Neurological Surgery at Ehime University School of Medicine. This article was presented, in part, at the 48th annual meeting of the Society of Nuclear Medicine; Toronto, Ontario, Canada; June 2001.

## REFERENCES

1. Berenstein A, Ransohoff J, Kupersmith M, Flamm E, Graeb D. Transvascular treatment of giant aneurysms of the cavernous carotid and vertebral arteries: functional investigation and embolization. *Surg Neurol.* 1984;21:3–12.
2. Higashida RT, Halbach VV, Dowd C, et al. Endovascular detachable balloon embolization therapy of cavernous carotid artery aneurysms: results in 87 cases. *J Neurosurg.* 1990;72:857–863.
3. Linskey ME, Jungreis CA, Yonas H, et al. Stroke risk after abrupt internal carotid artery sacrifice: accuracy of preoperative assessment with balloon test occlusion and stable xenon-enhanced CT. *AJNR.* 1994;15:829–843.
4. Peterman SB, Taylor A Jr, Hoffman JC Jr. Improved detection of cerebral hypoperfusion with internal carotid balloon test occlusion and <sup>99m</sup>Tc-HMPAO cerebral perfusion SPECT imaging. *AJNR.* 1991;12:1035–1041.
5. Simonson TM, Ryals TJ, Yuh WT, Farrar GP, Rezaei K, Hoffman HT. MR imaging and HMPAO scintigraphy in conjunction with balloon test occlusion: value in predicting sequelae after permanent carotid occlusion. *AJR.* 1992;159:1063–1068.
6. Mathews D, Walker BS, Purdy PD, et al. Brain blood flow SPECT in temporary balloon occlusion of carotid and intracerebral arteries. *J Nucl Med.* 1993;34:1239–1243.
7. Askienazy S, Lebtahi R, Meder JF. SPECT HMPAO and balloon test occlusion: interest in predicting tolerance prior to permanent cerebral artery occlusion [editorial comment]. *J Nucl Med.* 1993;34:1243–1245.
8. Lorberboym M, Pandit N, Machac J, et al. Brain perfusion imaging during preoperative temporary balloon occlusion of the internal carotid artery. *J Nucl Med.* 1996;37:415–419.
9. Dare AO, Chaloupka JC, Putman CM, Fayad PB, Awad IA. Failure of the hypotensive provocative test during temporary balloon test occlusion of the internal carotid artery to predict delayed hemodynamic ischemia after therapeutic carotid occlusion. *Surg Neurol.* 1998;50:147–155.
10. Chang LT. A method for attenuation correction in radionuclide computed tomography. *IEEE Trans Nucl Sci.* 1978;25:638–643.
11. Monsein LH, Jeffery PJ, van Heerden BB, et al. Assessing adequacy of collateral circulation during balloon test occlusion of the internal carotid artery with <sup>99m</sup>Tc-HMPAO SPECT. *AJNR.* 1991;12:1045–1051.
12. Sugawara Y. SPECT evaluation of cerebral perfusion reserve in patients with occlusive cerebrovascular diseases: evaluation with acetazolamide test and crossed cerebellar diaschisis. *Kaku Igaku.* 1995;32:287–299.
13. Kikuchi K, Murase K, Miki H, et al. Measurement of cerebral hemodynamics with perfusion-weighted MR imaging: comparison with pre- and post-acetazolamide <sup>133</sup>Xe-SPECT in occlusive carotid disease. *AJNR.* 2001;22:248–254.
14. Kanno I, Lassen NA. Two methods for calculating regional cerebral blood flow from emission computed tomography of inert gas concentrations. *J Comput Assist Tomogr.* 1979;3:71–76.
15. Nishioka H. Results of the treatment of intracranial aneurysms by occlusion of the carotid artery in the neck. *J Neurosurg.* 1966;25:660–704.
16. Fox AJ, Vinuela F, Pelz DM, et al. Use of detachable balloons for proximal artery occlusion in the treatment of unclippable cerebral aneurysms. *J Neurosurg.* 1987;66:40–46.
17. Leveille J, Demonceau G, Walovitch RC. Intrasubject comparison between technetium-99m-ECD and technetium-99m-HMPAO in healthy human subjects. *J Nucl Med.* 1992;33:480–484.
18. Leveille J, Demonceau G, De Roo M, et al. Characterization of technetium-99m-L,L-ECD for brain perfusion imaging, part 2: biodistribution and brain imaging in humans. *J Nucl Med.* 1989;30:1902–1910.
19. Palestro CJ, Sen C, Muzinic M, Afriyie M, Goldsmith SJ. Assessing collateral

- cerebral perfusion with technetium-99m-HMPAO SPECT during temporary internal carotid artery occlusion. *J Nucl Med*. 1993;34:1235–1238.
20. Moody EB, Dawson RCd, Sandler MP. <sup>99m</sup>Tc-HMPAO SPECT imaging in interventional neuroradiology: validation of balloon test occlusion. *AJNR*. 1991; 12:1043–1044.
  21. Oritano TC, al-Mefty O, Leonetti JP, DeMonte F, Reichman OH. Vascular considerations and complications in cranial base surgery. *Neurosurgery*. 1994; 35:351–362.
  22. Komiyama M, Khosla VK, Tamura K, Nagata Y, Baba M. A provocative internal carotid artery balloon occlusion test with <sup>99m</sup>Tc-HM-PAO CBF mapping: report of three cases. *Neurol Med Chir (Tokyo)*. 1992;32:747–752.
  23. Standard SC, Ahuja A, Guterman LR, et al. Balloon test occlusion of the internal carotid artery with hypotensive challenge. *AJNR*. 1995;16:1453–1458.
  24. Tanaka F, Nishizawa S, Yonekura Y, et al. Changes in cerebral blood flow induced by balloon test occlusion of the internal carotid artery under hypotension. *Eur J Nucl Med*. 1995;22:1268–1273.
  25. Coyle P, Panzenbeck MJ. Collateral development after carotid artery occlusion in Fischer 344 rats. *Stroke*. 1990;21:316–321.
  26. Widder B, Kleiser B, Krapf H. Course of cerebrovascular reactivity in patients with carotid artery occlusions. *Stroke*. 1994;25:1963–1967.
  27. Hasegawa Y, Yamaguchi T, Tsuchiya T, Minematsu K, Nishimura T. Sequential change of hemodynamic reserve in patients with major cerebral artery occlusion or severe stenosis. *Neuroradiology*. 1992;34:15–21.
  28. Cao B, Hasegawa Y, Yokota C, Minematsu K, Yamaguchi T. Spontaneous improvement in reduced vasodilatory capacity in major cerebral arterial occlusive disease. *Neuroradiology*. 2000;42:19–25.
  29. Yonas H, Smith HA, Durham SR, Pentheny SL, Johnson DW. Increased stroke risk predicted by compromised cerebral blood flow reactivity. *J Neurosurg*. 1993;79:483–489.
  30. Yamauchi H, Fukuyama H, Nagahama Y, et al. Evidence of misery perfusion and risk for recurrent stroke in major cerebral arterial occlusive diseases from PET. *J Neurol Neurosurg Psychiatry*. 1996;61:18–25.

