
Rapid Imaging of Experimental Colitis with ^{99m}Tc -Interleukin-8 in Rabbits

Stefan Gratz, Huub J.J.M. Rennen, Otto C. Boerman, Wim J.G. Oyen, and Frans H.M. Corstens

Department of Nuclear Medicine, University Medical Center Nijmegen, Nijmegen, The Netherlands

Radiolabeled autologous leukocytes (WBCs) are the gold standard for imaging inflammatory bowel disease (IBD). For the rapid and adequate management of patients with IBD, there is need for a new agent at least as good as radiolabeled WBCs, but easier to prepare and without its inherent risks. In this study, the potential of interleukin-8 (IL-8) labeled with ^{99m}Tc using hydrazinonicotinamide (HYNIC) to image IBD was investigated in a rabbit model of acute colitis and compared with that of ^{99m}Tc -HMPAO-labeled granulocytes. **Methods:** In rabbits with chemically induced acute colitis, inflammatory lesions were scintigraphically visualized after injection of either IL-8 or purified granulocytes, both labeled with ^{99m}Tc . Gamma camera images were acquired at 2 min and at 1, 2, and 4 h after injection. Four hours after injection, the rabbits were killed, and the uptake of the radiolabel in the dissected tissues was determined. The dissected colon was imaged and the inflammatory lesions were scored macroscopically. For each affected colon segment, the colitis index (affected colon-to-normal colon uptake ratio, CI) was calculated and correlated with the macroscopically scored severity of inflammation. **Results:** Both agents visualized the colitis within 1 h after injection. ^{99m}Tc -HYNIC-IL-8 images of the colonic abnormalities were more accurate and the intensity of uptake in the affected colon continuously increased until 4 h after injection, whereas no further increase 1 h after injection was noticed scintigraphically for ^{99m}Tc -HMPAO-granulocytes. The absolute uptake in the affected colon was much higher for IL-8 than for the radiolabeled granulocytes with the percentage injected dose per gram (%ID/g) 0.41 ± 0.04 %ID/g and 0.09 ± 0.05 %ID/g 4 h after injection, respectively. With increasing severity, the CI at 4 h after injection for ^{99m}Tc -HYNIC-IL-8 was 4.4 ± 0.6 , 13.5 ± 0.5 , and 25.8 ± 1.0 ; for granulocytes, the CI at 4 h after injection was 1.5 ± 0.1 , 3.4 ± 0.2 , and 6.4 ± 0.5 , respectively. The CI correlated with the severity of the inflammation ($r = 0.95$, $P < 0.0001$ for IL-8; $r = 0.95$, $P < 0.0001$ for granulocytes). **Conclusion:** Within 1 h after injection, visualization of the extent of colonic inflammation in vivo was possible with ^{99m}Tc -HYNIC-IL-8 and ^{99m}Tc -HMPAO-granulocytes. Within 2 h after injection, ^{99m}Tc -IL-8 allowed a good evaluation, and within 4 h after injection, a meticulous evaluation of the severity of IBD. Although ^{99m}Tc -HMPAO-granulocytes were able to delineate the extent of IBD within 2 h after injection, an accurate estimation of severity of inflammation was not possible. ^{99m}Tc -HYNIC-IL-8 is an inflammation-imaging agent that showed promising results in this

study. ^{99m}Tc -IL-8 can be prepared off-the-shelf and yields excellent imaging with high target-to-background ratios.

Key Words: inflammatory bowel disease; interleukin-8; granulocytes; imaging infection; technetium

J Nucl Med 2001; 42:917-923

The degree of activity of inflammatory bowel disease (IBD) may be difficult to evaluate because of the fluctuating episodes of relapses and remissions of acute colitis. A noninvasive method for monitoring the disease is needed to allow accurate therapeutic management of patients during exacerbations of IBD. Various nuclear medicine diagnostic procedures have become available for evaluating the status of the diseased colon. The advantage of nuclear medicine procedures over conventional diagnostic modalities, such as planar radiography with barium, is their ability to provide functional information and to allow an estimation of the degree of inflammatory activity in affected areas in the intestine, rather than to give information of a more morphologic nature. The radiopharmaceutical of choice for imaging IBD at present is radiolabeled leukocytes. Unfortunately, the preparation has several disadvantages limiting its application (e.g., laboriousness, handling of possibly contaminated blood). Therefore, an agent is needed that is at least as good as radiolabeled white blood cells (WBCs) but easier to prepare.

IBDs with chronic character, such as Crohn's disease, are characterized by a high intestinal mononuclear cell infiltration (1). More acute IBDs, such as ulcerative colitis, are characterized by a strong neutrophil infiltration to the extracellular matrix of the colonic wall. Proinflammatory cytokines play an important role in the neutrophil recruitment of neutrophils into the colonic mucosa. Levels of these cytokines (interleukin-1 β [IL-1 β], IL-6, IL-8, and tumor necrosis factor- α), as well as neutrophils expressing receptors for these cytokines, are markedly increased in active ulcerative colitis compared with the normal noninflamed bowel tissue (2). In acute IBD, chemotactic factors generated in the mucosa attract neutrophils from the circulation into the inflammatory site and induce infiltration of neutrophils in the interstitial tissue, thus contributing to accumulation and activation of neutrophils in the infected mucosa

Received Nov. 1, 2000; revision accepted Feb. 15, 2001.

For correspondence or reprints contact: Stefan Gratz, MD, Department of Nuclear Medicine, University Medical Center Nijmegen, P.O. Box 9101, 6500 HB Nijmegen, The Netherlands.

(3). Because neutrophils express high-affinity IL-8 receptors (0.3–4 nmol/L) (4–7), radiolabeled IL-8 might prove useful for the imaging of acute IBD.

The scintigraphic imaging characteristics of radiolabeled IL-8 strongly depend on the procedure of labeling. van der Laken et al. (8) showed that ^{123}I -IL-8 labeled using the Bolton–Hunter method was clearly superior to ^{123}I -IL-8 labeled using the IODO-GEN (Pierce, Rockford, IL) method, despite similar in vitro cell binding characteristics. Recently, we described the development of a $^{99\text{m}}\text{Tc}$ -labeled IL-8 preparation using hydrazinonicotinamide (HYNIC) as a chelator (9). In rabbits with *Escherichia coli* infection, absolute uptake of $^{99\text{m}}\text{Tc}$ -HYNIC-IL-8 in the soft-tissue abscess was more rapid and higher than that obtained with the radioiodinated preparation, whereas abscess-to-muscle ratios reached values >100 at 8 h after injection (9). Furthermore, $^{99\text{m}}\text{Tc}$ -HYNIC-IL-8 showed a remarkably fast clearance from nontarget tissues.

We studied the performance of $^{99\text{m}}\text{Tc}$ -HYNIC-IL-8 in a well-established animal model of acute IBD (10,11). $^{99\text{m}}\text{Tc}$ -HMPAO-labeled purified granulocytes were used as a reference agent in this study. The in vivo characteristics of $^{99\text{m}}\text{Tc}$ -HYNIC-IL-8 were compared in rabbits with chemically induced colitis (11) with those obtained after administration of $^{99\text{m}}\text{Tc}$ -HMPAO labeled purified granulocytes.

The aim of this study was 2-fold: to determine the potential of $^{99\text{m}}\text{Tc}$ -HYNIC-IL-8 to visualize acute colitis in rabbits and to find the earliest imaging time point that allows accurate diagnosis of acute colitis using this agent.

MATERIALS AND METHODS

Animal Model

In 10 female New Zealand White rabbits (weight, 2.5–3 kg), acute colitis was induced as described with minor modifications (12–14). Briefly, the rabbits were anesthetized with an intramuscular injection of a 0.7-mL mixture of 0.315 mg/mL fentanyl and 10 mg/mL fluanisone (Hypnorm; Janssen Pharmaceutical, Oxford, U.K.). After retrograde insertion of a flexible silicone tube, 1 mL 50% ethanol followed by 1 mL 25 mg trinitrobenzene sulfonic acid (TNBS; Sigma Chemicals, St. Louis, MO) in 50% ethanol, and 3 mL 50% ethanol flush, was instilled in the colon at 25 cm proximal to the anal sphincter. Forty-eight hours after induction of the colitis, the respective radiopharmaceuticals were injected into the ear vein. Experiments were performed in accordance with the guidelines of the local animal welfare committee. During the experiment, the rabbits were kept fasting. Water was provided ad libitum.

Radiopharmaceuticals

Preparation of HYNIC-Conjugated IL-8. Human recombinant IL-8 was kindly provided by Dr. Ivan Lindley (Novartis, Vienna, Austria). IL-8 was conjugated to HYNIC essentially as described by Abrams et al. (15). Briefly, in a 1.5-mL vial, 1.5 μL 1 mol/L NaHCO_3 , pH 8.2, was added to 15 μL IL-8 (5.7 mg/mL). Subsequently, a 3-fold excess of succinimidyl-hydrazinonicotinamide (S-HYNIC) in 5 μL dry dimethyl sulfoxide was added in drops to the IL-8 solution. After incubation at room temperature for 3 min, the reaction was stopped by adding 115 μL 1.0 mol/L glycine

solution in phosphate-buffered saline (PBS). Subsequently, 30 μL precooled PBS was added to a total volume of 170 μL . To remove excess unconjugated S-HYNIC, the mixture was extensively dialyzed against PBS (0.1- to 0.5-mL dialysis cell, 3.5 molecular weight cutoff; Pierce). Dialyzed samples of circa 7 μg IL-8-HYNIC were stored at -20°C .

$^{99\text{m}}\text{Tc}$ Labeling of HYNIC-Conjugated IL-8. Tricine- SnSO_4 kits (0.2 mL) were prepared containing 20 mg tricine (*N*-[tris(hydroxymethyl)methyl]glycine; Fluka, Buchs, Switzerland) and 0.01 mg SnSO_4 (Merck, Darmstadt, Germany) in 0.2 mL PBS, pH 7.0. To prevent precipitation of stannous ion, SnSO_4 dissolved in 2 mol/L HCl was added to a solution of tricine in PBS; pH was subsequently adjusted to 7.0 with 1.0 mol/L NaOH.

For the rabbit studies, a 0.2-mL tricine- SnSO_4 kit and 0.5 mL 400 MBq $^{99\text{m}}\text{TcO}_4^-$ in saline were added to 7 μg thawed HYNIC-IL-8 and incubated at room temperature for 30 min. After the labeling reaction, the reaction mixture was applied on a Sephadex G-25 column (PD-10; Pharmacia, Uppsala, Sweden) and eluted with 0.5% bovine serum albumin in PBS to purify the radiolabeled IL-8. The radiochemical purity was determined by instant thin-layer chromatography (ITLC) on ITLC-SG strips (Gelman Laboratories, Ann Arbor, MI) with 0.1 mol/L citrate, pH 6.0, as the mobile phase. Each rabbit was injected with 18.5 MBq $^{99\text{m}}\text{Tc}$ labeled to 0.5 mL IL-8 solution.

Receptor Binding Assay

As described by Rennen et al. (9), the leukocyte receptor binding fraction of the $^{99\text{m}}\text{Tc}$ -IL-8 preparation was determined in an in vitro receptor binding assay. For this assay, heparinized human whole blood (10 mL) was mixed with 2.5 mL 5% dextran (Sigma). After sedimentation of the red blood cell bulk for 1 h at room temperature, the remainder of the blood sample was washed in incubation buffer (1 mmol/L NaH_2PO_4 , 5 mmol/L Na_2HPO_4 , 140 mmol/L NaCl, 0.5 mmol/L MgCl_2 , 0.15 mmol/L CaCl_2 , 0.5% human serum albumin, pH 7.4) and centrifuged at 500g for 20 min. The cell pellet was then resuspended in 7 mL incubation buffer and layered on 5 mL Ficoll-Hypaque (Pharmacia), followed by centrifugation at 500g for 20 min. The pellet was washed once and subsequently resuspended in incubation buffer. Afterward, a series of serially diluted polymorphonuclear (PMN) suspensions ($0.5\text{--}8 \times 10^6$ cells PMNs/0.5 mL) was incubated with 10,000 cpm $^{99\text{m}}\text{Tc}$ -IL-8 during 2 h at 37°C . A duplicate of the lowest cell concentration was incubated in the presence of a 100-fold molar excess of unlabeled IL-8 to determine the nonspecific binding. The radioactivity in the cell pellet (total bound activity) was measured in a shielded well scintillation gamma counter (Wizard; Pharmacia-LKB, Uppsala, Sweden).

The specific activity of $^{99\text{m}}\text{Tc}$ -IL-8 was 20 MBq/ μg . The radiochemical purity of the radiopharmaceutical was $>95\%$ after gel filtration, as determined by ITLC. The receptor binding fraction of the $^{99\text{m}}\text{Tc}$ -IL-8 preparation was 65%.

$^{99\text{m}}\text{Tc}$ -HMPAO-Granulocytes

Carotid artery cannulation was performed on 1 anesthetized donor rabbit. A total amount of 100 mL blood was carefully drawn into acid/citrate/dextrose tubes (containing 7 mL acid/citrate/dextrose per 35 mL blood). The total leukocyte count of the donor rabbits was $7.1 \times 10^9/\text{L}$ with approximately 50% granulocytes. Purification of granulocytes was performed according to the method described by Lillevang et al. (16) with minor modifications (17). Briefly, the blood was mixed with 0.1 volume of 6% dextran (Dextran 500; Pharmacia) solution in 0.9% NaCl and allowed to

settle for 1 h at room temperature. The leukocyte-rich supernatant was layered carefully on one-third volume of Nycoprep density medium (14.1% Nycodenz, 0.3% NaCl, 5 mmol/L Tricine/NaOH pH, 7.2; density = 1.077 g/mL; osmolality = 265 mOsm; Nycoprep, Oslo, Norway) and centrifuged for 15 min at 600g. The plasma above the mononuclear cells, the mononuclear band and the density medium above the granulocyte pellet were carefully removed. The pellet was washed with 5 mL Hanks' balanced salt solution (HBSS) with 10% autologous plasma and centrifuged for 10 min at 50g. The cell pellet was resuspended in 1.5 mL HBSS/10% rabbit plasma. After this purification procedure, the granulocyte purity was >90% (11). Added to the cell suspension was 0.5 GBq freshly prepared ^{99m}Tc -hexamethylpropyleneamine oxine (HMPAO). The cells were incubated at room temperature for 30 min and centrifuged for 10 min at 50g. The pellet was resuspended in 5 mL cell-free autologous plasma. Labeling efficiency (cell-associated activity/total activity added) exceeded 80%. Functional integrity of labeled granulocytes was evaluated by their *in vivo* performance, including hepatic and splenic uptake and transit through the lungs. A dose of 18.5 MBq ^{99m}Tc -granulocytes was administered intravenously in each rabbit.

Gamma Camera Image Acquisition and Data Analysis

Forty-eight hours after induction of the colitis, 5 rabbits were intravenously injected through the ear vein with ^{99m}Tc -HYNIC-IL-8. Another group of 5 rabbits was injected with ^{99m}Tc -HMPAO-WBCs. The rabbits were immobilized in a mold and placed prone on a gamma camera equipped with a parallel-hole, low-energy, all-purpose collimator (Orbiter; Siemens Medical Systems, Hoffman Estates, IL). Each rabbit was imaged at 2 min and at 1, 2, and 4 h after injection. Images with 300,000 counts were acquired and stored in a 256×256 matrix.

After acquiring the final images, the rabbits were killed with an overdose of sodium phenobarbital, and biodistribution of the radiolabeled radiopharmaceuticals was determined. After dissection, an image of the entire dissected colon was acquired (100,000 counts per image) using the same collimator and matrix. Blood was obtained by cardiac puncture. Tissues (lung, liver, spleen, kidney, small intestine, normal [ascending] colon, and affected [transverse and descending] colon) were obtained. The affected colon was divided into 7 consecutive colonic segments of 5 cm

each. The degree of inflammation of the colonic segments was scored macroscopically on an arbitrary scale (0 = no visible abnormalities, 1 = redness and wall thickening, 2 = ulcers). The tissue samples were weighed and the radioactivity was measured in a shielded well scintillation gamma counter (Wizard; Pharmacia-LKB). The stool and the intestinal wall of the inflamed and the noninflamed colon were separately analyzed and their average uptake was assessed. To correct for decay and to permit calculation of the uptake of the radiolabeled radiopharmaceuticals in each organ as a fraction of the injected dose, aliquots of 1% of the injected dose were counted simultaneously. The results were expressed as the percentage injected dose per gram (%ID/g). From these results, the colitis index (affected-to-normal colon ratio [CI]) for each of the radiopharmaceuticals was calculated for each segment.

Statistical Analysis

All mean uptake values are given as %ID/g \pm 1 SEM. For statistical analysis, the Mann-Whitney test was performed and correlations were calculated by linear regression analysis using the Spearman rank correlation (GraphPad InStat 3.00 Win 95; GraphPad Software, San Diego, CA). The level of significance was set at $P < 0.05$.

RESULTS

Two days after the retrograde installation of TNBS in all 10 rabbits, severe mucosal alterations in the colon transversum and colon descendens were observed.

The scintigraphic images of the 2 radiotracers at 2 min and at 1, 2, and 4 h after injection, as well as the respective image of the dissected colon 4 h after injection, are shown in Figure 1. Both radiotracers showed focally increased uptake in the inflamed colon. Quantitative analysis of the scintigrams of ^{99m}Tc -HMPAO-granulocytes showed that the lung uptake decreased from 39 %ID to 17 %ID between 5 min and 1 h after injection. The hepatic uptake did not exceed 17 %ID at 2 h after injection, indicating that the ^{99m}Tc labeling procedure had not compromised granulocyte function.

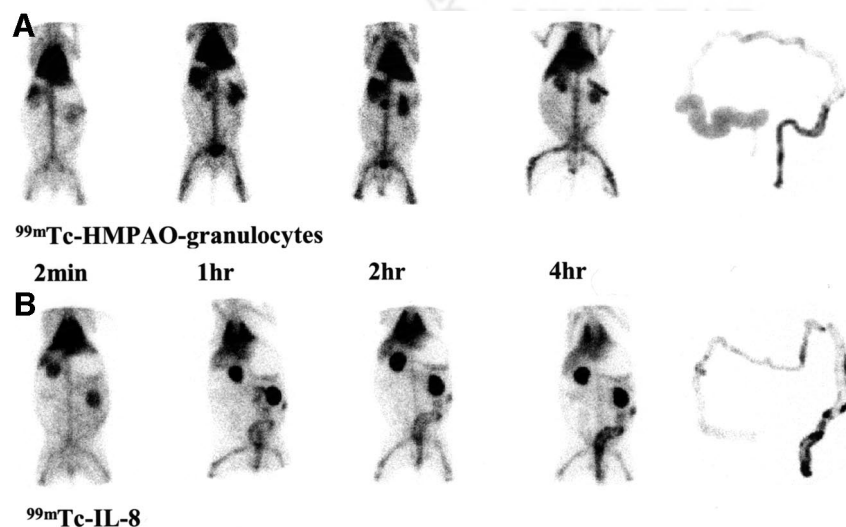


FIGURE 1. Scintigraphic images of rabbits with experimental colitis, imaged at 2 min and at 1, 2, and 4 h after injection, together with separate image of dissected colon of ^{99m}Tc -HMPAO-granulocytes (A). *In vivo*, no nonspecific bowel uptake is seen until 4 h after injection and ^{99m}Tc -HYNIC-IL-8 (B).

^{99m}Tc-HYNIC-IL-8 and ^{99m}Tc-HMPAO-granulocytes nicely delineated the inflamed colon as early as 1 h after injection. With ^{99m}Tc-HYNIC-IL-8, the extent of the inflammation in the colon was clearly visualized at 2 h after injection and a further increase of uptake in the inflamed colon was observed until 4 h after injection. Whole-body images of the rabbit and images of the dissected colon clearly showed the focal ulcerations and the extent of the colonic inflammation (Fig. 1). Using ^{99m}Tc-HMPAO-granulocytes, images were less precise because uptake in the inflammatory foci was much lower at 2 and 4 h after injection. No nonspecific bowel uptake was apparent with either of the radiotracers until 4 h after injection. The quantitative analysis of both radiotracers with respect to the uptake in the infected colon is summarized in Table 1.

The biodistribution data of ^{99m}Tc-HYNIC-IL-8 and ^{99m}Tc-HMPAO-granulocytes at 4 h after injection are shown in Table 2. The uptake of ^{99m}Tc-HYNIC-IL-8 in the affected colon exceeded that of ^{99m}Tc-HMPAO-WBCs by a factor of 4.5 (0.41 ± 0.04 %ID/g for ^{99m}Tc-IL-8 and 0.091 ± 0.05 %ID/g for ^{99m}Tc-HMPAO-WBCs, respectively) ($P < 0.007$). ^{99m}Tc-HYNIC-IL-8 showed higher CIs at 1 and 4 h after injection compared with ^{99m}Tc-HMPAO-granulocytes (grades 0, 1, and 2 at 1 h after injection, $P < 0.05$; and at 4 h after injection, $P < 0.008$ each grade) (Figs. 2A and 2B). The uptake of both radiotracers in the nonaffected colon was similarly low (Table 3). Consequently, the affected colon/nonaffected colon uptake was much higher for ^{99m}Tc-HYNIC-IL-8 with 18.5 ± 4.1 , compared with 4.1 ± 1.4 for ^{99m}Tc-HMPAO-granulocytes ($P < 0.007$) (Table 3). With both radiotracers, the CIs increased with the severity of inflammation. When evaluating the relative uptake in the affected segments for both radiopharmaceuticals, a positive correlation was observed between CIs and the severity of the macroscopic abnormalities (Fig. 3). For ^{99m}Tc-HYNIC-IL-8, the correlation ($r^2 = 0.95$, $P < 0.0001$) was as strong as for ^{99m}Tc-HMPAO-WBCs ($r^2 = 0.95$, $P < 0.0001$).

^{99m}Tc-IL-8 and ^{99m}Tc-HMPAO-granulocytes showed similar low uptake in the stool (Table 2) of the affected

TABLE 2
Biodistribution of ^{99m}Tc-HYNIC-IL-8 and ^{99m}Tc-HMPAO-Granulocytes in 2 Groups of Rabbits with Experimental Colitis

Parameter	4 h after injection		P*
	^{99m} Tc-HYNIC-IL-8 (%ID/g)	^{99m} Tc-HMPAO-granulocytes (%ID/g)	
Blood	0.044 ± 0.001	0.30 ± 0.03	<0.007
Small intestine	0.032 ± 0.003	0.024 ± 0.003	<0.06
Nonaffected colon tissue	0.025 ± 0.004	0.023 ± 0.008	<0.70
Affected colon tissue	0.41 ± 0.04	0.091 ± 0.055	<0.007
Feces			
Nonaffected colon	0.005 ± 0.001	0.015 ± 0.003	<0.35
Affected colon	0.013 ± 0.002	0.022 ± 0.007	<0.26
Lung	0.27 ± 0.09	0.18 ± 0.01	<0.70
Spleen	0.67 ± 0.22	0.83 ± 0.12	<0.15
Kidney	1.86 ± 0.28	0.20 ± 0.01	<0.007
Liver	0.091 ± 0.005	0.21 ± 0.03	<0.007

*Mann-Whitney test: ^{99m}Tc-HYNIC-IL-8 vs. ^{99m}Tc-HMPAO-granulocytes. Level of significance was set at $P < 0.05$.

Biodistribution of 2 groups of rabbits (5 rabbits per group) is shown at 4 h after injection. Data are expressed as mean \pm SEM.

colon and the nonaffected colon as well as in the nonaffected colonic wall. The absolute uptake in the stool of the inflamed colon and the total uptake in the inflamed colonic wall and the ratios of the uptake in the inflamed colon and the nonaffected colon are shown in Tables 2 and 3. The 4.5-fold higher %ID/g uptake of ^{99m}Tc-IL-8 compared with ^{99m}Tc-HMPAO in the affected colonic wall led to an affected colonic wall/affected stool ratio of 31:1 for ^{99m}Tc-IL-8, compared with a ratio of 4:1 for ^{99m}Tc-HMPAO WBCs, respectively.

At 4 h after injection, ^{99m}Tc-HYNIC-IL-8 showed significantly higher uptake for the different grades of inflammation ($P < 0.008$) compared with those after injection of ^{99m}Tc-HMPAO-granulocytes. Focal uptake in the inflamed

TABLE 1
Uptake of ^{99m}Tc-HYNIC-IL-8 and ^{99m}Tc-HMPAO-Granulocytes in Affected and Nonaffected Colonic Segments

Time	^{99m} Tc-HYNIC-IL-8		^{99m} Tc-HMPAO-granulocytes		P†
	Nonaffected* (%ID)	Affected (%ID)	Nonaffected* (%ID)	Affected (%ID)	
2 min	—	0.012 ± 0.003	—	0.010 ± 0.003	<0.7
1 h	—	0.034 ± 0.005	—	0.029 ± 0.003	<0.5
2 h	—	0.07 ± 0.017	—	0.021 ± 0.002	<0.03
4 h	—	0.08 ± 0.02	—	0.019 ± 0.006	<0.03

*No visual uptake.

†Mann-Whitney test: ^{99m}Tc-HYNIC-IL-8 vs. ^{99m}Tc-HMPAO-granulocytes. Level of significance was set at $P < 0.05$. Colonic uptake (%ID [mean \pm SEM]) of both tracers is shown at different time points.

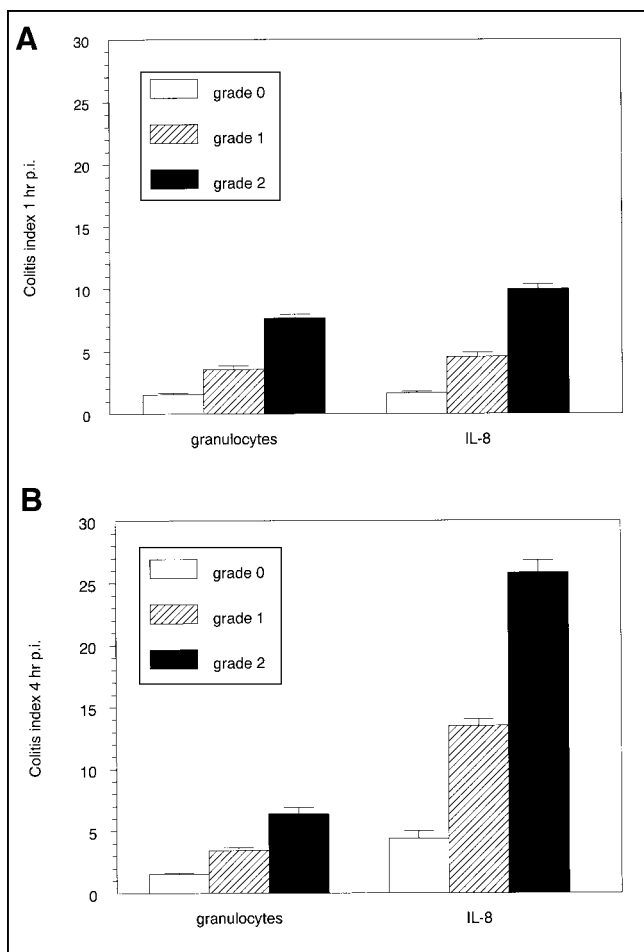


FIGURE 2. CIs of both radiotracers at 1 h (A) and 4 h (B) postinjection (p.i.) compared with severity of macroscopic inflammation (grade 0 = normal; grade 1 = inflammation; grade 2 = ulceration). Error bars represent SEM.

colon 4 h after injection allowed a point-by-point comparison with macroscopic ulcerations at inflammatory sites. Furthermore, ^{99m}Tc -HYNIC-IL-8 had significantly lower blood levels than ^{99m}Tc -HMPAO-WBCs ($P < 0.007$), resulting in a lower uptake in background tissues (muscle, small intestine). In the kidneys, the uptake of the ^{99m}Tc -IL-8

Macroscopic aspect of colonic mucosa

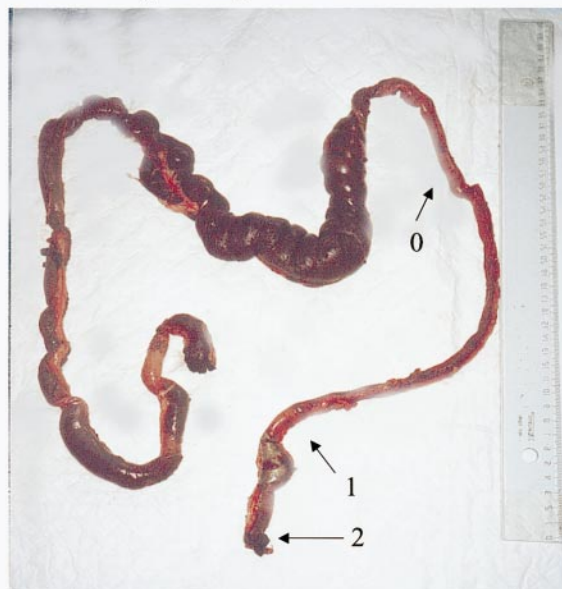


FIGURE 3. Macroscopic aspect of colonic mucosa in TNBS-induced acute colitis. Scoring of inflammation is shown: 0 = normal (colon descending); 1 = inflammation (sigmoid colon); 2 = ulceration (rectum).

was higher probably because of tubular reabsorption of the peptide (18,19). The uptake of both radiotracers in most other tissue samples was remarkably similar. Hepatic uptake of ^{99m}Tc -HYNIC-IL-8 was relatively low, reflecting the predominantly renal excretion of the tracer.

DISCUSSION

For nuclear medicine imaging of IBD, the use of radio-labeled leukocytes still is the gold standard because an accurate diagnosis of the extent and severity of IBD is possible. Several reports documented the superior performance of ^{99m}Tc -HMPAO-WBCs compared with ^{111}In -WBCs for the evaluation of colitis (20–22). When ^{99m}Tc -HMPAO-WBCs are used, only images 2 h after injection

TABLE 3

Relative Uptake of ^{99m}Tc -HYNIC-IL-8 and ^{99m}Tc -HMPAO-Granulocytes in Stool and Colonic Wall and Absolute Uptake of ^{99m}Tc -HYNIC-IL-8 and ^{99m}Tc -HMPAO-Granulocytes for Ratio of Inflamed Healthy Colon

Parameter	4 h after injection				P^*
	^{99m}Tc -HYNIC-IL-8		^{99m}Tc -HMPAO-granulocytes		
	%ID	Relative uptake	%ID	Relative uptake	
Stool in inflamed colon	1.07	(12.6 ± 3.5)	0.38	(19.8 ± 3.5)	<0.42
Inflamed colonic wall	5.18	(87.3 ± 3.5)	1.70	(80.1 ± 3.5)	<0.51
Ratio of inflamed to healthy colon		%ID/g 18.5 ± 4.1		%ID/g 4.1 ± 1.4	<0.007

*For ^{99m}Tc -HYNIC-IL-8 vs. ^{99m}Tc -HMPAO-granulocytes. Data are expressed as mean ± SEM. Level of significance was set at $P < 0.05$.

(23) will allow specific imaging of IBD, because nonspecific bowel uptake is visible on later images.

However, preparation of labeled autologous leukocytes is rather laborious and time-consuming. Furthermore, there is a small but definite risk of personnel contamination or even inadvertent cross-contamination between patients (24). Therefore, there is an urgent need for a sensitive and specific imaging agent that can be prepared relatively easily.

Recently, we introduced ^{99m}Tc -HYNIC-IL-8 as such a new agent for scintigraphy. In a rabbit animal model with *E. coli* infection, ^{99m}Tc -HYNIC-IL-8 allowed rapid visualization of the abscess as early as 1 h after injection with high and rapid accretion of the radiolabel in the abscess.

Our study was designed to test this new ^{99m}Tc -HYNIC-IL-8 agent for its potential to visualize inflammatory lesions in a more clinically relevant animal model and to determine the earliest time point for diagnosis of IBD. Diagnostic imaging was done until 4 h after injection because no further increase of uptake in the affected colon can be expected with ^{99m}Tc -HMPAO-granulocytes (11). The results of this study show that both the ^{99m}Tc -HYNIC-IL-8 and the ^{99m}Tc -HMPAO-granulocytes preparation at 1 h after injection visualized the affected colon with similar uptake in the affected colon. At 2 h after injection, images of ^{99m}Tc -HYNIC-IL-8 were superior. Uptake in the affected colon increased to a level of 4.5-fold higher than with ^{99m}Tc -HMPAO-granulocytes at 4 h after injection. ^{99m}Tc -HYNIC-IL-8 scintigraphically allowed a visual differentiation between mild (grade 1 = inflammation) and severe (grade 2 = ulceration) inflammation within 2 h after injection. In addition, image quality improved even further from 2 to 4 h after injection (Fig. 1). Such a differentiation between mild and severe inflammation was not possible with ^{99m}Tc -HMPAO-granulocytes. Ex vivo, very mild nonspecific uptake in the nonaffected colon was observed with ^{99m}Tc -HMPAO-granulocytes after dissection; this was not seen with ^{99m}Tc -HYNIC-IL-8, apparently because of specific binding. The higher uptake of ^{99m}Tc -HYNIC-IL-8 in the affected colon was mainly due to an increased uptake of ^{99m}Tc -IL-8 in the inflamed colonic wall. This led to a more accurate visual differentiation between inflamed colon and noninflamed colon for ^{99m}Tc -HYNIC-IL-8 compared with ^{99m}Tc -HMPAO-granulocytes. Furthermore, the excellent performance of ^{99m}Tc -HYNIC-IL-8 was illustrated by its low uptake in the cell wall of the nonaffected colon and the low uptake in the stool of the affected colon. Apparently, this seems to be an important reason for the dramatically better performance of ^{99m}Tc -HYNIC-IL-8 compared with ^{99m}Tc -HMPAO-granulocytes in scintigraphic imaging of chemically induced colitis.

With ^{99m}Tc -HMPAO-granulocytes, the CI was the same at 2 and 4 h after injection, facilitating adequate delineation of inflamed tissue at 4 h after injection. With ^{99m}Tc -HYNIC-IL-8 the absolute uptake from 2 to 4 h after injection strongly increased in the affected colon and the CI index

showed a > 5-fold higher value over ^{99m}Tc -HMPAO-granulocytes, almost allowing a point-by-point comparison between whole-body images and macroscopical observations. In addition, compared with labeled granulocytes, labeled HYNIC-IL-8 has the important advantage of an easier preparation without the need for blood manipulation.

The moderate performance of ^{99m}Tc -HMPAO-granulocytes (23) compared with ^{99m}Tc -HYNIC-IL-8 (8) is remarkable. This could be caused by the longer circulating time and slower background clearance of labeled WBCs or, more probable, additional specific uptake of IL-8 in inflammatory cells. Because quantitative analysis of the scintigrams of ^{99m}Tc -HMPAO-granulocytes showed rapid initial lung transit and low hepatic uptake, there was no indication of deterioration of granulocyte function associated with the labeling procedure.

Previous studies showed that ^{99m}Tc -HYNIC-IL-8 induced a transient neutropenia in rabbits (8,9). We aim to further increase the specific activity of the ^{99m}Tc -HYNIC-IL-8 preparation and to decrease the biological activity of the agent. Until now, a 25-fold reduction of protein dose was achieved when going from ^{123}I to ^{99m}Tc as radiolabel (9).

CONCLUSION

In this rabbit model, the imaging performances of ^{99m}Tc -HYNIC-IL-8 and ^{99m}Tc -HMPAO-WBCs were similar at 1 h after injection in the evaluation of experimental colitis. At 2 h after injection, ^{99m}Tc -HYNIC-IL-8 appeared superior to the ^{99m}Tc -HMPAO-WBCs, providing sufficient diagnostic information for accurate evaluation of the extent and severity of experimental colitis. Because of its high uptake in inflammatory foci in combination with minimal nonspecific bowel uptake, ^{99m}Tc -HYNIC-IL-8 allowed a point-by-point correlation with the macroscopical observation at 4 h after injection associated with specific uptake in the inflammatory foci. These results suggest that ^{99m}Tc -HYNIC-IL-8 is an imaging agent that permits accurate diagnosis of IBD, provided that the problem related to the biologic activity can be circumvented.

ACKNOWLEDGMENTS

The authors thank Gerry Grutters (University of Nijmegen, Central Animal Laboratory) for expert assistance in the animal experience, Emile Koenders (University Hospital Nijmegen, Department of Nuclear Medicine) for his excellent technical assistance, and Peter Mast for his assistance with the hematological measurements. The study was partially supported by the Deutsche Forschungs Gesellschaft.

REFERENCES

1. Signore A, Chianelli M, Annovazzi A, et al. ^{123}I -interleukin-2 scintigraphy for in vivo assessment of intestinal mononuclear cell infiltration in Crohn's disease. *J Nucl Med.* 2000;41:242-249.
2. Murata Y, Ishiguro Y, Itoh J, Munakata A, Yoshida Y. The role of proinflammatory and immunoregulatory cytokines in the pathogenesis of ulcerative colitis. *J Gastroenterol.* 1995;30(suppl)8:56-60.

3. Ina K, Kusugami K, Yamaguchi T, et al. Mucosal interleukin-8 is involved in neutrophil migration and binding to extracellular matrix in inflammatory bowel disease. *Am J Gastroenterol.* 1997;92:1342–1346.
4. Holmes WE, Lee J, Kuang WJ, Rice GC, Wood WI. Structure and functional expression of a human interleukin-8 receptor. *Science.* 1991;253:1278–1280.
5. Murphy PM, Tiffany HL. Cloning of complementary DNA encoding a functional human interleukin-8 receptor. *Science.* 1991;253:1280–1283.
6. Lee J, Horuk R, Rice GC, Bennett GL, Camerato T, Wood WI. Characterization of two high affinity human interleukin-8 receptors. *J Biol Chem.* 1992;267:16283–16287.
7. Cerretti DP, Kozlosky CJ, VandenBos T, Nelson N, Gearing DP, Beckmann MP. Molecular characterization of receptors for human interleukin-8, GRO/melanoma growth-stimulatory activity and neutrophil activating peptide-2. *Mol Immunol.* 1993;30:359–367.
8. van der Laken CJ, Boerman OC, Oyen WJG, van de Ven MTP, van der Meer JWM, Corstens FHM. Radiolabeled interleukin-8: scintigraphic detection of infection within a few hours. *J Nucl Med.* 2000;41:463–469.
9. Rennen HJJM, Boerman OC, Oyen WJG, van der Meer JWM, Corstens FHM. Specific and rapid scintigraphic detection of infection with Tc-99m-labeled interleukin-8. *J Nucl Med.* 2001;42:117–123.
10. Oyen WJ, Boerman OC, Dams ET, et al. Scintigraphic evaluation of experimental colitis in rabbits. *J Nucl Med.* 1997;38:1596–1600.
11. Dams ET, Oyen WJ, Boerman OC, et al. Technetium-99m-labeled liposomes to image experimental colitis in rabbits: comparison with technetium-99m-HMPAO-granulocytes and technetium-99m-HYNIC-IgG. *J Nucl Med.* 1998;39:2172–2178.
12. Allgayer H, Deschryver K, Stenson WF. Treatment with 16,16'-dimethyl prostaglandin E2 before and after induction of colitis with trinitrobenzenesulfonic acid in rats decreases inflammation. *Gastroenterology.* 1989;96:1290–1300.
13. Percy WH, Burton MB, Rose K, Donovan V, Burakoff R. In vitro changes in the properties of rabbit colonic muscularis mucosae in colitis. *Gastroenterology.* 1993;104:369–376.
14. Kim HS, Berstad A. Experimental colitis in animal models. *Scand J Gastroenterol.* 1992;27:529–537.
15. Abrams MJ, Juweid M, tenKate CI, et al. Technetium-99m-human polyclonal IgG radiolabeled via the hydrazino nicotinamide derivative for imaging focal sites of infection in rats. *J Nucl Med.* 1990;31:2022–2028.
16. Lillevang ST, Toft P, Nilsen B. A method for isolating granulocytes from rabbit blood without causing activation. *J Immunol Methods.* 1994;169:137–138.
17. Böyum A, Lövhaug D, Tresland L, Nordlie EM. Separation of leucocytes: improved cell purity by fine adjustments of gradient medium density and osmolality. *Scand J Immunol.* 1991;34:697–712.
18. Behr TM, Becker WS, Sharkey RM, et al. Reduction of renal uptake of monoclonal antibody fragments by amino acid infusion. *J Nucl Med.* 1996;37:829–833.
19. Behr TM, Sharkey RM, Sgouros G, et al. Overcoming the nephrotoxicity of radiometal-labeled immunoconjugates: improved cancer therapy administered to a nude mouse model in relation to the internal radiation dosimetry. *Cancer.* 1997;80(suppl):2591–2610.
20. Mansfield JC, Gjaffer MH, Tindale WB, Holdsworth CD. Quantitative assessment of overall inflammatory bowel disease activity using labelled leucocytes: a direct comparison between indium-111 and technetium-99m HMPAO methods. *Gut.* 1995;37:679–683.
21. Allan RA, Sladen GE, Bassingham S, Lazarus C, Clarke SE, Fogelman I. Comparison of simultaneous ^{99m}Tc-HMPAO and ¹¹¹In oxine labelled white cell scans in the assessment of inflammatory bowel disease. *Eur J Nucl Med.* 1993;20:195–200.
22. Arndt JW, van der Sluys Veer A, Blok D, et al. Prospective comparative study of technetium-99m-WBCs and indium-111-granulocytes for the examination of patients with inflammatory bowel disease. *J Nucl Med.* 1993;34:1052–1057.
23. Lantto EH, Lantto TJ, Vorne M. Fast diagnosis of abdominal infections and inflammations with technetium-99m-HMPAO labeled leukocytes. *J Nucl Med.* 1991;32:2029–2034.
24. Lange JM, Boucher CA, Hollak CE, et al. Failure of zidovudine prophylaxis after accidental exposure to HIV-1. *N Engl J Med.* 1990;322:1375–1377.

