

Use of ^{201}Tl SPECT for Evaluation of Biologic Behavior in Pituitary Adenomas

Takahiro Nakano, Kenichiroh Asano, Masahiko Tanaka, Toshio Takahashi, Hiroyuki Miura, and Shigeharu Suzuki

Departments of Neurosurgery and Radiology, Hirosaki University School of Medicine, Hirosaki, Japan

Although pituitary adenomas are regarded as benign tumors, some of them behave aggressively with malignant behavior of invasion and metastasis. Prediction of such biologic behavior in a tumor is important for therapeutic planning. The purpose of this study was to assess the usefulness of ^{201}Tl chloride SPECT (^{201}Tl SPECT) for evaluation of biologic behavior in pituitary adenomas. **Methods:** ^{201}Tl SPECT was performed on 22 patients with pituitary adenomas. ^{201}Tl uptake indices were calculated, and the results were compared between invasive pituitary adenomas and noninvasive pituitary adenomas. Correlation of the ^{201}Tl uptake index and the MIB1 monoclonal antibody labeling index (MIB1 labeling index) of the tumors was also estimated. **Results:** In comparison with noninvasive pituitary adenomas, invasive pituitary adenomas exhibited significantly higher ^{201}Tl uptake indices on both the early and the delayed images ($P = 0.0010$ and 0.0019 , respectively). A significant correlation was found between the ^{201}Tl uptake index on the delayed image and the MIB1 labeling index ($P = 0.0107$). **Conclusion:** ^{201}Tl SPECT can be useful for detecting biologic aggressiveness in pituitary adenomas.

Key Words: pituitary adenoma; ^{201}Tl SPECT; invasion; MIB1 monoclonal antibody

J Nucl Med 2001; 42:575–578

Although pituitary adenomas are generally regarded as benign tumors, some of them behave aggressively and manifest malignant behavior such as invasion or metastasis. Prediction of biologic behavior is important for therapeutic planning of the tumor. ^{201}Tl chloride SPECT (^{201}Tl SPECT) has been reported to be useful for detecting tumor viability in malignant tumors (1–7). However, to our knowledge, there have been no reports of ^{201}Tl SPECT of pituitary adenomas. In this study, ^{201}Tl SPECT was performed on 22 patients with pituitary adenomas and ^{201}Tl uptake indices were calculated to determine whether it is possible to predict the biologic behavior of pituitary adenomas. We also investigated the correlation between the ^{201}Tl index and the presence of cavernous sinus invasion by tumor and exam-

ined the MIB1 monoclonal antibody labeling index (MIB1 labeling index) as a marker of proliferative activity in the tumor (8–11).

MATERIALS AND METHODS

We studied 22 of 28 patients with pituitary adenomas who were surgically treated in our hospital between January 1997 and June 1999. ^{201}Tl SPECT was performed preoperatively on all 22 patients (11 men, 11 women; age range, 18–65 y; mean age, 45 y). ^{201}Tl SPECT was not performed on the other 6 patients, who were excluded from the study. All patients had early SPECT imaging 15 min after intravenous injection of 148 MBq ^{201}Tl and delayed SPECT imaging 4 h after injection. All images were obtained with a continuous rotation of $4^\circ/60$ s, with a total of 120° per detector by means of a three-detector system with fanbeam collimators (Multispect 3; Siemens, Erlangen, Germany). We used 15% and 20% symmetric windows at 166 and 70 keV, respectively. A 128×128 matrix with a Butterworth filter was used for correction, and images were reconstructed on the transverse plane with a ramp filter. A transverse line was made that passed over the tumor on the axial image, and counts on the line were plotted. The ^{201}Tl uptake index was then obtained by dividing the maximum count on the curve by the mean value of the nontumor area (Fig. 1).

Cavernous sinus invasion by tumor was defined on the basis of MRI findings. Those tumors with a grade higher than 2 by the classification of Knosp et al. (12) were defined as invasive.

Tumor tissues were fixed in neutral buffered formalin and embedded in paraffin. Four-micrometer-thick sections were mounted onto glass slides and dried. After deparaffinization and rehydration, endogenous peroxidase activity was blocked. Slide-mounted sections were incubated in 0.01 mmol/L sodium citrate buffer (pH 6.0) and then microwaved for 20 min at 500 W. Sections were incubated overnight at 4°C in MIB1 (1:100 dilution; DAKO, Santa Barbara, CA). Sections were then incubated with biotin-conjugated secondary antibody, followed by peroxidase-conjugated streptavidin. Antigen-antibody complexes were detected with 3,3'-diaminobenzidine/ H_2O_2 . Slides were counterstained with hematoxylin, dehydrated, cleared, and mounted. In each case, $>1,000$ tumor cells were counted by light microscopy, and the MIB1 labeling index was expressed as a percentage.

All statistical analyses were performed with StatView, version 5.0, computer software (SAS Institute, Inc., Cary, NC). Differences in the ^{201}Tl uptake index between the invasive tumor group and the noninvasive tumor group were evaluated by the Mann-Whitney U test.

Received Apr. 20, 2000; revision accepted Nov. 10, 2000.

For correspondence or reprints contact: Takahiro Nakano, MD, Department of Neurosurgery, Hirosaki University School of Medicine, Zaifucho 5, Hirosaki, 036-8562, Japan.

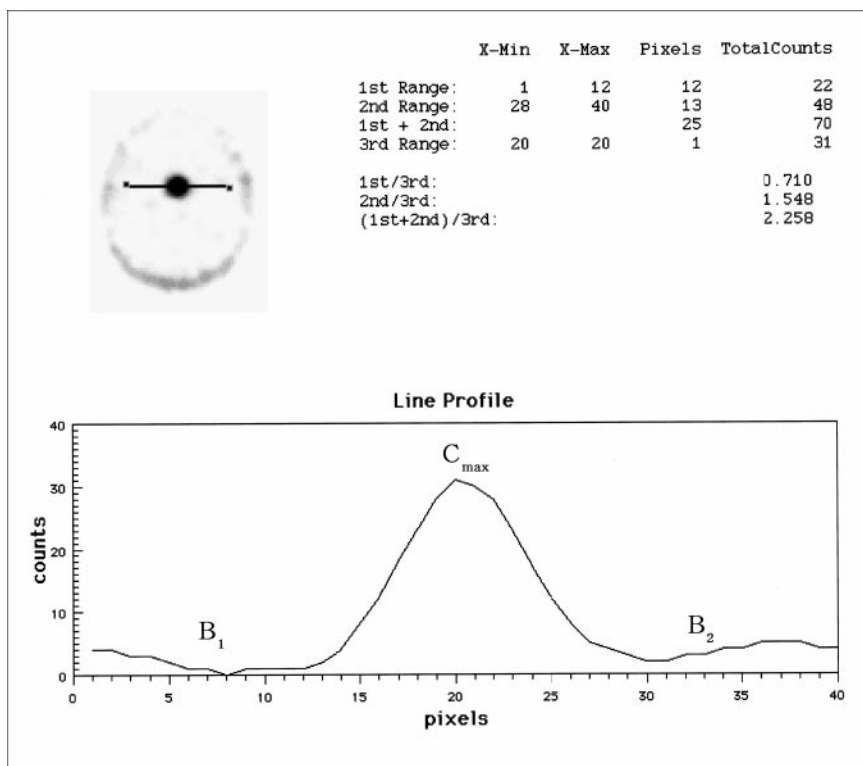


FIGURE 1. Calculation of ^{201}Tl uptake index. Transverse line was made that passed over tumor, and counts on line were plotted as curve. Maximum count (C_{max}) of tumor part was divided by mean count of nontumor area (B_1 and B_2).

RESULTS

Among the 22 cases of pituitary adenoma, 12 were invasive tumors and 10 were noninvasive tumors. Significant differences in the ^{201}Tl uptake indices were found between the invasive tumor group and the noninvasive tumor group, including both the early images (TI^{e} index) (mean \pm SE, 11.40 ± 2.49 and 4.26 ± 0.41 , respectively) and the delayed images (TI^{d} index) (6.69 ± 0.71 and 3.76 ± 0.37 , respectively) (Fig. 2). Threshold values were defined as 5.0 on the TI^{e} index and 4.5 on the TI^{d} index. Among the 12 invasive tumors, 11 were >5.0 on the TI^{e} index and 10 were >4.5 on the TI^{d} index (sensitivity, 92% and 83%, respectively). Conversely, among the 10 noninvasive tumors, only 3 were >5.0 on the TI^{e} index and 1 was >4.5 on the TI^{d} index (specificity, 70% and 90%, respectively).

Three prolactinomas and five growth hormone-producing adenomas were included in this study. However, no correlation was found between the ^{201}Tl index and the functional type of pituitary adenomas. No significant difference was found between the invasive tumor group and the noninvasive tumor group on the MIB1 labeling index (Table 1).

The TI^{d} index correlated significantly with the MIB1 labeling index ($P = 0.0107$) (Fig. 3). This finding means that the delayed image indicates proliferative activity of the tumors. A representative case is presented in Figure 4.

DISCUSSION

Despite being regarded as benign tumors, pituitary adenomas frequently invade surrounding structures or rapidly

regrow after the first operation. In therapeutic planning it is very important to predict such aggressive behavior, especially in cases of nonsymptomatic tumor found incidentally. In this study, we investigated whether the invasiveness and proliferative activity of pituitary adenomas can be predicted with ^{201}Tl SPECT. Significant differences were found between the invasive tumor group and the noninvasive tumor group in the TI^{e} index and the TI^{d} index. Moreover, the MIB1 labeling index, which is a marker of tumor proliferative activity, correlated significantly with the TI^{d} index.

Early ^{201}Tl concentration in tumors is related to tumor vascularity and destruction of the blood-brain barrier (2). However, histologically, pituitary tissue does not have a blood-brain barrier, so even normal pituitary tissue exhibits twice the counts on ^{201}Tl SPECT compared with surrounding normal brain structures. Therefore, in pituitary adenomas, early ^{201}Tl concentration in the tumors is related primarily to tumor vascularity. When ^{201}Tl is not taken into cells, it is washed out by blood flow. But when ^{201}Tl is taken into tumor cells by active transport with Na^+, K^+ adenosine triphosphatase (ATPase), it is retained in the tumor cells. Thus, retention of ^{201}Tl by the tumor is related to the activity of Na^+, K^+ -ATPase in tumor cells (6). Therefore, the TI^{d} index on the delayed image indicates viability of the tumor. In this study, tumor invasion was related to both the early image and the delayed image, but the MIB1 labeling index was related only to the delayed image. The explanation for these findings is that tumor invasion is related to both tumor vascularity and the proliferative activity of tumor cells

(11,13), but the MIB1 labeling index is related only to the proliferative activity of tumor cells (8,10). Consequently, we can detect two different characteristics of tumors by studying the early and the delayed images of ^{201}Tl SPECT.

Knowing the biologic characteristics of a tumor preoperatively can be significantly beneficial for therapeutic decision making; hence, many studies on the biologic behavior of pituitary adenomas have been reported (1,2,8,10,14–16). However, because most of these studies used tumor tissue specimens such as MIB1 indices, they could not be used before surgery as an index for deciding whether tumors should be removed surgically.

Although ^{201}Tl SPECT has been reported to be useful for detecting tumor viability or tumor recurrence in malignant glioma (1,3–5,17), to our knowledge, no such study has been

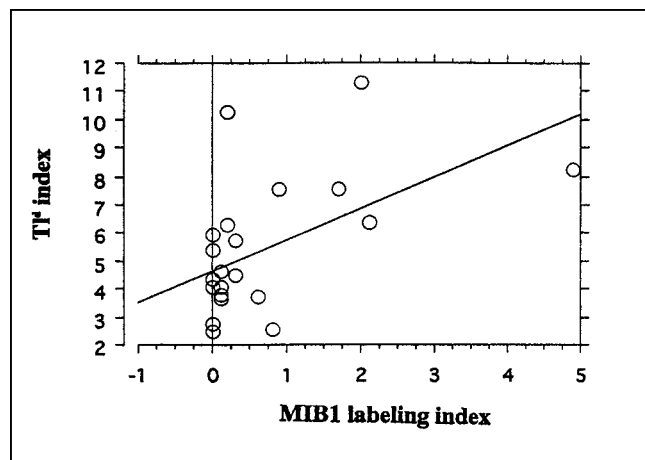


FIGURE 3. Tl^d index correlated significantly with MIB1 labeling index ($P = 0.0107$). Pearson's $r = 0.527$.

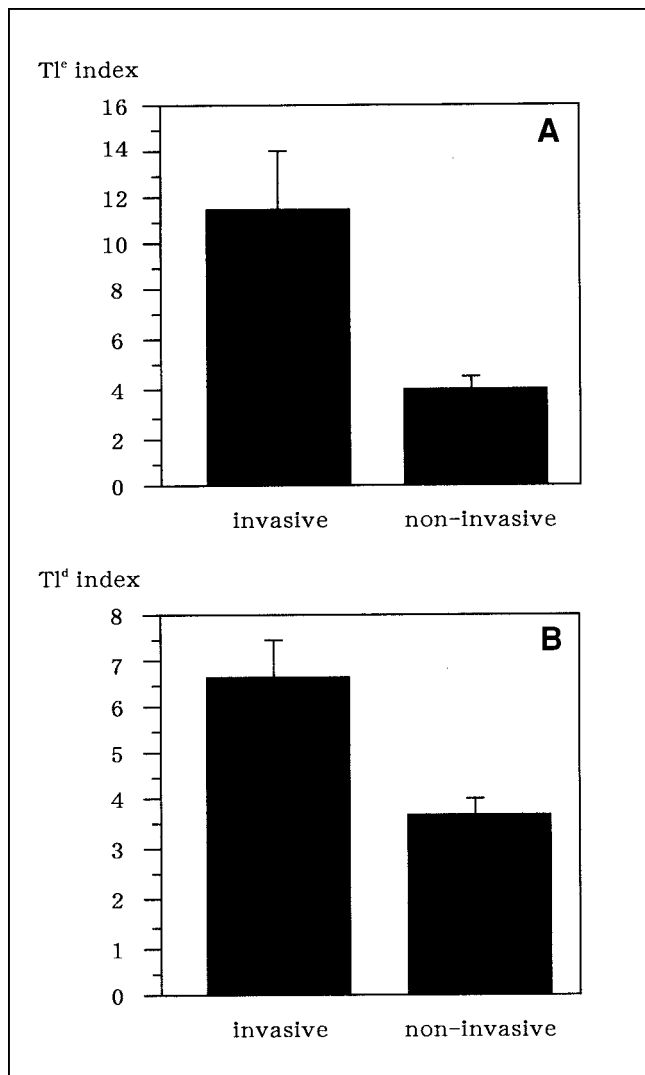


FIGURE 2. (A) Tl^e index was significantly greater in invasive tumor group (mean \pm SE, 11.40 ± 2.49) than in noninvasive tumor group (4.26 ± 0.41) ($P = 0.0010$). (B) Tl^d index was also significantly greater in invasive tumor group (mean \pm SE, 6.69 ± 0.71) than in noninvasive tumor group (3.76 ± 0.37) ($P = 0.0019$).

reported concerning pituitary adenoma. ^{201}Tl SPECT has not been used to evaluate pituitary adenomas because ^{201}Tl is taken up only by viable tumor cells; therefore, it has not been regarded as a useful study for benign tumors. However, in this study we performed ^{201}Tl SPECT on patients with pituitary adenoma, calculated ^{201}Tl uptake indices, and found that it is possible to predict the biologic behavior of these tumors. Therefore, ^{201}Tl SPECT may be helpful to guide therapy and surgical decision making, especially for patients in whom pituitary adenoma is found incidentally.

CONCLUSION

^{201}Tl SPECT makes prediction of the biologic behavior of pituitary adenomas potentially possible. Its clinical use may be helpful to guide therapeutic planning, especially in the case of incidentally discovered pituitary adenomas.

REFERENCES

- Black KL, Hawkins RA, Kim KT, Becker DP, Lerner C, Marciano D. Use of thallium-201 SPECT to quantitate malignancy grade of gliomas. *J Neurosurg.* 1989;71:342–346.
- Igase K, Oka Y, Ohta S, Murakami Y, Kumon Y, Sasaki S. Usefulness of thallium-201 single photon emission computed tomography to quantify the malignancy grade of brain tumors. *Neurol Med Chir (Tokyo).* 1996;36:434–439.
- Ishibashi M, Taguchi A, Sugita Y, et al. Thallium-201 in brain tumors: relationship between tumor cell activity in astrocytic tumor and proliferating cell nuclear antigen. *J Nucl Med.* 1995;36:2201–2207.
- Kahn D, Follett KA, Bushnell DL, et al. Diagnosis of recurrent brain tumor: value of ^{201}Tl SPECT vs ^{18}F -fluorodeoxyglucose PET. *AJR.* 1994;163:1459–1466.
- Kosuda S, Fujii H, Aoki S, et al. Reassessment of quantitative thallium-201 brain SPECT for miscellaneous brain tumors. *Ann Nucl Med.* 1993;7:257–263.
- Lorberboym M, Baram J, Feibel M, Hercbergs A, Lieberman L. A prospective evaluation of thallium-201 single photon emission computerized tomography for brain tumor burden. *Int J Radiat Oncol Biol Phys.* 1995;32:249–254.
- Rubinstein R, Karger H, Pietrzyk U, Siegal T, Gomori JM, Chisin R. Use of ^{201}Tl thallium brain SPECT, image registration, and semi-quantitative analysis in the follow-up of brain tumors. *Eur J Radiol.* 1996;21:188–195.
- Cattoretti G, Becker MHG, Key G, et al. Monoclonal antibodies against recombinant parts of the Ki-67 antigen (MIB1 and MIB3) detect proliferating cells in microwave-processed formalin-fixed paraffin sections. *J Pathol.* 1992;168:357–363.
- Kawamoto H, Uozumi T, Kawamoto K, Arita K, Yano T, Hirohata T. Analysis of the growth rate and cavernous sinus invasion of pituitary adenomas. *Acta Neurochir (Wien).* 1995;136:37–43.

TABLE 1
 Tl Uptake Indices and MIB1 Labeling Indices in Pituitary Adenomas

Patient	Age (y)	Sex	Size (mm)	Invasion	Tl ^e index	Tl ^d index	MIB1	Function
1	65	M	12 × 18 × 12	—	4.78	3.73	0.61	NF
2	48	F	27 × 22 × 22	—	.40	2.46	0.00	NF
3	18	F	20 × 17 × 23	—	2.70	4.39	0.00	PRL
4	54	F	27 × 20 × 18	—	5.20	4.11	0.00	NF
5	41	M	26 × 22 × 22	—	6.33	2.52	0.00	NF
6	55	F	10 × 7 × 10	—	3.50	3.78	0.10	GH
7	64	F	13 × 11 × 10	—	3.62	4.07	0.10	NF
8	47	F	5 × 5 × 10	—	4.00	2.54	0.80	GH
9	20	M	11 × 9 × 9	—	2.86	3.67	0.10	GH
10	24	M	12 × 10 × 11	—	6.18	6.36	2.10	GH
11	51	M	32 × 28 × 23	+	9.60	5.43	0.00	NF
12	43	M	25 × 20 × 20	+	8.70	5.96	0.00	NF
13	65	F	28 × 17 × 17	+	7.21	7.56	0.90	PRL
14	49	F	24 × 24 × 28	+	7.20	4.62	0.10	NF
15	30	M	40 × 49 × 42	+	37.00	6.33	0.20	NF
16	47	F	40 × 28 × 28	+	3.48	4.48	0.30	NF
17	38	M	47 × 36 × 50	+	11.75	8.24	4.90	PRL
18	36	M	25 × 20 × 13	+	11.47	5.74	0.30	NF
19	37	F	11 × 20 × 27	+	5.05	2.76	0.00	NF
20	40	M	26 × 38 × 39	+	9.34	7.56	1.70	NF
21	62	F	27 × 20 × 27	+	14.00	11.29	2.00	NF
22	61	M	20 × 20 × 25	+	12.04	10.28	0.20	GH

NF = nonfunctioning; PRL = prolactin; GH = growth hormone.

- Mizoue T, Kawamoto H, Arita K, Kurisu K, Tominaga A, Uozumi T. MIB1 immunopositivity is associated with rapid regrowth of pituitary adenomas. *Acta Neurochir (Wien)*. 1997;139:426–432.
- Thaper K, Kovacs K, Scheithauer BW, et al. Proliferative activity and invasiveness among pituitary adenomas and carcinomas: an analysis using the MIB-1 antibody. *Neurosurgery*. 1996;38:99–107.
- Knosp E, Steiner E, Kitz K, Matula C. Pituitary adenomas with invasion of the cavernous sinus space: a magnetic resonance imaging classification compared with surgical findings. *Neurosurgery*. 1993;3:610–618.
- Knosp E, Kitz K, Perneczky A. Proliferation activity in pituitary adenomas: measurement by monoclonal antibody Ki-67. *Neurosurgery*. 1989;25:927–930.
- Asano K, Kubo O, Tajika Y, Huang MC, Takakura K. The relationship between cell proliferation activity and secretory activity in pituitary adenoma: review of 63 cases [in Japanese]. *No To Shinkei*. 1996;48:543–549.
- Hsu DW, Hakim F, Biller BMK, et al. Significance of proliferating cell nuclear antigen index in predicting pituitary adenoma recurrence. *J Neurosurg*. 1993;78:753–761.
- Scheithauer BW, Kovacs KT, Laws ER, Randall RV. Pathology of invasive pituitary tumors with special reference to functional classification. *J Neurosurg*. 1986;65:733–744.
- Alexander E III, Loeffler JS, Schwartz RB, et al. Thallium-201 technetium-99m HMPAO single-photon emission computed tomography (SPECT) imaging for guiding stereotactic craniotomies in heavily irradiated malignant glioma patients. *Acta Neurochir (Wien)*. 1993;122:215–217.

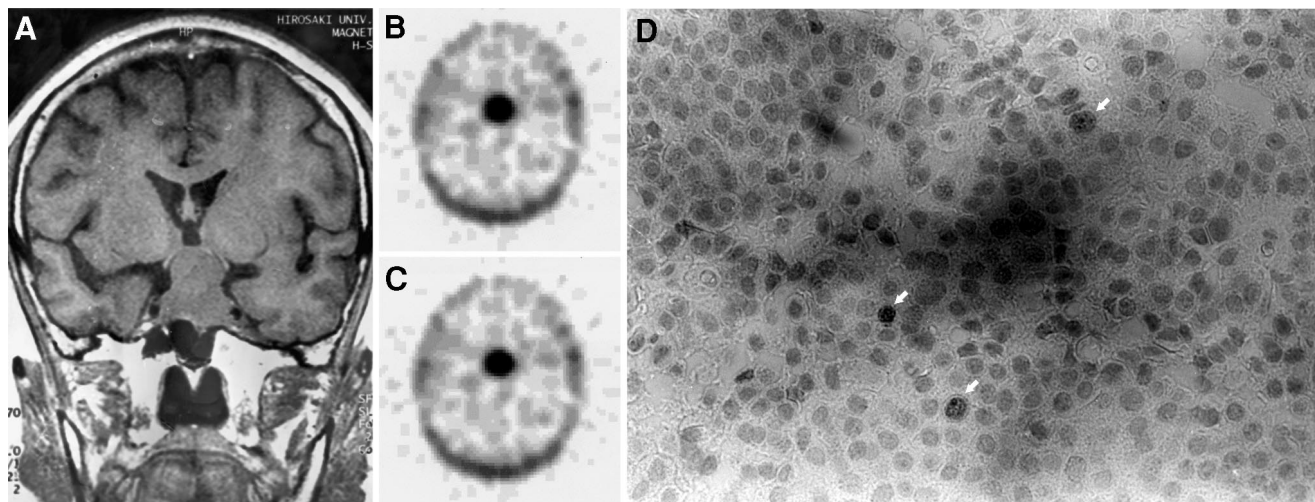


FIGURE 4. Patient 21. (A) MR coronal T1-weighted image shows macroadenoma that extended bilateral cavernous sinuses. (B) ²⁰¹Tl SPECT early image shows marked concentration of ²⁰¹Tl in tumor. (C) On ²⁰¹Tl SPECT delayed image, ²⁰¹Tl was retained in tumor. (D) Light-microscopic section (×400). MIB1 immunostaining shows relatively high percentage of MIB1-positive cells (arrows).