
Serum Thyroglobulin Concentrations and ^{131}I Whole-Body Scan Results in Patients with Differentiated Thyroid Carcinoma After Administration of Recombinant Human Thyroid-Stimulating Hormone

Alessia David, Annabella Blotta, Marta Bondanelli, Roberta Rossi, Elio Roti, Lewis E. Braverman, Luciano Busutti, and Ettore C. degli Uberti

Section of Endocrinology, Department of Biomedical Sciences and Advanced Therapies, University of Ferrara, Ferrara; Radiotherapy Department, Malpighi Hospital, Bologna; Institute of Endocrinology, University of Milan, Milan, Italy; and Section of Endocrinology, Diabetes and Nutrition, Boston University, Boston, Massachusetts

The use of recombinant human thyroid-stimulating hormone (rhTSH) has recently become available as an alternative diagnostic tool to assess the persistence and recurrence of differentiated thyroid carcinoma (DTC) in patients on thyroid hormone-suppressive therapy (THST) after near-total or total thyroidectomy and ablative doses of ^{131}I . We report the results of rhTSH administration in patients who were monitored for DTC. **Methods:** Thirty-three adult DTC patients (13 men, 20 women; mean age \pm SE, 45.6 ± 2.31 y; age range, 21–65 y) underwent diagnostic follow-up after rhTSH administration at a dose of 0.9 mg once a day for 2 d. Whole-body scanning and serum thyroglobulin (Tg) measurement were performed after rhTSH administration. Patients were divided into 2 groups depending on serum Tg concentrations on THST: 29 patients had Tg concentrations of <2 ng/mL (group A) and 4 patients had Tg values of >2 ng/mL (group B). **Results:** In group A, Tg values remained at <2 ng/mL in 25 patients and increased from 1.1 ± 0.14 ng/mL to 22.0 ± 5.75 ng/mL (mean \pm SE) in 4 patients after rhTSH administration. Whole-body scanning did not reveal any uptake of ^{131}I in the 25 patients without an increase in Tg, whereas ^{131}I uptake was evident in 2 of the 4 patients with a rise in Tg. In group B, Tg values increased in all 4 patients from 17.3 ± 6.35 ng/mL to 55.3 ± 12.75 ng/mL, and ^{131}I uptake was evident in 3 of the 4 patients. No major adverse effects were reported after rhTSH administration. **Conclusion:** Our results show that the measurement of serum Tg concentrations after rhTSH has a higher diagnostic value than whole-body scanning in detecting the persistence of thyroid tissue. Therefore, rhTSH should be administered in TSH-suppressed patients with basal serum Tg concentrations of <2 ng/mL because the increment in serum Tg concentrations may reveal the persistence of thyroid tissue in these patients.

Key Words: recombinant human thyroid-stimulating hormone; differentiated thyroid carcinoma; thyroglobulin

J Nucl Med 2001; 42:1470–1475

Although adequate treatment of differentiated thyroid carcinoma (DTC) by means of total thyroidectomy followed by radioiodine ablation generally leads to its cure, long-term follow-up is necessary in all patients, especially those at high risk, for the presence of residual thyroid bed tissue or recurrent or metastatic thyroid cancer. Whole-body scanning and serum thyroglobulin (Tg) measurements after discontinuation of thyroid hormone-suppressive therapy (THST) are the most sensitive methods in the follow-up of such patients (1–4). Withdrawal of THST is required to increase endogenous thyroid-stimulating hormone (TSH) to stimulate adequate ^{131}I uptake from the thyroid bed or metastatic tissue and to stimulate Tg release (5–10). However, this procedure is associated with a negative impact on the quality of life because of the appearance of symptoms of hypothyroidism (11). Moreover, L-thyroxine withdrawal for a long period of time might increase the risk of cancer growth (12).

The availability of recombinant human TSH (rhTSH) has provided a new tool in the diagnostic management of DTC (13–16). Recent studies have shown the ability of rhTSH to promote radioiodine uptake on diagnostic scans and raise serum Tg concentrations (17,18) with a diagnostic accuracy comparable with that of THST withdrawal (19,20), avoiding the morbidity of hypothyroidism.

This report describes the results obtained after rhTSH administration in patients monitored for DTC who had been treated previously with total or near-total thyroidectomy and

Received Dec. 12, 2001; revision accepted May 29, 2001.

For correspondence or reprints contact: Ettore C. degli Uberti, MD, Section of Endocrinology, Department of Biomedical Sciences and Advanced Therapies, University of Ferrara, via Savonarola, 9, 44100 Ferrara, Italy.

a high ablative dose (3.7 kBq [100 mCi]) of ¹³¹I. We evaluated whether Tg measurement after rhTSH can be a sensitive marker for the presence of thyroid remnants or metastatic disease when used alone or in combination with whole-body scanning.

MATERIALS AND METHODS

Patients

Thirty-three adult DTC patients (13 men, 20 women; mean age ± SE, 45.6 ± 2.31 y; age range, 21–65 y) underwent diagnostic follow-up after rhTSH administration. All patients had been treated previously with total or near-total thyroidectomy, with

lymph node dissection in 20 cases, and treated with a high ablative dose (3.7 kBq [100 mCi]) of ¹³¹I. Twenty-one patients (63.6%) had papillary carcinoma, 8 (24.2%) had a follicular variant of papillary carcinoma, 3 (9.1%) had an insular variant of papillary carcinoma, and 1 (3%) had follicular carcinoma. All subjects were on THST in doses sufficient to suppress serum TSH concentrations to <0.1 mIU/L. All subjects underwent diagnostic or posttherapy ¹³¹I whole-body scanning 6–24 mo before this rhTSH study.

Patients were divided into 2 groups depending on serum Tg concentrations on THST: Group A includes 29 patients with Tg concentrations of <2 ng/mL; group B includes 4 patients with Tg values of >2 ng/mL. This cutoff value for Tg results was chosen because a Tg value of 2 ng/mL has been suggested as the threshold

TABLE 1
Tumor Characteristics, Serum Tg Concentrations, and ¹³¹I WBS in 33 DTC Patients Before Study

Group*	Patient no.	Histology	TNM classification†	¹³¹ I dose‡ (kBq)	¹³¹ I WBS uptake	Baseline Tg on THST§
A	1	P/i	T4N0M0	3.7 (100)	T [¶]	0.9
	2	P	T3N0M0	3.7 (100)	T [¶]	<0.9
	3	P	T4N1M1	3.7 (100)	M, L [¶]	1.5
	4	P	T4N1M0	3.7 (100)	T [¶]	1.2
	5	P	T4N0M0	3.7 (100)	T [¶]	<0.9
	6	P/f	T4N1M1	3.7 (100)	L [¶]	<0.9
	7	P/i	T2N0M1	3.7 (100)	T, L [¶]	<0.9
	8	P	T4N0M0	3.7 (100)	T [¶]	<0.9
	9	P/f	T2N0M0	0.18 (5)	T [¶]	<0.9
	10	P	T1N0M0	0.18 (5)	0 [¶]	<0.9
	11	P	T1N0M0	0.18 (5)	0 [¶]	<0.9
	12	P	T2N0M0	0.18 (5)	0 [¶]	<0.9
	13	P	T3N0M0	0.18 (5)	0 [¶]	<0.9
	14	P	T1N0M0	0.18 (5)	0 [¶]	<0.9
	15	P	T1N0M0	0.18 (5)	0 [¶]	<0.9
	16	P	T1N0M0	0.18 (5)	T [¶]	<0.9
	17	P	T1N0M0	0.18 (5)	T [¶]	<0.9
	18	P	T4N1M0	0.18 (5)	0 [¶]	<0.9
	19	P	T2N0M0	0.18 (5)	0 [¶]	<0.9
	20	P	T3N0M0	0.18 (5)	T [¶]	<0.9
	21	P	T2N0M0	0.18 (5)	0 [¶]	<0.9
	22	P	T3N1M0	0.18 (5)	0 [¶]	<0.9
	23	P	T2N1M0	0.18 (5)	T [¶]	<0.9
	24	P	T1N0M0	0.18 (5)	0 [¶]	<0.9
	25	P/i	T3N0M0	0.18 (5)	0 [¶]	<0.9
	26	P	T2N0M0	0.18 (5)	0 [¶]	<0.9
	27	P	T2N0M0	0.18 (5)	0 [¶]	<0.9
	28	P/f	T2N0M0	0.18 (5)	0 [¶]	<0.9
	29	P	T1N0M0	0.18 (5)	T [¶]	<0.9
B	30	P	T4N1M1	7.4 (200)	T, L [¶]	17
	31	P	T4N1M1	7.4 (200)	T, M, L [¶]	12
	32	P/f	T2N1M1	7.4 (200)	L [¶]	5.3
	33	F	T4N0M1	7.4 (200)	B [¶]	35

*Group A = patients with Tg of <2 ng/mL on THST; group B = patients with Tg of >2 ng/mL on THST.

†TNM classification from (28).

‡¹³¹I (kBq; mCi in parentheses) administered 72–96 h before WBS.

§Serum Tg concentrations measured 6–24 mo after diagnostic or therapeutic ¹³¹I WBS.

¶Posttherapy WBS performed 6–12 mo before study.

‖Diagnostic WBS performed 6–24 mo before study.

¹³¹I WBS = whole-body scanning; P/i = insular variant of papillary carcinoma; T = thyroid bed uptake; P = papillary carcinoma; M = mediastinal uptake; L = lung uptake; P/f = follicular variant of papillary carcinoma; 0 = no uptake; F = follicular carcinoma; B = bone uptake.

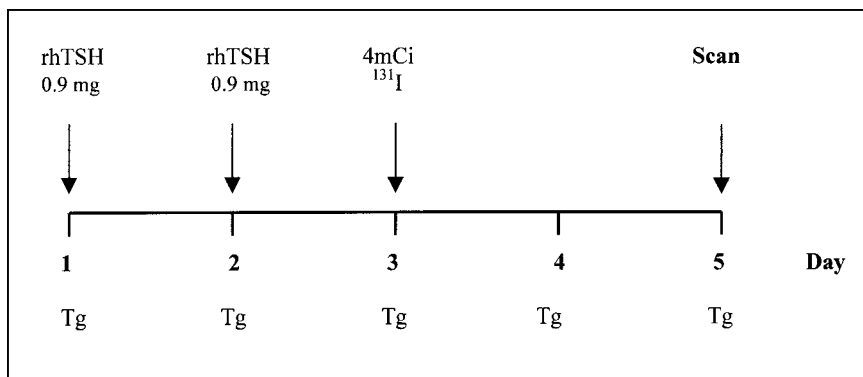


FIGURE 1. Protocol for rhTSH administration and radioiodine scanning procedure for patients on THST (148 MBq [4 mCi] ¹³¹I were administered).

level indicative of persistence of DTC (20). The characteristics of the patients are reported in Table 1.

No patients had evidence of other medical disorders, were pregnant, or were on medications known to affect thyroid function or interfere with hormone measurements. None of the subjects received radiographic contrast agents that could interfere with the ¹³¹I uptake by a thyroid remnant or metastatic tissue. A low-iodine diet was recommended before whole-body scanning. None of the patients discontinued THST. All patients gave written informed consent to participate in the study, which was approved by the respective local ethical committees.

Study Design

All patients were hospitalized from Monday to Friday and received intramuscular rhTSH (Thyrogen; Genzyme Corp., Cambridge, MA) at a dose of 0.9 mg once a day for 2 d. Twenty-four hours after the last dose of rhTSH, 148 MBq (4 mCi) ¹³¹I were administered.

Whole-body scanning was then performed with a double-head gamma camera fitted with a high-energy collimator, and uptake was measured 48 h after ¹³¹I had been administered (Fig. 1). Scanning was performed at a constant low speed with acquisition at a minimum of 30 min or of at least 140,000 counts. Single spot images of body regions were acquired after scanning a minimum of 10–15 min or after obtaining 60,000 counts for a large-field-of-view camera or 35,000 counts for a small-field-of-view camera. The extent of disease was defined on the basis of the presence of ¹³¹I uptake in the thyroid bed or abnormal activity elsewhere in the neck, lungs, mediastinum, bone, or other sites. All previous ¹³¹I diagnostic scans, posttherapy scans, and those obtained after rhTSH stimulation were evaluated by 2 independent observers.

Serum Measurements

Blood samples for measurements of TSH, free thyroxine (FT₄), free triiodothyronine (FT₃), Tg, and Tg antibodies were obtained in the morning before the first rhTSH administration and 24, 48, 72, and 96 h later. Serum Tg, TSH, FT₄, FT₃, and Tg antibodies were measured using the automated chemiluminescence system. All samples were processed in duplicate in the same assay. The Tg assay (Immulite; Diagnostic Products Corp., Los Angeles, CA) had a detection limit of 0.2 ng/mL and a functional sensitivity of 0.9 ng/mL, with intra- and interassay coefficients of variation of 5.3% and 7%, respectively. The TSH assay (ACS Centaur; Chiron Diagnostics Corp., East Walpole, MA) had an analytic sensitivity of 0.010 mIU/L, with intra- and interassay coefficients of variation of 2.41% and 3.17%, respectively. The FT₃ assay (ACS Centaur; Chiron Diagnostics) had an analytic sensitivity of 0.46 pmol/L,

with intra- and interassay coefficients of variation of 3.40% and 6.76%, respectively. The FT₄ assay (ACS Centaur; Chiron Diagnostics) had an analytic sensitivity of 1.29 pmol/L, with intra- and interassay coefficients of variation of 4.69% and 4.59%, respectively. All samples collected from an individual patient were tested in a single assay. The basal serum specimens of all patients were also screened for the presence of Tg antibodies with the automated chemiluminescence system (Immulite; Diagnostic Products Corp.). The sensitivity was 2.0 IU/mL, and the intra- and interassay coefficients of variation were 4.2% and 8.7%, respectively.

Statistical Analysis

Results are reported as mean ± SE. ANOVA for repeated measures was used to compare the results of TSH, FT₃, and FT₄ during the protocol period. If values were significantly different ($P < 0.05$), a Student paired or unpaired test was also used.

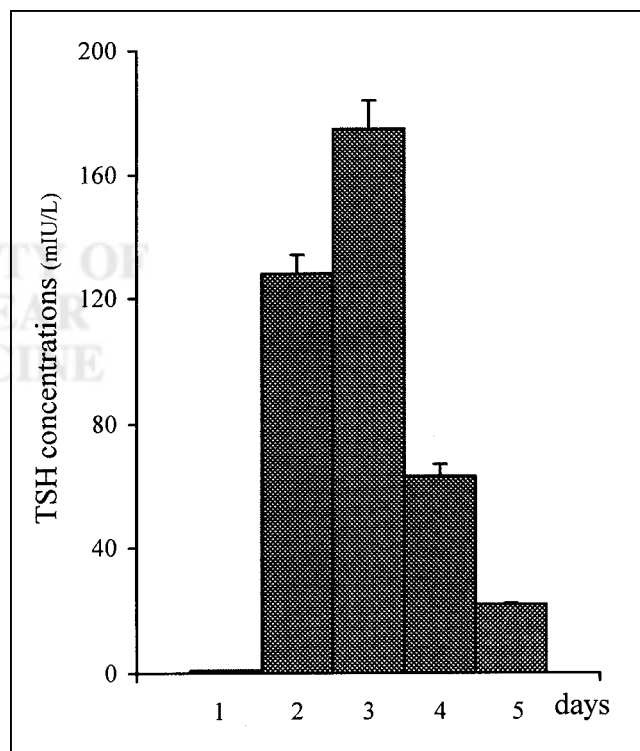


FIGURE 2. Serum TSH concentrations (mean ± SE) at baseline and after rhTSH injections during 5 d of study.

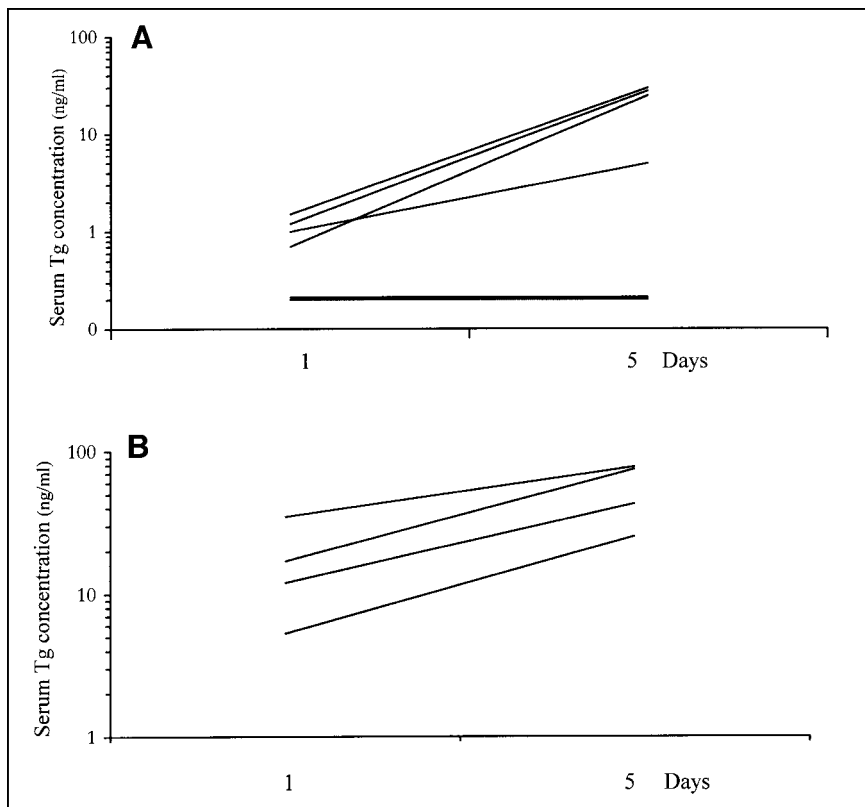


FIGURE 3. Serum Tg levels at baseline and after rhTSH administration in 29 patients of group A (A) and in 4 patients of group B (B).

RESULTS

All subjects tolerated rhTSH well. Three patients complained of nausea, which was mild and short-lived, and 1 patient experienced a transient headache.

Serum TSH concentrations before and after rhTSH administration in patients on THST are presented in Figure 2. Serum TSH concentrations increased from 0.03 ± 0.001 mIU/L on day 1 to 128 ± 6.90 mIU/L and 175 ± 9.05 mIU/L, 24 h after the first and the second rhTSH injections, respectively. Peak serum TSH concentrations after rhTSH

administration were significantly higher ($P < 0.001$) than that measured (78.9 ± 3.39 mIU/L) on the day of ^{131}I administration after L-thyroxine withdrawal on prior occasions.

No significant changes in serum FT_3 and FT_4 concentrations were observed before and after rhTSH administration. No patients had circulating Tg antibodies.

Baseline serum Tg concentrations were < 2 ng/mL in 29 patients (group A) and > 2 ng/mL in 4 patients (group B). In group A, serum Tg concentrations remained < 2 ng/mL in

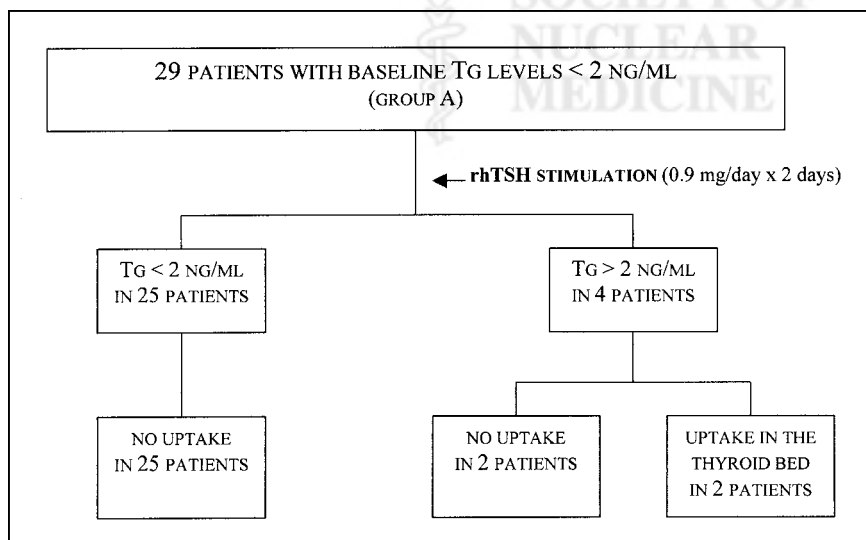


FIGURE 4. Results of whole-body scanning and Tg measurements after rhTSH administration in 29 patients with baseline Tg levels of < 2 ng/mL (group A) on THST.

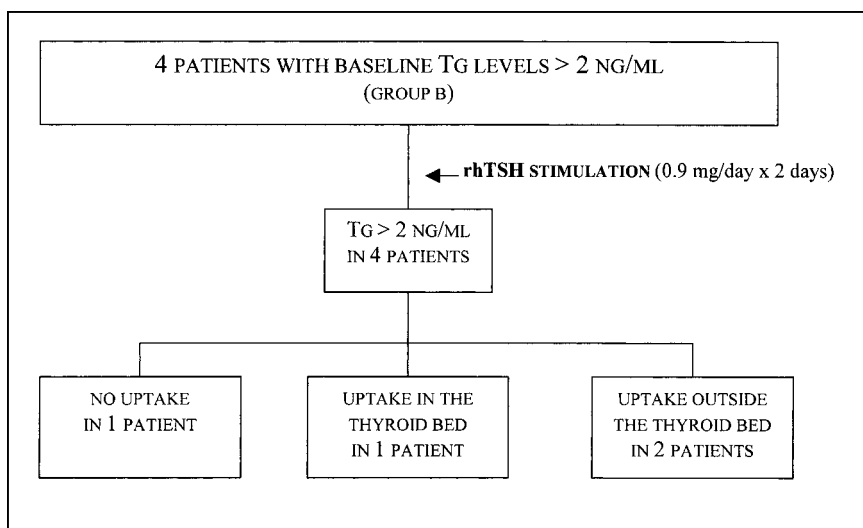


FIGURE 5. Results of whole-body scanning and Tg measurements after rhTSH administration in 4 patients with baseline Tg levels of >2 ng/mL (group B) on THST.

25 patients and increased after rhTSH stimulation in 4 patients from 1.1 ± 0.14 ng/mL (range, 0.9–1.5 ng/mL) to 22.0 ± 5.75 ng/mL (range, 5–30 ng/mL) (Fig. 3A). Whole-body scanning obtained after rhTSH showed no uptake in the patients who did not have a rise in the serum Tg value after rhTSH, whereas uptake of ^{131}I was observed in 2 of the 4 patients who had a rise in serum Tg concentrations of >2 ng/mL after rhTSH administration (Fig. 4).

In group B, rhTSH administration induced a marked rise in serum Tg concentrations in all patients from 17.3 ± 6.35 ng/mL (range, 5.3–35.0 ng/mL) to 55.3 ± 12.75 ng/mL (range, 25.3–78.0 ng/mL) (Fig. 3B). Whole-body scanning obtained after rhTSH administration showed ^{131}I uptake in 3 of these 4 patients: in the thyroid bed in 1 patient and outside the thyroid bed in bone or lung in 2 patients (Fig. 5).

Seven of the 8 patients with a rise in serum Tg concentrations after rhTSH (group A, 3 patients; group B, 4 patients) were treated with therapeutic doses of ^{131}I after L-thyroxine withdrawal. In these 7 patients, posttherapy ^{131}I whole-body scanning revealed uptake in or outside the thyroid bed. In particular, the 2 patients with increased serum Tg concentrations and negative whole-body scans after rhTSH showed ^{131}I lung uptake after receiving therapeutic dose of ^{131}I .

DISCUSSION

We report the results of rhTSH administration in 33 DTC patients on THST, who were treated previously by near-total thyroidectomy and radioiodine therapy, to detect the persistence or recurrence (or both) of thyroid disease. The patients given rhTSH preserved a good quality of life, avoiding the physical discomfort, the metabolic alterations, and the mood disorders occurring after THST withdrawal. Moreover, patients did not have any serious adverse reactions to the administration of rhTSH. Only mild nausea and headache were observed in 9% of the cases, similar to findings of other studies (18,19).

Several clinical trials using rhTSH have shown that its administration is an effective means to stimulate serum Tg secretion and ^{131}I uptake by thyroid tissue in THST patients monitored for DTC (18–23). Our study shows that the administration of rhTSH to 25 patients did not reveal any increment of serum Tg concentration or ^{131}I uptake, thus indicating an excellent concordance between Tg and whole-body scan findings. Furthermore, this study shows that, even in THST patients with Tg values of <2 ng/mL, the cutoff value reported for persistence of bed uptake or DTC (20,21), rhTSH administration stimulated Tg secretion, suggesting the presence of thyroid tissue remnants or metastatic thyroid cancer in 4 other patients (13.8%). This finding is in agreement with the findings of other studies (18,20). In a large multicenter study, the increment of serum Tg concentrations above the cutoff value of 2 ng/mL after rhTSH administration increased the detection rate of thyroid tissue from 22% to 52% in patients with ^{131}I uptake limited to the thyroid bed and from 80% to 100% in patients with metastatic disease (19).

In addition, our study indicates that ^{131}I whole-body scanning performed after rhTSH administration does not provide information that improves the detection rate of DTC. In fact, in 4 patients in group A, with serum Tg concentrations of <2 ng/mL on THST, a 20-fold increase in serum Tg concentrations was observed after rhTSH administration, whereas only 2 patients had whole-body scans that revealed ^{131}I uptake in the thyroid bed. In the 4 patients in group B with elevated baseline serum Tg concentrations, rhTSH administration induced a marked rise in serum Tg values. In these patients, with Tg values suggesting the presence of metastatic disease or local recurrence, whole-body scanning performed after rhTSH stimulation revealed ^{131}I uptake in only 3 of the 4 patients: in the thyroid bed in 1 patient and outside the thyroid bed in 2 patients.

The presence of ^{131}I uptake on the posttherapy whole-body scans of the patients with a rise in serum Tg concentration and negative whole-body scans after rhTSH confirms that the measurement of serum Tg after rhTSH can have a higher diagnostic value than whole-body scanning in detecting the presence of thyroid tissue.

Our results are in agreement with the findings of other studies indicating that discordant results between ^{131}I scans and Tg measurements after rhTSH administration may be seen in patients with metastatic thyroid cancer (20,24). Furthermore, a rise in serum Tg values after rhTSH administration indicates that the thyroid cells are sensitive to TSH stimulation. The failure to detect any abnormal ^{131}I uptake after rhTSH administration could be attributed to the 2-fold higher clearance of ^{131}I when patients are euthyroid compared with hypothyroid patients (25,26) or to a short-time exposure of thyroid tissue to TSH stimulation. At present, serum Tg testing after rhTSH stimulation has not been reported to give false-positive results (20,27).

CONCLUSION

Our findings indicate that in DTC patients on THST, Tg measurements should be performed after rhTSH administration and may have a higher diagnostic value in comparison with whole-body scans for the selection of subjects with persistent normal or neoplastic thyroid tissue. However, Tg testing cannot be used as a precise method for the detection of DTC when anti-Tg antibodies are present or the thyroid tissue is unable to secrete Tg in response to TSH.

ACKNOWLEDGMENTS

The authors thank Genzyme Corporation for providing the rhTSH. This work was supported by grants from the Italian Ministry of University and Scientific and Technological Research (project 9906153187-004, 40% in 1999 and 60% in 2000).

REFERENCES

- Schlumberger MJ. Papillary and follicular thyroid carcinoma. *N Engl J Med*. 1998;338:297–306.
- Mazzaferri EL, Jhiang SM. Long-term impact of initial surgical and medical therapy on papillary and follicular thyroid cancer. *Am J Med*. 1994;97:418–428.
- Tubiana M, Schlumberger M, Rougier P, et al. Long-term results and prognostic factors in patients with differentiated thyroid carcinoma. *Cancer*. 1985;55:794–804.
- Maxon HR III, Smith HS. Radioiodine-131 in the diagnosis and treatment of metastatic well differentiated thyroid cancer. *Endocrinol Metab Clin North Am*. 1990;19:685–718.
- Ozata M, Suzuki S, Miyamoto T, Liu RT, Fierro-Renoy F, DeGroot LJ. Serum thyroglobulin in the follow-up of patients with treated differentiated thyroid cancer. *J Clin Endocrinol Metab*. 1994;79:98–105.
- Schlumberger M, Baudin E. Serum thyroglobulin determination in the follow-up of patients with differentiated thyroid carcinoma. *Eur J Endocrinol*. 1998;138:249–252.
- Pacini F, Lari R, Mazzeo S, Grasso L, Taddei D, Pinchera A. Diagnostic value of a single serum thyroglobulin determination on and off thyroid suppressive therapy in the follow-up of patients with differentiated thyroid cancer. *Clin Endocrinol (Oxf)*. 1985;23:405–411.
- Guimaraes V, DeGroot LJ. Moderate hypothyroidism in preparation for whole body ^{131}I scintiscans and thyroglobulin testing. *Thyroid*. 1996;6:69–73.
- Pacini F, Pinchera A, Giani C, Grasso L, Baschieri L. Serum thyroglobulin concentrations and ^{131}I whole body scans in the diagnosis of metastases from differentiated thyroid carcinoma (after thyroidectomy). *Clin Endocrinol (Oxf)*. 1980;13:107–110.
- Spencer CA, LoPresti JS, Fatemi S, Nicoloff JT. Detection of residual and recurrent differentiated thyroid carcinoma by serum thyroglobulin measurement. *Thyroid*. 1999;9:435–441.
- Hassey Dow K, Ferrell BR, Anello C. Quality-of-life changes in patients with thyroid cancer after withdrawal of thyroid hormone therapy. *Thyroid*. 1997;7:613–619.
- Kaplan M. Progress in thyroid cancer. *Endocrinol Metab Clin North Am*. 1990;19:469–478.
- Law A, Jack GW, Tellez M, Edmonds CJ. In-vivo studies of a human thyrotropin preparation. *J Endocrinol*. 1986;110:375–378.
- Wondisford FE, Radovick S, Moates JM, Usala SJ, Weintraub BD. Isolation and characterization of the human thyrotropin beta-subunit gene: differences in gene structure and promoter function from murine species. *J Biol Chem*. 1988;263:12538–12542.
- Weintraub BD, Szkudlinski MW. Development and in vitro characterization of human recombinant thyrotropin. *Thyroid*. 1999;9:447–450.
- Braverman LE, Pratt BM, Ebner S, Longcope C. Recombinant human thyrotropin stimulates thyroid function and radioactive iodine uptake in the rhesus monkey. *J Clin Endocrinol Metab*. 1992;74:1135–1139.
- Meier CA, Braverman LE, Ebner SA, et al. Diagnostic use of recombinant human thyrotropin in patients with thyroid carcinoma (phase I/II study). *J Clin Endocrinol Metab*. 1994;78:188–196.
- Ladenson PW, Braverman LE, Mazzaferri EL, et al. Comparison of administration of recombinant human thyrotropin with withdrawal of thyroid hormone for radioactive iodine scanning in patients with thyroid carcinoma. *N Engl J Med*. 1997;377:888–896.
- Haugen BR, Pacini F, Reiners C, et al. A comparison of recombinant human thyrotropin and thyroid hormone withdrawal for the detection of thyroid remnant or cancer. *J Clin Endocrinol Metab*. 1999;84:3877–3885.
- Ladenson PW. Strategies for thyrotropin use to monitor patients with treated thyroid carcinoma. *Thyroid*. 1999;9:429–433.
- Mazzaferri EL, Kloos RT. Using recombinant human TSH in the management of well differentiated thyroid cancer: current strategies and future directions. *Thyroid*. 2000;10:767–778.
- Schlumberger M, Ricard M, Pacini F. Clinical use of recombinant human TSH in thyroid cancer patients. *Eur J Endocrinol*. 2000;143:557–563.
- Mariani G, Ferdeghini M, Augeri C, et al. Clinical experience with recombinant human thyrotropin (rhTSH) in the management of patients with differentiated thyroid cancer. *Cancer Biother Radiopharm*. 2000;15:211–217.
- Schlumberger M, Incerti C, Pacini F, Reiners C. The role of recombinant thyroid-stimulating hormone (rhTSH) in the detection and management of well differentiated thyroid carcinoma: a roundtable discussion. *J Endocrinol Invest*. 1999;22:35–41.
- Montenegro J, Gonzalez O, Saracho R, Aguirre R, Gonzales O, Martinez I. Changes in renal function in primary hypothyroidism. *Am J Kidney Dis*. 1996;27:195–198.
- Ramirez L, Braverman LE, White B, Emerson CH. Recombinant human thyrotropin is a potent stimulator of thyroid function in normal subjects. *J Clin Endocrinol Metab*. 1997;82:2836–2839.
- Pacini F, Lippi F. Clinical experience with recombinant human thyroid-stimulating hormone (rhTSH): serum thyroglobulin measurement. *J Endocrinol Invest*. 1999;22:25–29.
- American Joint Committee on Cancer. *Manual for Staging of Cancer: Thyroid Gland*. 4th ed. Philadelphia, PA: JB Lippincott; 1992:53–56.