

---

# Cerebellar Vasoreactivity in Stroke Patients with Crossed Cerebellar Diaschisis Assessed by Acetazolamide and $^{99m}\text{Tc}$ -HMPAO SPECT

Sang Eun Kim and Myung Chul Lee

Department of Nuclear Medicine, Samsung Medical Center, Sungkyunkwan University School of Medicine, Seoul; and Department of Nuclear Medicine, Seoul National University College of Medicine, Seoul, Korea

---

Crossed cerebellar diaschisis (CCD) tends to persist or even worsen after supratentorial infarction. Several studies have shown impairment of cerebral vasomotor responsiveness in the hemispheric area of diaschisis in patients with hemispheric infarction. This finding has led to the concern that the lack of CCD reversibility might be associated with chronic circulatory abnormalities. We therefore assessed the vasoreactivity in the cerebellar hemisphere in which diaschisis is manifested using acetazolamide (ACZ) and SPECT. **Methods:** Eight stroke patients with CCD (5 with unilateral hemispheric infarcts and 3 with unilateral intracerebral hemorrhage) had  $^{99m}\text{Tc}$ -HMPAO SPECT scanning at rest and 20 min after intravenous injection of 1.0 g ACZ. The time interval after stroke ranged from 25 to 904 d. From the total counts obtained from each cerebellar hemisphere, the asymmetry index (AI) was calculated as (unaffected - affected cerebellar hemisphere)/unaffected cerebellar hemisphere  $\times$  100. **Results:** After ACZ, the mean AI ( $8.7 \pm 6.6$ ) was significantly decreased ( $P < 0.05$ ) compared with that at rest ( $17.7 \pm 5.8$ ). Seven of the 8 patients showed decrease in the AI after ACZ. In 1 patient, the direction of the asymmetry was reversed after ACZ so that the AI was negative. The ACZ-induced change in the AI did not show a significant correlation with the time interval after stroke, whether calculated in absolute terms or as a percentage change. **Conclusion:** This study shows that normal vascular supply is maintained in the CCD-affected cerebellar hemisphere over long periods of time after a stroke. Thus, the lack of CCD reversibility may not be attributed to a chronic circulatory insufficiency. The results lend support to the concept of functional deactivation and subsequent transneuronal degeneration as a likely explanation for CCD. It is unclear whether decreased AI after ACZ indicates a higher vascular response of the affected cerebellar hemisphere than that of the normal side.

**Key Words:** crossed cerebellar diaschisis; cerebellar vasoreactivity; acetazolamide;  $^{99m}\text{Tc}$ -HMPAO; SPECT

**J Nucl Med 2000; 41:416-420.**

---

**A** coupled depression of blood flow and metabolism in the otherwise normal contralateral cerebellar hemisphere is frequently found in patients with supratentorial lesions

(1-7). This phenomenon, termed "crossed cerebellar diaschisis" (CCD), has been interpreted as a functional deactivation, presumably caused by interruption of the corticopontocerebellar pathway at the supratentorial level (1,3,4,6). However, in contrast with the theoretic interpretation of CCD as a diaschisis are examples in which CCD persists or even worsens after infarction (2,3,5,6,8-10). In addition, CCD may develop in association with slowly growing supratentorial tumors (4,11), indicating that acute brain injury is not essential for its development. Thus, 2 essential criteria for a diaschisis—namely, sudden onset and reversibility—are often lacking in CCD.

A likely explanation for the lack of CCD reversibility may be transneuronal degeneration. Crossed cerebellar atrophy was described initially as developing in the immature brain, but there are examples of its occurrence after adult-onset vascular lesions develop (12). Trans-synaptic degeneration of the corticopontocerebellar system, rather than retrograde degeneration through the dentatohalamocortical pathway, may be involved in its pathophysiology (6,12).

However, several studies have shown that autoregulation and chemical control (i.e., cerebrovascular reactivity to  $\text{PaCO}_2$  changes) of the cerebral circulation may be impaired in the contralateral or ipsilateral hemispheric area of diaschisis in patients with hemispheric infarction (13-17). This led to the concern that the lack of CCD reversibility might be associated with chronic circulatory abnormalities. To examine this question we investigated whether vasoreactivity is preserved, and hence blood flow adequately maintained, in the cerebellar hemisphere in which diaschisis is manifested.

Intravenous administration of acetazolamide (ACZ) induces dilatation of the cerebral microvasculature and an associated increase in cerebral blood flow (18,19). In patients with impaired cerebrovascular hemodynamic reserve, the response to ACZ in the affected perfusion territories is attenuated or abolished (19,20). We assumed that intact and unchanging vasoreactivity, over long periods of time after a stroke, in the cerebellar hemisphere in which diaschisis is manifested excludes circulatory insufficiency as a likely explanation for the lack of recovery of CCD, lending support to the concept of functional deactivation and subse-

---

Received Feb. 5, 1999; revision accepted Jul. 21, 1999.

For correspondence or reprints contact: Sang Eun Kim, MD, Department of Nuclear Medicine, Samsung Medical Center, Sungkyunkwan University School of Medicine, 50 Ilwon-dong, Kangnam-ku, Seoul 135-710, Korea.

quent transneuronal degeneration. We therefore assessed the cerebellar vasoreactivity in stroke patients with CCD presenting at various time intervals after ictus using ACZ and SPECT.

## MATERIALS AND METHODS

### Patients

The population in this study consisted of 8 stroke patients (5 men, 3 women) with CCD: 5 patients with unilateral hemispheric infarcts in the internal carotid artery territory and 3 patients with unilateral intracerebral hemorrhage. The age of the patients ranged from 12 to 78 y (mean age,  $53.8 \pm 21.2$  y). The presence of CCD was defined according to a normal range of cerebellar perfusion asymmetry determined previously using the same SPECT methods as those used in this study (10). None of the patients in this study had clinical symptoms and MRI findings suggesting ischemic episodes in the vertebrobasilar territory, gross morphologic alterations in the cerebellum on routine MRI, or a second symptomatic neurologic event since the initial event. The time interval between the onset of the symptom(s) resulting from the ictal event and the SPECT study ranged from 25 to 904 d. Characteristics of the individual patients are given in Table 1.

### SPECT Imaging

Brain SPECT studies were performed at rest and after intravenous injection of ACZ on separate days using  $^{99m}\text{Tc}$ -hexamethyl propyleneamine oxime (HMPAO). The ACZ studies were performed within 2 d after the baseline study. For the ACZ studies,  $^{99m}\text{Tc}$ -HMPAO was administered 20 min after injection of 1.0 g ACZ dissolved in 10 mL distilled water.

SPECT imaging was performed 10–60 min after intravenous administration of  $\sim 740$  MBq (20 mCi)  $^{99m}\text{Tc}$ -HMPAO. Using a rotating  $\gamma$  camera interfaced to a dedicated computer system and a low-energy, high-resolution collimator during a  $360^\circ$  rotation, 60 frames of images with a  $64 \times 64$  matrix were acquired within 30 min. Total counts of 3.6–4 million were collected for each study. The transaxial slices were reconstructed by filtered backprojection using a Butterworth filter. Each reconstructed slice was corrected for tissue absorption using Chang's method (attenuation coefficient  $\mu = 0.12/\text{cm}$ ) (21). An average of 20 SPECT image planes, 0.625-cm thick, was required to image the entire brain. The cerebellum was typically seen in 5 transaxial slices. The SPECT pixel size was 0.625 cm in all 3 dimensions. Before analysis, all images were resliced parallel to the orbitomeatal plane.

### Image Analysis

Three consecutive SPECT image slices representing the cerebellum were added to construct a 1.875-cm-thick slice. The outline of the unaffected cerebellar hemisphere (ipsilateral to the supratentorial lesion) was determined by visual inspection, and a region of interest (ROI) was drawn manually. A symmetric ROI was automatically placed over the CCD-affected cerebellar hemisphere (contralateral to the supratentorial lesion). From the total counts obtained from each cerebellar hemisphere, the asymmetry index (AI) was calculated using the following equation:  $\text{AI} = (\text{unaffected} - \text{affected cerebellar hemisphere}) / \text{unaffected cerebellar hemisphere} \times 100$ .

### Statistical Methods

Data are expressed as mean  $\pm$  SD. Differences between paired data were analyzed by a Wilcoxon's signed rank test. Pairwise correlation, using Spearman's rank correlation coefficients, was used to examine the correlation between the time interval after the

**TABLE 1**  
Patient Data

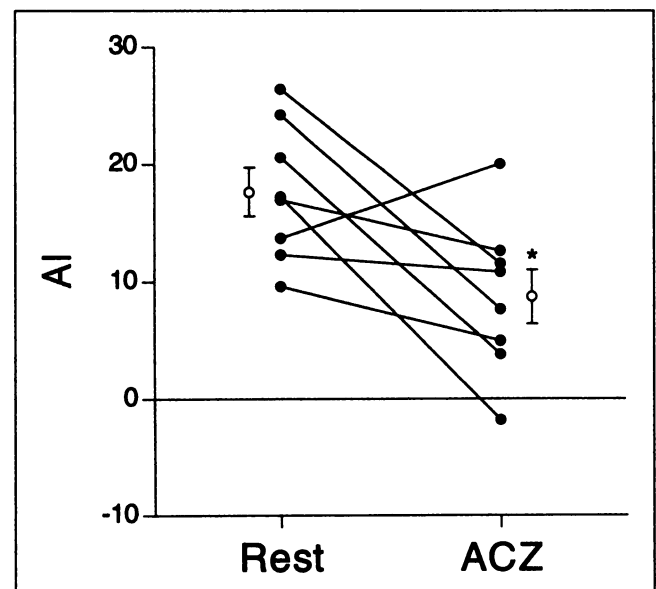
Patient no.	Sex	Age (y)	Days after infarction	Brain lesion	AI	
					At rest	After ACZ
1	M	54	817	Infarction, L frontoparietal white matter and basal ganglia	17.3	-1.8
2	F	64	904	Infarction, L ACA territory	26.4	11.6
3	M	73	554	Infarction, L temporoparietal lobe	9.6	4.9
4	M	62	350	Infarction, L periventricular white matter	12.3	10.9
5	M	38	726	Infarction, L MCA territory	13.7	20.1
6	F	12	74	ICH, R fronto-temporal lobe	20.6	3.8
7	F	78	25	ICH, L thalamus	24.3	7.7
8	M	49	29	ICH, L basal ganglia and frontoparietal lobe	17.0	12.7

ACA = anterior cerebral artery; MCA = middle cerebral artery; ICH = intracerebral hemorrhage.

stroke and the ACZ-induced change in the AI. A probability value of less than 0.05 was considered significant.

## RESULTS

The AI values at rest and after ACZ are shown in Table 1, and the individual responses are plotted in Figure 1. After



**FIGURE 1.** Scatter plots show change in AI after ACZ administration versus at rest (●). ○ = mean  $\pm$  SEM. Asterisk indicates  $P < 0.05$  versus at rest.

administration of ACZ, the mean AI ( $8.7 \pm 6.6$ ) was significantly decreased ( $P < 0.05$ ) compared with that at rest ( $17.7 \pm 5.8$ ). Seven of the 8 patients showed a reduction in the AI after ACZ administration (Fig. 2A). In 1 patient, the direction of the asymmetry was reversed after ACZ administration (i.e., higher radioactivity in the affected cerebellar hemisphere than in the unaffected side), so that the AI was negative (Fig. 2B).

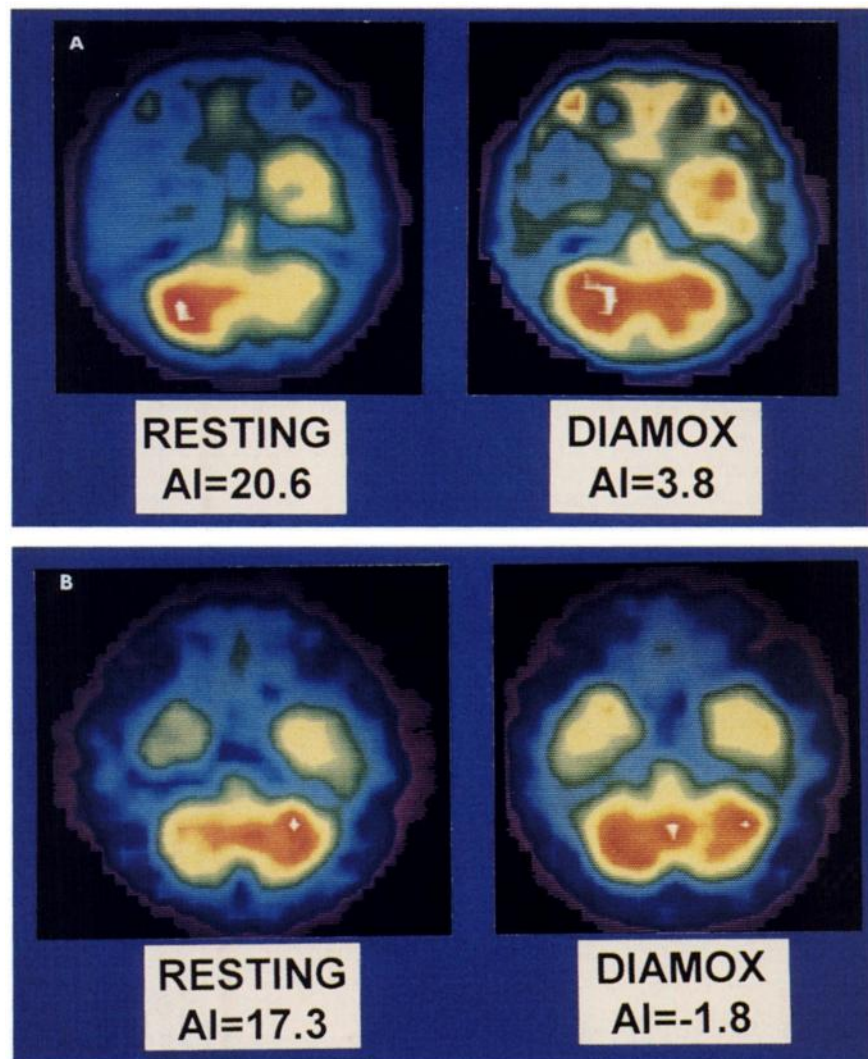
The ACZ-induced change in the AI did not show a significant correlation with the time interval after stroke, whether calculated in absolute terms (the difference between the AI values at rest and after ACZ) ( $\rho = 0.024$ , not significant) or as a percentage change (the difference divided by the AI at rest  $\times 100$ ) ( $\rho = 0.024$ , not significant) (Fig. 3).

## DISCUSSION

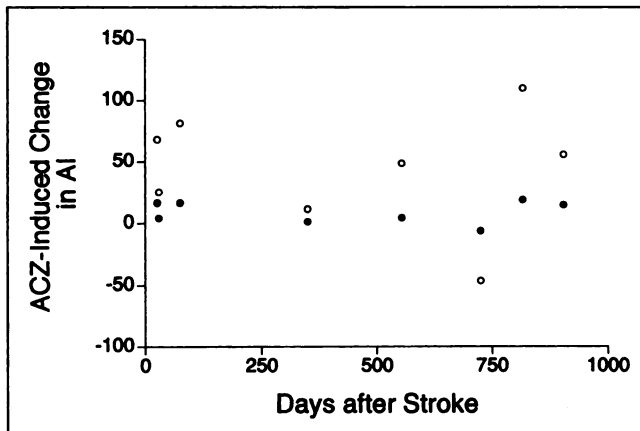
Our patients were studied 25–904 d after their strokes, supporting the view that CCD may be persistent. In this study, we showed that vasoreactivity to ACZ in the CCD-

affected cerebellar hemisphere was preserved up to years after stroke. In addition, there was no significant correlation between the cerebellar vasoreactivity and the time interval after a stroke. These results indicate that normal vascular supply is maintained in the affected cerebellar hemisphere over long periods of time after a stroke and, thus, the lack of CCD reversibility may not be attributed to chronic circulatory insufficiency. This leads us to favor the concept of functional deactivation and subsequent transneuronal degeneration as a likely explanation for CCD. Because dendritic alterations as early as 2–3 d after deafferentation have been described (22,23), CCD seen within hours of a stroke (5) might be an early manifestation of evolving transneuronal degeneration (6). As the latter develops slowly, the hypometabolism would persist or even worsen. Also, despite a lack of macroscopic atrophy identifiable on CT or MRI scans, CCD seen years after a stroke could then represent degeneration of the cerebellar granule cells (6).

The lack of recovery of CCD and its apparent progression



**FIGURE 2.** SPECT images at rest and after ACZ (Diamox; Lederle Laboratories, Wayne, NJ) administration in patient 6 (A) and patient 1 (B).



**FIGURE 3.** Plots of time after stroke versus ACZ-induced change in AI calculated in absolute terms (●) or as percentage change (○).

to degeneration contrast sharply with inter- or intrahemispheric diaschisis (24–26). Nevertheless, recovery of CCD has been reported in a few stroke patients (1,4–6,27), suggesting that this process is not necessarily inescapable. Although the mechanisms for recovery are unclear, they may represent a link between reversible diaschisis and irreversible degeneration (6).

The AI values decreased after ACZ administration compared with those at rest. Two possibilities explain this finding. The first possibility reflects a higher vasoreactivity in the affected cerebellar hemisphere than in the normal contralateral side. Takano et al. (17) studied the vascular response to CO<sub>2</sub> in the ipsilateral sensorimotor cortex with diaschisis in patients during the subacute or chronic stage after a small capsular infarct. The vascular response to hypercapnia was higher in the area of diaschisis than in normal brain, whereas the hypocapnic response was lower in the area of diaschisis than in normal brain. Because, in the area of diaschisis, an excessive resting arteriolar vasoconstriction may result from decreased tissue elaboration of CO<sub>2</sub> associated with local hypometabolism, more vasodilatory reserve can be allowed during vasodilatory stimuli than in the area without diaschisis. However, it is unclear whether this hypothesis is equally effective for CCD. The second possibility involves the pattern and magnitude of blood flow reactivity to ACZ. ACZ causes approximately the same increase in blood flow in healthy subjects regardless of the baseline value or the vascular region (18). Indeed, Bogsrud et al. (28) found that the ACZ-induced absolute cerebellar blood flow increase did not differ between CCD-affected and normal cerebellar hemispheres. Furthermore, Leinsinger et al. (29) reported a negative correlation between ACZ-induced increase of blood flow and baseline blood flow in healthy subjects. Considering these reports, it should not be surprising that after ACZ administration the AI values decreased compared with those at rest.

In this study, 1 patient, unlike the other 7 patients, had an increased AI after ACZ administration. We do not know what distinguished this patient from the rest of the patients

studied. Several factors, such as individual variation in the response to ACZ, metabolic status of the CCD-affected cerebellar hemisphere, or hemodynamic stability in the vertebrobasilar territory, might be involved in this phenomenon.

## CONCLUSION

This study shows that normal vascular supply is maintained in the CCD-affected cerebellar hemisphere over long periods of time after a stroke. Thus, the lack of CCD reversibility may not be attributed to chronic circulatory insufficiency. These findings lend support to the concept of functional deactivation and subsequent transneuronal degeneration as a likely explanation for CCD.

## ACKNOWLEDGMENT

This work was supported in part by Samsung Biomedical Research Institute grant C-98-001.

## REFERENCES

1. Baron JC, Boussier MG, Comar D, Castaigne P. "Crossed cerebellar diaschisis" in human supratentorial brain infarction. *Trans Am Neurol Assoc.* 1980;105:459–461.
2. Lenzi GL, Frackowiak RSJ, Jones T. Cerebral oxygen metabolism and blood flow in human cerebral ischemic infarction. *J Cereb Blood Flow Metab.* 1982;2:321–335.
3. Martin WRW, Raichle ME. Cerebellar blood flow and metabolism in cerebral hemisphere infarction. *Ann Neurol.* 1983;14:168–176.
4. Kushner M, Alavi A, Reivich M, Dann R, Burke A, Robinson G. Contralateral cerebellar hypometabolism following cerebral insult: a positron emission tomographic study. *Ann Neurol.* 1984;15:425–434.
5. Meneghetti G, Vorstrup S, Mickey B, Lindewald H, Lassen NA. Crossed cerebellar diaschisis in ischemic stroke: a study of regional cerebral blood flow by <sup>133</sup>Xe inhalation and single photon emission computerized tomography. *J Cereb Blood Flow Metab.* 1984;4:235–240.
6. Pantano P, Baron JC, Samson Y, Boussier MG, Derouesne C, Comar D. Crossed cerebellar diaschisis: further studies. *Brain.* 1986;109:677–694.
7. Pantano P, Lenzi GL, Guidetti B, et al. Crossed cerebellar diaschisis in patients with cerebral ischemia assessed by SPECT and <sup>123</sup>I-HIPDM. *Eur Neurol.* 1987;27:142–148.
8. Kanaya H, Endo H, Sugiyama T, Kuroda K. "Crossed cerebellar diaschisis" in patients with putaminal hemorrhage [abstract]. *J Cereb Blood Flow Metab.* 1983;3(suppl 1):27–28.
9. Biersack HJ, Hartmann A, Friedrich G, et al. Cause of crossed cerebellar diaschisis in cerebrovascular disease [in German]. *Nuklearmedizin.* 1984;23:227–230.
10. Kim SE, Choi CW, Yoon B-W, et al. Crossed-cerebellar diaschisis in cerebral infarction: technetium-99m HMPAO SPECT and MRI. *J Nucl Med.* 1997;38:14–19.
11. Patronas NJ, Di Chiro G, Smith BH, et al. Depressed cerebellar glucose metabolism in supratentorial tumors. *Brain Res.* 1984;291:93–101.
12. Baudrimont M, Gray F, Meininger V, Escourolle R, Castaigne P. Crossed cerebellar atrophy following hemispheric lesions occurring in adulthood [in French]. *Rev Neurol.* 1983;139:485–495.
13. Fieschi C, Agnoli A, Battistini N, Bozzao L, Prencipe M. Derangement of regional cerebral blood flow and its regulatory mechanisms in acute cerebrovascular lesion. *Neurology.* 1968;18:1166–1179.
14. Paulson OB, Olesen J, Christensen MS. Restoration of autoregulation of cerebral blood flow by hypocapnia. *Neurology.* 1972;22:286–293.
15. Melamed E, Lavy S, Portnoy Z. Regional cerebral blood flow response to hypocapnia in the contralateral hemisphere of patients with acute cerebral infarction. *Stroke.* 1975;6:503–508.
16. Slater R, Reivich M, Goldberg H, Banka R, Greenberg J. Diaschisis with cerebral infarction. *Stroke.* 1977;8:684–690.

17. Takano T, Nagatsuka K, Ohnishi Y, et al. Vascular response to carbon dioxide in areas with and without diaschisis in patients with small, deep hemispheric infarction. *Stroke*. 1988;19:840-845.
18. Rootwelt K, Dybevoid S, Nyberg-Hansen R, Russell D. Measurement of cerebral blood flow with <sup>133</sup>Xe inhalation and dynamic single photon emission computer tomography: normal values. *Scand J Clin Lab Invest*. 1986;46(suppl 184):97-105.
19. Vorstrup S. Tomographic cerebral blood flow measurements in patients with ischemic cerebrovascular disease and evaluation of the vasodilatory capacity by the acetazolamide test. *Acta Neurol Scand*. 1988;114(suppl):35-38.
20. Højer-Pedersen E. Effect of acetazolamide on cerebral blood flow in subacute and chronic cerebrovascular disease. *Stroke*. 1987;18:887-891.
21. Chang LT. A method for attenuation correction in radionuclide computed tomography. *IEEE Trans Nucl Sci*. 1978;NS-25:638-643.
22. Mouren-Mathieu AM, Colonnier M. The molecular layer of the adult cat cerebellar cortex after lesion of the parallel fibers: an optic and electron microscope study. *Brain Res*. 1969;16:307-323.
23. Wong-Riley MTT. Changes in the dorsal lateral geniculate nucleus of the squirrel monkey after unilateral ablation of the visual cortex. *J Comp Neurol*. 1972;146:519-547.
24. Meyer JS, Naritomi H, Sakai F, Ishihara N, Grant P. Regional cerebral blood flow, diaschisis and steal after stroke. *Neurol Res*. 1979;1:101-119.
25. Celesia GG, Polcyn RE, Holden JE, Nickles RJ, Koeppel RA, Gatley SJ. Determination of regional cerebral blood flow in patients with cerebral infarction. *Arch Neurol*. 1984;41:262-267.
26. Meyer JS, Hata T, Imai A. Clinical and experimental studies of diaschisis. In: Wood JH, ed. *Cerebral Blood Flow: Physiologic and Clinical Aspects*. New York, NY: McGraw-Hill; 1988:481-502.
27. Baron JC, Bousser MG, Comar D, Duquesnoy N, Sastre J, Castaigne P. "Crossed cerebellar diaschisis": a remote functional depression secondary to supratentorial infarction of man [abstract]. *J Cereb Blood Flow Metab*. 1981;1(suppl 1):S500-S501.
28. Bogsrud TV, Rootwelt K, Russell D, Nyberg-Hansen R. Acetazolamide effect on cerebellar blood flow in crossed cerebral-cerebellar diaschisis. *Stroke*. 1990;21:52-55.
29. Leinsinger G, Schmiedek P, Kreisig T, Einhaupl K, Bauer W, Moser E. <sup>133</sup>Xe-DSPECT: significance of the cerebrovascular reserve capacity for the diagnosis and therapy of chronic cerebral ischemia [in German]. *Nuclearmedizin*. 1988;27:127-134.