

Transient Prolonged Stunning Induced by Dipyridamole and Shown on 1- and 24-Hour Poststress ^{99m}Tc -MIBI Gated SPECT

Dong Soo Lee, Jeong Seok Yeo, June-Key Chung, Myoung Mook Lee, and Myung Chul Lee

Departments of Nuclear Medicine and Internal Medicine, Seoul National University College of Medicine, Seoul, Korea

We investigated whether poststress gated SPECT, which was believed to show resting wall motion, revealed stunning induced by dipyridamole stress. **Methods:** In 62 patients with coronary artery disease ($n = 57$) or chest pain ($n = 5$), dipyridamole stress gated ^{99m}Tc -hexakis-2-methoxyisobutyl isonitrile (MIBI) SPECT and rest ^{201}Tl SPECT were performed on the first day; 24-h delayed ^{201}Tl SPECT and rest gated ^{99m}Tc -MIBI SPECT were performed on the second day. Stress and rest gated ^{99m}Tc -MIBI SPECT was performed 1 h after injection. The myocardium was divided into 17 segments, and perfusion was scored on a 4-point scoring system (scores, 0–3 for normal to defect); wall motion during first-day poststress gated and second-day rest gated SPECT was also scored on another 4-point scale (scores, 0–3 for normal to dyskinesia). **Results:** Thirty-one of 62 patients showed wall motion abnormality that was worse after stress than during resting. Three hundred eight (29%) of the total 1054 segments showed wall motion abnormality on poststress gated SPECT. In 198 of these segments, wall motion abnormality was the same on poststress and rest gated SPECT, and 106 segments showed wall motion that was worse on 1-h poststress than on rest gated SPECT. Perfusion was normal either during rest ($n = 113$) or after a 24-h delay ($n = 18$) in 131 segments with the poststress wall motion abnormality. Of these 131 segments, 69 showed the same wall motion abnormality between poststress and resting periods (persistent stunning). However, in 40 segments, abnormal wall motion on 1-h poststress gated SPECT normalized on rest gated SPECT (transient prolonged stunning). The other 20 segments showed improvement of wall motion during rest compared with the poststress period but still showed abnormal wall motion during the resting period (between transient prolonged stunning and persistent stunning). Stress perfusion decrease was more severe in transient prolonged stunning than in persistent stunning. Poststress wall motion abnormality was more severe in persistent stunning. **Conclusion:** Using gated ^{99m}Tc -MIBI SPECT, stunned myocardium was found on 1-h poststress SPECT compared with normal resting wall motion found on rest gated SPECT on the next day. We conclude that some myocardial walls did not show true resting wall motion on 1-h poststress gated SPECT; hence, caution is necessary when using wall motion on 1-h poststress gated SPECT to assess resting wall motion.

Key Words: gated myocardial SPECT; stunning; dipyridamole stress
J Nucl Med 2000; 41:27–35

After exercise stress, poststress myocardial SPECT is believed to represent stress perfusion and resting wall motion (1). If poststress myocardial SPECT simultaneously represents stress perfusion and resting wall motion, return to normal resting wall motion after stress should be very quick. Recent reports have indicated that ischemic myocardium does not recover its normal resting contractile function so quickly (2,3). According to 1 echocardiographic report, dysfunctional myocardium improved dramatically during the first few minutes after exercise, but not to normal levels, and contractile dysfunction was sustained for a while after initial improvement (2). Some ischemic myocardium recovered normal contractility only after several hours, although these walls had already restored normal resting perfusion.

When coronary steal occurs in the territory of a severely stenosed artery, dipyridamole causes ischemic wall motion abnormality, although dipyridamole does not induce demand ischemia. This characteristic was exploited in dipyridamole stress echocardiography to diagnose significant coronary artery stenosis (4). However, few reports have described how quickly an ischemic abnormality returns to normal after pharmacologic stress. If the gated wall motion of poststress SPECT is used to represent resting wall motion, it is necessary to know whether and how often poststress wall motion represents real resting wall motion.

In this study, we aimed to determine whether poststress 1-h wall motion examined by gated myocardial SPECT was always the same as real resting wall motion. When this was not the case, we investigated how often dipyridamole stress caused a prolonged wall motion abnormality and whether this improved by the next day.

MATERIALS AND METHODS

Subjects

Sixty-two patients (46 men, 16 women; mean age, 59 ± 11 y) were included in this study. Patients were referred for SPECT studies because of chest pain or discomfort. Coronary angiography was performed on 28 patients. Eight patients had single-vessel disease, 6 had two-vessel disease, and 12 had triple-vessel disease. Two patients had normal findings on angiography. Twenty patients had a history of myocardial infarction, 36 suffered from chronic

Received Jul. 27, 1998; revision accepted May 18, 1999.
For correspondence or reprints contact: Dong Soo Lee, MD, Department of Nuclear Medicine, Seoul National University College of Medicine, 28 Yungun-dong Chongnongu, Seoul 110-744, Korea.

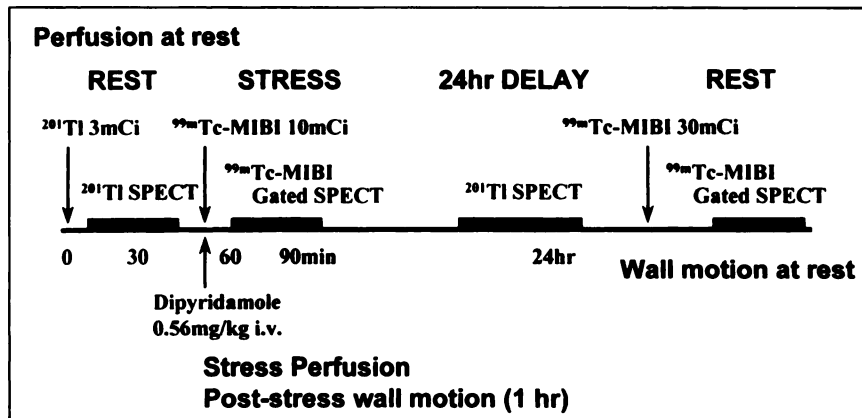


FIGURE 1. SPECT protocol. In addition to routine dual isotope separate acquisition SPECT protocol, 24-h rest gated $^{99\text{m}}\text{Tc}$ -hexakis-2-methoxyisobutyl isonitrile (MIBI) SPECT was performed after 24-h delayed ^{201}Tl SPECT.

coronary artery disease, and 2 had undergone coronary artery bypass graft.

All patients underwent rest ^{201}Tl SPECT, dipyridamole stress gated $^{99\text{m}}\text{Tc}$ -hexakis-2-methoxyisobutyl isonitrile (MIBI) SPECT, and 24-h redistribution ^{201}Tl SPECT. After the 24-h delayed ^{201}Tl study, additional rest gated $^{99\text{m}}\text{Tc}$ -MIBI SPECT was performed.

Reconstruction and Perfusion Analysis

Patients fasted and abstained from taking calcium channel blockers and long-acting nitrates for 24 h. Two SPECT cameras were used for acquisition. Twenty-six patients were studied with a Prism 3000 camera (Picker International, Inc., Cleveland Heights, OH) and 36 patients were studied with a Vertex camera (ADAC Laboratories, Milpitas, CA). Resting ^{201}Tl SPECT was performed using 111 MBq ^{201}Tl (Fig. 1). Dipyridamole (0.14 mg/min/kg administered for 4 min) and 370 MBq (Prism 3000) or 1110 MBq (Vertex) $^{99\text{m}}\text{Tc}$ -MIBI were injected. Thirty minutes later, one egg and 360 mL milk were administered; gated myocardial SPECT was performed 30 min later. $^{99\text{m}}\text{Tc}$ -MIBI uptake on this SPECT represented stress perfusion, and gated wall motion represented wall motion during the poststress period. On the next day, delayed imaging of ^{201}Tl SPECT was performed. After this imaging, 1110 MBq $^{99\text{m}}\text{Tc}$ -MIBI was administered, and gated SPECT images were acquired.

For the Prism 3000 camera, each step lasted 15 s at 3° intervals of the whole 360° orbit. Gating was performed with 8 frames/cycle. For the Vertex camera, each step lasted 25 s at 3° intervals of 180° . Gating was performed with 16 frames/cycle.

After image acquisition, summing gated raw projection files yielded an ungated raw file. Using files of a 180° orbit, SPECT images were reconstructed with a Butterworth filter (Prism 3000:

cutoff frequency, 0.22–0.30; order, 5; Vertex: cutoff frequency, 0.45; order, 10). After reorientation to the short and the vertical and horizontal long axes, these images were used for the assessment of perfusion.

Using apical, middle, and basal short-axis and horizontal long-axis images, the myocardium was divided into 17 segments (Fig. 2). For rest, stress, and redistribution studies, perfusion was graded as normal (0), mild decrease (1), severe decrease (2), or defect (3). After angiography, arteries that were $>50\%$ stenotic were considered significant, and coronary artery disease was determined if 1 of the major vessels was significantly stenosed.

Reconstruction and Display of Gated Images

Gated SPECT images were reconstructed separately for post-stress and rest SPECT studies. For gated SPECT images from the Prism 3000 camera, we examined cine-loop tomographic short-axis images viewed simultaneously on the same screen with slice-to-slice comparison. Wall motion was graded for the same 17 segments using short-axis images (apical, middle, and basal) and horizontal long-axis images. For gated SPECT images from the Vertex camera and quantitative gated SPECT (QGS; ADAC Laboratories), cine loop images of the three-dimensional left ventricle were obtained. Three-dimensional display using end-diastolic endocardial mesh and moving endocardial surface was used for display of motion.

Wall Motion Analysis and Stunned Myocardium

Wall motion was graded as normal (0), hypokinesia (1), akinesia (2), or dyskinesia (3) on visual examination. We surveyed separately wall motion during the resting and the poststress states and

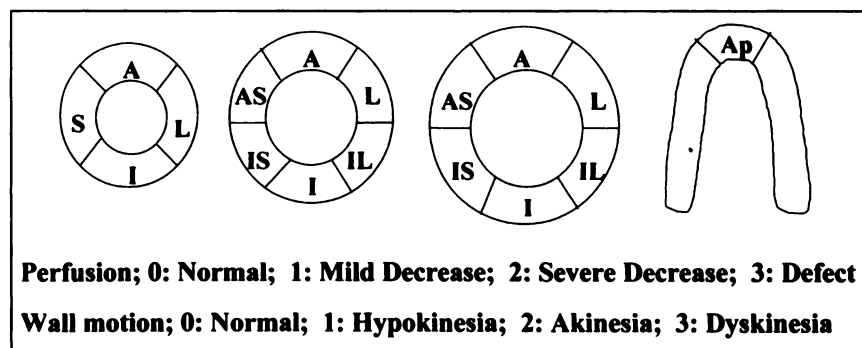


FIGURE 2. Myocardial segments ($n = 17$). Apical, middle, and basal short-axis and horizontal long-axis images were examined.

again simultaneously viewed both images on the same screen (Prism 3000 camera) or sequentially viewed (Vertex camera).

The myocardial segments with poststress wall motion abnormality were split in 2 groups: group 1, which showed improvement of wall motion during rest compared with that of the poststress period; and group 2, which showed persistent wall motion abnormality during both the poststress and the resting periods.

For the myocardial segments whose resting or 24-h ²⁰¹Tl uptake was normal, comparison of the resting and poststress wall motion revealed 3 kinds of myocardial segments (Table 1): the transient prolonged stunned segments, the persistent stunned segments, and the in-between segments. First, if resting wall motion was normal but poststress wall motion was abnormal, these segments were considered as stunned myocardium. This stunning was transient and prolonged (wall motion abnormality was observed during the 1-h poststress period but was improved on the next day). Second, if resting wall motion and poststress wall motion were abnormal to the same degree, these segments were considered as persistently stunned. Third, if resting wall motion was abnormal but better than the poststress wall motion abnormality, these segments were considered to be in-between transient prolonged stunning and persistent stunning.

Calculation of Ejection Fraction

In 26 patients who were studied by the Prism 3000 camera, the left ventricular ejection fraction (EF) was calculated using 3D Perfusion-Motion Map software (Picker International) (5) by operators 1 and 2 working individually. The intra- or interoperator coefficients of variation (root mean square of coefficients of variation with repeated calculation with the same images) were 7.1% and 9.5%, respectively. This degree of variance was not suitable for comparison between the poststress and rest EF. The EF data obtained from the Prism 3000 images were abandoned.

In 36 patients who were studied using the Vertex camera, the left ventricular EF was calculated using QGS software. Intra- or interobserver reproducibility was perfect with the same SPECT images using this method. Variability of the EF on sequential (immediate) acquisition was 1.9% (root mean square of coefficient of variation) (6). According to Bland Altman analysis, 2 SDs of the calculated EF on sequential acquisition was 4.7%. Increase or decrease >4.7% was considered significant between poststress gated SPECT and rest gated SPECT on the next day.

TABLE 1
Types of Stunning and Wall Motion Abnormalities on Poststress and Rest Gated ^{99m}Tc-MIBI SPECT

Stunning	Wall motion		Perfusion at rest or after 24 h
	1 h after stress	Rest	
Persistent	Abnormal	Abnormal	Normal
In-between	Abnormal	Less abnormal	Normal
Transient prolonged*	Abnormal	Normal	Normal

*Prolonged means 1 h after stress.

Comparison of Patients with Persistent Wall Motion Abnormality and Patients with Worse Wall Motion After Stress than During Rest

Patients were also grouped as follows: patients having persistent wall motion abnormality, patients having worse wall motion abnormality after stress than during rest, and patients having normal wall motion during both the poststress and the resting periods. Among 36 patients whose EFs were calculated with QGS software, changes of EF were determined between the poststress and the resting periods in the 2 groups.

Statistical Analysis

Spearman rank correlation analysis was performed to compare rest perfusion with rest wall motion or poststress wall motion. Stress or rest perfusion scores between group 1 and group 2 segments were compared using an unpaired Student *t* test. Perfusion scores or poststress wall motion abnormalities between segments with persistent stunning and segments with transient prolonged stunning were compared using an unpaired Student *t* test. Paired Student *t* tests were used to evaluate differences in the EF between poststress and resting periods.

RESULTS

Correlation of Wall Motion and Perfusion

A significant correlation was found between rest perfusion and rest wall motion (Spearman $\rho = 0.79$) (Fig. 3A) or poststress wall motion ($\rho = 0.77$) (Fig. 3B). When segments with normal perfusion and wall motion were excluded, correlation between rest perfusion and wall motion during rest and during the poststress period was fair (Spearman $\rho = 0.27$ and 0.29 , respectively).

Comparison of EF During Poststress and Resting Periods

The mean EF calculated for 36 patients with QGS software was 40.6% during the poststress period and 42.0% during the resting period. The paired *t* test indicated no difference between EFs of these 2 periods as a whole ($P = 0.16$).

Patients were divided into 2 groups: 1 group with 1 or more segments with worse wall motion during the poststress period than during resting and another group of patients with persistent wall motion abnormality. Among the former group of 19 patients (Fig. 4A), 8 had a significantly greater EF during the resting period than during the poststress period; the difference between resting and after stress was >4.7% (2 SDs of sequential imaging on Bland Altman analysis). Eight patients showed no significant difference. The EF was smaller during the resting period than during the poststress period in the other 3 patients. Among the group of 16 patients with persistent wall motion abnormality (Fig. 4B), 13 showed no significant difference between the EF during the poststress and resting periods. One patient had a greater EF during the resting period and 2 had smaller EFs. The remaining patient did not belong to either of the 2 groups because his wall motion was normal during the poststress and the resting periods.

FIGURE 3. Correlation between myocardial perfusion and resting (A) or poststress wall motion (B). Resting perfusion was graded as normal (0), mild decrease (1), severe decrease (2), or defect (3). Resting or poststress myocardial wall motion was graded as normal (0), hypokinesia (1), akinesia (2), or dyskinesia (3).

		A Perfusion at Rest						B Perfusion at Rest			
		0	1	2	3			0	1	2	3
Wall Motion at Rest	0	717	44	22	10	Wall Motion 1hr Post-Stress	0	686	35	20	5
	1	52	19	23	36		1	68	15	20	26
	2	26	7	20	68		2	40	18	22	77
	3	4	1	2	3		3	5	3	5	9

Comparison of Wall Motion During Poststress and Resting Periods

Among 62 patients, 19 had persistent wall motion abnormality, 12 had normal wall motion during both the poststress and the resting periods, and 31 had segments showing worse wall motion during the poststress period than during rest.

Resting wall motion was normal in 793 of 1054 segments (62 patients \times 17 segments/patient) and was abnormal in 261. Poststress wall motion was normal in 746 segments and abnormal in 308 (Fig. 5). The wall motion of 936 segments (including 738 normal segments) was the same during the poststress and resting periods. One hundred eighteen segments showed different wall motion: 106 segments showed worse wall motion during the poststress period and 12 showed worse wall motion during the resting period.

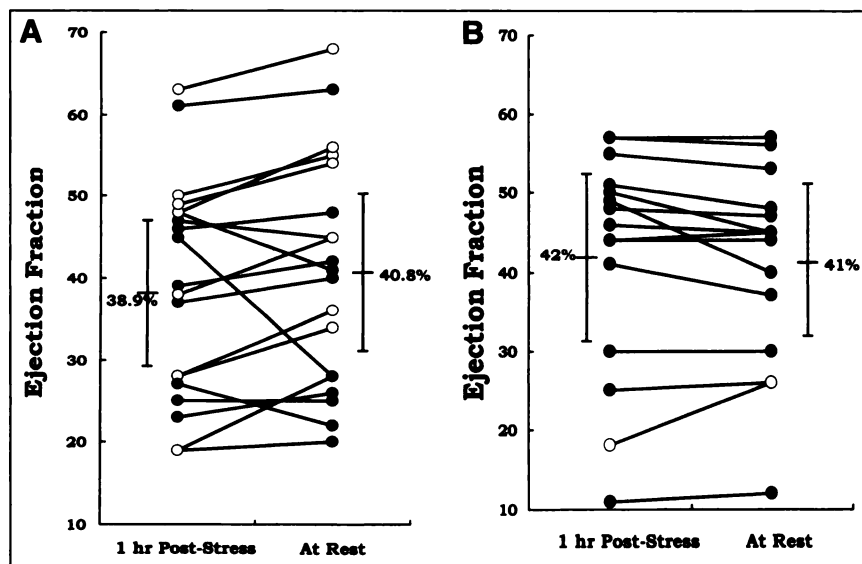
Among 793 segments with normal resting wall motion, poststress wall motion was abnormal in 55 segments (normal-hypokinesia, 42; normal-akinesia, 12; normal-dyskinesia, 1). Among 130 segments with resting hypokinesia, 41 showed worse wall motion during the poststress and resting

periods (hypokinesia-akinesia, 38; hypokinesia-dyskinesia, 3). Among 121 segments with resting akinesia, the wall motion of 10 was worse during the poststress period (akinesia-dyskinesia).

Characteristics of Segments with Worse Wall Motion During Poststress Period than During Resting Period

Three hundred eight segments with wall motion abnormalities during the poststress period were divided into 2 groups: segments showing no difference between the poststress and resting periods (group 1, $n = 198$) and segments in which wall motion was worse during the poststress period than during the resting period (group 2, $n = 106$). The grade of stress perfusion was not significantly different between the 2 groups (group 1, 1.94 ± 1.3 ; group 2, 1.75 ± 1.43 ; $P > 0.05$) (Fig. 6A), but there were significant differences in rest perfusion grades (group 1, 1.73 ± 1.29 ; group 2, 1.08 ± 1.22 ; $P < 0.01$) (Fig. 6B). Resting perfusion was better in group 2.

FIGURE 4. Ejection fraction (EF) during poststress period and during rest calculated by gated myocardial SPECT using quantitative gated SPECT software (●). (A) EF of 19 patients having segments with worse wall motion during poststress period than during rest. (B) EF of 12 patients having persistent wall motion abnormality. (○) Patients show significantly greater EF during resting period than during poststress period.



Post-Stress Wall Motion						
Wall Motion at Rest		0	1	2	3	Sum
	0	738	42	12	1	793
	1	4	85	38	3	130
	2	4	2	105	10	121
	3			2	8	10
	Sum	746	129	157	22	1054

FIGURE 5. Comparison of wall motion during poststress period and resting period. Myocardial wall motion was graded as normal (0), hypokinesia (1), akinesia (2), or dyskinesia (3).

Stunned Myocardium

Among the 308 segments with abnormal wall motion, resting or 24-h delayed ^{201}Tl uptake was normal in 131 segments, of which 2 showed decreased ^{201}Tl uptake on 24-h delayed images (Fig. 7). Among the 131 segments, resting ^{201}Tl uptake was normal in 113 segments, whereas resting ^{201}Tl uptake was decreased but delayed uptake was normal in 18 segments.

Forty of these 131 segments with abnormal wall motion during the poststress period and normal ^{201}Tl uptake during rest or the 24 h-delay showed normal wall motion at rest. These segments were considered to have transient prolonged stunning. In the other 91 segments, wall motion abnormality persisted until the next day at rest. Sixty-nine segments showed the same wall motion abnormality after stress and at rest. These segments were considered to have persistent stunning. Twenty segments showed improved wall motion at rest. These segments displayed characteristics between the 2 stunned states (transient prolonged stunning and persistent stunning) and were considered in-between segments. Resting wall motion was worse in the other 2 segments, which were excluded from the analysis.

Comparison of Transient Prolonged Stunned Myocardium and Persistent Stunned Myocardium

Forty segments with transient prolonged stunned myocardium and 69 with persistent stunned myocardium showed no differences in ^{201}Tl uptake at rest. Stress perfusion abnormality was more severe in transient prolonged stunned segments than in persistent stunned segments ($P < 0.05$) (Fig. 8A). Wall motion abnormality during the poststress period was less severe in the transient prolonged stunned segments than in the persistent stunned segments ($P < 0.05$) (Fig. 8B).

Hyperkinesia in Adjacent Segments of Stunned Myocardium

In 5 of 31 patients in group 2, hyperkinesia was seen in 9 segments that were adjacent to 18 dysfunctional segments. All hyperkinetic segments returned to normal at rest.

DISCUSSION

Using gated myocardial SPECT, myocardial perfusion and contraction were observed simultaneously, and coupling–uncoupling between myocardial perfusion and contraction was examined. Stunning is a well-known example of the uncoupling of myocardial perfusion and contraction and indicates that, although perfusion was re-established with revascularization in the infarcted region, myocardial contraction was not improved. Myocardial contraction has been examined traditionally using echocardiography and perfusion has been examined by myocardial SPECT, but gated

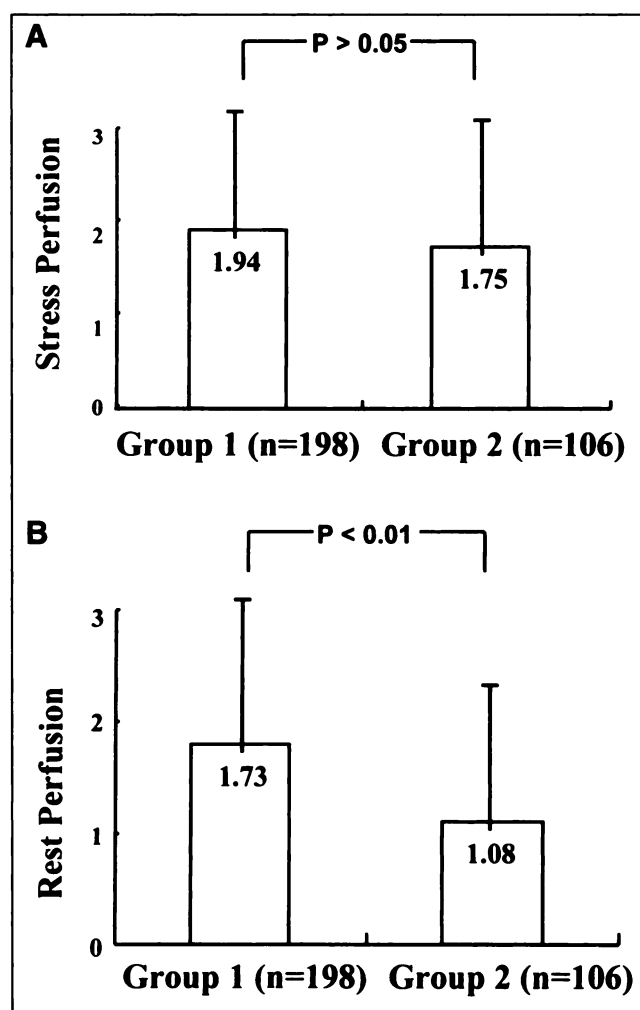


FIGURE 6. Difference in stress perfusion (A) and rest perfusion (B) between segments showing no difference in wall motion during poststress period and resting period (group 1, $n = 198$) and segments in which wall motion during resting period was better than that during poststress period (group 2, $n = 106$). Rest perfusion was better in group 2 than that in group 1.

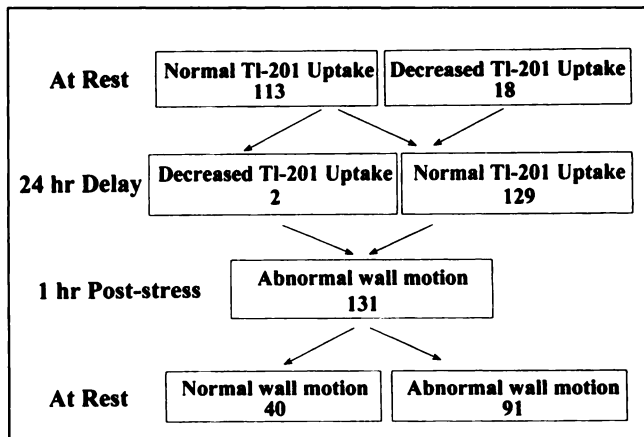


FIGURE 7. Characteristics of ^{201}Tl uptake and wall motion abnormality in stunned segments in which ^{201}Tl uptake was normal at rest or after 24-h delay. Number in each rectangle = number of segments.

myocardial SPECT permits simultaneous examination of both perfusion and contraction (7).

Exercise-induced ischemia could cause wall motion abnormality during stress. However, perfusion returned to the

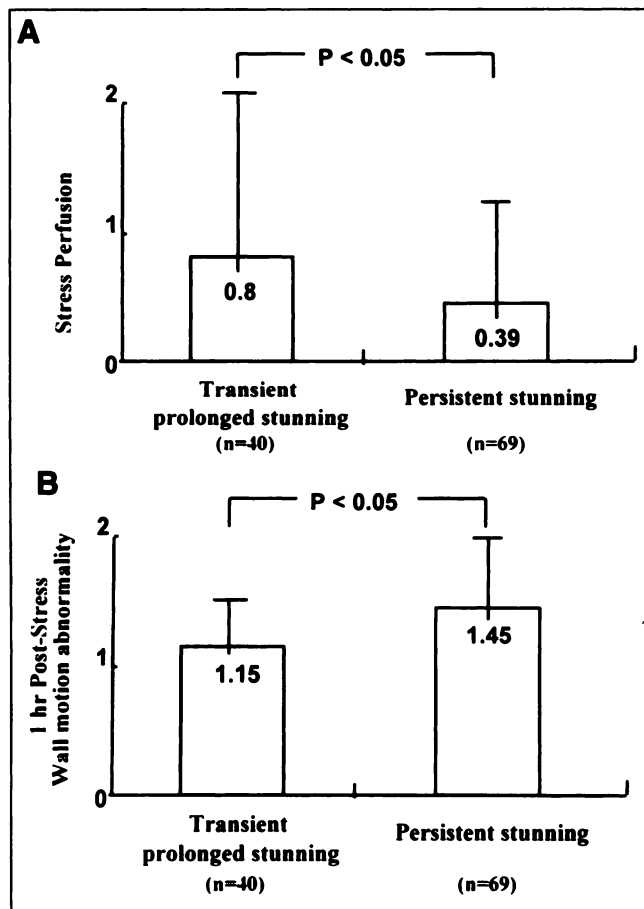


FIGURE 8. Comparison of stress perfusion (A) and poststress wall motion abnormality (B) between transient prolonged and persistent stunned segments. (A) In transient prolonged stunned segments, stress perfusion decrease was more severe ($P < 0.05$). (B) In persistent stunned segments, poststress wall motion abnormality was more severe ($P < 0.05$).

resting state so rapidly after completion of exercise that exercise echocardiography could not show myocardial contraction at the stress peak during the immediate period after exercise (6). This phenomenon implied that physicians could observe resting contraction 1 h after exercise stress. Because $^{99\text{m}}\text{Tc}$ -MIBI SPECT was performed 1 h after stress (after excretion from the liver and gallbladder), the implication is that ischemic wall motion should have returned to normal by this time (1,7).

However, a recent report warned that ischemic wall motion abnormality did not usually return to the resting state after exercise as quickly as suggested by this speculation; some ischemic walls required several hours to recover resting contractility, even though ischemic perfusion abnormality improved considerably within a few minutes (2). These authors suggested that during the short-term period after severe ischemia, perfusion and contraction should be uncoupled and the myocardium experienced stunning.

Pharmacologic stimulation differs from exercise stress in that it does not cause demand ischemia. It only increases myocardial perfusion and reveals the myocardial segments that have an insufficient perfusion reserve and are supplied by significantly stenosed arteries. In myocardium supplied by healthy arteries, perfusion increases 3–5 times after pharmacologic stress, whereas in myocardium supplied by severely stenosed arteries, the reserve is deficient and stress perfusion is less than expected. Sometimes stress perfusion is even less than resting perfusion. This phenomenon is termed coronary steal. A demand–supply mismatch could occur after pharmacologic stress in these myocardial segments (8). To our knowledge, the prevalence of coronary steal during pharmacologic stress has not been reported, although ischemic wall motion can be observed readily on echocardiography and this phenomenon is exploited by dipyridamole or adenosine echocardiography (9).

Although the duration or time course of ischemic wall motion abnormality after dipyridamole stress is unknown (using wall motion on 1-h poststress gated $^{99\text{m}}\text{Tc}$ -MIBI SPECT to represent resting wall motion), all ischemic wall motion abnormalities should have been normalized within 1 h. This study attempted to investigate whether this was the case by comparing 1-h poststress wall motion with resting state wall motion on the next day. One hundred six segments (group 2) showed worse wall motion abnormality during the poststress period than during rest (Fig. 5). Although wall motion was abnormal during the poststress period, wall motion returned to normal in 40 segments; we believed this finding was associated with short-term stunning because resting perfusion of these segments was normal during the resting period before and 24 h after stress.

We investigated whether there were any differences between segments (group 1) in which wall motion abnormality between the poststress and the resting periods was the same and segments (group 2) in which wall motion was worse during the poststress period. There was no difference in the severity of stress perfusion, but there was a difference

in rest perfusion; in group 2 segments, rest perfusion was better, and it could be assumed that better perfusion at rest led to improvement on the next day of dipyridamole-induced wall motion abnormalities.

To understand the influence of persistence or transience of wall motion abnormalities on left ventricular global function, we calculated and compared the left ventricular EF of the poststress period with that of the resting period. Reproducibility analysis indicated that comparison could be relied on only in patients studied with QGS software. In patients studied with QGS software, reproducibility of EF was excellent on sequential acquisitions, and we used 2 SDs of variation to determine significant differences of the EF between poststress and resting periods. The EF of the poststress period was significantly smaller in nearly half of the patients who had worse wall motion on poststress SPECT images, whereas only 1 patient showed a smaller EF on poststress SPECT among the patients with persistent wall motion abnormality. Another half of the patients showed no significant difference of the EF between the poststress and resting periods among the former group of patients, but the EF tended to be greater at rest. This finding enhanced our belief that visually recognized difference on poststress and rest gated SPECT was not an artifact.

Calculation of the EF with 3D Perfusion-Motion Map software implied significant operator-dependent variability (5). The inherent uncertainty of this software with an intraobserver reproducibility of 7% with the same gated SPECT images made further analysis difficult. The difference between EFs of the poststress and resting periods was only 2.8% in the group of 26 patients studied with 3D Perfusion-Motion Map software. The difference was thus within 1 SD of the estimated mean, and these data could not prove or disprove this speculation.

^{201}Tl uptake was normal at rest or the 24-h delay, but wall motion was abnormal during the poststress period in 131 segments. Wall motion of 40 of these dysfunctional segments returned to the normal resting state on the next day. Wall motion of the other 69 dysfunctional segments did not change between the poststress and resting periods. The former was considered as transient prolonged stunned myocardium. This term was coined on the basis of the beliefs that (a) all motion abnormality must have occurred during stress; (b) ischemic wall motion abnormality persisted 1 h after stress, although resting perfusion was normal; and (c) wall motion became normal 24 h after stress. This stunning was transient and was induced by dipyridamole stress (Fig. 9).

In contrast to these transient prolonged stunned segments, continuing wall motion abnormality was observed despite normal perfusion at rest; in some segments (69/89), the degree of wall motion abnormality was the same between the poststress and the resting periods. This was termed persistent stunning (Table 1). Twenty segments showed slight improvement during the period from 1 h after stress to 24 h, but not a return to the normal resting state.

On the basis of these findings, it seemed reasonable that a spectrum of stunning from transience to persistence should exist. This might be described as follows: (a) segments in which wall motion was abnormal because of stress but in which, at the time of imaging (1 h after stress), wall motion had already returned to its normal state (ischemic wall motion abnormality); (b) segments with abnormal wall motion that did not return to normal within 1 h of stress but did so on the next day (transient prolonged stunning); (c) segments in which wall motion was abnormal on poststress SPECT, had not returned to the resting state within 1 h of stress, and improved on the next day but was still abnormal (between transient prolonged stunning and persistent stunning); and (d) segments with persistent abnormal wall motion without change of the degree of wall motion abnormality until the next day (persistent stunning). Transient prolonged stunned myocardium plus the in-between segments is termed transient stunned myocardium.

When the characteristics of the persistent and transient stunned segments were compared, no difference was found in rest perfusion but persistent stunned segments showed more severe wall motion abnormality during the poststress period despite a less severe perfusion decrease during stress (Fig. 8). This finding suggested that in persistent stunned myocardium, wall motion abnormality was more severe during stress and would have taken longer to recover its resting state. It might be assumed that persistent stunned myocardium had developed over a longer period and was thus in a chronic state.

Hyperkinetic motion was found in adjacent segments near stunned myocardium, and as transient stunned segments recovered their resting wall motion, this hyperkinetic motion returned to normal on the next day. This observation corroborated our belief that the stunned appearance of movement in poststress perfusion-defective walls was not an artifact but a real finding because stunning and adjacent compensatory movements were all transient.

In this study it was not necessary to increase acquisition time or injected dose to get gated SPECT images of similar quality. Mazzanti et al. (10) suggested that 6–7 min of acquisition with 1110 MBq $^{99\text{m}}\text{Tc}$ -MIBI were sufficient for the assessment of wall motion and thickening using gated SPECT. This study used 370 MBq $^{99\text{m}}\text{Tc}$ -MIBI for stress imaging with the Prism 3000 camera, and acquisition lasted for 15 s per step with gating. Although poststress radioactivity was lower than that of resting activity, image quality was the same and it was not difficult to compare wall motion and perfusion. When the Vertex camera was used, because the camera sensitivity with the high-resolution collimator was about half that of the Prism 3000 camera with the low-energy, high-resolution collimator, 1110 MBq $^{99\text{m}}\text{Tc}$ -MIBI were used for both stress and rest studies.

It was not easy to confidently assess wall motion in perfusion-defective walls. Thus, it is thus possible that poststress wall motion was underestimated on the tomographic images. When 3D Perfusion-Motion Map software

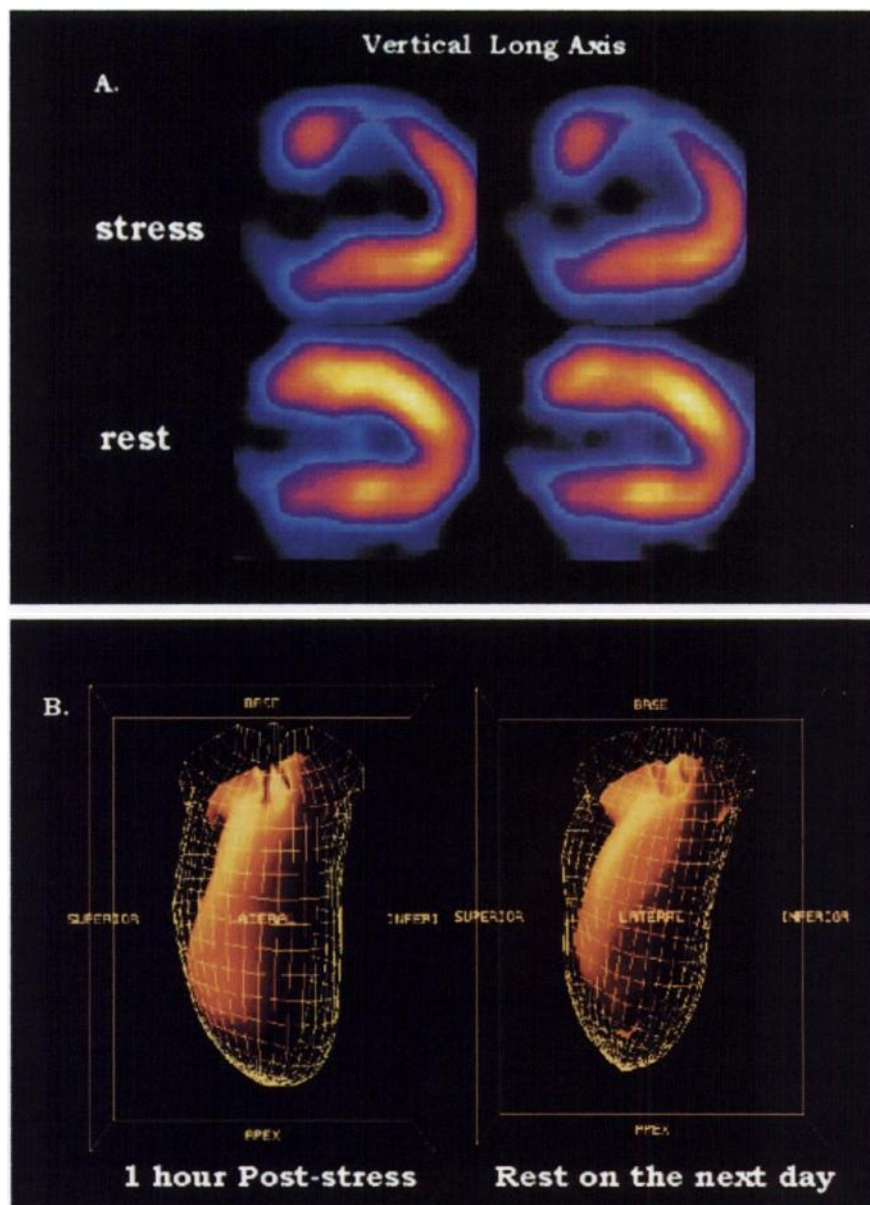


FIGURE 9. ^{99m}Tc -MIBI SPECT in 64-y-old man. (A) Reversible perfusion defect in mid anterior wall. (B) Akinetic wall motion abnormality in perfusion-defective area during 1-h poststress period improved much during resting period.

was used, attempts were made to lessen this possibility of underestimation using a dual display for both poststress and rest images on the same monitor screen; however, we were not absolutely free of subjectivity in the visual scoring of semiquantitative grades of wall motion. When QGS software (11) was used, a 3-dimensional display was used and there was no need to worry about the reproducibility of making 3-dimensional images. Reading the same images by 1 or 2 operators yielded good reproducibility ($\kappa = 0.75$) (6).

CONCLUSION

The occurrence of dipyridamole stress-induced short-term stunning was proven in this study. Using gated myocardial SPECT, myocardial contraction and perfusion were assessed simultaneously and short-term sequelae of ischemic wall motion abnormality were found during the 1-h poststress

period. Because poststress and resting wall motion was sometimes different and the prevalence of this short-term stunning was not negligible, caution is necessary when wall motion on 1-h poststress gated SPECT is used to assess resting wall motion.

ACKNOWLEDGMENTS

The authors thank Jae Ryong Woo and Moon Hye Kim for their reconstruction of more than 500 gated SPECT images and calculation of the ejection fraction. We also thank Yoo Jung Lee for preparation of the graphs and images.

REFERENCES

1. Chua T, Kiat H, Germano G, et al. Gated technetium-99m sestamibi for simultaneous assessment of stress myocardial perfusion, postexercise regional ventricular function and myocardial viability: correlation with echocardiography and rest thallium-201 scintigraphy. *J Am Coll Cardiol*. 1994;23:1107-1114.

2. Allen J, Cox T, Kloner RA. Myocardial stunning following exercise testing in man: early time course [abstract]. *Circulation*. 1995;92:1-551.
3. Johnson LL, Verdesca SA, Aude WY, et al. Postischemic stunning can affect left ventricular ejection fraction and regional wall motion on post-stress gated sestamibi tomograms. *J Am Coll Cardiol*. 1997;30:1641-1648.
4. Picano E. Dipyridamole stress echocardiography. In: Picano E, ed. *Stress Echocardiography*. 3rd ed. Berlin, Germany: Springer; 1997:108-116.
5. Faber TL, Akers MS, Peshock RM, Corbett JR. Three-dimensional motion and perfusion quantification in gated single-photon emission computed tomograms. *J Nucl Med*. 1991;32:2311-2317.
6. Lee DS, Cheon GJ, Ahn JY, Chung J-K, Lee MC. Reproducibility of the assessment of myocardial function using gated Tc-99m-MIBI SPECT and quantitative software. *Korean J Nucl Med*. 1998;32:403-413.
7. DePuey EG, Razanski A. Using gated technetium-99m-sestamibi SPECT to characterize fixed myocardial defects as infarct or artifact. *J Nucl Med*. 1995;36:952-955.
8. Becker LC. Conditions for vasodilator-induced coronary steal in experimental myocardial ischemia. *Circulation*. 1978;57:1103-1110.
9. Dagianti A, Penco M, Agati L, et al. Stress echocardiography: comparison of exercise, dipyridamole and dobutamine in detecting and predicting the extent of coronary artery disease. *J Am Coll Cardiol*. 1995;26:18-25.
10. Mazzanti M, Germano G, Kiat H, Friedman J, Berman D. Fast technetium-99m-labeled sestamibi gated SPECT for the evaluation of myocardial function. *J Nucl Cardiol*. 1996;3:143-149.
11. Germano G, Kiat H, Karvanagh PB, et al. Automatic quantification of ejection fraction from gated myocardial perfusion SPECT. *J Nucl Med*. 1995;36:2138-2147.