

^{99m}Tc -Labeled Vasoactive Intestinal Peptide Analog for Rapid Localization of Tumors in Humans

Mathew L. Thakur, Carol S. Marcus, Sohail Saeed, Venkat Pallela, Craig Minami, Linda Diggles, H. Le Pham, Robert Ahdoot, and E. Anthony Kalinowski

Department of Radiology, Thomas Jefferson University, Philadelphia, Pennsylvania; and Departments of Radiology, Nuclear Medicine, and Pharmacy, Harbor-UCLA Medical Center, Torrance, California

In recent years, imaging tumors with receptor-specific biomolecules has been the focus of increasing interest. Vasoactive intestinal peptide (VIP) has a high affinity for specific receptors that are expressed in high density on a large number of malignant tumors. VIP was modified (TP 3654) without compromising its biologic activity and labeled with ^{99m}Tc . Pharmacokinetics and feasibility studies were performed in 3 healthy volunteers and 11 patients with a history of cancer. Imaging was performed for up to 2 h after injection. Within 24 h after injection of ^{99m}Tc -TP 3654 (370–555 MBq/5 μg), approximately 70% of the tracer cleared through the kidneys and 20% through the liver. Blood clearance was rapid. No adverse reaction was noted in any subject. All known tumors were clearly delineated within 20 min. Findings were compared with the results of ^{99m}Tc -methoxyisobutyl isonitrite, CT, MRI, or histology. There was concordance in 9 patients. In the other 2 patients, only the VIP scan was positive for tumors known to express VIP receptors. The early results of imaging tumors with ^{99m}Tc -VIP are promising and warrant further study.

Key Words: ^{99m}Tc -VIP; receptor-specific tumor imaging; imaging human tumors with ^{99m}Tc -VIP; vasoactive intestinal peptide

J Nucl Med 2000; 41:107–110

Vasoactive intestinal peptide (VIP) is a 28 amino acid peptide first characterized more than a quarter of a century ago. A neuroendocrine mediator with a broad spectrum of biologic activities, VIP stimulates secretion of various hormones and promotes growth and proliferation of normal and malignant cells. The action is mediated by cell surface membrane receptors, VPAC1 and VPAC2, which are expressed in much higher density on tumor cells of breast, prostate, colorectum, pancreas, and brain; sarcomas; and carcinoids, to name a few, than on normal cells (1).

VIP labeled with ^{123}I (half-life [$t_{1/2}$] = 13.3 h; γ = 159 keV, 84%) was given intravenously to cancer patients, and

all known and unknown lesions were detected by scintigraphic imaging (2). ^{123}I , however, is a cyclotron-produced, relatively expensive radionuclide with limited availability and must be ordered days ahead of the examination. The radiolabeling chemistry is also such that it requires high-performance liquid chromatography purification and 2–3 h of preparation time. This is inconvenient and further limits its use. Imaging is performed 2–3 h later.

^{99m}Tc , on the other hand, not only has excellent physical characteristics ($t_{1/2}$ = 6 h; 140 keV, 90%) for scintigraphic imaging but is also inexpensive and is available throughout the world by a ^{99}Mo generator system. We have modified VIP (TP 3654) that permits us to rapidly label the peptide with ^{99m}Tc without compromising its biologic characteristics or receptor specificity (3). This study was undertaken to examine its pharmacokinetics (4) and to determine the feasibility of using ^{99m}Tc -TP 3654 as an agent for imaging tumors in humans.

MATERIALS AND METHODS

To be able to label VIP with ^{99m}Tc , the peptide was modified at the C-terminus by the addition of 5 amino acids. Of these, Gly³⁰-(D)-Ala³¹-Gly³²-Gly³³ (GAGG) served as a chelating moiety for strong chelation of ^{99m}Tc and Aba²⁹ (4-amino butyric acid) as a spacer to minimize steric hindrance. The entire 33 amino acid peptide was synthesized, purified, characterized by mass spectroscopy, and named TP 3654 (3).

A total of 10 μg TP 3654, together with 25 μg $\text{SnCl}_2 \cdot 2\text{H}_2\text{O}$ and 400 μL 0.05 mol/L Na_3PO_4 solution, were lyophilized and stored under N_2 at -80°C . At the time of preparation approximately 1.1 GBq ^{99m}Tc in 0.5 mL 0.9% NaCl was added and incubated at 22°C for 30 min. To the solution was then added 1 mL 0.05 mol/L NaH_2PO_4 solution, followed by the addition of 0.25 mL ascorbic acid (250 mg/mL). Routine quality control tests were performed (3). After approval from the Institutional Review Board and the Radioactive Drug Research Committee, 3 healthy volunteers and 11 patients with a history of cancer were enrolled in the study. Each individual was given, intravenously, approximately 370 MBq ^{99m}Tc -TP 3654 (407 GBq/ μmol) and serial spot views or whole-body images were then obtained for up to 2 h after injection. The vital signs of each patient were monitored. Scans were called

Received May 4, 1999; revision accepted Aug. 5, 1999.

For correspondence or reprints contact: Mathew L. Thakur, PhD, Thomas Jefferson University Hospital, 1020 Locust St., Ste. 359 JAH, Philadelphia, PA 19107.

positive when ^{99m}Tc -TP 3654 uptake in lesions exceeded radioactivity in the adjacent tissue. Findings were compared with the results of ^{99m}Tc -methoxyisobutyl isonitrite (MIBI), CT, MRI, or histology.

RESULTS

The lyophilized kits were stable, and unbound ^{99m}Tc and colloid formation were $<3\%$. No adverse reactions or changes in vital signs were noted in any of the subjects. Over a 24-h period, in the 3 healthy volunteers, approximately 70% of the injected dose was eliminated in urine and 20% was cleared through the liver (4). Blood clearance of the tracer was rapid. Whole-body images for up to 2 h after injection showed tracer uptake in the bladder, kidneys, and gallbladder, as well as faint uptake in the liver, spleen, and lungs (4).

The 11 patients were composed of 5 patients with breast cancer, 1 with osteosarcoma, 1 with a history of colon cancer, 1 with spindle cell sarcoma in the neck, 1 with bowel obstruction caused by an hemangiopericytoma, 1 with humeral spread of adenocarcinoma, and 1 with a small nodule in the left lung from a clear cell cancer of the uterus. Eight patients had positive scans within 20 min of injection. These results corroborated well with the findings of CT, MRI, ^{99m}Tc -sestamibi scans, or histopathology. There was a normal VIP scan in a patient with previously removed colon cancer and no evidence of recurrence. One patient with a

small left lung nodule seen by CT had a normal VIP scan, possibly because of the small size of the nodule. One patient with right breast hyperplastic ductal epithelium with atypia had a normal ^{99m}Tc -MIBI scan as well as normal ^{99m}Tc -VIP scan. A 42-y-old woman with a history of right breast cancer followed by mastectomy and silicon implant presented with a left breast mass suggestive of malignancy. Because of dense tissue in the left breast, the mammogram was difficult to evaluate. ^{99m}Tc -sestamibi was normal, but ^{99m}Tc -VIP showed a large area of increased uptake. Biopsy sample analysis revealed that it was ductal epithelial hyperplasia, which is known to express VIP receptors (1). Autoradiographic studies of the biopsy tissues showed intense uptake of ^{99m}Tc -VIP in the ductal region but not in the connecting tissue. The high-grade spindle cell sarcoma was normal on the ^{99m}Tc -MIBI scan but intensely positive on the ^{99m}Tc -VIP scan. The history, diagnosis, and findings from ^{99m}Tc -TP 3654 studies of the 11 patients are given in Table 1, and two specific examples are shown in Figures 1 and 2.

DISCUSSION

Cancer remains a major health problem of mankind. Although extensive new knowledge has led health care professionals to a changing philosophy in its management, 1 factor that remains of undisputed importance is early

TABLE 1
Scintigraphic Results with ^{99m}Tc -VIP and Final Diagnosis

Patient no.	Age (y)	Sex	^{99m}Tc -VIP results	History and diagnosis
1	44	F	L breast positive R breast positive	Bilaterally positive mammography and positive SMM 6 wk previously. Lesions of same shape and size as on ^{99m}Tc -VIP.
2	42	F	L chest wall positive R breast positive	L breast mastectomy for cancer. Presented with recurrence in L chest wall and R breast. SMM positive for L chest wall and R breast. Lesions same shape and size with ^{99m}Tc -VIP.
3	42	F	L breast positive	R breast mastectomy for cancer followed by silicon implant. Presented with L breast palpable mass with ductal epithelial hyperplasia. Mammography was difficult to evaluate. SMM normal.
4	39	F	L breast positive R breast positive	R breast cancer treated with surgery, chemo- and radiotherapy. Mammography showed mass in R breast. SMM showed L breast mass and faint R breast uptake. ^{99m}Tc -VIP showed L breast uptake and greater R breast uptake than SMM. Histology showed malignancy.
5	47	F	Normal breast scan	Biopsy for R breast mass with hyperplastic ductal epithelium atypia. SMM normal bilaterally.
6	27	M	Uptake close to bladder	Long history of bowel obstruction. CT showed mass near bladder. ^{99m}Tc -MIBI inconclusive because of bladder activity.
7	20	F	Positive for left neck mass	History of neurofibroma. Presented with L neck mass. Bone scan showed faint blood-pool activity. ^{99m}Tc -MIBI normal. ^{99m}Tc -VIP scan positive, consistent with visible mass and histology showing spindle cell sarcoma.
8	50	M	R shoulder positive	R shoulder adenocarcinoma. Bone scan showed involved bone. ^{99m}Tc -MIBI positive for R shoulder.
9	18	M	Positive for R lower femur	Positive on MRI, bone scan, and ^{99m}Tc -MIBI for osteosarcoma.
10	59	F	Normal scan	Had surgical resection for colon cancer. No evidence of recurrence.
11	43	F	Normal scan	History of clear cell cervical carcinoma. Small nodule in L upper lung seen by CT. No ^{99m}Tc -MIBI scan.

VIP = VIP analog TP 3654; SMM = ^{99m}Tc -sestamibi mammography; MIBI = methoxyisobutyl isonitrite.

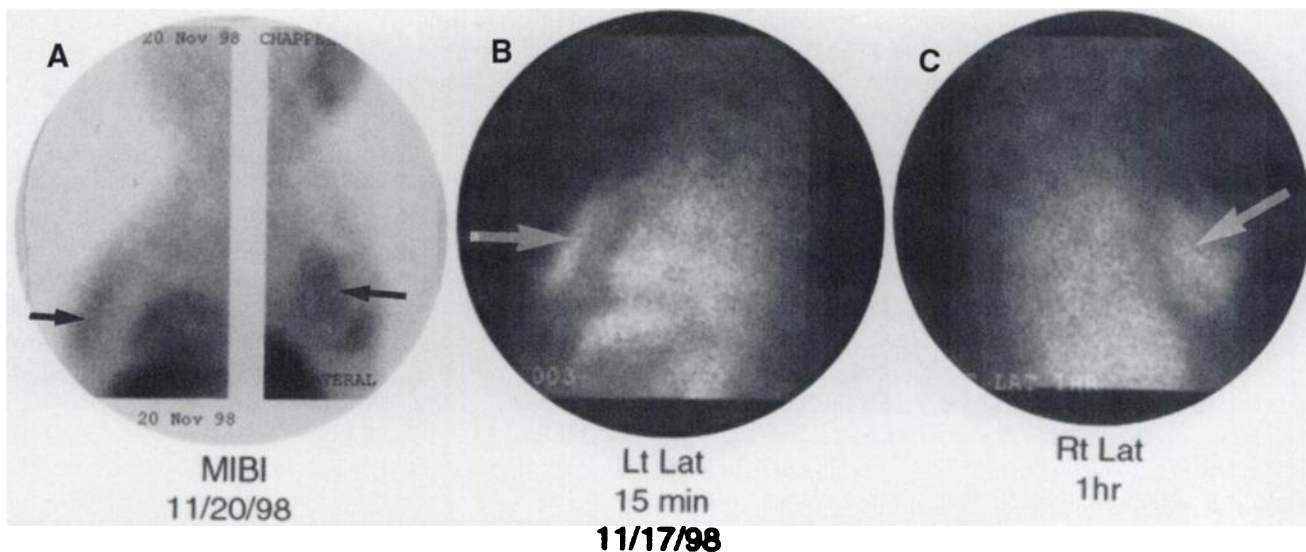


FIGURE 1. A 42-y-old woman with prior left mastectomy presented with recurrence in right breast and left operative site. (A) Lateral images with ^{99m}Tc -sestamibi show uptake in chest wall and right breast (arrows). Left (B) and right (C) lateral views obtained at 15 min and 1 h after injection of ^{99m}Tc -VIP show same lesions (arrows) perhaps with better intensity than on corresponding ^{99m}Tc -sestamibi images.

diagnosis. In recent years, CT and MRI have greatly improved the diagnostic abilities for anatomic localization of tumors. However, metabolic or receptor-specific tumor imaging is advantageous because such imaging can reveal the state of malignancy and may distinguish malignant tumors from benign ones. Metabolic or receptor-specific tumor imaging is more advanced with radionuclide imaging than with CT, MRI, or sonography. The complementary role of nuclear medicine imaging is therefore well recognized, and the search has continued for better and more specific imaging agents than those currently available.

There are other tumor imaging agents, 2 of which are based on tumor metabolism. The first, FDG, is an excellent

agent but needs ^{18}F , with a $t_{1/2}$ of 110 min. This must be produced by a cyclotron and requires PET or a coincidence γ camera for imaging. Currently, <1% of the nation's nuclear medicine centers can use FDG. The second, a perfusion agent, ^{99m}Tc -sestamibi, is presumed to be taken up by mitochondria in tumors and generally suffers from high background activity caused by nonspecific uptake in many normal tissues. Although it is 86% sensitive for palpable breast tumors, it detects only 63% of nonpalpable breast tumors and does not obviate biopsy for histologic examinations (5). Its usefulness in detecting other tumor types is not yet well established.

Frequently overexpressed on the surface of malignant

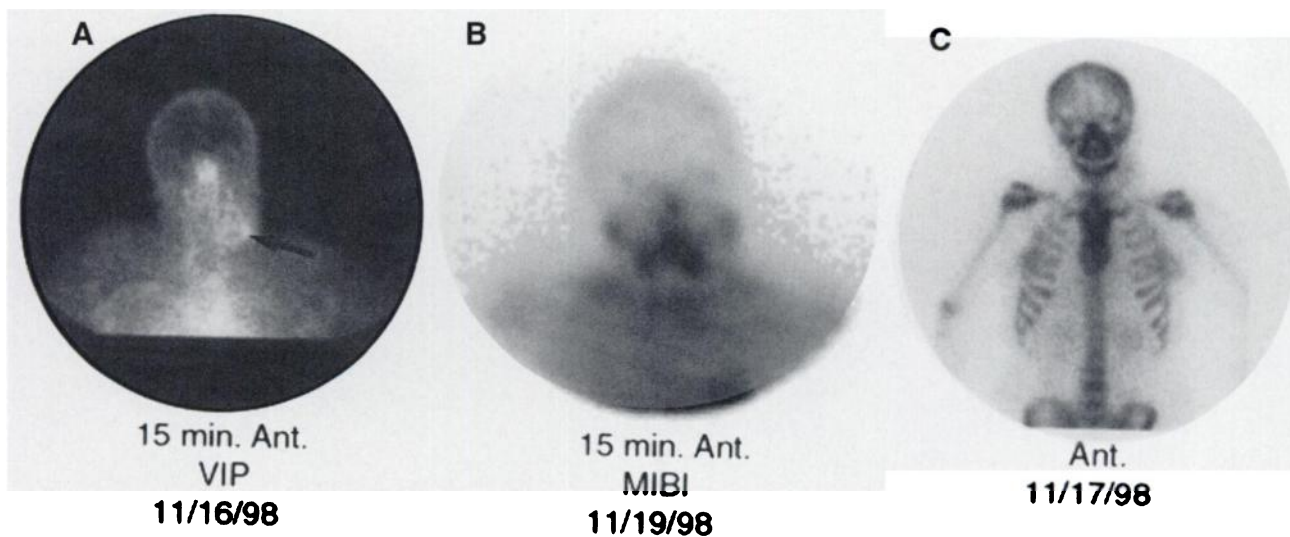


FIGURE 2. A 20-y-old woman with history of neurofibroma of brain in childhood presented with mass in left neck that was evident for 1 mo. (B) ^{99m}Tc -MIBI scan was negative. (C) Bone scan showed faint blood pool. However, ^{99m}Tc -VIP scan (A) showed unequivocally positive uptake (arrow). Immunohistology of lesion showed that it was high-grade spindle cell sarcoma.

proliferative cells are certain characteristic biomolecules, the receptors, that specifically interact with a family of substances discovered during the last 25 y. These endogenous compounds or their analogs bind to the specific cell surface receptors in nanomole to femtomole concentrations and have been the focus of considerable interest, both in therapy and diagnosis of malignant tumors. The only commercially available neuropeptide, somatostatin receptor-specific ^{111}In -[diethylenetriamine pentaacetic acid-D-Phe¹]octreotide, is the third tumor imaging agent. However, cyclotron-produced ^{111}In is much more expensive than $^{99\text{m}}\text{Tc}$ and is not as easily available. Furthermore, somatostatin-receptor density on most types of tumors is much lower than their VIP-receptor density (1).

These data, obtained with a $^{99\text{m}}\text{Tc}$ -VIP analog in a limited number of patients, indicate that the agent is easy to prepare, convenient to use, and permits rapid imaging of tumors with planar γ camera scintigraphy. In our current preparation, we used approximately 5 μg VIP. No adverse reaction of any kind was noted in any subject. Lung uptake of $^{99\text{m}}\text{Tc}$ -VIP was much less than that of ^{123}I -VIP (2). $^{99\text{m}}\text{Tc}$ -VIP was cleared from circulation through the kidneys and liver. All positive images were diagnostic in <20 min after injection. Although late images showed gastrointestinal activity, the speed of its tumor uptake may permit us to image abdominal tumors. Rapid bladder uptake may make it difficult to image prostate cancer and may require continuous elimination of urine to succeed.

Most $^{99\text{m}}\text{Tc}$ -VIP images were similar to MIBI images, including a scan of hyperplastic atypia, which was negative on both VIP and MIBI images. The receptor characteristics

of hyperplastic atypia are unknown. However, it was interesting to note that the lesions with ductal epithelial hyperplasia and the high-density spindle cell sarcoma, known to express VIP receptors, were both positive on only $^{99\text{m}}\text{Tc}$ -VIP scans and not with other, commonly used imaging modalities. The patient with ductal epithelial hyperplasia underwent mastectomy of the right breast for malignant cancer. The hyperplastic lesion that presented in the left breast 2 y later did not show malignant morphology. However, the $^{99\text{m}}\text{Tc}$ -VIP image of the lesion was intensely positive and suggested that the technique can reveal biochemical changes by noninvasive means, before the characteristic changes of malignant morphology have occurred.

CONCLUSION

Thus, currently, the agent shows reliability, simplicity, speed, and the lack of toxicity. Further studies will determine if this agent can distinguish malignant tumors from benign ones and identify those lesions that are still morphologically normal but destined to become malignant.

REFERENCES

1. Reubi JC. In vitro identification of VIP receptors in human tumors: potential clinical application. *Ann NY Acad Sci.* 1996;805:753-759.
2. Virgolini I, Kurtaran A, Raderer M, et al. Vasoactive intestinal peptide receptor scintigraphy. *J Nucl Med.* 1995;36:1732-1739.
3. Pallela V, Thakur ML, Chakder S, Rattan S. $^{99\text{m}}\text{Tc}$ -labeled vasoactive intestinal peptide receptor agonist: functional studies. *J Nucl Med.* 1999;40:352-360.
4. Marcus CS, Thakur ML, Saeed S, et al. Human dosimetry of Tc-99m-vasoactive intestinal peptide (VIP) [abstract]. *J Nucl Med.* 1999;40(suppl):310P.
5. Khalkhali I, Mena I, Diggles L. Review of imaging technique for the diagnosis of breast cancer: a new role of prone scintimammography using Tc-99m-SestaMIBI. *Eur J Nucl Med.* 1994;21:357-362.