

Loss of ^{123}I -MIBG Uptake by the Heart in Parkinson's Disease: Assessment of Cardiac Sympathetic Denervation and Diagnostic Value

Akira Satoh, Takumi Serita, Makiko Seto, Itsuro Tomita, Hideyo Satoh, Keisuke Iwanaga, Hidetoshi Takashima and Mitsuhiro Tsujihata

Division of Neurology, Nagasaki Kita Hospital, Nagasaki, Japan

Myocardial imaging with ^{123}I -metaiodobenzylguanidine (MIBG) was performed on 35 patients with Parkinson's disease and 24 control subjects to evaluate cardiac sympathetic function in patients with Parkinson's disease, verify this phenomenon and examine whether myocardial MIBG uptake and clearance are correlated with the clinical severity of Parkinson's disease. **Methods:** We studied 35 patients with Parkinson's disease and 24 control subjects with other central nervous system diseases. The latter group consisted of 12 subjects with other neurodegenerative disorders (4 with spinocerebellar degeneration, 2 with amyotrophic lateral sclerosis, 3 with progressive supranuclear palsy and 3 with corticobasal degeneration and 12 patients with cerebral infarction (CI), 6 with vascular parkinsonism and 6 without it. Early and delayed images of the anterior view were obtained 15 min and 4 h after injection of ^{123}I -MIBG, respectively. MIBG uptake was quantified by calculating a heart-to-mediastinum count (H/M) ratio. **Results:** The H/M ratio was markedly reduced in the patients with Parkinson's disease (II to V on the Hoehn and Yahr scale) compared with the control subjects. None of the subjects with neurodegenerative diseases showed a marked decrease in myocardial MIBG uptake nor did any subject with CI. **Conclusion:** Our findings indicate that, in Parkinson's disease, a reduction in myocardial MIBG uptake is a very common, specific phenomenon that can be used to detect cardiac autonomic dysfunction to diagnose Parkinson's disease, particularly in patients without typical signs and symptoms.

Key Words: Parkinson's disease; metaiodobenzylguanidine; autonomic function; sympathetic nervous system

J Nucl Med 1999; 40:371-375

The autonomic nervous system is impaired in patients with Parkinson's disease and cardiovascular autonomic failure, e.g., low spine values (1,2) and orthostatic hypotension (3-5) have been described in Parkinson's disease. Neuropathologic studies (6,7) support major involvement of the nervous system in Parkinson's disease. The existence and extent of cardiac autonomic neuron integrity in Parkinson's disease, however, is not clear. Metaiodobenzylguanidine

(MIBG) accumulates specifically in postganglionic sympathetic neurons in the way that norepinephrine does. Consequently, the myocardial activity and kinetics of MIBG may reflect the normal structure and functions of the cardiac sympathetic nerves (8-10). Rapid clearance of myocardial MIBG has been reported in patients with such autonomic neuropathies as familial amyloidotic polyneuropathy (11), Shy-Drager syndrome (idiopathic orthostatic hypotension) (12) and diabetes mellitus (13). Myocardial MIBG accumulation in Parkinson's disease with orthostatic hypotension is also reduced (14). We have had a male patient with Parkinson's disease without orthostatic hypotension who showed almost complete loss of MIBG uptake in the heart (15). We therefore used MIBG imaging to evaluate cardiac sympathetic function in patients with Parkinson's disease, to verify this phenomenon and to examine whether myocardial MIBG uptake and clearance are correlated with the clinical severity of Parkinson's disease.

SUBJECTS AND METHODS

Subjects

We studied 35 patients with idiopathic Parkinson's disease and 24 control subjects with other central nervous system diseases (CNS-control). The patients with Parkinson's disease included 15 men and 20 women, mean age 69.3 y (48-84 y). Mean disease duration was 73.2 mo (8-180 mo). In 3 patients, parkinsonian signs were limited to one side only (Hoehn and Yahr [HY] I) and the symptoms of these 3 patients are resting tremor and mild rigidity to one side. Thirty-two patients had bilateral symptoms and at least two of the cardinal motor symptoms of Parkinson's disease (akinesia, rigidity and resting tremor). Disability levels on the HY scale were 3 patients, stage I; 8 patients, stage II; 13 patients, stage III; 7 patients, stage IV and 4 patients, stage V. Twenty-five patients with Parkinson's disease had histories of receiving antiparkinsonian medications or were under medication at the time of the study. Ten patients had no history of medication. All patients underwent detailed medical and neurological examinations that included blood tests, electrocardiography, echocardiography, brain CT and MRI. No focal abnormalities were found.

The CNS-control group consisted of 12 subjects with other neurodegenerative disorders (4 with spinocerebellar degeneration, 2 with amyotrophic lateral sclerosis, 3 with progressive supranuclear palsy, and 3 with cortico-basal degeneration) and 12 with

Received Dec. 8, 1997; revision accepted Aug. 4, 1998.
For correspondence or reprints contact: Akira Satoh, MD, Division of Neurology, Nagasaki Kita Hospital, 4-61 Nameshi 5-chome, Nagasaki 852, Japan.

cerebral infarction, 6 with vascular parkinsonism and 6 without it. The subjects with other neurodegenerative diseases included 4 men and 8 women, mean age 67.8 y (57–77 y). Mean disease duration was 62.2 mo (24–120 mo). The patients with cerebral infarction were 4 men and 8 women, mean age 73.9 y (66–89 y). Mean disease duration was 58.8 mo (38–96 mo). All control subjects underwent detailed medical and neurological examinations that included blood tests, electrocardiography, echocardiography, brain CT and MRI. No abnormalities on electrocardiography and echocardiography were found. We accepted 6 persons as normal controls who were suspected of having angina pectoris, but electrocardiography, echocardiography and coronary angiography proved that they had no cardiac disorders. These normal controls included 3 men and 3 women, mean age 58.8 y (48–69 y).

Methods

While the patient was at rest, 111 MBq (3 mCi) ^{123}I -MIBG were injected intravenously. Early and delayed images of the anterior view were obtained 15 min and 4 h after injection, respectively. Planar scans were made with a gamma camera equipped with a low-energy, high-resolution, parallel-hole collimator. To analyze the images, delayed uptake in the heart was divided into three categories: normal uptake, decreased uptake and no uptake (Fig. 1). MIBG uptake was quantified by calculating a heart-to-mediastinum count (H/M) ratio, drawing regions of interest over the mediastinum (10×10 mm) and whole heart on the anterior views of the thorax. Care was taken to exclude lung or liver from the myocardial region and to exclude large vessels and lung from the mediastinum region. To obtain the H/M ratio, average counts per pixel in the myocardium were divided by average counts per pixel in the mediastinum. The washout ratio was calculated with the following formula: (myocardial counts per pixel at 15 min – myocardial counts per pixel at 4 h) / myocardial counts per pixel at 15 min.

Statistical Analysis

All results were expressed as mean \pm SD and were analyzed by Student *t* test. Correlation analysis was performed by linear regression analysis. Statistical significance was defined as $P < 0.05$.

RESULTS

Semiquantitative Study

We used delayed images (4-h images) for semiquantitative study. Image quality and data acquisition for all patients with Parkinson's disease and control subjects were suitable for quantitative and semiquantitative analysis. Results of the semiquantitative analysis are shown in Figure 1. Of the 24 CNS-control subjects (patients with neurodegenerative diseases or CI), 21, and all 6 normal control subjects, showed a homogeneous, intense uptake of MIBG, with a slight decrease toward the apex of the heart, as has been reported in a normal population (13). Three CNS-control subjects showed decreased MIBG uptake, but no CNS-control subject showed no uptake. In contrast, 27 of the 35 patients with Parkinson's disease showed no uptake, 4 decreased and 4 normal uptakes.

Quantitative Analysis

The H/M and washout ratios are shown in Figure 2. The H/M ratio for Parkinson's disease was significantly lower ($P < 0.001$) than the ratio for the CNS-control subjects in both the early and delayed images. The washout ratio for Parkinson's disease was significantly higher ($P < 0.001$) than that for the CNS-control subjects.

H/M Ratio and Parkinson's Disease Severity

The H/M ratio for the patients with Parkinson's disease was significantly lower ($P < 0.001$) than that for the control subjects; whereas, the H/M ratio for the patients with Parkinson's disease HY I did not differ markedly from that for the CNS-control subjects. The H/M ratio for the patients with Parkinson's disease HY II was significantly lower ($P < 0.001$) than that for the CNS-control subjects and significantly higher ($P < 0.001$) than the ratios for the patients with Parkinson's disease HY III, IV and V. No significant difference in the H/M ratio was found in patients with Parkinson's disease HY III, IV and V (Fig. 3).

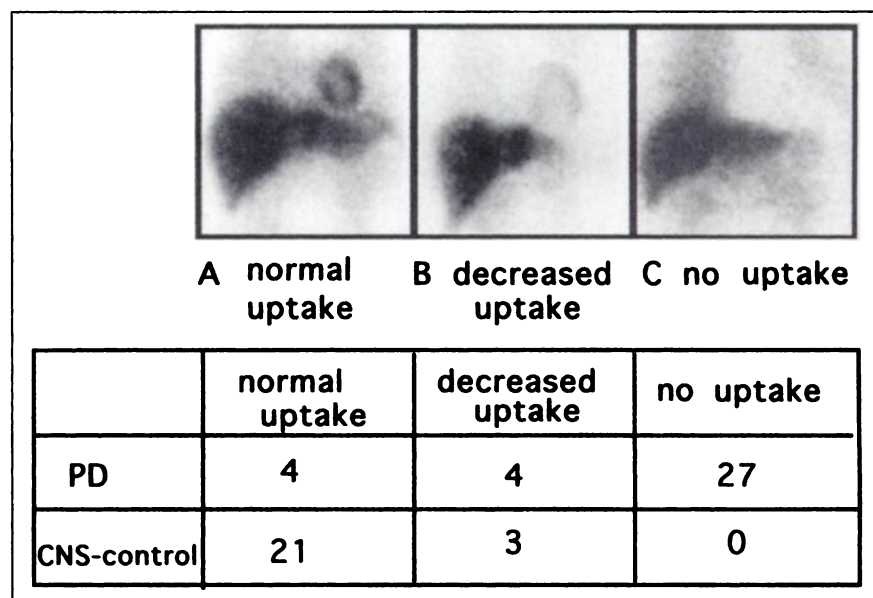


FIGURE 1. Upper panel: Anterior planar scans obtained 4 h after injection of ^{123}I -MIBG. A, B and C indicate normal, decreased and no uptake, respectively. Lower panel: Number of Parkinson's disease patients and control subjects with each type of MIBG uptake.

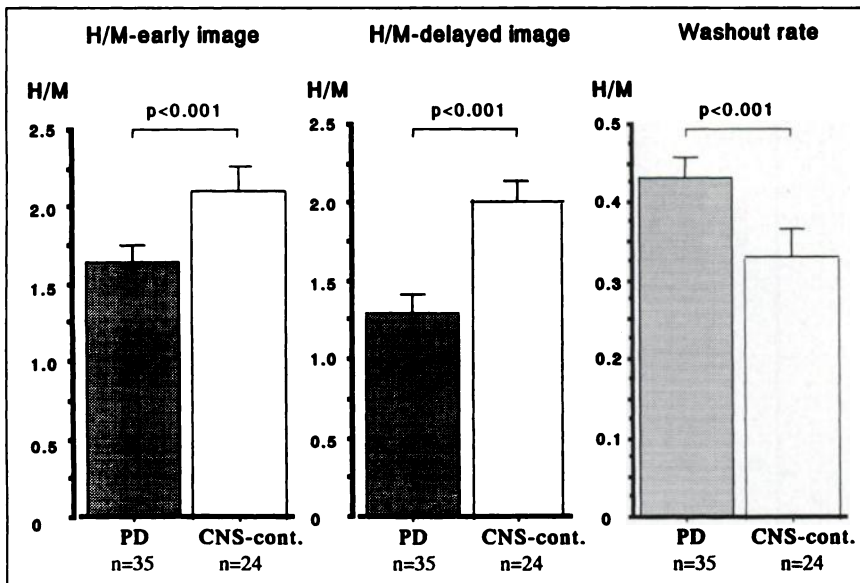


FIGURE 2. Heart-to-mediastinum (H/M) ratio in early (left) and delayed (center) images and washout ratio (right) in patients with Parkinson's disease and control subjects. Difference between patients with Parkinson's disease and control subjects is significant for each item (mean \pm SD).

H/M Ratio and Disease Duration

For the patients with Parkinson's disease there was slight relationship between the H/M ratio and disease duration ($r = -0.418$, $P < 0.05$) (Fig. 4). The duration of Parkinson's disease usually was short in patients with a high H/M ratios, with some exceptions. This suggests that certain patients have a marked decrease in myocardial MIBG uptake shortly after the onset of Parkinson's disease.

H/M Ratio and Medication

As shown in Figure 4, 5 unmedicated patients with Parkinson's disease had low H/M ratios compared with the control subjects. This indicates that even unmedicated

patients with Parkinson's disease had marked reduction of myocardial MIBG uptake and that antiparkinson drugs do not affect myocardial MIBG uptake in patients with Parkinson's disease.

DISCUSSION

This study clearly shows there was marked reduction in, or loss of, myocardial MIBG uptake in patients with Parkinson's disease, except those at stage HY I, and that there was reduced uptake even in patients with a short history of Parkinson's disease. Anti-parkinsonian drugs had no effect on the uptake of MIBG in the myocardium.

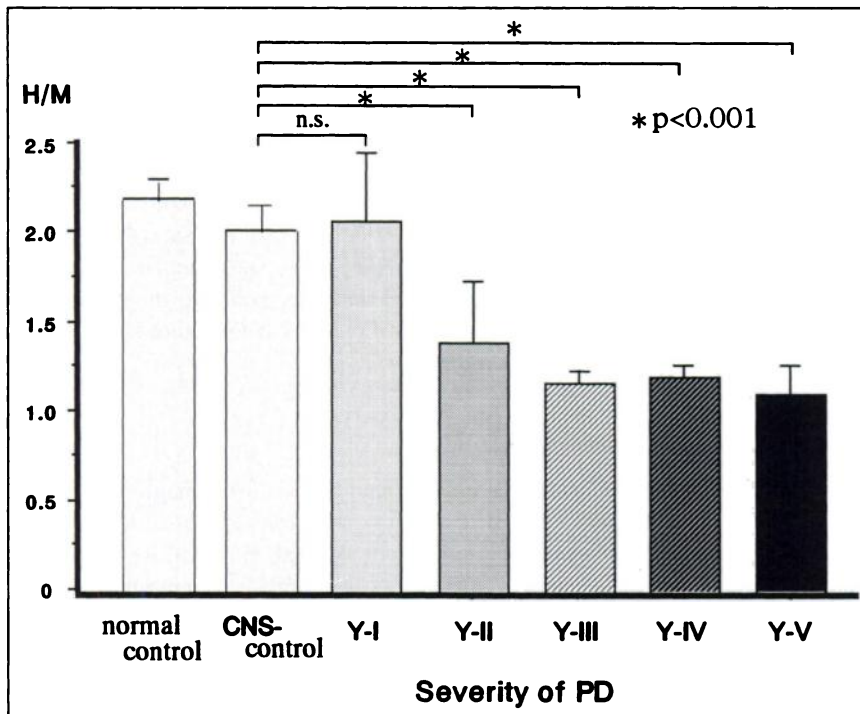
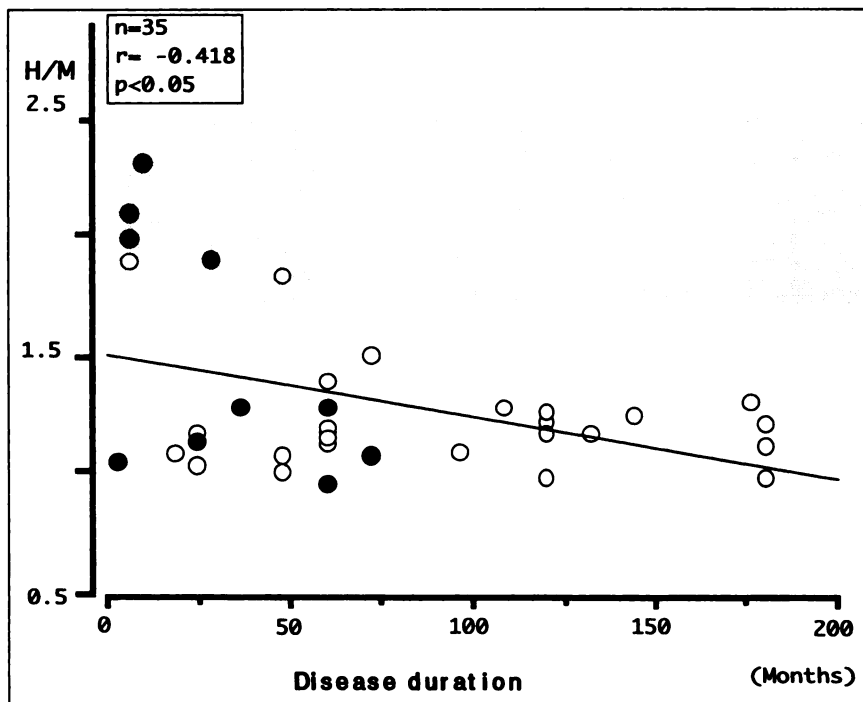


FIGURE 3. Heart-to-mediastinum (H/M) ratio and Parkinson's disease (PD) severity. H/M ratio for patients with HY I stage Parkinson's disease did not differ significantly from values for control subjects, but H/M ratio for patients with HY II stage Parkinson's disease was significantly lower than that for control subjects and significantly higher than ratios for patients with HY III, IV and V Parkinson's disease.

FIGURE 4. Correlation between heart-to-mediastinum (H/M) ratio and disease duration. Filled circles: unmedicated patients with Parkinson's disease; open circles, medicated ones. There is slight inverse correlation between H/M ratio for patients with Parkinson's disease and disease duration. Some patients, however, showed marked reduction of myocardial MIBG uptake shortly after onset of Parkinson's disease. Even unmedicated patients with Parkinson's disease had marked reductions in myocardial MIBG uptake. Shaded area represents mean \pm 2 SD of H/M ratio for control subjects.



Noninvasive imaging with radioiodinated MIBG can assess efferent adrenergic neuronal function in the heart. It competes with norepinephrine for neuronal uptake (uptake-1) and is taken up by a low-affinity non-neuronal mechanism (uptake-2) (16). Denervated myocardium treated with epicardial phenol and subjected to ganglionectomy showed a decrease in tissue norepinephrine and MIBG (17). These experimental findings suggest that MIBG uptake reflects the actual adrenergic neuronal function in the myocardium in vivo. In these studies, decreased myocardial MIBG accumulation clearly coincided with the denervated areas of the myocardial sympathetic nerves. Furthermore, radiolabeling with ^{123}I facilitates the use of the standard gamma camera in a clinical setting, as documented by a variety of patient studies. Even normal subjects show reduced MIBG uptake at the cardiac apex and septum (13). Decreased accumulation of myocardial MIBG has been reported in myocardial infarction (18), transplanted hearts (19), cardiomyopathy (20), heart failure (21) and familial amyloidotic polyneuropathy (11). In this study, none of the Parkinson's disease patients with defective MIBG uptake showed ischemic heart disease, cardiomyopathy or heart failure in their physical examinations, chest radiographs, electrocardiograms and echocardiographs. Various symptoms associated with autonomic dysfunction are usually present in the advanced stages of Parkinson's disease (1-5).

In this study, markedly reduced MIBG uptake was seen even in patients at stage HY II and in patients without signs or symptoms of autonomic dysfunction. This indicates that cardiac sympathetic denervation may occur in the early stage of Parkinson's disease and that myocardial imaging

with ^{123}I -MIBG is a sensitive method for detecting cardiac sympathetic denervation in patients with Parkinson's disease.

In Parkinson's disease, Lewy bodies (LBs) are present in the substantia nigra and locus caeruleus and are distributed widely throughout the central and peripheral nervous systems (6,7). Wakabayashi et al. (22) and Wakabayashi (23), who examined the distribution of LBs in the peripheral autonomic system, found LBs in the cardiac plexuses and the nerves in the myocardium, which originate in the paravertebral sympathetic ganglia.

The manner in which myocardial MIBG uptake is markedly reduced in patients with Parkinson's disease, even during the fairly early stages, is unknown. None of the control subjects with other neurodegenerative diseases and vascular parkinsonism showed a marked reduction in myocardial MIBG uptake. Our findings indicate that reduced myocardial MIBG uptake is a phenomenon specific to Parkinson's disease and that it is useful in diagnosing this condition, particularly in patients who do not show typical signs and symptoms.

CONCLUSION

This article documented myocardial imaging with ^{123}I -MIBG in 35 patients with Parkinson's disease and 24 control subjects. The findings indicate that, in Parkinson's disease, a reduction in myocardial MIBG uptake is a common, specific phenomenon that can be used to detect cardiac autonomic dysfunction to diagnose Parkinson's disease, particularly in patients without typical signs and symptoms.

REFERENCES

1. Aminoff MJ, Wilcox CS. Assessment of autonomic function in patients with a parkinsonian syndrome. *BMJ*. 1971;4:80-84.
2. McDowell FH, Lee JE, Levodopa. Parkinson's disease and hypotension. *Ann Intern Med*. 1970;72:751-752.
3. Calne DB, Brennan J, Spiers ASD, Stern GM. Hypotension caused by L-dopa. *BMJ*. 1970;1:474-475.
4. Vanderhaegen JJ, Perrier O, Steron JE. Pathological findings in idiopathic orthostatic hypotension. *Arch Neurol*. 1970;22:207-214.
5. Micieli G, Martignoni E, Cavallini A, et al. Postprandial and orthostatic hypotension in Parkinson's disease. *Neurology*. 1987;37:386-393.
6. Den Hartog Jager WA, Bethrem J. The distribution of Lewy bodies in the central and autonomic nervous systems in idiopathic paralysis agitans. *J Neurol Neurosurg Psychiatry*. 1960;23:283-290.
7. Rajput AH, Rozdilky B. Dysautonomia in Parkinsonism: clinico-pathological study. *J Neurol Neurosurg Psychiatry*. 1976;39:1092-1100.
8. Wieland DM, Brown LE, Rogers L, et al. Myocardial imaging with a radioiodinated norepinephrine storage analog. *J Nucl Med*. 1981;22:22-31.
9. Kline RC, Swanson DP, Wieland DM, et al. Myocardial imaging in man with I-123-metaiodobenzylguanidine. *J Nucl Med*. 1981;22:129-132.
10. Dae MW, O'Connell JW, Botvinick EH, et al. Scintigraphic assessment of regional cardiac adrenergic innervation. *Circulation*. 1989;79:634-644.
11. Nakata T, Shimamoto K, Yonekura S, et al. Cardiac sympathetic denervation in transthyretin-related familial amyloidotic polyneuropathy: detection with iodine-123-MIBG. *J Nucl Med*. 1995;36:1040-1042.
12. Scisson JC, Schapiro B, Mayer L, et al. Metaiodobenzyl-guanidine to map scintigraphically the adrenergic nervous system in man. *J Nucl Med*. 1987;28:1625-1636.
13. Langer A, Freeman MR, Josse RD, Armstrong PW. Metaiodobenzylguanidine imaging in diabetes mellitus: assessment of cardiac sympathetic denervation and its relation to autonomic dysfunction and silent myocardial ischemia. *J Am Coll Cardiol*. 1995;25:610-618.
14. Hokusui S, Yasuda T, Yanagi T, et al. ¹²³I-myo-cardial scintigraphical analysis in patients with and without autonomic disorder. *Clin Neurol*. 1994;34:402-404.
15. Serita T, Irita A, Ueyama C, et al. Autonomic nervous function of the heart in patient with Parkinson's disease. *Ther Res*. 1995;16:60-64.
16. Tobes MC, Jaques S Jr, Wieland DM, Sisson JC. Effect of uptake-one inhibitors on the uptake of norepinephrine and metaiodobenzylguanidine. *J Nucl Med*. 1985;26:897-907.
17. Minardo JD, Tuli MM, Moch BH, et al. Scintigraphic and electrophysiological evidence of canine myocardial sympathetic denervation and innervation produced by myocardial infarction or phenol application. *Circulation*. 1988;78:1008-1019.
18. Stanton MS, Tuli MM, Radtke NL, et al. Regional sympathetic denervation after myocardial infarction in humans detected noninvasively using I-123-metaiodobenzylguanidine. *J Am Coll Cardiol*. 1989;14:1519-1526.
19. Marco TD, Dae M, Yuen-Green MSF, et al. Iodine-123 metaiodobenzylguanidine scintigraphic assessment of the transplanted human heart: evidence for late reinnervation. *J Am Coll Cardiol*. 1995;25:927-931.
20. Carrio I, Estorch M, Berna L, et al. Iodine-111-antimycin and iodine-123-MIBG studies in early assessment of doxorubicin cardiomyopathy. *J Nucl Med*. 1995;36:2044-2049.
21. Wakasugi S, Inoue M, Tazawa S. Assessment of adrenergic neuron function altered with progression of heart failure. *J Nucl Med*. 1995;36:2069-2074.
22. Wakabayashi K, Takahashi H, Ohama E, et al. Lewy bodies in the visceral autonomic nervous system in Parkinson's disease. In: Ikuta F, ed. *Neuropathology in Brain Research*. Amsterdam, The Netherlands: Excerpta Medica; 1991:133-141.
23. Wakabayashi K. Parkinson's disease: the distribution of Lewy bodies in the peripheral autonomic nervous system. *Brain Nerve*. 1993;45:965-971.