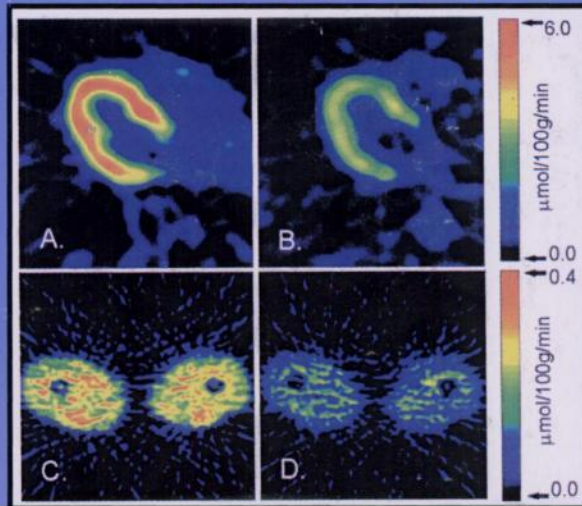
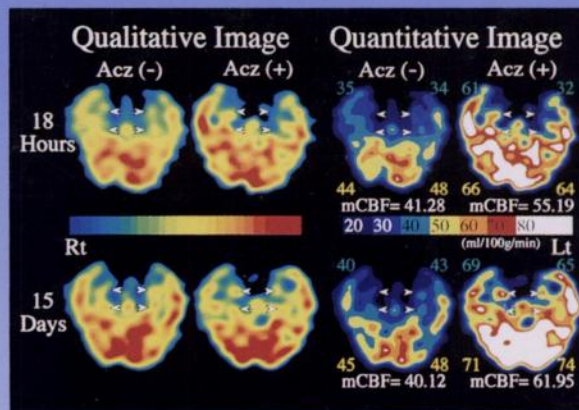


Quantitative Scintigraphy



Fluorine-18-FTHA metabolism in the myocardium (A,B) and skeletal muscles (C,D) measured during fasting (A,C) and following insulin infusion (B,D) in the same subject. See pages 1320-1327.



Resting and acetazolamide-challenged qualitative and quantitative rCBF images (^{99m}Tc -ECD) in a patient with transient global amnesia. See pages 1360-1362.

