

# Meckel's Diverticulum: Demonstration of Heterotopic Gastric Mucosa with Technetium-99m-Pertechnetate SPECT

Leonard P. Connolly, S. Ted Treves, Farshid Bozorgi and Stephen C. O'Connor

Division of Nuclear Medicine, Department of Radiology, Children's Hospital, Harvard Medical School, Boston, Massachusetts

Demonstration of functioning heterotopic gastric mucosa with  $^{99m}\text{Tc}$ -pertechnetate SPECT is reported. Abnormal tracer uptake was shown conclusively with SPECT but not with planar imaging. When a Meckel's diverticulum is suspected, we suggest SPECT be performed if the results of planar scintigraphy are equivocal and that it be considered if there is a high clinical suspicion and planar imaging is normal.

**Key Words:** Meckel's diverticulum; SPECT; technetium-99m-pertechnetate

**J Nucl Med 1998; 39:1458-1460**

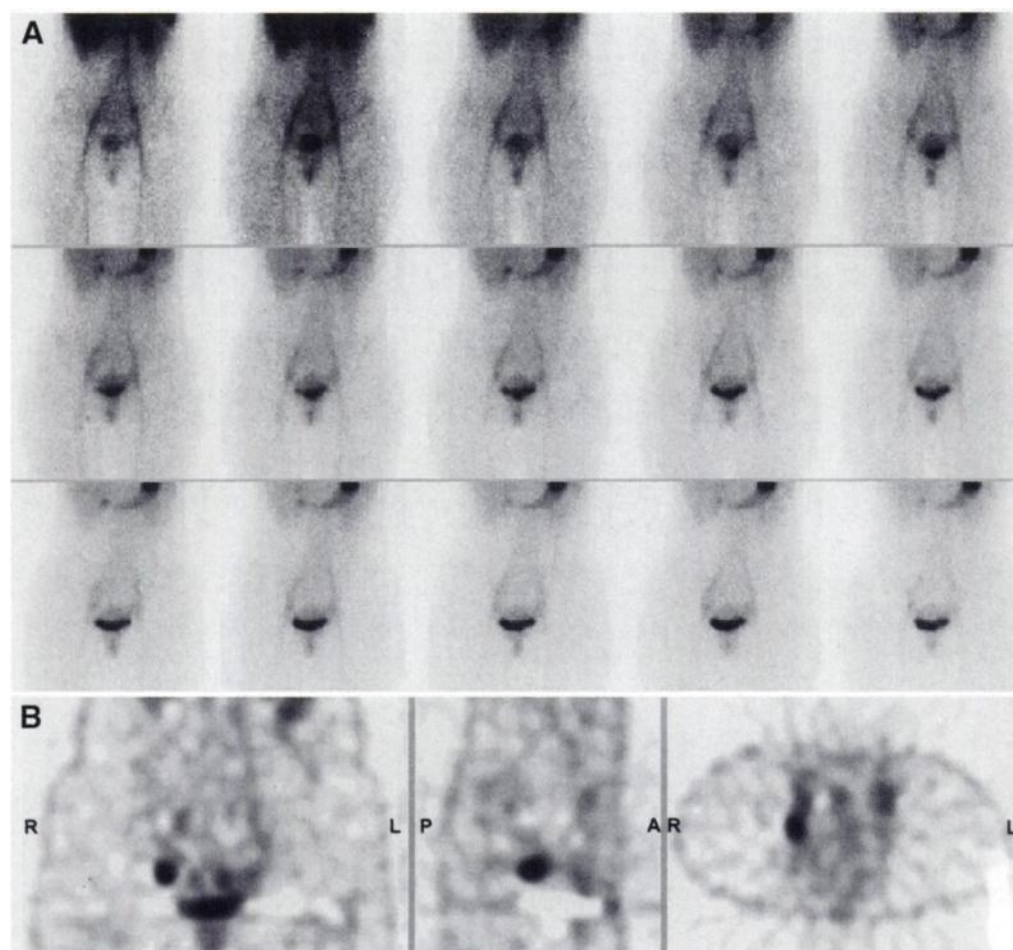
SPECT precisely depicts the distribution of a radionuclide within a volume of tissue. Uncertainty in localizing a site of abnormal radionuclide localization with planar imaging, which depicts tracer distribution two-dimensionally, can be largely

eliminated through SPECT. A wide variety of clinical applications have made use of the excellent contrast and superior anatomic localization provided by SPECT. In this report, we describe the use of SPECT in establishing a diagnosis of Meckel's diverticulum.

## CASE REPORT

The patient was an 18-yr-old woman with a documented history of three significant gastrointestinal (GI) bleeding episodes. The initial episode occurred at 6 mo, when the patient's mother noted the passing of tarry and maroon stools by the patient. Diagnostic evaluation, performed outside our institution, included barium enema, upper GI series with small bowel follow-through, sigmoidoscopy and  $^{99m}\text{Tc}$ -pertechnetate scintigraphy. A bleeding source was reportedly not identified. The patient remained well and asymptomatic throughout childhood with nearly annual hematocrit checks being within normal limits. At 17 yr, she experienced the abrupt onset of fatigue and exercise intolerance and a single

Received Aug. 5, 1997; revision accepted Nov. 11, 1997.  
For correspondence or reprints contact: Leonard P. Connolly, MD, Division of Nuclear Medicine, Children's Hospital, 300 Longwood Avenue, Boston, MA, 02115.



**FIGURE 1.** (A) Sequential 2-min anterior planar images depict possible focus of abnormal  $^{99m}\text{Tc}$ -pertechnetate uptake overlying right iliac vessels. (B) SPECT demonstrates this focus and delineates it from vascular structures. Intensity of tracer uptake in this focus, as depicted by SPECT, is equal to that in stomach. SPECT is displayed as coronal, sagittal and transverse images (R = right, L = left, P = posterior, A = anterior).

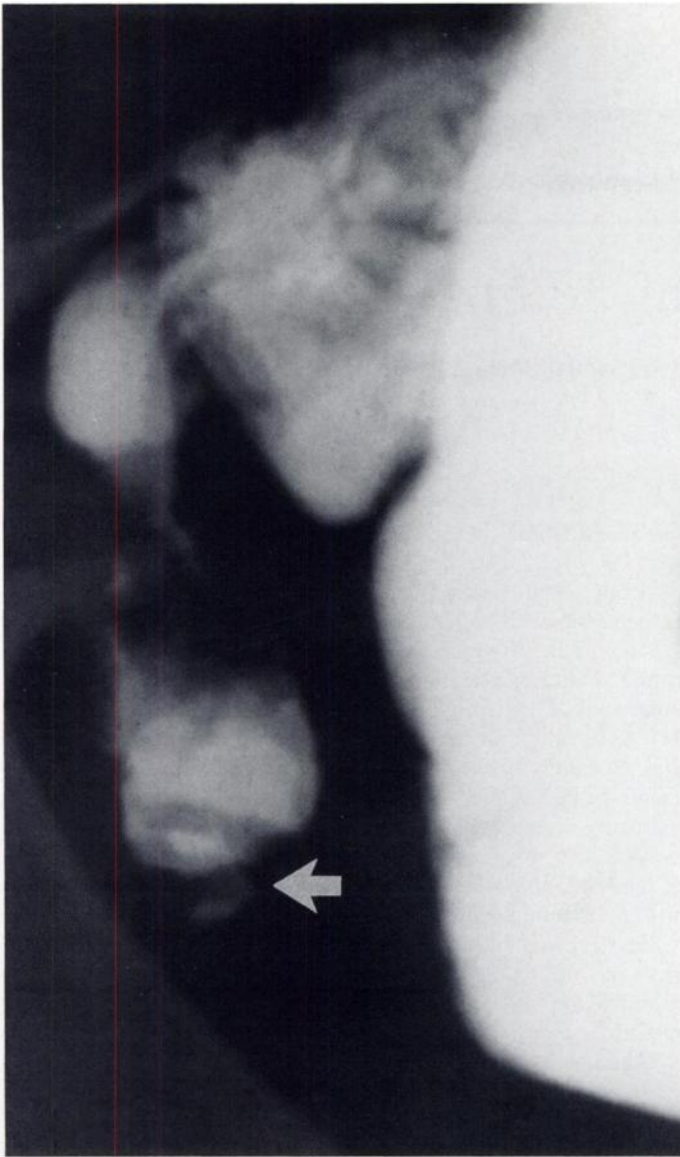


FIGURE 2. Spot film from small bowel series confirms presence of Meckel's diverticulum and shows ulceration (arrow) at its tip.

episode of bloody diarrhea. Evaluation by her primary physician revealed a normochromic, normocytic anemia with a hematocrit of 21. She promptly recovered from this episode and regained her strength. Her hematocrit returned to normal and a follow-up occult blood screen of her stool was negative. After passing a maroon stool and experiencing a syncopal episode at 18 yr, her evaluation again revealed a normocytic, normochromic anemia with a hematocrit of 27. Before referral to our institution, this patient had undergone upper endoscopy, colonoscopy and an upper GI series, which did not demonstrate a bleeding source. Technetium-99m-pertechnetate scintigraphy was performed due to suspicion that a Meckel's diverticulum with ectopic gastric mucosa was the cause of the bleeding. Planar images revealed a possible site of abnormal tracer localization overlying the iliac vessels in the right lower quadrant (Fig. 1A). Focal tracer localization that was clearly separate from vascular structures and was of qualitatively equal intensity to that observed in the stomach was demonstrated with SPECT (Fig. 1B). A small bowel follow-through, with fluoroscopy directed by the results of scintigraphy, showed a diverticulum with an ulceration at its distal aspect arising from the ileum (Fig. 2). A Meckel's diverticulum was surgically excised from the ileum at its site of origin approximately 2 ft proximal to the cecum. The

diverticulum measured 2 cm in length, had a 1-cm base and contained copious gastric mucosa. An ulceration was present at its tip.

### Imaging Technique

Pentagastrin (6  $\mu\text{g}/\text{kg}$ ) was administered subcutaneously 30 min prior to the tracer administration. The patient also received the  $\text{H}_2$ -receptor antagonist, ranitidine (150 mg, BID), for 7 days before scintigraphy at the discretion of her referring physician. The patient was positioned supine under a Siemens Orbiter (Siemens Gamma-sonics, Hoffmann Estates, IL) fitted with a high-resolution, parallel-hole collimator and  $^{99\text{m}}\text{Tc}$ -pertechnetate was administered intravenously in a dose of 3.7 MBq/kg. Acquisition of a series of 1-min planar images in the anterior projection was immediately begun and continued for 30 min. Immediately after planar imaging, SPECT was performed using a triple-detector gamma camera (Siemens Multispect 3) fitted with a high-resolution collimator. One-hundred twenty projections (40/detector) of 30-sec duration were acquired over a  $360^\circ$  noncircular orbit using a  $128 \times 128$  matrix. Images were reconstructed using Butterworth filtered backprojection with a cutoff frequency of 0.5 cycles/cm.

### DISCUSSION

Technetium-99m-pertechnetate scintigraphy is the imaging study of choice for evaluating children with GI bleeding in whom a Meckel's diverticulum is suspected (1). Cumulative experience with this technique has shown it to carry a 90%–98% accuracy, an 85% sensitivity and a 95% specificity for detecting heterotopic gastric mucosa (2). Various pharmacological interventions, including pentagastrin (3,4), histamine  $\text{H}_2$ -receptor antagonists (5) and glucagon (6) have been applied to optimize the results of  $^{99\text{m}}\text{Tc}$ -pertechnetate scintigraphy.

In the case described here, SPECT was used to detect  $^{99\text{m}}\text{Tc}$ -pertechnetate uptake in a Meckel's diverticulum that was not demonstrated by planar imaging. SPECT enhanced the contrast between focal  $^{99\text{m}}\text{Tc}$ -pertechnetate uptake in the diverticulum and tracer localized within the soft tissues, small bowel and vascular structures. The anatomic resolution provided by SPECT distinguished abnormal  $^{99\text{m}}\text{Tc}$ -pertechnetate accumulation in the Meckel's diverticulum from tracer in adjacent vascular structures. SPECT, but not planar imaging, showed uptake in the heterotopic gastric mucosa to be qualitatively identical to that observed in the stomach.

This case shows that  $^{99\text{m}}\text{Tc}$ -pertechnetate uptake in the heterotopic gastric mucosa of a Meckel's diverticulum can be seen to greater advantage with SPECT than with planar imaging. Whether SPECT enables detection of smaller amounts of gastric mucosa than the  $1 \text{ cm}^2$  that is estimated to be required for identification with planar scintigraphy (6) is uncertain. This prevents us from advocating the routine use of SPECT for all cases in which a Meckel's diverticulum is considered. We suggest that SPECT is an adjunct tool for establishing the presence of a Meckel's diverticulum containing heterotopic gastric mucosa. SPECT should be performed in cases where the results of planar imaging are equivocal and should be considered in cases where there is a high clinical suspicion and planar imaging is interpreted as normal.

### REFERENCES

1. Rossi P, Gourtsoyiannis N, Bezzi M, et al. Meckel's diverticulum: imaging diagnosis (review). *Am J Roentgenol* 1996;166:567–573.
2. Sfakianakis GN, Conway JJ. Detection of ectopic gastric mucosa in Meckel's diverticulum and in other aberrations by scintigraphy: I. pathophysiology and 10-year clinical experience. *J Nucl Med* 1981;22:647–654.

3. Treves ST, Grand RJ, Eraklis AJ. Pentagastrin stimulation of technetium-99m uptake by ectopic gastric mucosa in a Meckel's diverticulum. *Radiology* 1978; 128:711-712.
4. Khettery J, Effmann E, Grand RJ, Treves ST. Effect of pentagastrin, histalog, glucagon, secretin and perchlorate on the gastric handling of technetium-99m-pertechnetate in mice. *Radiology* 1976;120:629-631.
5. Diamond RH, Rothstein RD, Alavi A. The role of cimetidine-enhanced technetium-99m-pertechnetate imaging for visualizing Meckel's diverticulum. *J Nucl Med* 1991;32:1422-1424.
6. Sfakianakis GN, Anderson GF, King DR, Boles ET. The effect of intestinal hormones on the technetium-99m-pertechnetate imaging of ectopic gastric mucosa in experimental Meckel's diverticulum. *J Nucl Med* 1981;22:678-683.

## Adrenocortical SPECT Using Iodine-131 NP-59

Inku Hwang, Antonio G. Balingit, William J. Georgitis, James C. Sisson and Brahm Shapiro

*Nuclear Medicine and Endocrine and Metabolic Disease Services, Walter Reed Army Medical Center, Washington, DC; and Department of Internal Medicine, Division of Nuclear Medicine, The University of Michigan Medical Center, Ann Arbor, Michigan*

Adrenal scintigraphy with  $^{131}\text{I}$ -labeled 6-beta-iodomethyl-19-norcholesterol (NP-59) is a technically demanding and complex procedure. However, it can provide crucial and unique information about the functional status of the adrenal glands and guide the appropriate therapeutic management of patients with biochemically proven disease. Since the introduction of this new investigational drug, scintigraphic imaging has been performed using conventional planar techniques. We present an interesting case of primary aldosteronism in which planar scintigraphy and SPECT were combined in an attempt to increase the sensitivity of the study. SPECT revealed scintigraphic evidence of bilateral adrenocortical hyperplasia. Interestingly, the CT scan of this patient showed only an equivocal abnormality in the left adrenal gland, suggestive of an adenoma.

**Key Words:** primary aldosteronism; 6-beta-iodomethyl-19-norcholesterol; SPECT

**J Nucl Med 1998; 39:1460-1463**

Primary hyperaldosteronism is a rare cause of low-renin hypertension, representing only about 1% of hypertensive patients (1). It can result from a tumor (a benign unilateral adrenocortical adenoma in 75% of patients) or bilateral adrenal hyperplasia (2). Adrenal carcinoma is very rare (3,4). The distinction between different causes of primary aldosteronism is of utmost importance, because treatment options differ. Adrenal adenomas are best treated surgically, whereas adrenal hyperplasia is best treated by medical management (5). Radiopharmaceutical scintigraphy with dexamethasone-suppression technique has long been used to help differentiate between these causes using NP-59. The purpose of this pharmacological maneuver is to suppress the tracer into the large pool of cells that depend on adrenocorticotrophic hormone (ACTH) for function (zona fasciculata and zona reticularis) and in turn enable the detection of tracer in tumors or hyperplastic tissues that are small but ACTH independent in function located in the outer zone (zona glomerulosa) (6). We present a case in which planar scintigraphy and SPECT were combined to image a patient with biochemical evidence of hyperaldosteronism. The sensitivity of the test to detect disease was clearly increased by combining these techniques, and we have demonstrated that planar imaging alone may miss the correct diagnosis.

Received Aug. 20, 1997; revision accepted Nov. 20, 1997.

The opinions and assertions contained herein are the private views of the authors, and not to be construed as official or as reflecting the views of the Department of the Army or Department of Defense.

For correspondence or reprints contact: Antonio G. Balingit, MD, Nuclear Medicine Service, Department of Radiology, Walter Reed Army Medical Center, Washington, DC 20307-5001.

### CASE REPORT

A 59-yr-old man was referred to our endocrine service for evaluation and management of hypertension and hypokalemia. Hypertension had been present for 9 yr. Serum potassium level was 2.5 mmol/liter (normal 3.6-5.0 mmol/liter), accompanied by a serum aldosterone of 26.3 ng/dl (normal 7-30 ng/dl) and a urinary potassium of 111 mEq/liter 124 hr. (normal 43-217 mEq/liter/24 hr). A collection for urinary-free cortisol had normal results. There was no family history of hyperaldosteronism. Potassium supplements helped relieve malaise. He admitted having mild upper-extremity paresthesias but denied muscle weakness, cramping or polyuria. An abdominal ultrasound study had shown a 10.5-cm cyst in the left kidney and two small cortical cysts in the right kidney, with normal bilateral renal artery flow (not shown).

Physical examination revealed generalized obesity without stigmata of Cushing's syndrome and a self-reported weight of 704 kg (320 lb). Supine blood pressure was 164/81 mm Hg with a pulse rate of 76 bpm.

While taking 50 mg hydrochlorothiazide, 75 mg triamterene, 40 mEq potassium chloride, 50 mg atenolol and 2 mg daily terazosin, a profile consistent with primary hyperaldosteronism was noted. The aldosterone-to-plasma renin activity (PRA) ratio was 120 with a low PRA of 0.10 ng/ml/hr (low-renin hypertension <0.65 ng/ml/hr). To eliminate medication effects, a 2-liter intravenous saline infusion suppression test was performed after all antihypertensive drugs had been discontinued for 2 wk. Serum aldosterone was 25 ng/dl before and 12 ng/dl after the 4-hr infusion, demonstrating a failure to suppress below 5 ng/dl. Serum 18-hydroxycorticosterone was 75 ng/dl (normal 5-80 ng/dl). Plasma renin levels were again low at 0.15 and 0.10 ng/ml/hr.

A 24-hr urine aldosterone excretion collected for the period immediately after the saline loading was also elevated at 27.4  $\mu\text{g}/\text{dl}$  (normal 2.30-21  $\mu\text{g}/\text{dl}$ ). Suppression to <5  $\mu\text{g}/\text{dl}$  is expected with salt loading or mineralocorticoid suppression. Serum aldosterone and plasma renin were 34 ng/dl and 0.10 ng/ml/hr, respectively, while on adrenal-suppressive doses of dexamethasone. CT scan demonstrated a normal right adrenal gland and a lobulated left adrenal gland, 2 cm in thickest transverse dimension with areas of hypointensity consistent with an adrenal adenoma. The patient was then referred for adrenocortical scintigraphy.

### METHODS AND PROCEDURES

The patient was premedicated with 4 mg of dexamethasone orally in divided doses beginning 1 wk before and continuing throughout the imaging period, lasting 4 days postinjection. He was given 5 drops of Lugol's solution in a glass of water daily to block thyroidal uptake of free  $^{131}\text{I}$  on the day of dosing and continued for