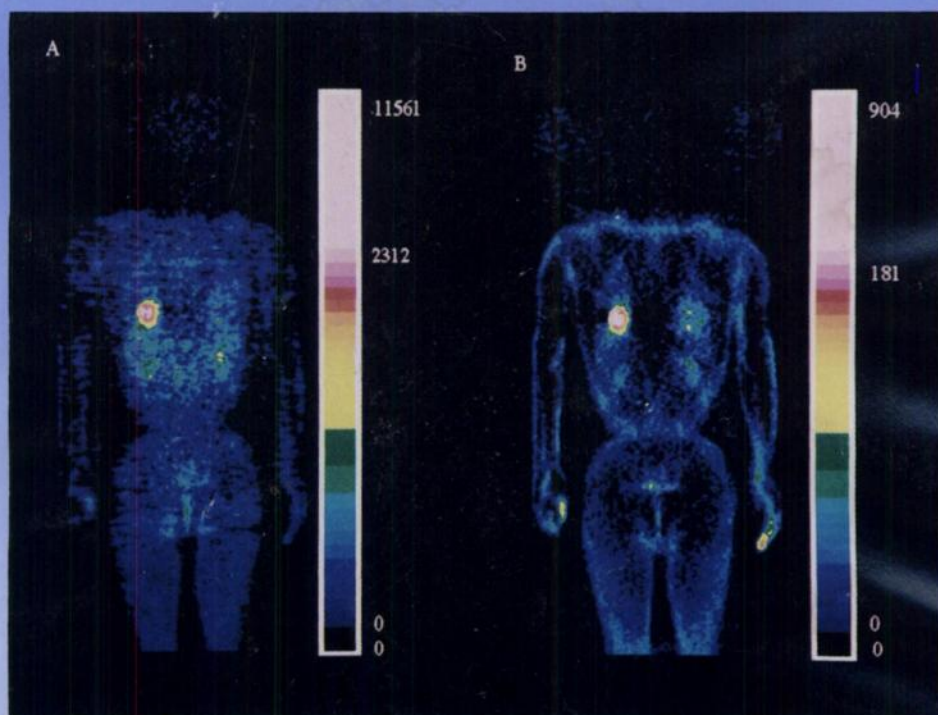

The Journal of Nuclear Medicine

JNM

Volume 39, Number 7 • July 1998



Attenuation-corrected (A) and uncorrected (B) ^{18}F -FDG images in a patient with adenocarcinoma of the lung. See pages 1219-1223.



The Official Publication of
the Society of Nuclear Medicine, Inc.
