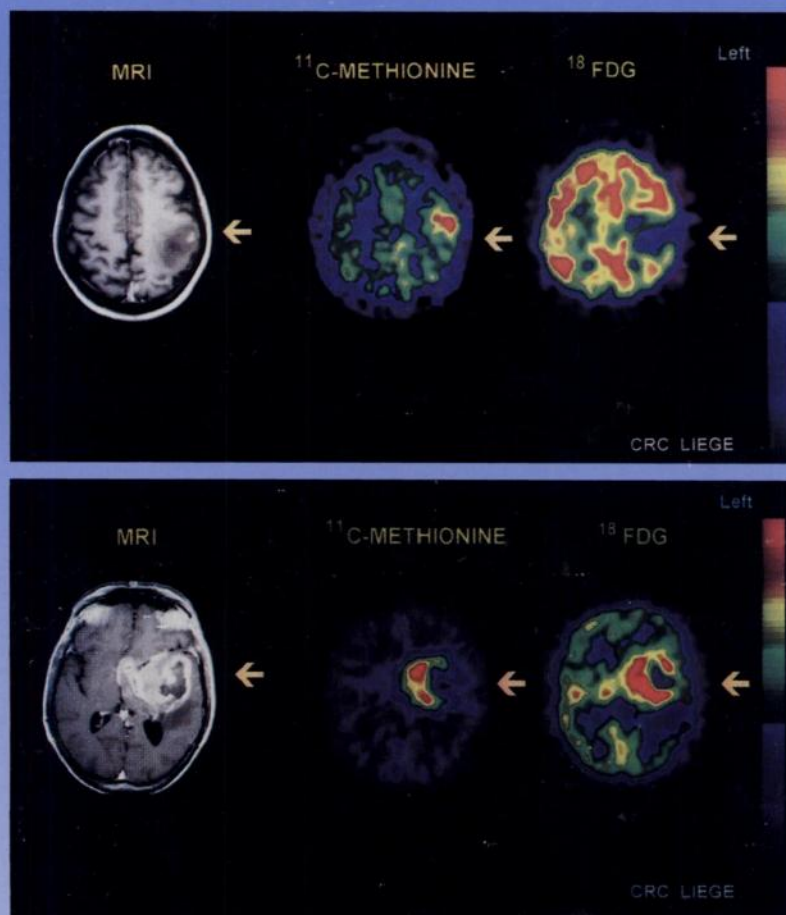

The Journal of Nuclear Medicine

JNM

Volume 39, Number 5 • May 1998



MRI (T1-weighted image after gadolinium injection), PET ¹¹C-methionine and ¹⁸F-FDG transverse sections in a patient with a Grade II astrocytoma (top) and in a patient with a Grade IV glioblastoma (bottom). See pages 778-785.



The Official Publication of
the Society of Nuclear Medicine, Inc.
