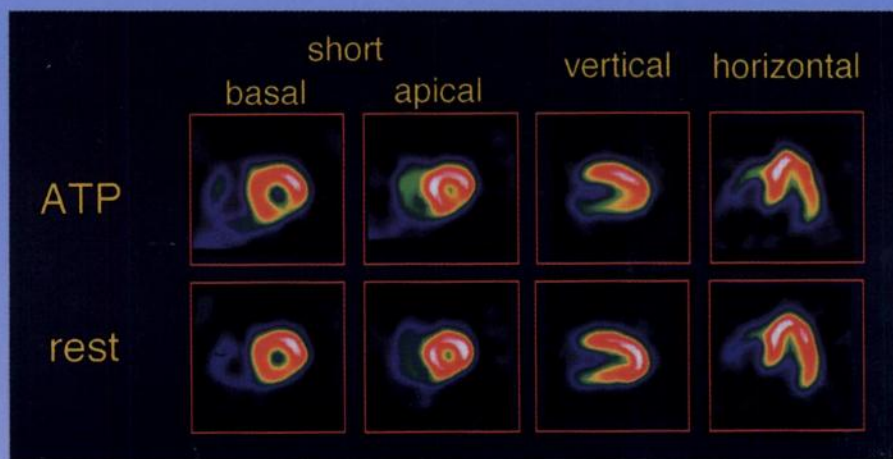

The Journal of Nuclear Medicine

JNM

Volume 39, Number 4 • April 1998



Myocardial SPECT images of ^{99m}Tc -tetrofosmin following an ATP infusion and at rest in a patient with severe stenosis of the circumflex branch of the LCA. See pages 582-586.



The Official Publication of
the Society of Nuclear Medicine, Inc.
