

Fluorine-18-Fluorodeoxyglucose Dual-Head Gamma Camera Coincidence Imaging of Recurrent Colorectal Carcinoma

Hussein M. Abdel-Dayem, Arthur I. Radin, Jian-Qiao Luo, Hillel Y. Marans, Steven Wong, Sleiman Y. Naddaf, Hossam M. El-Zeftawy, Walid S. Omar, Kumar Mithilesh, Hani Abujudeh and Saadat Atay

Nuclear Medicine Section, Departments of Radiology and Surgery, Section of Medical Oncology, Department of Medicine, St. Vincent's Hospital and Medical Center of New York; and New York Medical College, Valhalla, New York

We report our experience with coincidence detection imaging of ^{18}F -fluorodeoxyglucose (FDG) using a dual-head gamma camera. Scanning of the pelvis and abdomen of a patient with recurrent colorectal carcinoma showed recurrent disease in the pelvic floor and the base of the urinary bladder and metastatic disease in the retroperitoneal space of the pelvis. Although the tumor involving the bladder and pelvic floor was detected by CT and magnetic resonance imaging (MRI), metastatic spread to the retroperitoneal nodes on the left side was detected only by ^{18}F -FDG imaging. Based on the ultrasound, CT, MRI and cystoscopy, a local recurrence of cancer was presumed in our patient. An exploratory laparotomy was performed to resect the tumor in its entirety. At the time of surgery, the retroperitoneal metastasis in the pelvis was confirmed. Had the findings of the coincidence detection imaging study been considered, the patient would have been spared the surgical procedure.

Key Words: coincidence detection; fluorine-18-fluorodeoxyglucose; colorectal cancer

J Nucl Med 1998; 39:654-656

PET allows physicians to discriminate tissues based on metabolic activity rather than tissue density. It adds another dimension to the noninvasive evaluation of the oncology patient. PET imaging has been used to differentiate benign from malignant disease, to stage malignancies, to differentiate tumor recurrence from radiation necrosis or post-treatment fibrosis and to evaluate the response of cancer to therapy (1-12).

Until now, PET has been limited to those few centers that can afford the high cost of the PET system and cyclotron and also support the technical and professional staff required to operate this technology. Two recent approaches for imaging ^{18}F -fluorodeoxyglucose (FDG) apart from dedicated PET systems have been reported. The first is to use 511 keV collimators to image 511 keV photons in a manner similar to SPECT imaging of other radionuclides (13,14). This approach has the problems of decreased sensitivity and poor resolution (15). The second approach uses special electronic circuits on a fully digitized dual-head gamma camera (16,17). This approach is under clinical evaluation in the U.S. and Europe. Early results and comparisons with PET images are encouraging (18-20). The clinical indications for this new technology are being evaluated.

We present one of the earliest patients studied at our institution using this digitized dual-head coincidence imaging system. Our case illustrates how ^{18}F -FDG coincidence imaging, using this new technology, provided staging information that was not detected with any other imaging modality available. The information obtained by our ^{18}F -FDG study would have

altered this patient's care if it had been taken into consideration. We demonstrate how this new technology can improve the clinical management of patients at a substantial reduction in cost.

CASE REPORT

A 65-yr-old man presented in 1992 with Stage C-2 colorectal carcinoma that was locally invasive into the urinary bladder. At that time, he had a partial colectomy and a partial cystectomy followed by pelvic radiation. After this local cancer therapy, adjuvant chemotherapy with 5-fluorouracil (5-FU) and levamisole hydrochloride was administered for 1 yr. Chemotherapy was well tolerated, and he completed the full course of treatment. He remained in clinically complete remission for 4 yr.

In August 1996, he returned to our hospital in total renal failure, with profound anemia and chest discomfort. His laboratory data showed white blood cell count 2.3×10^3 , hemoglobin 8.6, hematocrit 24.4% and platelets 76,000. His electrolytes were abnormal, sodium 134 (n = 135-145), potassium 3.2 (n = 3.2-5.7), chloride 94 (n = 95-105), CO_2 16 (n = 25-32), blood urea nitrogen 22 (n = 10-20) and creatinine 8.5 (n = 0.7-1.4). His prostate-specific antigen and carcinoembryonic antigen were normal at 1.8 (n = 0-4) and 2.0 (n = 0-10), respectively. An ultrasound of the abdomen showed bilateral hydronephrosis with a mass of undetermined etiology infiltrating the right posterior bladder wall. A cystoscopy August 27, 1996, demonstrated a lesion invading the bladder trigone, which proved on biopsy to be an infiltrating intestinal-type adenocarcinoma with necrosis. A right percutaneous nephrostomy was performed on the same day, and a left percutaneous nephroureteral stent placement was performed 2 days later.

An abdominal CT scan August 30, 1996, demonstrated a mass contiguous with the posterior wall of the bladder that was thought to be a residual prostate gland versus recurrence of the colorectal cancer. On September 4, 1996, magnetic resonance imaging (MRI) showed probable tumor involvement of the base and left lateral wall of the bladder (Fig. 1). Abdominal and chest CT scans were negative for other masses. It appeared that the patient had a local recurrence of his colorectal cancer that might be amenable to pelvic exenteration and intraoperative radiotherapy. Surgical and radiation oncology consultations were requested, and surgery was scheduled for September 12, 1996.

Preoperatively, on August 10, 1996, an ^{18}F -FDG study was done. The patient was prepared for the study by overnight fasting. His whole blood glucose level before radiopharmaceutical injection, as determined by the Chemstrip/G method (Boehringer Mannheim Corp., Indianapolis, IN) was 120 mg/100 ml. At 1 hr postinjection of 5.0 mCi (185 MBq) ^{18}F -FDG intravenously, 64 projections of coincidence detection were obtained, 40 sec per projection, using a dual-head gamma camera (ADAC, Vertex,

Received Jun. 26, 1997; revision accepted Aug. 6, 1997.

For correspondence or reprints contact: Hussein M. Abdel-Dayem, MD, Professor of Radiology and Chief, Nuclear Medicine Service, St. Vincent's Hospital and Medical Center of New York, 153 West 11th St., New York, NY 10011.

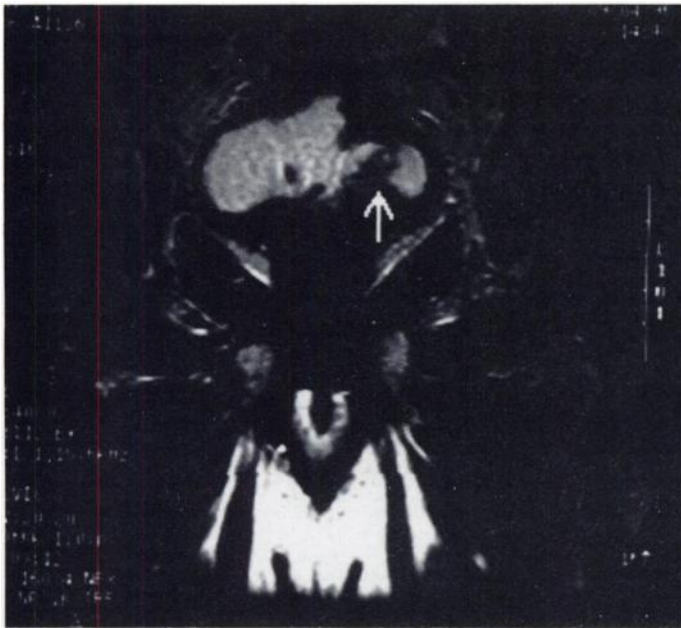


FIGURE 1. MRI of the pelvis demonstrates recurrent tumor in base of the bladder (arrow).

MCD version; Meliptas, San Francisco, CA). Two sweeps were obtained for the abdomen and pelvis in list mode. After rebinning, data are processed using a Butterworth filter, cutoff frequency was 0.35 and order 5. Data were displayed in transaxial, coronal and sagittal projections in three-pixel thickness. As shown in Figure 2, the study demonstrated evidence of recurrent disease in the posterior pelvis with invasion at the base of the bladder. In addition, a left pelvic retroperitoneal mass in the region of the internal iliac lymph nodes was detected.

On September 12, 1996, the patient underwent an exploratory laparotomy based on the ultrasound, CT and MRI studies. However, as demonstrated by the ^{18}F -FDG study alone, a mass was found in the region of the left internal iliac lymph nodes encasing the big vessels. It was decided the cancer was inoperable and only a colostomy and ileal conduit were performed. Biopsy of the retroperitoneal mass confirmed the presence of metastatic, moderately differentiated adenocarcinoma of the colon. This patient was referred to a medical oncologist and resumed chemotherapy. Had the findings of the ^{18}F -FDG study been considered reliable, his

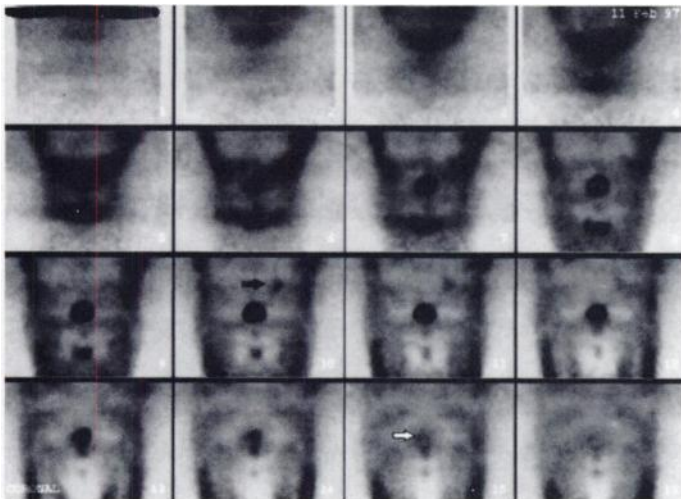


FIGURE 2. Fluorine-18-FDG coincidence imaging of the abdomen and pelvis demonstrates recurrent tumor in base of bladder (white arrow) and in left pelvic retroperitoneal node (black arrow).

oncologist would have deferred surgery and begun chemotherapy immediately for metastatic colorectal cancer.

DISCUSSION

The limitations of radiograph, CT and MRI in the postoperative follow-up of patients with malignant disease are hampered by the morphological changes after surgery. Metabolic imaging, especially with ^{18}F -FDG, is helpful in these clinical situations in addition to the other applications mentioned. Coincidence imaging technology using a dual-head gamma camera is new, and improvements in both acquisition and data processing continue to be made. The success of this technology will make coincidence ^{18}F -FDG imaging available to the vast majority of centers and will provide service to a much wider patient population.

The digital dual-head coincidence imaging system used for this patient can be acquired at an additional cost of \$200-\$250,000 U.S. dollars. This is a fraction of the cost of a dedicated PET system that requires a minimum investment of \$1.0-\$1.5 million U.S. dollars. To increase the sensitivity for coincidence detection, the 3/8-in. sodium iodine crystal of the dual-head gamma camera was replaced by a thicker crystal 5/8-in. thick. This increased crystal thickness was not associated with a decrease in sensitivity when used for routine nuclear medicine procedures.

In addition to the cost savings of this technology, a second advantage is the flexibility of the system, which may be used for routine nuclear medicine procedures as well as coincidence imaging studies. Another advantage is that it does not require special site preparation or personnel to run it as is the case with dedicated PET systems.

The fourth advantage of these new systems is the higher sensitivity and better resolution of the digital detectors. These advantages come at the cost of less resolution and lack of transmission imaging needed for attenuation correction.

New methods to acquire transmission imaging for coincidence imaging have been recently introduced but have not yet been tested in clinical trials. The case we are presenting demonstrates the success of this technology and its impact on patient management. After standard staging procedures including ultrasonography, CT and MRI, the patient was believed to have a local recurrence of his cancer at the base of the bladder and was taken to surgery in anticipation of pelvic exenteration. Had the presence of distant metastases or unresectable disease been documented preoperatively, the patient would have been treated instead by ureteral stents followed by a chemotherapy combination. The use of FDG imaging would have spared this patient the pain of exploratory surgery and a prolonged convalescence. Because this technology was still being evaluated clinically when the patient was seen, his surgery was required for verification of the results.

As this case also demonstrates, the improvement in staging cancer patients is cost effective as well. The ^{18}F -FDG scan would have added only \$1200 to \$1600 U.S. dollars to our patient's hospitalization, whereas the cost of his surgery and 5 days of postoperative care exceeded \$16,000 U.S. dollars.

CONCLUSION

Coincidence detection imaging is a promising technique. This report shows its feasibility and potentially wider availability as a new technology for ^{18}F -FDG imaging.

REFERENCES

1. Kim EE, Chung SK, Tillbury R, et al. Differentiation of residual or recurrent tumors for post treatment changes with PET using ^{18}F -FDG. *Radiographics* 1992;12(2):269-279.
2. Patz EF Jr, Lowe VJ, Hoffman JM, Paine SS, Harris LK, Goodman PC. Persistent or recurrent bronchogenic carcinoma: Detection with PET and 2-[^{18}F]-2 deoxy-D-glucose. *Radiology* 1994;191:379-382.
3. Ichiya Y, Kuwabara Y, Otsuka M, et al. Assessment of response to cancer therapy using fluorine-18-fluorodeoxyglucose and positron emission tomography. *J Nucl Med* 1991;32:1655-1660.
4. Bailey JW, Abemayor E, Jabour BA, et al. Positron emission tomography: a new, precise imaging modality for detection of primary head and neck tumors and assessment of cervical adenopathy. *Laryngoscope* 1992;102:281-288.
5. Stollfuss J, Glatting G, Friess H, Kocher F, Beger H, Reske SN. 2-[fluorine-18] fluoro 2-deoxy-D-glucose PET in detection of pancreatic cancer; value of quantitative image interpretation. *Radiology* 1995;195:339-344.
6. Wahl RL, Cody RL, Hutchins GD, Mudgett EE. Primary and metastatic breast carcinoma: initial clinical evaluation with PET with the radiolabeled glucose analogue FDG. *Radiology* 1991;179:765-770.
7. Okada J, Yoshikawa K, Imazeki K, et al. Positron emission tomography using fluorine-18-fluorodeoxyglucose in malignant lymphoma: a comparison with proliferative activity. *J Nucl Med* 1992;33:325-329.
8. Lapela M, Leskinen S, Minn H, et al. Increased glucose metabolism in untreated non-Hodgkin's lymphoma: a study with positron emission tomography and fluorine-18-fluorodeoxyglucose. *Blood* 1995;9:3522-3527.
9. Rodriguez M, Rehn S, Ahlstrom H, Sundstrom C, Glimelius B. Predicting malignancy grade with PET in non-Hodgkin's lymphoma. *J Nucl Med* 1995;36:1790-1796.
10. Newman JS, Francis IR, Kaminski MS, Wahl RL. Imaging of lymphoma with PET with 2-(^{18}F)-fluoro-2 deoxy-D-glucose: correlation with CT. *Radiology* 1994;190:111-116.
11. Haberkorn U, Strauss LG, Dimitrakopoulou A, et al. PET studies of fluorodeoxyglucose metabolism in patients with recurrent colorectal tumors receiving radiotherapy. *J Nucl Med* 1991;32:148-149.
12. Rozental JM, Levine RL, Nickles RJ, Dobkin JA. Glucose uptake in glioma after treatment: A positron emission tomographic study. *Arch Neurol* 1989;46:1302-1307.
13. Martin WH, Delbeke D, Patton JA, et al. FDG-SPECT: correlation with FDG-PET. *J Nucl Med* 1995;36:988-995.
14. Van Ling A, Huijgens PC, Visser FC, et al. Performance characteristics of a 511-KeV collimator for imaging positron emission with a standard gamma camera. *Eur J Nucl Med* 1992;19:15-321.
15. MacFarlane DJ, Cotton L, Ackermann RJ, et al. Triple-head SPECT with 2-[fluorine-18] fluoro-2-deoxyglucose (FDG): initial evaluation in oncology and comparison with FDG PET. *Radiology* 1995;194:425-429.
16. Dran WE, Abbott FD, Nicloe MW, Mastin ST, Kuperus JH. Technology for FDG-SPECT with a relatively inexpensive gamma camera—work in progress. *Radiology* 1994;191:461-465.
17. Mertens JD, Bhend WL. Digital coincidence detection: a scanning VLSI implementation. *Conference Record of the IEEE NSS/MIC*. Orlando, FL; 1992:879-881.
18. Ziegler SI, Enterrotacher A, Boning G, et al. Performance characteristics of a dual head coincidence camera for the detection of small lesions [Abstract]. *J Nucl Med* 1997; 38(suppl):206.
19. Smith EM, McCroskey Wk, Vickers DS, et al. Simultaneous SPECT and coincidence imaging using a dual detector scintillation camera—works in progress. *J Nucl Med* 1997; 38(suppl):208.
20. Patton JA, Hefetz Y, Shane MD, et al. Measured coincidence imaging parameters of a clinical dual head scintillation camera. *J Nucl Med* 1997; 38(suppl):221.

Accumulation of Iodine-131-Iodocholesterol in Renal Cell Carcinoma Adrenal Metastases

Eriko Tsukamoto, Kazuo Itoh, Kakuko Kanegae, Shinya Kobayashi, Tomohiko Koyanagi and Nagara Tamaki
Department of Nuclear Medicine and Urology, Hokkaido University School of Medicine, Sapporo, Japan

Adrenocortical scintigraphy is a useful technique for differentiating between types of nonhyperfunctioning adrenal masses. Metastatic tumors do not normally accumulate radioiodocholesterol and show discordant uptake on scintigrams. We present two patients who showed accumulation of ^{131}I -6 β -iodomethyl-19-norcholesterol (NP59) in the adrenal metastases from renal cell carcinoma. In one patient with bilateral adrenal metastases, accumulation in the primary tumor as well as adrenal metastases was demonstrated. The adrenal metastases in both patients were resected and were histologically proven to be metastases from clear-cell renal carcinoma. Accumulation of NP59 in metastatic adrenal tumors, although a very rare finding, suggests a pitfall in the differential diagnosis of adrenal cortical tumors.

Key Words: adrenal metastases; adrenocortical scintigraphy; renal cell carcinoma; iodocholesterol

J Nucl Med 1998; 39:656-658

Adrenocortical scintigraphy is a useful tool for the differential diagnosis of nonhyperfunctioning adrenal masses (1-3). In patients with malignant neoplasms, it is crucial to distinguish between metastatic adrenal tumors and other benign tumors to assess tumor staging and plan further management. Accumulation in the adrenal gland decreases (discordant uptake) when it is replaced with neoplasms, because malignant and metastatic tumors do not accumulate the radiolabeled cholesterol analog (4,5). Although several cases of adrenal metastatic tumors

coexisting with an adenoma have been reported showing increased uptake (concordant uptake) on adrenocortical scintigraphy (6-8), no cases with concordant uptake have been reported in patients with only adrenal metastatic tumors.

We have performed adrenocortical scintigraphy on patients with malignant neoplasms for the evaluation of their adrenal tumors, seven of which were histologically proven to have had adrenal metastatic tumors. Of these patients, five showed discordant uptake consistent with cases in previous literature; the other two, however, demonstrated accumulation of radioiodocholesterol. We present these two cases and discuss the possibility of accumulation of NP59 in the malignant neoplasms.

CASE REPORTS

Patient 1

A 58-yr-old woman entered the hospital for resection of a left renal cell carcinoma (RCC). CT scan demonstrated a huge right adrenal mass and the left renal tumor (Fig. 1A). Hormonal measurements revealed no adrenocortical or medullary dysfunction. Adrenocortical scintigraphy was performed for the evaluation of the right adrenal tumor. She received 37 MBq of ^{131}I -6 β -iodomethyl-19-norcholesterol (NP59). Posterior and anterior abdominal images taken 8 days after injection demonstrated increased uptake (concordant uptake) in the right adrenal gland compared to the left side (Fig. 1B). In addition, diffuse distribution of radioactivity was shown in the vicinity of the left adrenal gland. This radioactivity persisted for 10 days after injection, suggesting radiotracer accumulation in some parts of the primary renal tumor. The right adrenal gland (7 \times 3 cm, 36 g) was resected and was histologically proven to be metastatic from the RCC (Fig. 2). No

Received Jul. 2, 1997; accepted Jul. 3, 1997.

For correspondence or reprints contact: Eriko Tsukamoto, MD, Department of Nuclear Medicine, Hokkaido University School of Medicine, Kita 15 Nishi 7 Kita-ku Sapporo, 060-8638, Japan.