

the radioiodine scan is negative and the thyroglobulin level is undetectable.

## REFERENCES

1. Larson SM. Cancer or inflammation? A holy grail for nuclear medicine. *J Nucl Med* 1994;35:1653-1655.
2. Grunwald F, Schomburg A, Bender H, et al. Fluorine-18 fluorodeoxyglucose positron emission tomography in the follow-up of differentiated thyroid cancer. *Eur J Nucl Med* 1996;23:312-319.
3. Gilliland BC, Mannik M. Rheumatoid arthritis. In: Isselbacher KJ, Adams RD, Braunwald E, Petersdorf RG, Wilson JD, eds. *Harrison's principles of internal medicine*, 9th ed. New York: McGraw-Hill;1980:1872-1880.
4. Lewis PJ, Salama A. Uptake of fluorine-18-fluorodeoxyglucose in sarcoidosis. *J Nucl Med* 1994;35:1647-1649.
5. Patz EF, Lowe VJ, Hoffman JM, et al. Focal pulmonary abnormalities: evaluation with fluorine-18-fluorodeoxyglucose PET scanning. *Radiology* 1993;188:487-490.
6. Okazumi S, Enomoto K, Fukunaga T, et al. Evaluation of the cases of benign disease with high accumulation on the examination of  $^{18}\text{F}$ -fluorodeoxyglucose PET. *Kaku Igaku* 1993;30:1439-1443.
7. Tahara T, Ichiya Y, Kuwabara Y, et al. High-fluorodeoxyglucose uptake in abdominal abscesses: a PET study. *J Comp Assist Tomog* 1989;13:829-831.
8. Sasaki M, Ichiya Y, Kuwabara Y, et al. Ring-like uptake of FDG in brain abscess: a PET study. *J Comp Assist Tomog* 1990;14:486-487.
9. Polisson RP, Schoenberg OI, Fischman A, et al. Use of magnetic resonance imaging and positron emission tomography in the assessment of synovial volume and glucose metabolism in patients with rheumatoid arthritis. *Arthritis Rheum* 1995;38:819-825.
10. Gupta NC, Maalof J, Gunel E. Probability of malignancy in solitary pulmonary nodules using fluorine-18-FDG and PET. *J Nucl Med* 1996;37:943-948.
11. Sisson JC, Ackermann RJ, Meyer MA, Wahl RL. Uptake of 18-fluoro-2-deoxy-d-glucose by thyroid cancer: implications for diagnosis and therapy. *J Clin Endocrinol Metab* 1993;77:1090-1094.
12. Joensuu H, Ahonen A. Imaging of metastases of thyroid carcinoma with fluorine-18-fluorodeoxyglucose. *J Nucl Med* 1987;28:910-914.

# Thallium-201 Uptake with Negative Iodine-131 Scintigraphy and Serum Thyroglobulin in Metastatic Oxyphilic Papillary Thyroid Carcinoma

Walter Harder, Peter Lind, Mario Molnar, Peter Mikosch, Iris Gomez, Hans Jürgen Gallowitsch, Ewald Kresnik, Oliver Unterweger and Hans Peter Dinges

Department of Nuclear Medicine and Special Endocrinology, Institute of Pathology, LKH Klagenfurt, Austria

We report a case of a 48-yr-old woman who underwent surgery because of papillary oxyphilic thyroid carcinoma pT3. After total thyroidectomy, we administered 2960 MBq  $^{131}\text{I}$  for ablation of the residual tissue. Initial follow-up visits showed no clinical, radiological or scintigraphic evidence of residual or metastatic thyroid tissue. Serum thyroglobulin levels (Tg) and  $^{131}\text{I}$  whole-body scintigraphy were negative. Three years after thyroidectomy, the patient experienced seizures, and as a consequence a brain tumor was removed. It was an undetected metastasis of the primary thyroid carcinoma. Histological examinations showed that neither the primary tumor nor the metastasis produced any Tg. With this fact in mind and the knowledge of negative  $^{131}\text{I}$  whole-body scans we had to concentrate on radiological (CT and MRI scans) and nonspecific scintigraphic methods such as  $^{201}\text{Tl}$  whole-body scintigraphy in our management of the patient. Further follow-up demonstrated multiple metastasis by  $^{201}\text{Tl}$  whole-body scan (mediastinum, bones and soft tissue), and most of them have been removed by surgery. This case report demonstrates that, in addition to  $^{131}\text{I}$  whole-body scans and measurement of serum Tg, the use of nonspecific tracers like  $^{201}\text{Tl}$  is important to detect  $^{131}\text{I}$  and/or Tg negative metastases.

**Key Words:** thallium-201; iodine-131; serum thyroglobulin; thyroid carcinoma; negative Tg expression

**J Nucl Med** 1998; 39:236-238

In the follow-up of differentiated thyroid carcinoma,  $^{131}\text{I}$  whole-body scan, ultrasonography of the neck, measurement of serum Tg levels and nonspecific radionuclides and tracers such as  $^{201}\text{Tl}$ ,  $^{99\text{m}}\text{Tc}$ -sestamibi or  $^{99\text{m}}\text{Tc}$ -tetrofosmin are in use. The combination of these methods is considered to give the best diagnostic results and the biggest benefit for the patient (1-7). Some studies emphasize the diagnostic capabilities of  $^{201}\text{Tl}$  scans in the management of patients with differentiated thyroid

carcinoma (8-12). It has been well known for years that there are some patients with elevated serum Tg, but negative, even post-therapeutic,  $^{131}\text{I}$  whole-body scans representing metastatic disease. Our case report refers to a patient in whom neither  $^{131}\text{I}$  whole-body scan nor increase in serum Tg gave evidence of developing metastases. Thallium-201 scans were the only nuclear medicine imaging techniques that showed pathologic uptake.

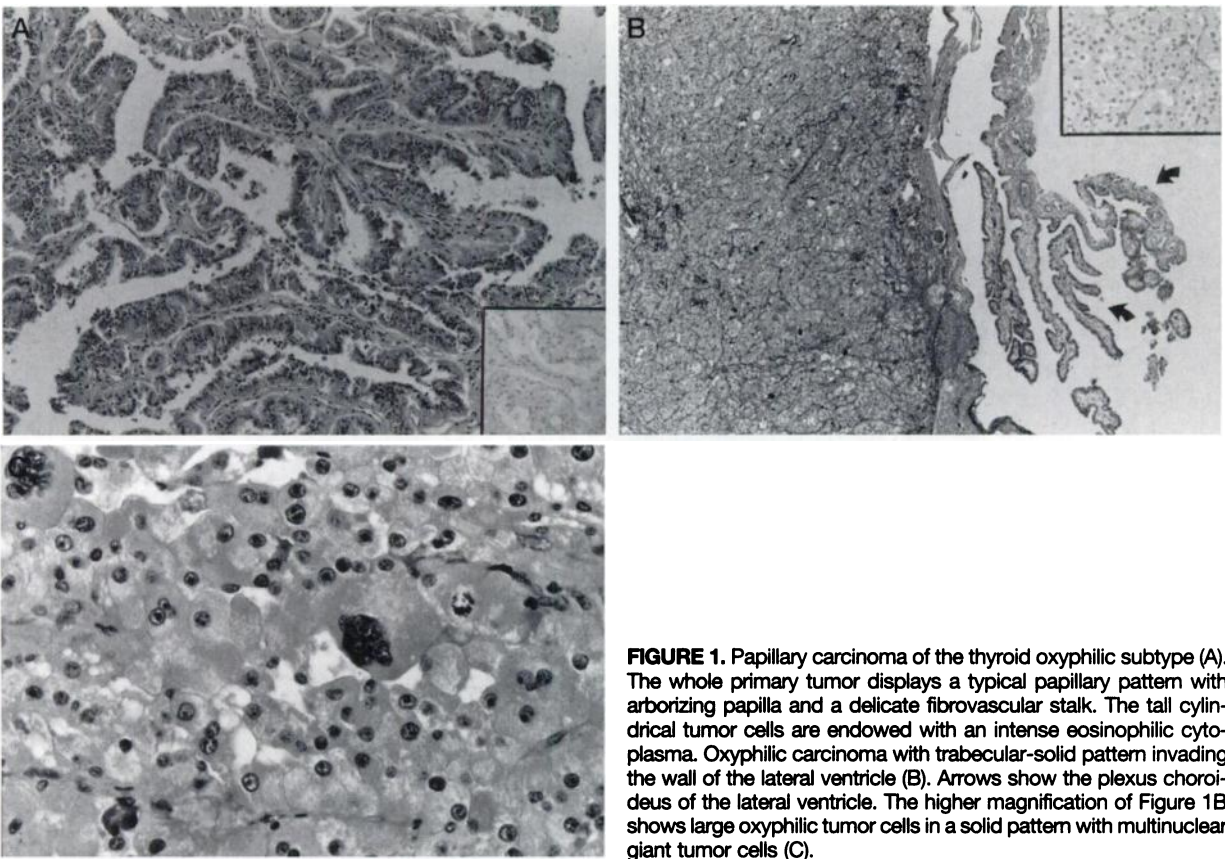
## CASE REPORT

A 48-yr-old woman was referred to our department after thyroidectomy because of a papillary oxyphilic carcinoma pT3. We administered an ablative  $^{131}\text{I}$  therapy with 2960 MBq. Iodine-131 whole-body scan showed uptake in the remnants but no pathological extrathyroidal uptake; the Tg serum measurement was also negative (<0,5 ng/ml, recovery 114% (Tg-Selco Medipan, Germany); functional assay sensitivity 0,5 ng Tg/ml). Clinical and radiological findings confirmed the absence of metastatic activity. During further follow-up 4 mo after radioiodine ablation of the remnant, no pathological  $^{131}\text{I}$  uptake was seen and the Tg level after withdrawing L-thyroxine treatment (bTSH >30 mU/l) was <0.5 ng/ml, indicating complete remission. Three years after thyroidectomy, the patient underwent brain surgery because of seizures, and a tumor was removed. Histological examination showed a metastasis of the primary thyroid carcinoma. Because of the absence of any signs of metastatic activity before brain surgery (negative  $^{131}\text{I}$  whole-body scan, negative Tg with a recovery between 70%-130% and negative Tg antibodies during the follow-up), we investigated the Tg expression on both the primary and the metastatic tumor (Fig. 1). Neither the primary carcinoma nor the brain metastasis produced any Tg.

For further follow-up, in addition to  $^{131}\text{I}$  whole-body scan and serum Tg measurement, we performed a  $^{201}\text{Tl}$  whole-body scan (20 min after intravenous injection of 74 MBq  $^{201}\text{Tl}$ ) using a dual-head, high-resolution camera. Only the  $^{201}\text{Tl}$  scan showed a pathological activity in the mediastinal region (Fig. 2). Findings were confirmed

Received Dec. 6, 1996; revision accepted Apr. 18, 1997.

For correspondence or reprints contact: Peter Lind, MD, Department of Nuclear Medicine and Special Endocrinology, LKH Klagenfurt, St. Veiterstr. 47 A-9020 Klagenfurt, Austria.



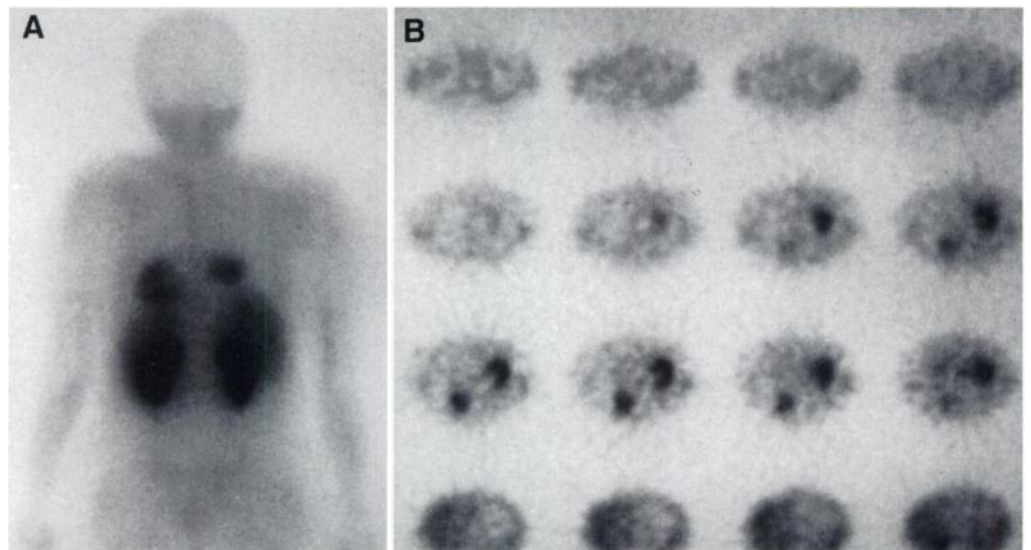
**FIGURE 1.** Papillary carcinoma of the thyroid oxyphilic subtype (A). The whole primary tumor displays a typical papillary pattern with arborizing papilla and a delicate fibrovascular stalk. The tall cylindrical tumor cells are endowed with an intense eosinophilic cytoplasm. Oxyphilic carcinoma with trabecular-solid pattern invading the wall of the lateral ventricle (B). Arrows show the plexus choroideus of the lateral ventricle. The higher magnification of Figure 1B shows large oxyphilic tumor cells in a solid pattern with multinuclear giant tumor cells (C).

by transmission CT (Fig. 3). With the knowledge of negative  $^{131}\text{I}$  uptake, the mediastinal metastasis was removed by surgery. Histology confirmed a metastasis of a papillary oxyphilic thyroid carcinoma without Tg expression. After surgery a  $^{201}\text{Tl}$  scan showed minimal residual activity in the mediastinum, and we decided to apply external radiation to the mediastinum.

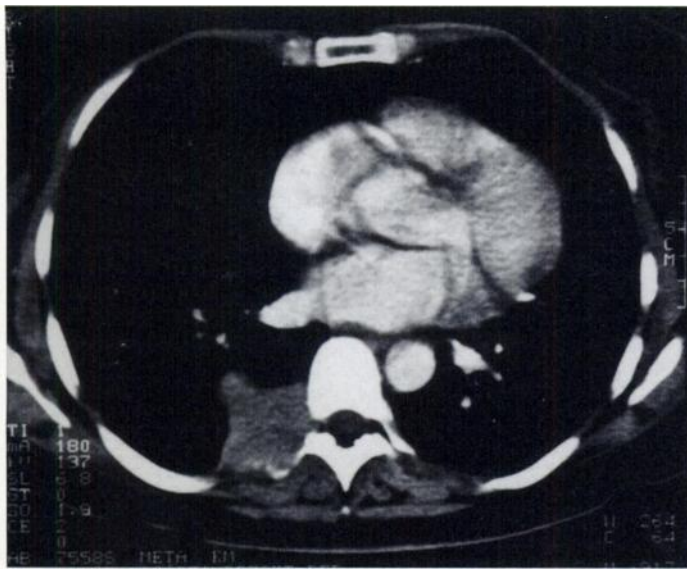
## DISCUSSION

In the follow-up of differentiated thyroid carcinoma,  $^{131}\text{I}$  whole-body scan, ultrasonography of the neck and measurement of serum Tg are well-established methods. The value of nonspecific radionuclides such as  $^{201}\text{Tl}$  or tracers like  $^{99\text{m}}\text{Tc}$ -sestamibi or  $^{99\text{m}}\text{Tc}$ -tetrofosmin is discussed controversially in the literature (2,3,8-16). For years, a negative  $^{131}\text{I}$  whole-body scan was regarded as a proof of cure. With the introduction of

sensitive Tg assays it became clear that there are discrepancies between the results of serum Tg and  $^{131}\text{I}$  whole-body scan (1,16). It is well accepted now that a rise in serum Tg is the most important indication of recurrent or metastatic disease even if the  $^{131}\text{I}$  whole-body scan is negative. In these patients, most physicians see the major role of nonspecific radionuclides and tracers to localize  $^{131}\text{I}$  negative lesions. Thallium-201, as a nonspecific tumor searching radionuclide, has been used for follow-up of differentiated thyroid carcinoma for years. Several studies were able to demonstrate the high sensitivity for detection of metastatic disease with  $^{201}\text{Tl}$ , and it is widely accepted now that nonspecific radionuclides or tracers are of clinical importance in patients with elevated serum Tg but negative  $^{131}\text{I}$  whole-body scan (9-12); even within one patient



**FIGURE 2.** Thallium-201 whole-body scintigraphy (posterior view 20 min after injection of 74 MBq) demonstrates a pathological uptake in the right mediastinum in addition to the physiological uptake in the heart, liver and kidneys (A). Transaxial SPECT slices clearly localizes the uptake in the right posterior mediastinum according to the metastasis originating from the  $^{131}\text{I}$  negative papillary oxyphilic thyroid carcinoma without thyroglobulin expression (B).



**FIGURE 3.** Transmission CT confirmed the scintigraphically detected lesion in the posterior mediastinum.

with some  $^{131}\text{I}$  positive metastases,  $^{201}\text{Tl}$  or other nonspecific tracers can detect additional  $^{131}\text{I}$  negative lesions (16,17).

### CONCLUSION

We report a patient with metastasizing papillary thyroid carcinoma oxyphilic subtype, in whom neither  $^{131}\text{I}$  whole-body scan nor measurement of serum Tg was able to indicate metastatic disease. The lack of  $^{131}\text{I}$  accumulation in differentiated thyroid carcinoma with oxyphilic subtype is well known (18,19). However, the additional absence of Tg expression, as demonstrated in this case, is a rare phenomenon. For patients with oxyphilic subtype and negative Tg expression,  $^{201}\text{Tl}$  or other nonspecific tracers may be the only tool to detect metastatic disease. Therefore,  $^{201}\text{Tl}$  whole-body scans or other nonspecific radionuclides should be used consistently in the postoperative follow-up, especially in patients with oxyphilic subtype of differentiated thyroid carcinoma and negative immunohistochemical Tg expression.

### REFERENCES

- Lubin E, Mechlis-Frsh S, Zatz S, et al. Serum thyroglobulin and iodine-131 whole-body scan in the diagnosis and assessment of treatment for metastatic differentiated thyroid carcinoma. *J Nucl Med* 1994;35:257-262.
- Van Sorge-Van Bortel RAJ, Van Eck-Smit BLF, Goslings BM. Comparisons of serum thyroglobulin, I-131 and Tl-201 scintigraphy in the postoperative follow-up of differentiated thyroid cancer. *Nucl Med Commun* 1993;14:365-372.
- Ugur Ö, Kostakoglu L, Caner B, et al. Comparison of Tl-201, Tc-99m-MIBI and I-131 imaging in the follow-up of patients with well-differentiated thyroid carcinoma. *Nucl Med Commun* 1996;17:373-377.
- Schlumberger M, Challeton C, De Vathaire F, et al. Radioactive iodine treatment and external radiotherapy for lung and bone metastases from thyroid carcinoma. *J Nucl Med* 1996;37:598-605.
- Lind P, Gallowitsch HJ. The use of nonspecific tracers in the follow-up of differentiated thyroid cancer: results with Tc-99m tetrofosmin whole-body scintigraphy. *Acta Med Austriaca* 1996;23:69-75.
- Franceschi M, Kusic Z, Franceschi D, et al. Thyroglobulin determination, neck ultrasonography and iodine-131 whole-body scintigraphy in differentiated thyroid carcinoma. *J Nucl Med* 1996;37:446-451.
- Ozata M, Suzuki S, Miyamoto T, et al. Serum thyroglobulin in the follow-up of patients with treated differentiated thyroid cancer. *J Clin Endocrinol Metab* 1994;79:98-105.
- Brendel AJ, Guyot M, Jeandot R, et al. Thallium-201 imaging in the follow-up of differentiated thyroid carcinoma. *J Nucl Med* 1988;29:1515-1520.
- Hoefnagel CA, Delprat CC, Marcuse HR, et al. Role of thallium-201 total-body scintigraphy in follow-up of thyroid carcinoma. *J Nucl Med* 1986;27:1854-1857.
- Ramanna L, Waxman A, Braunstein G. Thallium-201 scintigraphy in differentiated thyroid cancer: comparison with radioiodine scintigraphy and serum thyroglobulin determinations. *J Nucl Med* 1991;32:441-446.
- Burman KD, Anderson JH, Wartofsky L, et al. Management of patients with thyroid carcinoma: application of thallium-201 scintigraphy and magnetic resonance imaging. *J Nucl Med* 1990;31:1958-1964.
- Charkes ND, Vitti RA, Brooks K, et al. Thallium-201 SPECT increases detectability of thyroid cancer metastases. *J Nucl Med* 1990;31:147-153.
- Briele B, Hotze H, Kropp J, et al. Comparison of Tl-201 and Tc-99m MIBI in the follow-up of differentiated thyroid carcinoma. *Nuklearmedizin* 1991;30:115-124.
- Elser H, Henze M, Hermann C, et al. Follow-up of differentiated thyroid carcinoma by Tc-99m MIBI. *Nuklearmedizin* 1997;36:7-12.
- Klain M, Maurea S, Cuocolo A, et al. Tc-99m tetrofosmin imaging in thyroid diseases. Comparison with Tc-99m pertechnetate, thallium-201 and Tc-99m methoxyisobutylisonitrile scans. *Eur J Nucl Med* 1996;23:1568-1574.
- Lind P, Gallowitsch HJ, Langsteger W, et al. Technetium-99m tetrofosmin whole-body scintigraphy in the follow-up of differentiated thyroid carcinoma. *J Nucl Med* 1997 38:348-352.
- Nemec J, Zamrazil V, Pohunkova D, et al. The rationale use of Tl-201 scintigraphy in the evaluation of differentiated thyroid cancer. *Eur J Nucl Med* 1984;9:261-264.
- Reiners Ch, Schäffer R. Feasibility and limitations of radioiodine therapy in oxyphilic, medullary and anaplastic thyroid cancer. *Nuklearmediziner* 1991;14:37-43.
- Hamann A, Gratz KF, Soudah B, et al. Clinical behavior of oxyphilic thyroid carcinoma. *Nuklearmedizin* 1992;31:230-238.

## Visualization of Fibrous Dysplasia During Somatostatin Receptor Scintigraphy

Clara C. Chen, Frank S. Czerwiec and Penelope P. Feuillan

Department of Nuclear Medicine, Warren G. Magnuson Clinical Center and Developmental Endocrinology Branch, National Institute of Child Health and Human Development, National Institutes of Health, Bethesda, Maryland

Somatostatin receptor scintigraphy was performed on a patient with McCune-Albright syndrome and acromegaly. No evidence of pituitary disease was found, but uptake of  $^{111}\text{In}$ -pentetretotide was noted in areas of fibrous dysplasia. This uptake was not changed after 6 mo of octreotide therapy. The patient's bone disease also remained stable. The possible implications of these findings are discussed.

**Key Words:** indium-111-pentetretotide; fibrous dysplasia; McCune-Albright syndrome; somatostatin

**J Nucl Med 1998; 39:238-240**

Somatostatin receptor scintigraphy with  $^{111}\text{In}$ -pentetretotide (OctreoScan<sup>®</sup>), a labeled form of the somatostatin analog octreotide, is used primarily in localizing neuroendocrine tumors. Sensitivities of >90% have been reported for gastrinomas, paragangliomas and carcinoid tumors (1) and of 70%-75%

Received Jan. 16, 1997; accepted Apr. 23, 1997.

For correspondence or reprints contact: Clara C. Chen, MD, Department of Nuclear Medicine, Warren G. Magnuson Clinical Center, NIH, Building 10/1C401, 10 Center Drive MSC 1180, Bethesda, MD 20892-1180.