

---

The Journal of Nuclear Medicine

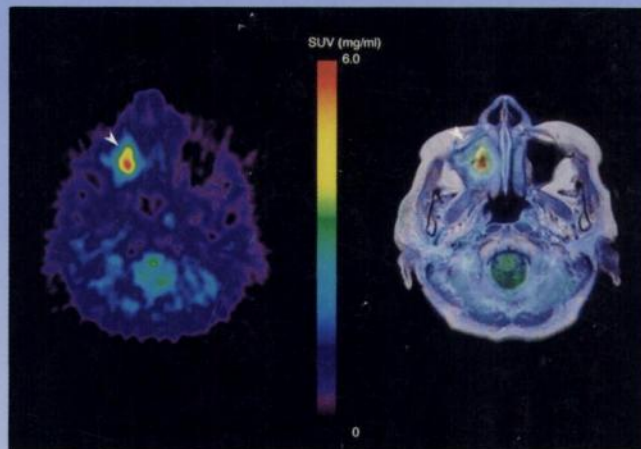
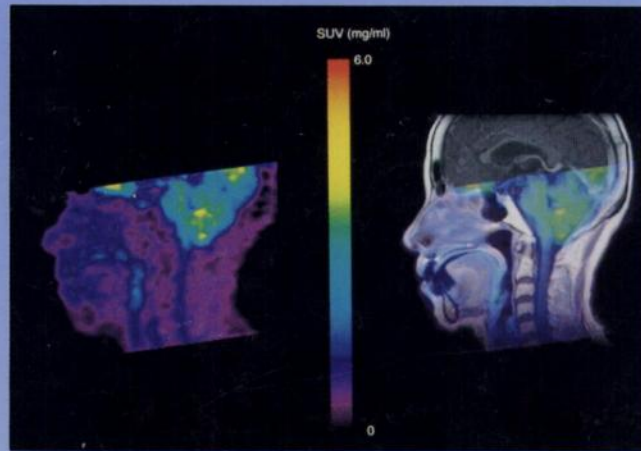
---

# JNM

---

Volume 39, Number 12 • December 1998

---



Midsagittal and transaxial FDG PET images of a patient with maxillary cancer and overlay on the coregistered MR image. See pages 2121-2127.



---

The Official Publication of  
the Society of Nuclear Medicine, Inc.

---