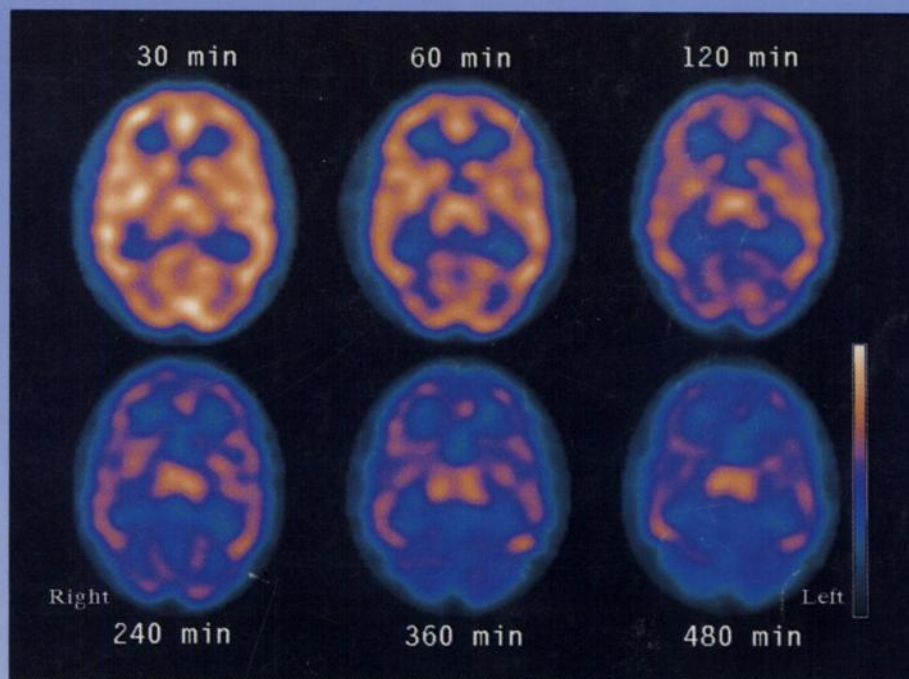

The Journal of Nuclear Medicine

JNM

Volume 38, Number 8 • August 1997



Serial ECD SPECT images (30–480 min postinjection) of a 32-yr-old woman at the level of the thalamus. Small but significant ECD activity clearance is apparent. See pages 1253–1260.



The Official Publication of
the Society of Nuclear Medicine, Inc.
