

7. Steele G Jr, Bleday R, Mayer R, Lindblad A, Petrelli N, Weaver D. A prospective evaluation of hepatic resection for colorectal carcinoma metastases to the liver: Gastrointestinal Tumor Study Group protocol 6584. *J Clin Oncol* 1991;9:1105-1112.
8. Granfield CAJ, Chamsangavej C, Dubrow RA, et al. Regional lymph node metastases in carcinoma of the left side of the colon and rectum: CT demonstration. *Am J Roentgenol* 1992;159:757-761.
9. Chamsangavej C, Whitley NO. Metastases to the pancreas and peripancreatic lymph nodes from carcinoma of the right colon: CT findings in 12 patients. *Am J Roentgenol* 1993;160:49-52.
10. McDaniel KP, Chamsangavej C, Dubrow R, Varma DGK, Granfield CAJ, Curley SA. Pathways of nodal metastases in carcinomas of the cecum, ascending colon and transverse colon: CT demonstration. *Am J Roentgenol* 1993;161:61-64.
11. Moss AA. Imaging of colorectal carcinoma. *Radiology* 1989;170:308-310.
12. Gupta NC, Frank AR, Mailliard J, Rysavy J, Chandramouli B, Boman B. Accurate detection of liver metastasis in patients with primary malignancies using PET-FDG imaging [Abstract]. *J Nucl Med* 1993;34:6P.
13. Nelson RC, Chezmar JL, Sugarbaker PH, Bernardino ME. Hepatic tumors: comparison of CT during arterial portography, delayed CT and MR imaging for preoperative evaluation. *Radiology* 1989;172:27-34.
14. Small WC, Mehard WB, Langmo LS, et al. Preoperative determination of the resectability of hepatic tumors: efficacy of CT during arterial portography. *Am J Roentgenol* 1993;161:319-322.
15. Soyer P, Levesque M, Elias D, Zeitoun G, Roche A. Detection of liver metastases from colorectal cancer: comparison of intraoperative US and CT during arterial portography. *Radiology* 1992;183:541-544.
16. Peterson MS, Baron RL, Dodd GD III, et al. Hepatic parenchymal perfusion detected with CTPA: imaging-pathologic correlation. *Radiology* 1992;185:149-155.
17. Miller EE, Simmons JT, Chang R, et al. Hepatic metastasis detection: comparison of three CT contrast enhancement methods. *Radiology* 1987;165:785-790.
18. Kim EE, Chung SK, Haynie TP, et al. Differentiation of residual or recurrent tumors from post-treatment changes with F-18 FDG PET. *Radiographics* 1992;12:269-279.
19. Yonekura Y, Benua RS, Brill AB, et al. Increased accumulation of 2-deoxy-2-[¹⁸F] fluoro-D-glucose in liver metastases from colon carcinoma. *J Nucl Med* 1982;23:1133-1137.
20. Flier JS, Mueckler MM, Usher P, Lodish HF. Elevated levels of glucose transport and transporter messenger RNA are induced by rats or src oncogenes. *Science* 1987;235:1492-1495.
21. Monakhov NK, Neistadt EL, Shavlovskil MM, et al. Physicochemical properties and isoenzyme composition of hexokinase from normal and malignant human tissues. *J Natl Cancer Inst* 1978;61:27-34.
22. Gupta NC, Omaha NE, Boman BM, et al. PET-FDG imaging for follow-up evaluation of treated colorectal cancer [Abstract]. *Radiology* 1991;181:199P.
23. Strauss LG, Clorius JH, Schlag P, et al. Recurrence of colorectal tumors: PET evaluation. *Radiology* 1989;170:329-332.
24. Vogel SB, Drane WE, Ros PR, Kerns SR, Bland KI. Prediction of surgical resectability in patients with hepatic colorectal metastases. *Ann Surg* 1994;219:508-516.
25. Falk PM, Gupta NC, Thorson AG, et al. Positron emission tomography for preoperative staging of colorectal carcinoma. *Dis Colon Rectum* 1994;37:153-156.
26. Ito K, Kato T, Tadokoro M, et al. Recurrent rectal cancer and scar: differentiation with PET and MR imaging. *Radiology* 1992;182:549-552.
27. Vitola JV, Delbeke D, Sandler MP, et al. Positron emission tomography to stage metastatic colorectal carcinoma to the liver. *Am J Surg* 1996;171:21-26.
28. Akhurst T, Scott AM, Berlangieri SU, et al. Validation of F-18 fluorodeoxyglucose-PET with surgical pathology in the detection of recurrent colorectal carcinoma [Abstract]. *J Nucl Med* 1996;37:131P.
29. Flanagan FN, Dehdashti F, Ogunbiyi OA, et al. The role of fluorine-18-fluorodeoxyglucose in advanced primary and recurrent colorectal cancer [Abstract]. *J Nucl Med* 1996;37:132P.
30. Valk PE, Abella-Columna E, Tesar RD, Pounds TR, Haseman MK, Myers RW. Diagnostic accuracy and cost effectiveness of whole-body PET-FDG imaging in recurrent colorectal cancer [Abstract]. *J Nucl Med* 1996;37:132P.
31. Scott AM, Akhurst T, Berlangieri SU, et al. Comparison of FDG-PET with computed tomography in the detection of recurrent colorectal carcinoma [Abstract]. *J Nucl Med* 1996;37:132P.
32. Hoffman EJ, Huang SC, Phelps ME. Quantitation in positron emission computed tomography: effect of object size. *J Comput Assist Tomogr* 1979;3:299-308.
33. Kubota K, Matsuzawa T, Fujiwara T, et al. Differential diagnosis of lung tumor with positron emission tomography: a prospective study. *J Nucl Med* 1990;31:1927-1933.

Arteriovenous Shunts in Patients with Hepatic Tumors

S. Ho, W.Y. Lau, W.T. Leung, M. Chan, K.W. Chan, P.J. Johnson and A.K.C. Li

Departments of Surgery, Clinical Oncology, Diagnostic Radiology and Organ Imaging,

The Chinese University of Hong Kong, Prince of Wales Hospital, Shatin, New Territories, Hong Kong

The study aimed to investigate the influence of tumor type, tumor size, tumor vascularity and treatment on arteriovenous shunts between the liver and lungs in patients with hepatic cancer. **Methods:** Our previous assessment of the degrees of lung shunting using intra-arterial ^{99m}Tc-macroaggregated albumin in 125 patients with hepatocellular carcinoma (HCC) was extended to include 377 patients with HCC and 25 patients with colorectal liver metastases. Patients were given 111 MBq (3 mCi) of ^{99m}Tc-macroaggregated albumin during hepatic angiography. The lungs and the liver were localized as regions of interest on the digitized gamma scintigraphic image. The total counts taken over the lungs divided by the total counts taken over both the lungs and the liver gave the percentage of lung shunting. Tumor size was measured by computerized tomography or ultrasound scan. Tumor vascularity was assessed based on the degree of neovascularization. Linear regression and Wilcoxon rank test were used for statistical analysis. **Results:** Patients with HCC had a higher median (7.6%) and a wider range (<1-75.4%) of percentages of lung shunting when compared with those with colorectal liver metastases (median, 4.7%; range, <1-23.9%). The lung shunting correlated with the tumor size in the 377 patients with HCC ($r = 0.359$; $p < 0.0001$). Excluding one outlier, we found a similar correlation in 24 patients with colorectal metastases ($r = 0.686$; $p < 0.0001$). In HCC, the mean lung shunting increased with increasing tumor size, up to 15 cm, and then remained almost unchanged, up to a size of >20 cm. The mean lung shunting also increased with increasing vascularity grades, as assessed by hepatic angiography. The difference between any two vascularity grades was statistically significant ($p = 0.0001-0.0148$). Similar

analysis by subgroups in colorectal liver metastases was impossible because of the small number of patients. Lung shunting decreased in HCC patients after the tumors were treated, but it might increase or decrease when the disease recurs. **Conclusion:** The lung shunting was influenced by the type, size and vascularity of the hepatic tumor. The change in lung shunting with the status of the tumor after treatment further suggests a neoplastic nature of the blood vessels involved in the arteriovenous shunt.

Key Words: lung shunting; factors; hepatic cancer

J Nucl Med 1997; 38:1201-1205

Regional targeted treatments for hepatic cancer aim at exposing the tumor to a high local concentration of cytotoxic agents, such as chemotherapeutic drugs or radioactive substances, including ¹³¹I-Lipiodol or ⁹⁰Y microspheres. Ideally, the agent should be concentrated in the tumor or at least be confined to within the liver. Shunting of part of the agent to neighboring organs, such as the lungs and the gastroduodenum, reduces the efficacy of the treatment and may cause damage to these organs when a radioactive substance is used.

Technetium-99m-macroaggregated albumin (^{99m}Tc-MAA), which has an average particular size close to that of ⁹⁰Y microspheres, has been widely used to assess the degree of shunting into the pulmonary circulation in metastatic liver tumors before treatment with ⁹⁰Y microspheres (1-5). Patients who have a high percentage of lung shunting and, thus, an increased risk of radiation pneumonitis (6) should be excluded from ⁹⁰Y microsphere therapy.

Lung shunting, as assessed by ^{99m}Tc-MAA, in 125 patients with hepatocellular carcinoma (HCC) has been analyzed and

Received Sep. 16, 1996; revision accepted Dec. 19, 1996.

For correspondence or reprints contact: W. Y. Lau, MD, Department of Surgery, The Chinese University of Hong Kong, Prince of Wales Hospital, Shatin, New Territories, Hong Kong.

reported from our center (7). The study has now been extended to include 377 patients with HCC and 25 patients with liver metastases from colorectal cancer. A comparison between the two types of tumors can thus be made. The increased number of HCC patients allows a more detailed analysis of the lung shunting in relation to tumor size and vascularity. Changes in the lung shunting after treatment also provided additional evidence of the nature of the blood vessels responsible for the arteriovenous shunts.

MATERIALS AND METHODS

The study included 377 patients with HCC. There were 331 men, aged 13–85 yr (mean \pm s.d. = 53.0 \pm 12.2), and 46 women, aged 25–73 yr (mean \pm s.d. = 56.9 \pm 13.5). The diagnosis of HCC was made by either histology or evidence of a space-occupying lesion in the liver upon radiological investigation in patients with serum alpha-fetoprotein of 500 ng/ml or more. The other 25 patients with colorectal cancer included in the study had liver metastasis only, and the primary cancer had been resected completely. There were 13 men, aged 35–70 yr (mean \pm s.d. = 58.8 \pm 11.2), and 12 women, aged 32–68 yr (mean \pm s.d. = 54.5 \pm 12.9). All the patients included in the study were being considered for selective internal radiotherapy of their malignant hepatic tumor using ^{90}Y microspheres and, therefore, had not been put on any medications that might significantly alter their arteriovenous shunts.

These patients underwent hepatic angiography (HAG) as part of an assessment for treatment. HAG was performed using the Seldinger technique. After the angiographic catheter had been placed selectively in the hepatic artery, 111 MBq (3 mCi) of $^{99\text{m}}\text{Tc}$ -MAA (with 80% of the particles being 10–60 μm in size and not greater than 150 μm in size; average size, 30 μm) were injected through the catheter into the liver. The catheter was then removed.

After hemostasis of the puncture site, the patient was transported to the gamma camera suite, and scintigraphic images of the lungs, liver and gastroduodenal regions were taken with an analog/digital gamma camera. Regions of interest were carefully drawn around the liver and lungs on the digitized images, and the percentage of activities shunted into the pulmonary circulation was calculated as the ratio of lung counts to total counts. Significant amounts of activity in any other organs, such as the gastroduodenum, were also considered.

Tumor sizes were measured by either computed tomography or ultrasound. The vascularity of the tumor on HAG was assessed by an interventional radiologist. Grading, on a scale from 0 (normal) to 4 (extremely hypervascular), was based on the following criteria:

- Grade 1: presence of mild tumor staining without an increase in the number of vessels;
- Grade 2: moderate tumor staining and an increased number of vessels;
- Grade 3: intense tumor staining and a marked increase in number of vessels, which were also dilated and tortuous;
- Grade 4: tumors having all the grade 3 characteristics together with venous pooling.

The degree of lung shunting was compared between sexes and correlated with the size and vascularity of the biggest tumor in the patient. Statistical methods for analysis included linear regression and the Wilcoxon rank test.

Patients with residual or recurrent diseases were reassessed for suitability of retreatment with selective internal radiotherapy, and the percentages of lung shunting were again measured after

TABLE 1
Lung Shunting as Determined by Technetium-99m-MAA

% lung shunting	No. of patients (%)
HCC	
<5.0	126 (33.4)
5.0–9.9	103 (27.3)
10.0–14.9	43 (11.4)
15.0–19.9	26 (6.9)
20.0–24.9	17 (4.5)
25.0–29.9	21 (5.6)
30.0–34.9	14 (3.7)
35.0–39.9	11 (2.9)
40.0–44.9	3 (0.8)
45.0–49.9	3 (0.8)
\geq 50.0	10 (2.7)
Total	377 (100)
Colorectal liver metastases	
<5.0	13 (52.0)
5.0–9.9	7 (28.0)
10.0–14.9	4 (16.0)
15.0–19.9	0 (0.0)
20.0–25.0	1 (4.0)
Total	25 (100)

infusion of $^{99\text{m}}\text{Tc}$ -MAA during HAG. These values were compared with the percentages before the initial treatment.

RESULTS

Comparison of Lung Shunting between Gender

The mean percentages of lung shunting for the 331 men and the 46 women with HCC were 12.8% and 11.2%, respectively, which were very similar, although the men showed a wider range (0–75.4%) than the women (0–52.7%). Among the patients with colorectal liver metastases, the mean percentages of lung shunting were similar for men and women (6.3% versus 7.1%, respectively), although in these patients, the women showed a wider range (2.9–23.9%) than the men (0%–14.8%).

Variation of Lung Shunting in HCC and Liver Metastases

The degree of lung shunting was found to vary between patients. The variation among the 377 patients with HCC was more remarkable than in the 25 patients with liver metastases from colorectal cancer (mean \pm s.d. = 12.6% \pm 13.3% for HCC and 6.7% \pm 5.4% for liver metastases). In the HCC patients, the percentage of lung shunting ranged from less than 1% to 75.4%, with a median of 7.6%. The range for the 25 cases of liver metastases was from less than 1% to 23.9%, and the median was 4.7%.

Table 1 illustrates the subdivision of the patients according to the degree of lung shunting. As can be seen, the percentages of lung shunting were generally lower in liver metastases, with 96% of the patients with values equal to or below 15%. On the other hand, 27.9% of the HCC patients had lung shuntings of 15% or more.

Correlation between Lung Shuntings and Sizes of Tumor

Sizes of the biggest tumor from computerized tomography or ultrasound scan in the 377 patients with HCC varied from 1.0–26.2 cm, with a median of 10.0 cm. Plotting of percentages of lung shunting against the tumor sizes on logarithmic-linear scales is illustrated in Figure 1. Percentages $<$ 1 were taken as 1 for the purpose of analysis. There was a correlation between percentages of lung shunting and tumor size in this study (coefficient of linear regression $r = 0.359$; $p < 0.0001$).

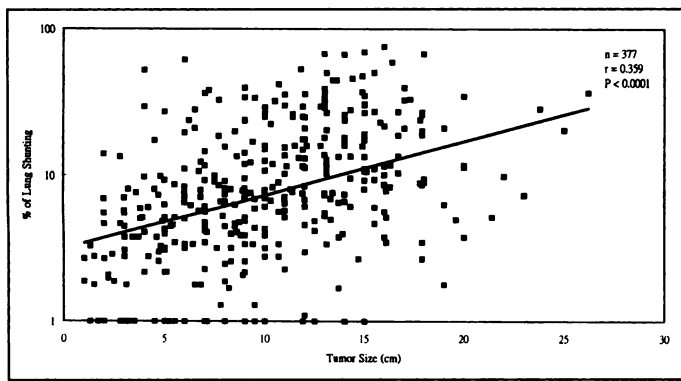


FIGURE 1. Correlation between lung shunting and tumor size in HCC.

The patients were stratified into subgroups according to the tumor sizes. The mean percentages of lung shunting in each subgroup are shown in Table 2. This analysis was impossible in our preliminary study (7) because the patient number was small ($n = 125$).

There was an increase in the mean lung shunting with increasing tumor sizes up to 15 cm, and then the mean lung shunting remained almost unchanged, up to a size of >20 cm. As the distribution of value was non-Gaussian, the Wilcoxon rank test was used to compare the differences between the subgroups and the p values are illustrated in Table 2. The differences between the subgroups were statistically significant, except between the three subgroups C, D and E, which have the largest tumor sizes.

In the 25 patients with liver metastases, the size of the biggest tumor ranged from 1.5 cm to 17.0 cm, with a median of 7.6 cm. A plot similar to that in Figure 1 for these patients is shown in Figure 2. The lung shunting did not correlate with the tumor size, taking all 25 patients into account (linear regression: $r = 0.3326$; $p = 0.1043$). However, excluding one outlier, we found a fair correlation between the two parameters (linear regression: $r = 0.686$; $p < 0.0001$). Due to the small number of patients, analysis by stratifying into subgroups according to tumor sizes was not performed.

Relationship between the Percentages of Lung Shunting and the Tumor Vascularity Grades

The relationship between the percentages of lung shunting and the tumor vascularity grades, as assessed by HAG for HCC and liver metastases, are illustrated in Figures 3 and 4, respectively. All except two patients with liver metastases had vascularity grades of 1 or 2, whereas the majority of HCC

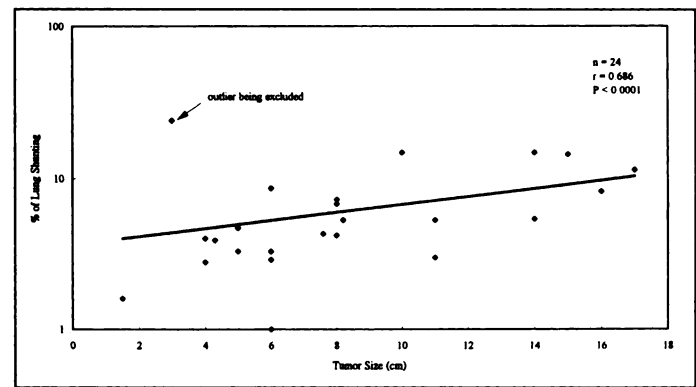


FIGURE 2. Correlation between lung shunting and tumor size in colorectal liver metastases.

patients had vascularity grades of 3 and 4. Thus, HCC are generally more vascular than liver metastases.

It is possible to analyze the difference between each vascularity grade in this study because of the larger number of patients with HCC ($n = 377$). The mean values of the lung shunting for each vascularity grade are shown in Table 3. The single patient with grade 0 was excluded from analysis.

The mean lung shunting increased with increasing vascularity grades, with a tremendous increase from grade 2 to grade 3 and then to grade 4. The p values from Wilcoxon rank test indicate that statistically significant differences exist between any two vascularity grades.

In comparing the percentages of lung shunting of patients with colorectal liver metastases having vascularity grades 1 and 2 with those having grades 3 and 4 using the same statistical test, a p value of 0.057 was obtained. However, this comparison might not be valid because there were only two patients who had vascularity grades 3 and 4.

Change in Lung Shunting after Treatment

Patients with residual or recurrent HCC after various types of treatment were reassessed with ^{99m}Tc -MAA, given through HAG, for suitability of retreatment with selective internal radiotherapy. Comparison of the lung shunting before and after the initial treatment is shown in Table 4. Patients 1–9, with recurrent disease that appeared as new lesions, showed both increases and decreases in lung shunting. The lung shunting associated with the new tumors due to recurrence was usually higher than that before the initial treatment (in Patients 1, 3 and 6–9), unless the new lesion was significantly smaller than the original tumor (in Patients 2, 4 and 5). The tremendous increase in the lung shunting in Patient 1 had prevented him from being retreated with selective internal radiotherapy because of the

TABLE 2
Relationship Between Lung Shunting and Tumor Size

Subgroup	Tumor size (cm)	n	Lung shunting (%)	
			Mean	Range
A*	≤ 5	69	5.7	0.0–52.0
B†	$>5, \leq 10$	131	9.2	0.0–61.1
C‡	$>10, \leq 15$	122	17.7	0.0–68.9
D§	$>15, \leq 20$	49	18.2	1.8–75.4
E	>20	6	18.0	5.2–36.7

* $p = 0.0002$ (vs. subgroup B), 0.0001 (vs. subgroup C), 0.0001 (vs. subgroup D) and 0.0018 (vs. subgroup E).

† $p = 0.0001$ (vs. subgroup C), 0.0001 (vs. subgroup D) and 0.0298 (vs. subgroup E).

‡ $p = 0.9170$ (vs. subgroup D) and 0.8172 (vs. subgroup E).

§ $p = 0.7768$ (vs. subgroup E).

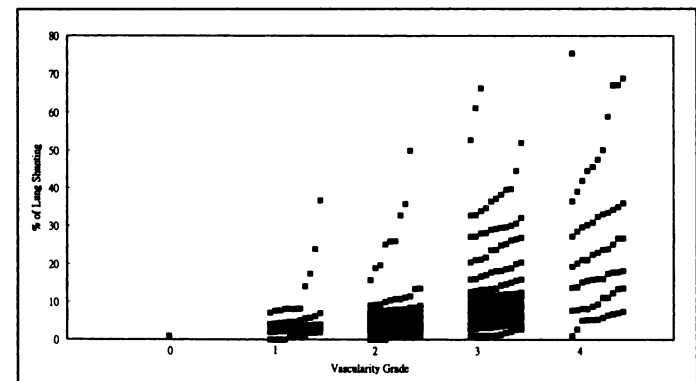


FIGURE 3. Scatter diagram plotting lung shunting against tumor vascularity in HCC.

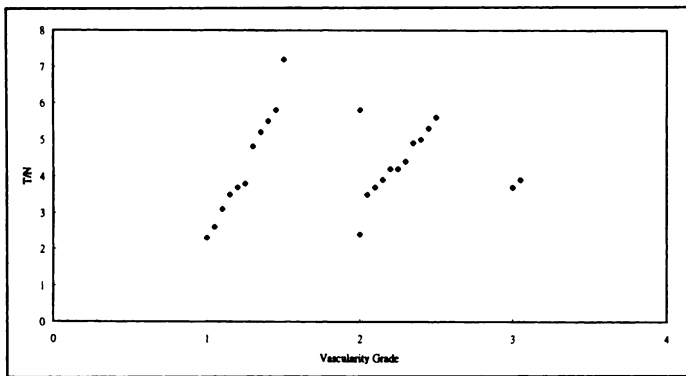


FIGURE 4. Scatter diagram plotting lung shunting against tumor vascularity in colorectal liver metastases.

high risk of radiation pneumonitis (6). On the other hand, all patients with residual tumors after selective internal radiotherapy showed a decrease in lung shunting.

DISCUSSION

Both HCC and colorectal liver metastases are usually more vascular than the normal liver parenchyma due to neovascularization (8). Technetium-99m-MAA particles are expected to be caught within the capillaries of the tumor or the normal liver because of their size, and few particles can pass through if there is no arteriovenous shunting. However, arteriovenous shunting is well-known to exist in HCC (9) and colorectal liver metastases (2). The shunted ^{99m}Tc-MAA go through these abnormal vascular channels into extrahepatic organs. The lungs, being first-pass organs with similar capillary structures, hold up the shunted ^{99m}Tc-MAA. Little MAA shunts to other organs because the capillary bed in the lungs stops any further systemic shunt. Our observation that there was no significant extrahepatic spread of ^{99m}Tc-MAA except in the lungs supports this theory. Thus, measuring the degree of lung shunting reflects the degree of arteriovenous shunting in the liver tumors.

Hepatic arterial perfusion scintigraphy using ^{99m}Tc-MAA has been used by other workers to assess the shunting of regional chemotherapy for liver metastases into the pulmonary circulation (2,10). The percentage of lung shunting was found to be between 6% and 26% (mean, 12.3%) in a series of 20 patients (2) and between 0.4% and 32% (mean, 6.2%) in another series of 67 patients (10). These ranges are very close to that of our 25 patients with liver metastases. A much wider range (<1–67.2%) of pulmonary shunting, observed in 125 patients with HCC, has previously been reported by us (7). The median value for HCC was also higher than that of liver metastases. With 377 HCC patients in this study, the range has become even wider (<1–75.4%). Zeissman et al. (10) found that 49% of their

patients with metastatic tumors had a percentage equal to or greater than 5%. In our series of 25 patients with liver metastases, 48% of them had a lung shunting of 5% or more. The results of the two studies are therefore very close. Significantly higher percentage (66.6%) of HCC patients showed lung shunting equal to or greater than 5%, suggesting that HCC has higher lung shunting than liver metastases. Gray et al. (11) recommend lung shunting of below 15% as the safe limit for selective internal radiotherapy. Using lung shunting below 15% as the only entry criteria, 27.9% of HCC patients have to be excluded from selective internal radiation therapy, as compared to only 4% of patients with liver metastases.

Using the partition model for estimating radiation doses from ⁹⁰Y microspheres in treating hepatic tumors (12), we can actually predict the radiation dose to the lungs from a certain activity of ⁹⁰Y microspheres infused into the liver. Based on the experience of whole-lung irradiation using external beams (13), an estimated radiation dose of less than 20 Gy to the lungs, rather than a lung shunting below 15%, is a more scientific way to use as an entry criteria to selective internal radiotherapy using ⁹⁰Y-microspheres. This is because the activity required to treat the hepatic cancer in different patients varies according to the size of tumor and tumor-to-normal uptake ratio of the radiopharmaceutical (12).

Our previous study (7) demonstrated that significant differences in lung shunting were found between different vascularity grades but not with tumor size. With the increased number of patients, the degrees of arteriovenous shunting to the lungs were shown to be influenced by both the vascularity of the tumors and the tumor size up to a certain size. The pattern of blood flow through the tumor seemed to be one of the determining factors of pulmonary shunting. This may be because tumors, which are vascular and rich in blood supply, usually have more arteriovenous shunts and a resultant increase in the percentages of lung shunting. The generally lower percentages of lung shunting observed in colorectal liver metastases is consistent with their lower vascularity. The increase in lung shunting with an increase in tumor size, up to 15 cm, is probably due to the increase in arteriovenous shunts as the tumor grows. As central necrosis frequently occurs when the tumor grows to beyond 15 cm, the degree of lung shunting becomes almost constant.

A strong association between lung shunting and the characteristics of HCC present in an individual patient is evident from the comparison between the percentages of lung shunting before the initial treatment with that after the detection of residual or recurrent disease. A tumor which has been treated by selective internal radiotherapy is smaller than the original tumor. It is also less vascular because of embolization by the ⁹⁰Y microspheres and the necrotic and fibrotic effects caused by radiation. The decrease in vascularity explains the observed lowering lung shunting associated with residual tumors. On the other hand, recurrence, which appeared as new lesions, might show tumors with completely different sizes and vascularities.

Previous observations of the lack of effect of angiotensin II on lung shunting (7,14) suggest a neoplastic nature of the blood vessels responsible for the shunt. This is further supported by the drastic decrease in lung shunting after the removal of tumors (7). Our present finding of a change of lung shunting associated with the status of the tumors provided additional evidence of the neoplastic nature of the blood vessels in the shunt.

Increased lung shunting found with increasing tumor size poses a great challenge to selective internal radiotherapy for hepatic cancer using ⁹⁰Y microspheres. It is large tumors that are more often nonresectable and require palliation by selective internal radiotherapy. Partial hepatic embolization has been

TABLE 3
Comparison of Lung Shunting between Different Vascularity Grades in Patients with HCC

Vascularity grade	n	Lung shunting (%)	
		Mean	Range
1*	55	5.1	0.0–36.7
2†	108	6.9	0.0–49.9
3‡	146	14.7	1.0–66.3
4	67	23.8	1.0–75.4

*p = 0.0148 (vs. grade 2), 0.0001 (vs. grade 3) and 0.0001 (vs. grade 4).

†p = 0.0001 (vs. grade 3) and 0.0001 (vs. grade 4).

‡p = 0.0001 (vs. grade 4).

TABLE 4
Lung Shunting (%) before Treatment and in the Presence of Residual or Recurrent HCC

Patient no.	Before treatment	With residual or recurrent HCC	Change*	Remarks
1	4.1	63.3	+59.2	Recurrence (8 cm) after resection of a 4-cm tumor
2	5.6	4.5	-1.1	Recurrence (1 cm) after resection of a 2-cm tumor
3	1.0	4.0	+3.0	Recurrence (5 cm) after resection of a 7-cm tumor
4	7.1	3.0	-4.1	Recurrence (1 cm) after resection of a 9-cm tumor
5	11.3	3.0	-8.3	Recurrence (0.8 cm) after resection of a 12-cm tumor
6	3.8	8.3	+4.5	Recurrence post TACE
7	7.7	18.1	+10.4	Recurrence (new lesion) after selective internal radiotherapy
8	4.0	9.1	+5.1	Recurrence (new lesion) after selective internal radiotherapy
9	2.3	6.9	+4.6	Recurrence (new lesion) after selective internal radiotherapy
10	11.4	7.3	-4.1	Residual disease after selective internal radiotherapy
11	11.8	3.8	-8.0	Residual disease after selective internal radiotherapy
12	6.6	<1	-6.6	Residual disease after selective internal radiotherapy
13	5.2	<1	-5.2	Residual disease after selective internal radiotherapy
14	2.2	1.5	-0.7	Residual disease after selective internal radiotherapy
15	4.9	<1	-4.9	Residual disease after selective internal radiotherapy
16	4.0	2.2	-1.8	Residual disease after selective internal radiotherapy
17	6.2	<1	-6.2	Residual disease after selective internal radiotherapy
18	6.2	2.0	-4.2	Residual disease after selective internal radiotherapy
19	7.7	1.7	-6.2	Residual disease after selective internal radiotherapy
20	6.4	<1	-6.4	Residual disease after selective internal radiotherapy

*<1 taken as 0 in calculations.

TACE = transarterial chemoembolization.

attempted to reduced lung shunting, but the results were unsatisfactory (6). Active searching for better methods is required.

Meanwhile, with the knowledge that lung shunting decreases when a treated tumor becomes smaller or less vascular, a possible strategy is to treat tumor associated with a high lung shunting using a nonradioactive protocol, such as cytoreductive surgery (15) or chemoembolization. After surgical removal of the main bulk of the tumor or when a response to chemoembolization is obtained, the lung shunting can be reassessed using ^{99m}Tc-MAA. If the estimated lung dose from the selective internal radiotherapy to be contemplated lies within the safety limit, the treatment can then be given.

CONCLUSION

This extended study showed that the variation in the degree of arteriovenous shunting between lungs and liver is more remarkable in HCC than in colorectal liver metastases. The lung shunting does not depend on sex, but it correlates with tumor size and tumor vascularity. It also changes when the tumor is treated or the disease recurs. Effective methods are needed to reduce the high lung shunting that more frequently associates with larger and more vascular tumors.

ACKNOWLEDGMENTS

We thank Rebecca Yau, W. Y. Lee and K. K. Man for their assistance in preparing this manuscript.

REFERENCES

- Ariel IM, Padula G. Treatment of asymptomatic metastatic cancer to the liver from primary colon and rectal cancer by the intraarterial administration of chemotherapy and radioactive isotopes. *J Surg Oncol* 1982;20:151-156.
- Zeissman HA, Thrall JH, Gyves JW, et al. Quantitative hepatic arterial perfusion scintigraphy and starch microspheres in cancer chemotherapy. *J Nucl Med* 1983;24: 871-875.
- Herba MJ, Illescaze FF, Thirlwell MP, et al. Hepatic malignancies: improved treatment with intraarterial Y-90. *Radiology* 1988;169:311-314.
- Blanchard RJW, Morrow IM, Sutherland JB. Treatment of liver tumors with yttrium-90 microspheres alone. *J Can Assoc Radiol* 1989;40:206-210.
- Houle S, Yip TCK, Shepherd FA, et al. Hepatocellular carcinoma: pilot trial of treatment with Y-90 microspheres. *Radiology* 1989;172:857-860.
- Leung WT, Lau WY, Ho SKW, et al. Radiation pneumonitis after selective internal radiation treatment with intraarterial ⁹⁰yttrium-microspheres for inoperable hepatic tumors. *Int J Radiat Biol Phys* 1995;33:919-924.
- Leung WT, Lau WY, Ho S, et al. Measuring lung shunting in hepatocellular carcinoma with intra-arterial technetium-99m macroaggregated albumin. *J Nucl Med* 1994;35: 70-73.
- Matsui O, Kadoya M, Kameyama T, et al. Benign and malignant nodules in cirrhotic liver: distinction based on blood supply. *Radiology* 1991;178:493-497.
- Foster JH, Berman MM. Primary epithelia cancer in adults. In: Foster JH, Berman MM, eds. *Solid liver tumors*. Philadelphia: W. B. Saunders; 1977:62-104.
- Zeissman HA, Thrall JH, Yang PJ, et al. Hepatic arterial perfusion scintigraphy with Tc-99m MAA. *Radiology* 1984;152:167-172.
- Gray BN, Burton MA, Kelleher DK, Anderson J, Klemp P. Selective internal radiation (SIR) therapy for treatment of liver metastases: measurement of response rate. *J Surg Oncol* 1989;42:192-196.
- Ho S, Lau WY, Leung WT, et al. Partition model for estimating radiation doses from yttrium-90 microspheres in treating hepatic tumors. *Eur J Nucl Med* 1996;23:947-952.
- Margolis LW, Philips TL. Whole lung irradiation for metastatic tumor. *Radiology* 1969;93:1173-1178.
- Goldberg JA, Bradnam MS, Kerr DJ, et al. Arteriovenous shunting of microspheres in patients with colorectal liver metastases: error in assessment due to free pertechnetate, and the effect of angiotensin II. *Nucl Med Commun* 1987;8:1033-1046.
- Lau WY, Leung TWT, Leung KL, et al. Cytoreductive surgery for hepatocellular carcinoma. *Surg Oncol* 1994;3:161-166.