

Perfusion and Blood-Pool Scintigraphy in the Evaluation of Head and Neck Hemangiomas

Yuji Murata, Ichiro Yamada, Isao Umehara, Yoshimasa Ishii and Norihiko Okada

Department of Radiology, Faculty of Medicine and Departments of Oral Surgery and Clinical Laboratory, Faculty of Dentistry, Tokyo Medical and Dental University, Tokyo, Japan

We investigated the sensitivity and specificity of perfusion and blood-pool scintigraphy in the detection of head and neck hemangiomas and evaluated their histopathologic types. **Methods:** Perfusion and blood-pool scintigraphy with ^{99m}Tc -red blood cells (RBCs) or ^{99m}Tc -human serum albumin combined with DTPA (HSA-D) were used to evaluate 51 head and neck lesions clinically suspected of being hemangiomas in 48 patients. Thirty-three of the 51 lesions were subsequently histologically confirmed to be hemangiomas, whereas the remaining 18 were histologically diagnosed as other lesions. **Results:** Perfusion and blood-pool scintigraphy correctly diagnosed 30 of 33 hemangiomas as being hemangiomas but could not detect the remaining 3 hemangiomas. Perfusion and blood-pool scintigraphy correctly diagnosed 12 of 18 lesions as nonhemangiomas, but the remaining 6 lesions were misdiagnosed as hemangiomas. Thus, the sensitivity for detecting hemangiomas was 91%, with a specificity and accuracy of 67% and 82%, respectively. Twenty-five (89%) of 28 cavernous or venous hemangiomas demonstrated normal activity on the perfusion images and increased activity on the delayed blood-pool images, whereas the remaining 3 (11%) showed normal activity on both perfusion and blood-pool images. Finally, 5 of 5 (100%) capillary or racemose hemangiomas showed increased activity on the perfusion and blood-pool images. **Conclusion:** Perfusion and blood-pool scintigraphy demonstrated sufficiently high sensitivity but relatively low specificity for detecting head and neck hemangiomas. Additionally, perfusion and blood-pool scintigraphy can clearly differentiate between cavernous and venous hemangiomas and capillary and racemose hemangiomas and are extremely useful for the detection and evaluation of head and neck hemangiomas.

Key Words: head and neck hemangiomas; technetium-99m-red blood cells; technetium-99m-human serum albumin

J Nucl Med 1997; 38:882-885

Hemangiomas, with benign tumors of the head and neck being the most common, are histopathologically classified as racemose, capillary, cavernous and venous hemangiomas. Each hemangioma type manifests different hemodynamics (1,2). Furthermore, treatment and management of head and neck hemangiomas requires preoperative evaluation of the hemangioma's hemodynamic characteristics since its vascularity will determine the most appropriate method of therapy (1).

Recently, perfusion and blood-pool scintigraphy with ^{99m}Tc -red blood cells (RBCs) have been used to diagnose cavernous hemangiomas of the head and neck (3,4), but there has been no study that assesses the sensitivity and specificity of perfusion and blood-pool imaging in the diagnosis of hemangiomas and evaluation of their histopathologic types.

MATERIALS AND METHODS

Patients

We studied 48 (28 women, 20 men; age 4-79 yr; mean age 31 yr) consecutive patients who underwent perfusion and blood-pool scintigraphy for clinically suspected head and neck hemangiomas. Forty-five of the patients had a single lesion and three patients had two lesions: A total of 51 lesions were investigated. The anatomical distribution of the lesions was: face, 20 lesions; oral cavity, 15 lesions; lip, 6 lesions; neck, 3 lesions; parotid gland, 2 lesions; bone, 2 lesions; nasal cavity, 2 lesions; and orbit, 1 lesion.

All patients underwent surgery within 1 mo after the scintigraphic study, and all lesions were subsequently diagnosed histopathologically: 33 were hemangiomas (24 cavernous, 4 venous, 4 capillary and 1 racemose); the remaining 18 were nonhemangiomas.

Imaging Protocol

The patients were administered 740 MBq (20 mCi) ^{99m}Tc -labeled RBCs or ^{99m}Tc -labeled human serum albumin combined with DTPA (HSA-D). The RBCs were labeled in accordance with the in vivo/in vitro method reported by Callahan (5). In brief, after a bolus injection of tracer, dynamic perfusion flow images were acquired at a rate of 2 sec per frame over a 40-sec interval. Subsequently, two static blood-pool images were obtained as early and delayed blood-pool images, which were taken at 5 and at 60 min postinjection, respectively.

Image Analysis

As shown in Table 1, the scintigraphic findings were classified as: type 1, normal activity on perfusion images and increased activity on delayed blood-pool images (Fig. 1); type 2, increased activity on both perfusion and blood-pool images (Fig. 2); and type 3, normal activity on both perfusion and blood-pool images.

The images were reviewed independently by three radiologists (YM, IY, IU) who were blinded to the histopathological diagnoses. Disagreements were resolved by consensus.

The images were compared on a lesion-by-lesion basis and were correlated with the histopathological findings. After routine hematoxylin-eosin staining, all microscopic inspections were performed by one of the authors (NO).

TABLE 1
Classification of Findings in Perfusion and Blood-Pool Scintigraphy

Scintigraphic findings	Scintigraphic images	
	Blood perfusion	Delayed blood pool
Type 1	-	+
Type 2	+	+
Type 3	-	-

Received Apr. 8, 1996; revision accepted Jul. 1, 1996.

For correspondence or reprints contact: Yuji Murata, MD, Department of Radiology, Faculty of Medicine, Tokyo Medical and Dental University, 1-5-45 Yushima, Bunkyo-ku, Tokyo 113, Japan.

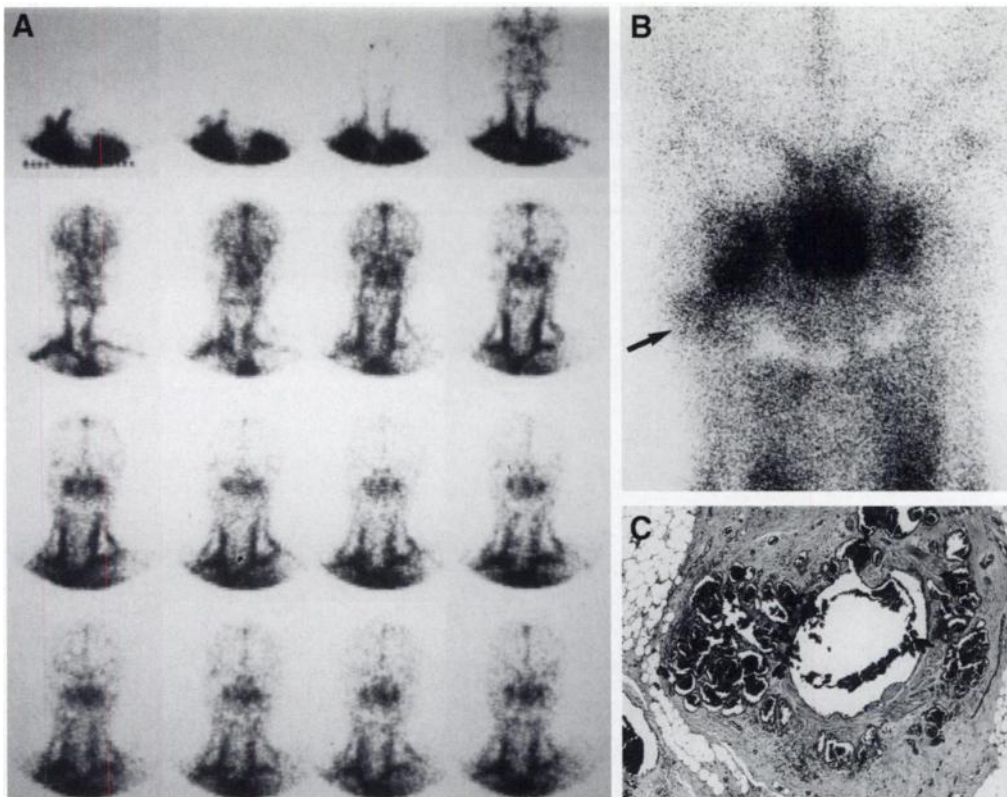


FIGURE 1. A 33-yr-old woman with a venous hemangioma of the right cheek. (A) Technetium-99m-HSA-D dynamic perfusion images are within normal. (B) Delayed blood-pool image shows an area of increased activity (arrow) in the right lower cheek. (C) Photomicrograph of the mass in the right cheek shows proliferative dilated venous vessels, indicative of a venous hemangioma.

RESULTS

Comparison of Scintigraphic Findings and Pathological Diagnosis

The correlation of the scintigraphic findings and the pathological diagnosis is summarized in Table 2. For 24 cavernous and 4 venous hemangiomas, scintigraphy revealed 25 lesions to be type 1. However, two cavernous and one venous hemangioma showed no accumulation of radioactivity (type 3), resulting in false-negative findings for the following lesions: 5-mm cavernous hemangioma with thrombi, 30-mm cavernous hemangioma without thrombi (Fig. 3) and a 28-mm venous hemangioma without thrombi.

All four capillary and one racemose hemangioma were

identified as type 2 lesions (Table 2). No false-negative results occurred in this series.

Of the 18 nonhemangiomas, 12 were type 3 lesions (Table 2), which were diagnosed as follows: lymphangioma (n = 3), fibrous tissue (n = 2), neurilemmoma (n = 1), fibroma (n = 1), fibro-osseous tissue (n = 1), inflammation (n = 1), varicose vein (n = 1), epipharyngeal cyst (n = 1) and papillary adenocarcinoma (n = 1). Five of the remaining six nonhemangiomas were type 1 lesions [hemangiopericytoma (n = 1), telangiectasia (n = 1), malignant lymphoma (n = 1), ectopic thyroid gland (n = 1) and nontumorous tissue (n = 1)], and one was type 2 (malignant hemangioendothelioma, Fig. 4), resulting in six false-positive findings.

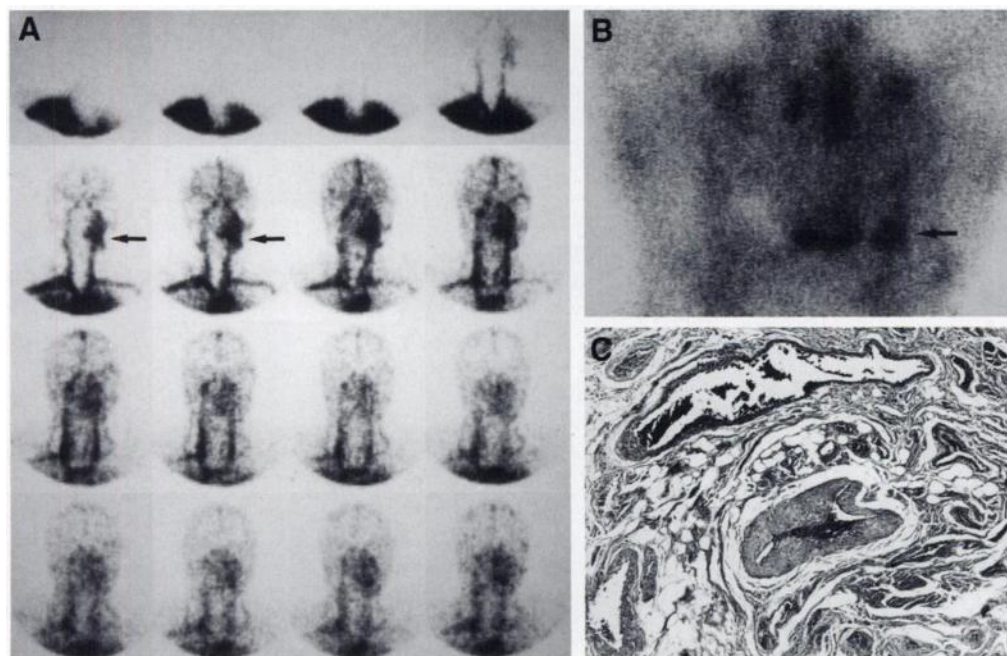


FIGURE 2. A 47-yr-old man with a racemose hemangioma of the left upper lip. (A) Technetium-99m-HSA-D dynamic perfusion images on the anterior view show an area of increased activity (arrows) in the left lip. (B) Delayed blood-pool image on the anterior view also shows increased activity (arrow) in the left lip. (C) Photomicrograph shows that mass is composed of proliferative arterial and venous components, indicative of racemose hemangioma.

TABLE 2
Comparison of Scintigraphic Findings and Histopathologic Diagnosis of 51 Lesions

Scintigraphic findings	Histologic diagnosis				
	Cavernous hemangioma (n = 24)	Venous hemangioma (n = 4)	Capillary hemangioma (n = 4)	Racemose hemangioma (n = 1)	Nonhemangioma (n = 18)
Type 1 (n = 31)	22	3	0	0	5
Type 2 (n = 6)	0	0	4	1	1
Type 3 (n = 14)	2	1	0	0	12

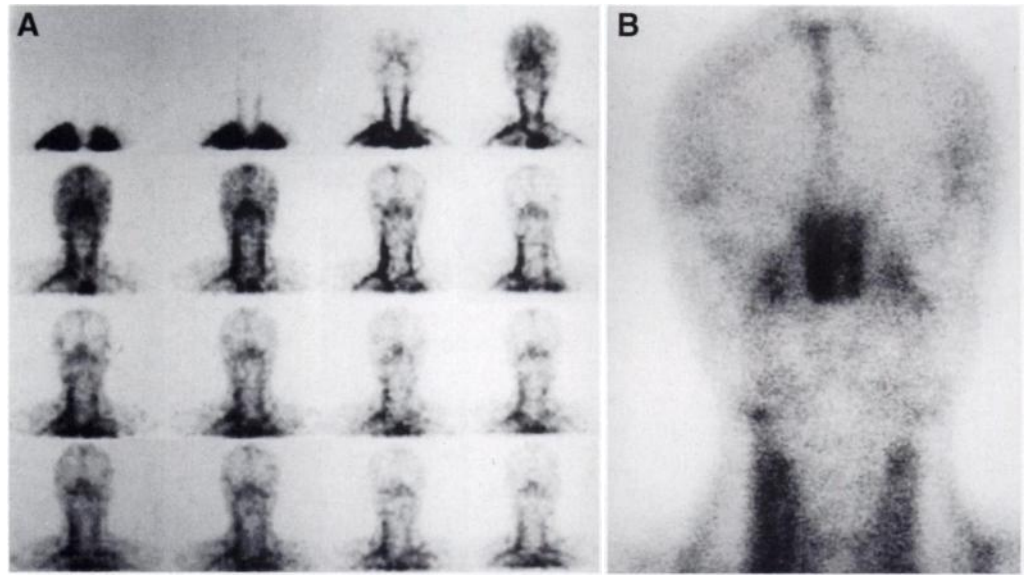


FIGURE 3. A 34-yr-old man with a cavernous hemangioma of the right parotid gland. (A, B) Technetium-99m-HSA-D dynamic perfusion (A) and delayed blood-pool (B) images are within normal range.

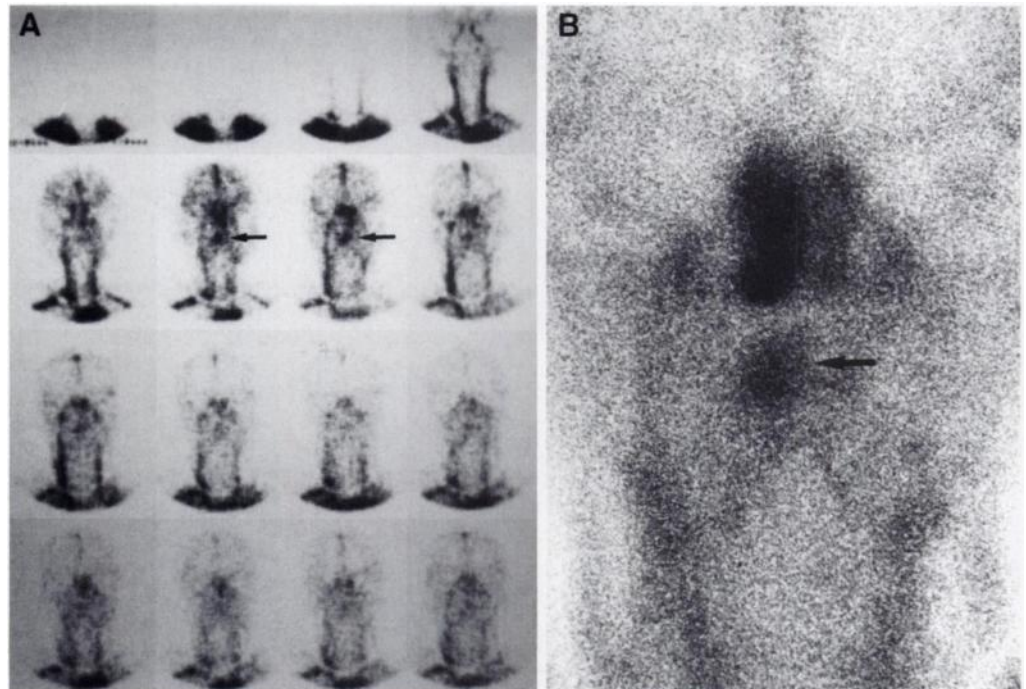


FIGURE 4. A 46-yr-old man with a malignant hemangioendothelioma of the tongue. (A) Technetium-99m-HSA-D dynamic perfusion images on anterior view show an area of increased activity (arrows) in the tongue. (B) Delayed blood-pool image also shows an area of increased activity (arrow) in the tongue.

TABLE 3
Diagnostic Accuracy of Scintigraphy for Detecting Hemangiomas

Scintigraphic diagnosis	Histologic diagnosis	
	Hemangioma (n = 33)	Nonhemangioma (n = 18)
Hemangioma (n = 36)	30	6
Nonhemangioma (n = 15)	3	12

Diagnostic Accuracy in Detecting and Evaluating Hemangiomas

Based on these scintigraphic findings, we diagnosed type 1 and type 2 lesions as hemangiomas and type 3 lesions as nonhemangiomas. Thus, the sensitivity of this method for detecting hemangiomas was 91%, with a specificity and accuracy of 67% and 82%, respectively (Table 3). The sensitivity of the method is sufficiently high but the specificity is low.

We evaluated the diagnostic accuracy of scintigraphy to determine histologic type (Table 4) in 33 lesions. All type 1 hemangiomas (n = 25) were either cavernous or venous, all type 2 lesions were either capillary or racemose and all type 3 lesions were either cavernous or venous. There was good correlation between the scintigraphic and histopathologic findings.

DISCUSSION

Hemangiomas frequently occur in infancy and childhood. Suggestive symptomatology hemangioma include compressible swelling of the soft tissue, bluish and/or erythematous surface and presence of abnormal vessels (1,6). As mentioned earlier, hemangiomas are classified into four pathologic types, and each type has different hemodynamics due to different vascular structures.

Racemose hemangiomas, which are composed of both arterial and venous components, have high blood flow dynamics; capillary hemangiomas also show a relatively high blood flow. In contrast, cavernous and venous hemangiomas have low blood flows due to their lack of arterial or capillary components. The hemodynamics of hemangiomas determine selection of the most appropriate therapy (1).

Our results demonstrate that perfusion and blood-pool scintigraphy can correctly differentiate between cavernous and venous hemangiomas and capillary and racemose hemangiomas. Because of delayed blood flow, cavernous or venous hemangiomas demonstrated normal activity on the perfusion images and increased activity on the blood-pool images (type 1 pattern). However, because of high blood flow, capillary or racemose hemangiomas showed increased activity on the perfusion images and persistent accumulation on the blood-pool images (type 2 pattern). Scintigraphy's ability to evaluate vascularity in head and neck hemangi-

omas is of great value for determining the optimum therapy, whether it be surgery or transluminal arterial embolization.

Although the sensitivity is high (91%), we did have three false-negatives. Earlier reports indicate that smaller hepatic hemangiomas with a thrombus or fibrosis are not detected by scintigraphy (7,8). Of our three false-negatives, one cavernous hemangioma was a small hemangioma with thrombi, but the other two cavernous or venous hemangiomas were relatively large with no evidence of thrombi. It should be noted, however, that cavernous or venous hemangiomas, which have a markedly delayed blood flow, may require much longer time for tracer accumulation in the lesions. Therefore, the 1-hr interval from tracer injection to scanning in our protocol might have been too short for sufficient evaluation of these two hemangiomas. Because of this possibility, repeated imaging 2-3 hr postinjection may be needed if there is no visualization on the 1-hr delayed image.

Our series included six lesions that were false-positive, which reflects a low specificity (67%). These lesions demonstrated the same hemodynamic patterns as type 1 and 2 hemangiomas and were scintigraphically misdiagnosed as hemangiomas. As we stated previously, three of the lesions were other vascular lesions: hemangiopericytoma, telangiectasis and malignant hemangioendothelioma (9). An ectopic thyroid gland of the tongue also resulted in a false-positive finding due to increased activity from accumulation of free [^{99m}Tc]pertechnetate in the thyroid gland. Although ^{99m}Tc-RBCs or ^{99m}Tc-HSA-D is stable, nevertheless a small amount of free ^{99m}Tc is often encountered. Finally, malignant lymphoma was also one of the false-positive lesions. Given that other vascular lesions may exhibit type 1 and 2 patterns, it should be remembered that perfusion and blood-pool scintigraphy, although helpful in determining and evaluating lesion hemodynamics, may not be useful in differentiating between benign and malignant lesions.

CONCLUSION

Perfusion and blood-pool scintigraphy with ^{99m}Tc-RBCs or ^{99m}Tc-HSA-D had sufficiently high sensitivity but relatively low specificity in detecting head and neck hemangiomas. However, perfusion and blood-pool scintigraphy can correctly differentiate between cavernous and venous hemangiomas and capillary and racemose hemangiomas. Thus, perfusion and blood-pool scintigraphy is most useful for diagnosing and evaluating head and neck hemangiomas.

ACKNOWLEDGMENTS

We are grateful to Emeritus Professor Soji Suzuki, Tokyo Medical and Dental University, for his valuable suggestions and contributions to this study.

REFERENCES

1. Handley, GH. Hemangiomas of the head and neck. *Ear Nose Throat J* 1987;66:486-490.
2. Enzinger FM. Histological typing of soft-tissue tumors. *International histological classification of tumors*, no. 3. Geneva: World Health Organization; 1969:21.
3. Front D, Israel O, Kleinhaus U, Gdal-On M. Technetium-99m-red blood cells in the evaluation of hemangiomas of the skull and orbit: concise communication. *J Nucl Med* 1982;23:1080-1084.
4. Front D, Groshar D, Israel O, Robinson E. Hemangioma of tongue demonstrating a perfusion blood-pool mismatch. *Clin Nucl Med* 1986;11:113-114.
5. Callahan RJ, Froelich JW, McKusick KA, Leppo J, Strauss HW. A modified method for the in vivo labeling of red blood cells with Tc-99m: concise communication. *J Nucl Med* 1982;23:315-318.
6. Batsakis JG, Rice DH. The pathology of head and neck tumors: vasoformative tumors, part 9A. *Head Neck Surg* 1981;3:231-239.
7. Rabinowitz SA, Mckusick KA, Strauss HW. Technetium-99m-red blood cell scintigraphy in evaluating focal liver lesions. *Am J Roentgenol* 1984;143:63-68.
8. Birnbaum BA, Weinreb JC, Megibow AJ, et al. Definitive diagnosis of hepatic hemangiomas: MR imaging versus Tc-99m-labeled red blood cell SPECT. *Radiology* 1990;176:95-101.
9. Iwamoto N, Kishi T, Sakagami M, Kusama M, Enomoto S, Okada N. A case of primary malignant hemangioendothelioma of the tongue. *Jpn J Oral Maxillofac Surg* 1995;41:148-150.

TABLE 4
Diagnostic Accuracy of Scintigraphy in Evaluating Histologic Types in 33 Histologically Confirmed Hemangiomas

Scintigraphic findings	Hemangiomas	
	Cavernous or venous (n = 28)	Capillary or racemose (n = 5)
Type 1 (n = 25)	25	0
Type 2 (n = 5)	0	5
Type 3 (n = 3)	3	0