

19. Dunnett CW. New table for multiple comparisons with a control. *Biometrics* 1964;20:482-491.
20. Fox PT, Mintun MA, Reiman EM, Raichle ME. Enhanced detection of focal brain responses using intersubject averaging and change-distribution analysis of subtracted PET images. *J Cereb Blood Flow Metab* 1988;8:642-653.
21. Watson JDG, Myers R, Frackowiak RSJ, et al. Area V5 of the human brain: evidence from a combined study using positron emission tomography and magnetic resonance imaging. *Cereb Cortex* 1993;3:79-94.
22. Koyama M, Kawashima R, Ito H, et al. Normal cerebral perfusion of ^{99m}Tc-HMPAO brain SPECT: evaluation by an anatomical standardization technique. *Jpn J Nucl Med* 1995;32:969-977.
23. Lévillé J, Botez MI, Taillefer R, et al. A clinical comparison of ^{99m}Tc-HMPAO and ^{99m}Tc-ECD in normal volunteers and patients as brain perfusion imaging agent [Abstract]. *J Nucl Med* 1988;29:844.
24. Ueda O, Ashihara T, Wake S, et al. Temporal change in regional brain distribution of the technetium-99m-ethyl cysteinyl dimer. *Jpn J Radio Technol* 1993;49:1609-1615.
25. Lévillé J, Démonceau G, Walovitch RC. Intrasubject comparison between technetium-99m-ECD and technetium-99m-HMPAO in healthy human subject. *J Nucl Med* 1992;33:480-484.
26. Neirinckx RD, Bruke JF, Harrison RC, Forster AM, Andersen AR, Lassen NA. The retention mechanism of technetium-99m-HMPAO: intracellular reaction with glutathione. *J Cereb Blood Flow Metab* 1988;8:S4-S12.
27. Walovitch RC, Franceschi M, Picard M, et al. Metabolism of ^{99m}Tc-L,L-ethyl cysteinyl dimer in healthy volunteers. *Neuropharmacology* 1990;30:283-292.
28. Borman G, Van Nerom C, Hoogmartens M, DeRoo M, Verbruggen A. Metabolism of ^{99m}Tc-ECD in isolated rat organs. *J Nucl Med* 1989;30:743.
29. Isaka Y, Iiji O, Imaizumi M, Ashida K, Itoi Y. Quantification of regional cerebral blood flow using ^{99m}Tc-HMPAO SPECT and intravenous ¹³³Xe injection method. *Jpn J Nucl Med* 1992;29:1463-1473.
30. Syed GMS, Eagger S, Toone BK, Levy R, Barrett JJ. Quantification of regional cerebral blood flow using ^{99m}Tc-HMPAO and SPECT: choice of the reference region. *Nucl Med Comm* 1992;13:811-816.
31. Heiss WD, Herholz K, Podreka I, Neubauer I, Pietrzyk U. Comparison of [^{99m}Tc]HMPAO SPECT with [¹⁸F]fluoromethane PET in cerebrovascular disease. *J Cereb Blood Flow Metab* 1990;10:687-697.
32. Rockel AJ, Hiorns RW, Powell TPS. The basic uniformity in structure of the neocortex. *Brain* 1980;103:221-244.
33. Abi-Dargham A, Laruelle M, Seibyl J, et al. SPECT measurement of benzodiazepine receptors in human brain with iodine-123-iomazenil: kinetic and equilibrium paradigms. *J Nucl Med* 1994;35:228-238.
34. Nakano S, Kinoshita K, Jinnouchi S, Hoshi H, Watanabe K. Comparative study of regional cerebral blood flow images by SPECT using xenon-133, iodine-123-IMP and technetium-99m-HMPAO. *J Nucl Med* 1990;30:157-164.

Discrepancies Between HMPAO and ECD SPECT Imaging in Brain Tumors

J.-P. Papazyan, J. Delavelle, P. Burkhard, P. Rossier, C. Morel, B. Maton, P. Otten, G.P. Pizzolato, D.A. Rüfenacht and D.O. Slosman
 Division of Nuclear Medicine, Neuroradiology Unit, Clinics of Neurology and Neurosurgery and Neuropathology Unit, Geneva University Hospital, Geneva, Switzerland

Among several brain radiopharmaceuticals for SPECT imaging, ^{99m}Tc complexes of HMPAO and ECD are the most widely used. They are considered to be equal in their capacity to reflect regional cerebral blood flow; but discrepancies between HMPAO and ECD brain uptake have been reported in stroke patients. This paper reports our observations regarding discrepancies between HMPAO and ECD SPECT in 14 of 23 patients with suspected brain tumors or presumed metabolic cerebral abnormalities. We obtained similar conflicting results, namely focal HMPAO hyperactivities and isoactive ECD SPECT. The majority of these discrepancies were found in patients with brain tumors (10 of 13 patients), while only 4 of the 10 remaining patients with nontumoral process showed similar discrepant results. The physiopathology behind these observations is discussed here, and it is likely to be related to the specific response to cellular metabolic disorders rather than to perfusion disturbances.

Key Words: brain perfusion; technetium-99m-HMPAO; technetium-99m-ECD; brain tumor

J Nucl Med 1997; 38:592-596

For more than a decade, several neutral and lipophilic brain radiopharmaceuticals have been developed to perform SPECT imaging of regional cerebral blood flow (rCBF) (1). Replacing the radioisotope ¹²³I with ^{99m}Tc gave investigators the capability to assess more easily rCBF in their own clinical environment. The ^{99m}Tc complex of hexamethylpropylene amine oxime (HMPAO), introduced in the late 1980s, showed rapid chemical decomposition, requiring its use within the first 30 min after reconstitution (2,3). This became a critical issue for epilepsy investigations during the ictal phase (4). Other ^{99m}Tc-labeled radiopharmaceuticals were then developed, in particular the ^{99m}Tc-ethylcysteinyl dimer (ECD), which showed rapid in vivo

blood clearance and prolonged in vitro stability (5,6). Moreover, in normal volunteers, intrasubject comparison between ECD and HMPAO showed better brain-to-background contrast with ECD than with HMPAO (7). Otherwise, HMPAO and ECD were considered to be similar with regard to their in vivo cerebral kinetics and initial distribution, as related to brain perfusion (7).

To our knowledge, the assessment of postischemic reperfusion was the only clinical situation in which HMPAO and ECD appeared to reflect rCBF in a different manner (8,9). Thus, in the present paper, we report our clinical experience of discrepant HMPAO and ECD brain uptake in several patients with suspected brain tumors or presumed metabolic cerebral abnormalities, and we discuss the possible physiopathological mechanisms behind these observations.

MATERIALS AND METHODS

We decided to perform both ECD and HMPAO-SPECT based on: (a) the results of our in vitro studies (10,11), (b) our preliminary discrepant observations related to decreased uptake of ECD associated to increased uptake of HMPAO and (c) a review of the literature. We made this decision under the following two conditions: (a) when the clinical suspicion was related to a possible situation of enhanced uptake of HMPAO (cerebral tumor, inflammatory or infectious processes and vascular disorders) and/or (b) when an increased uptake of HMPAO was observed in the first place.

During an 11-mo period (from March 1995 to February 1996), 234 brain SPECT examinations were executed in our division (34.6% patients were investigated for epilepsy, 32.9% with suspected or known brain tumors, 13.7% with cerebrovascular diseases and 18.8% with miscellaneous brain pathologies). Among our population, 23 patients (9 women, 14 men; mean age 60.2 yr, range 24-86 yr) underwent two consecutive brain SPECT exam-

Received Apr. 12, 1996; revision accepted Jul. 31, 1996.

For correspondence or reprints contact: Daniel Slosman, MD, Nuclear Medicine Division, Geneva University Hospital, 1211 Geneva 14 Switzerland.

TABLE 1
Final Diagnosis and Location of the Pathology for the 23 Patients Who Had ECD-SPECT and HMPAO-SPECT

Patient no.	Birth year	Location	Diagnosis
1	1928	Right frontal	Grade IV glioblastoma*
2	1926	Left fronto-parietal	Grade IV glioblastoma*
3	1937	Right frontal	Grade IV glioblastoma*
4	1930	Right temporal	Recurrent Grade IV glioblastoma*
5	1950	Left internal temporal	Grade III astrocytoma*
6	1963	Left temporo-occipital	Grade III astrocytoma*
7	1934	Right frontal	Low-grade glioma*
8	1966	Right frontal parasagittal	Cerebral lymphoma*
9	1945	Left frontal	Multifocal leukoencephalitis*
10	1959	Left parieto-occipital	Dysembryoplastic tumor
11	1922	Left parietal	Aspecific inflammatory lesion
12	1914	Right caudal nucleus	Cerebral abscess
13	1941	Left fronto-parietal	Recurrent fibrillary astrocytoma
14	1910	Right parietal	Right middle cerebral artery ischemia
15	1972	Right temporal	Dysembryoplastic tumor
16	1943	Bilateral fronto-temporal	Alzheimer's disease
17	1926	Bilateral hemispherical	Alzheimer's disease
18	1910	Left fronto-parieto-occipital	Subdural haematoma
19	1920	Right fronto-parieto-occipital	Chronic subdural haematoma*
20	1942	Left frontal	Recurrent Grade II astrocytoma*
21	1923	Right frontal	Recurrent meningioma*
22	1936	Bilateral hemispherical	Cortical degenerative disease
23	1927	Bilateral hemispherical	Normal pressure hydrocephalus

*Patients with histopathological diagnosis (surgery or stereotaxic biopsy).

inations, one with ^{99m}Tc-HMPAO and the other with ^{99m}Tc-ECD (Table 1).

HMPAO and ECD SPECT were performed 30 min after injection of 925 MBq (25 mCi) of ^{99m}Tc-HMPAO or 740 MBq (20 mCi) of ^{99m}Tc-ECD, injected intravenously. The time interval between the two examinations ranged from 1 day to 1 wk. Special care was given to patients with vascular or other active diseases. Only one patient had an interval of 20 days (Patient 13). All but one patient with suspected brain tumors had a ²⁰¹Tl SPECT performed 30 min after intravenous injection of 185 MBq (5 mCi) of ²⁰¹Tl in dual-isotope acquisition mode, simultaneously with HMPAO. SPECT examinations were performed using a three-head Toshiba GCA 9300A/HG gamma camera with fanbeam collimators. The protocol was a 120° rotation in step-by-step mode, with a 6° step and a 60-sec acquisition per step.

In addition, 16 patients had a PET scan performed 30 min after intravenous injection of 370 MBq (10 mCi), adjusted for a 70-kg body weight of [¹⁸F]fluorodeoxyglucose (FDG). These examinations were performed with the positron rotating tomograph prototype PRT-1 (12), which is comparable to an ECAT-953B PET camera (CTI-Siemens, Knoxville, TN).

Histopathological diagnosis was obtained by surgery or stereotaxic biopsy in 12 patients, while in the 11 remaining patients the final diagnosis was based on radiological findings, long-term radiological history and radiological and clinical follow-up.

RESULTS

Among the 23 patients, 13 patients were investigated for suspected or known brain tumors. In addition, at the time of the investigations, four patients (two with Alzheimer's disease, one with normal pressure hydrocephalus and one with cortical degenerative disease) were referred with a large differential diagnosis that led us to perform SPECT with both markers.

TABLE 2
Results of ECD, HMPAO and Thallium-201 SPECT and FDG-PET in 23 Patients

Patient no.	^{99m} Tc-HMPAO	^{99m} Tc-ECD	²⁰¹ Tl	[¹⁸ F]FDG
1	++	±	P	P
2	+	-	P	P
3	+	-	P	P
4	+	-	P	P
5	+	-	N	N
6	+	-	N	P
7	+	-	N	P
8	+	-	P	NP
9	+	-	N	N
10	+	-	NP	N
11	+	-	N	NP
12	+	-	N	NP
13	++	±	P	P
14	++	±	NP	NP
15	±	-	P	NP
16	-	-	N	N
17	-	-	NP	NP
18	±	±	N	N
19	-	-	NP	N
20	-	-	N	N
21	-	-	P	P
22	-	-	NP	N
23	-	-	NP	NP

ECD and HMPAO SPECT were graded: (++) intense focal increased uptake, (+) moderate focal increased uptake, (±) minimal increased uptake and (-) no increased uptake. FDG-PET and ²⁰¹Tl SPECT were identified as: p = abnormal focal uptake; n = no abnormal uptake; and NP = not performed.

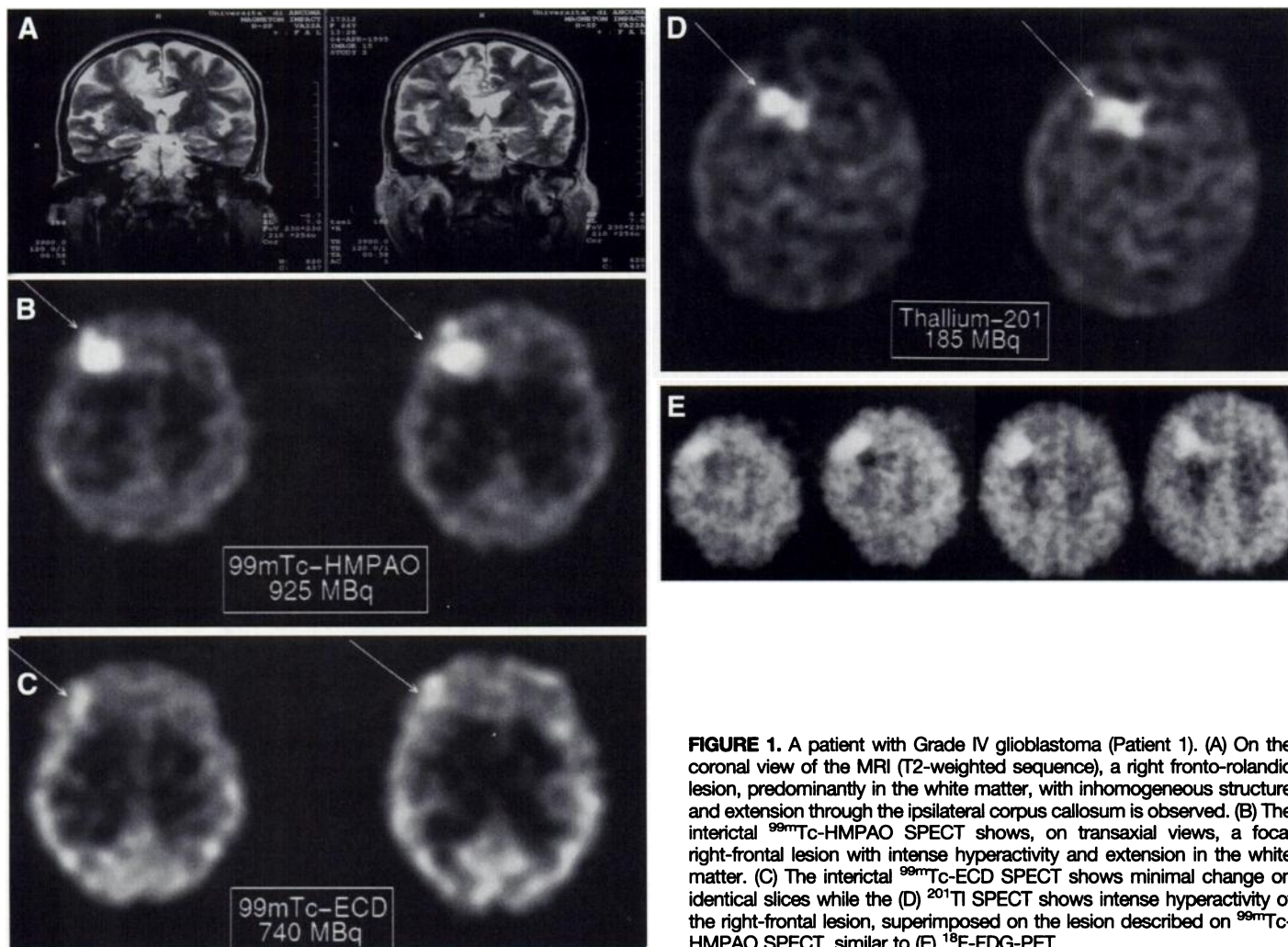


FIGURE 1. A patient with Grade IV glioblastoma (Patient 1). (A) On the coronal view of the MRI (T2-weighted sequence), a right fronto-rolandic lesion, predominantly in the white matter, with inhomogeneous structure and extension through the ipsilateral corpus callosum is observed. (B) The interictal ^{99m}Tc -HMPAO SPECT shows, on transaxial views, a focal right-frontal lesion with intense hyperactivity and extension in the white matter. (C) The interictal ^{99m}Tc -ECD SPECT shows minimal change on identical slices while the (D) ^{201}Tl SPECT shows intense hyperactivity of the right-frontal lesion, superimposed on the lesion described on ^{99m}Tc -HMPAO SPECT, similar to (E) ^{18}F -FDG-PET.

Fourteen of 23 patients (60.9%) with pairs of brain SPECT examinations showed discrepancies between ^{99m}Tc -HMPAO and ^{99m}Tc -ECD SPECT imaging, namely a focal intense or moderate hyperactivity with HMPAO not present with ECD (Table 2). As illustrated by Figure 1, the majority of these discrepancies were found in patients with brain tumors (10 of

13), while only four of the 10 remaining patients with nontumoral process also showed discrepant results. Surprisingly, the increased uptake of HMPAO was not purely related to the malignant nature of the brain tumor. Hence, if eight of eight malignant tumors (seven high-grade astrocytomas and one cerebral lymphoma) were positive with HMPAO, we also noticed that one of two low-grade gliomas was positive, as well as one dysembryoplastic tumor (Table 2). The histopathological analysis, the long-term radiological history (several years without radiological change) and the MRI semiology enabled us to assess the nature of the pathology.

Taking into account the design of the study and the small number of cases, one cannot calculate sensitivity and specificity of diagnosis of brain malignancy, but the proportions of each marker behavior could be evaluated as a function of the type of disease. As shown in Figure 2, false-positive results were smaller for FDG and ^{201}Tl than for HMPAO, but, in contrast, no false-negative was encountered with HMPAO. When the eight patients with increased uptake of HMPAO in the presence of high-grade brain tumor were considered, the glucose metabolic activity could not be directly associated with this phenomenon, considering that one patient of seven with FDG-PET did not have focal-increased glucose metabolism. Furthermore, alterations of the hemato-encephalic barrier and/or potassium channel activity could not be directly associated to this phenomenon, considering that two patients of eight did not have increased uptake of ^{201}Tl . Moreover, one patient (Patient 5) presented a high-grade astrocytoma with a hypointense FDG-PET, ^{201}Tl

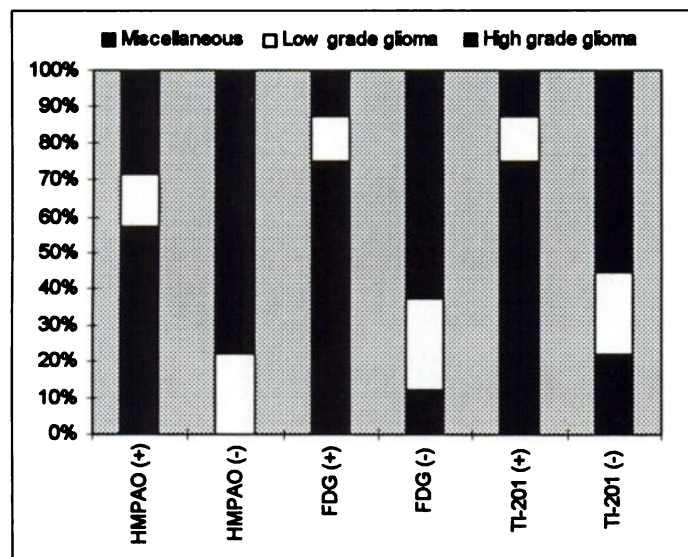


FIGURE 2. Proportion of observations as a function of the group of diseases (high-grade gliomas, low-grade gliomas and miscellaneous diseases) when the markers ^{99m}Tc -HMPAO, ^{18}F -FDG and ^{201}Tl were considered independently.

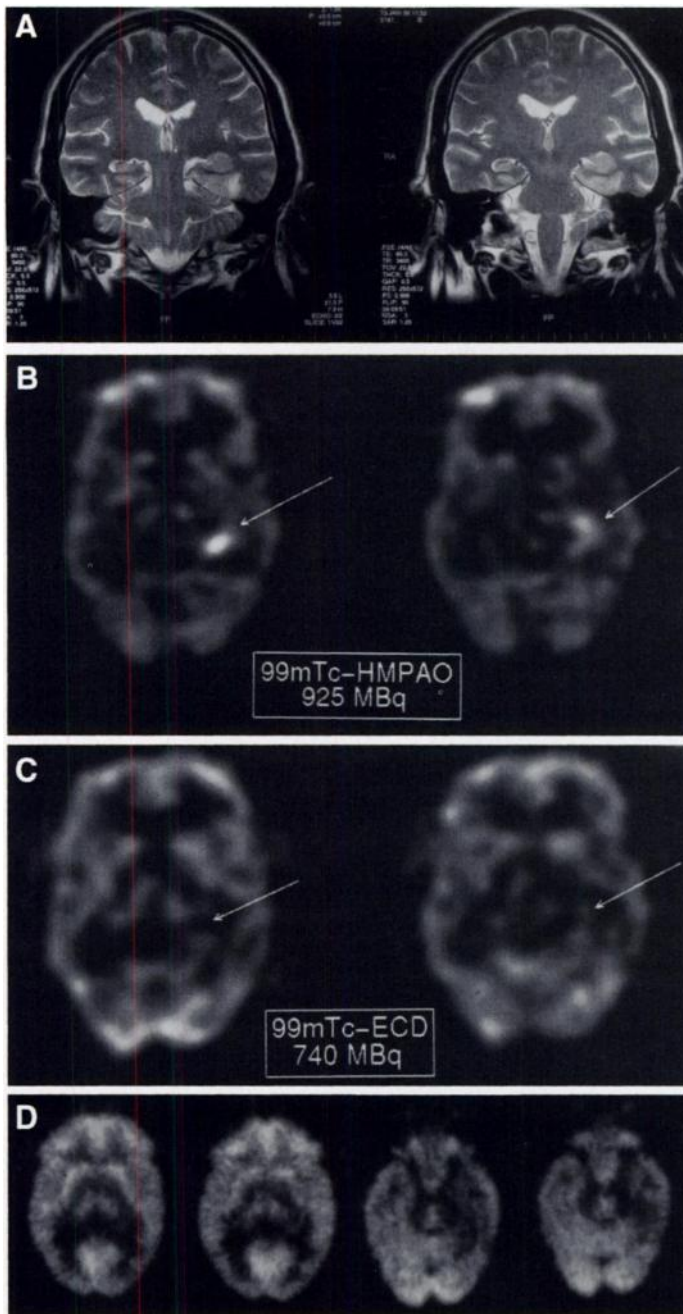


FIGURE 3. Patient with Grade III astrocytoma (Patient 5). (A) On the coronal view of the MRI (T2-weighted sequence), a left-temporal space-occupying lesion with infiltration of the left hippocampus and characteristics of a low-grade glioma is observed. (B) The interictal ^{99m}Tc -HMPAO SPECT shows, on transaxial views, a left internal and posterior temporal lesion with intense uptake of the tracer. (C) The interictal ^{99m}Tc -ECD SPECT shows heterogeneous cortical perfusion without focal abnormality of the left temporal lobe on identical slices, while ^{201}Tl SPECT shows no significant uptake on this lesion similar to the ^{18}F FDG PET image (D) that shows a left internal and posterior temporal defect without hypermetabolic component.

and ECD-SPECT, while only HMPAO-SPECT showed an increased uptake (Fig. 3).

DISCUSSION

Among the different radiopharmaceuticals developed for SPECT imaging of rCBF, ^{99m}Tc -HMPAO and ^{99m}Tc -ECD are currently used for clinical purposes. Both are considered to be similar in reflecting brain perfusion in healthy human subjects (7). However, recent papers report discrepancies between these two radiotracers in patients with vascular cerebral disease such as postischemic reperfusion (8,9). Several authors have already

reported the presence of increased HMPAO uptake in intracranial tumors (13–16), but to our knowledge, our paper is the first to report discrepant observations between ECD and HMPAO SPECT imaging in this particular clinical situation and to propose possible physiopathological mechanisms behind these observations.

Babich et al. have reported two patients of 12 with intracranial tumors and focal hyperperfusion (13). Schwartz et al. brought additional evidence in reporting four of 15 patients with brain tumors and increased HMPAO uptake (17); among them, three patients had local recurrence of irradiated tumors, while one was free of recurrent disease. These observations were related to tumor hyperperfusion, and the falsely positive case was associated with possible transient hyperperfusion postirradiation. In another series of 12 patients, one presented a focal hyperperfusion that was associated with brain infarction of the contralateral hemisphere (18). More recently, Rodriguez et al. studied 21 patients with histologically proven astrocytoma and reported that six of seven patients, before therapy, had increased HMPAO uptake and did not show neurological improvement after therapy. In contrast, only two of nine patients with increased HMPAO uptake before therapy showed neurological improvement after therapy (14). These observations enabled the authors to support the previously stated hypothesis of the relationship between hyperperfusion and increased uptake of HMPAO, and they suggested the use of HMPAO SPECT as a predictor of tumor response to therapy.

The presence of hyperperfusion per se could not explain our discrepant observations of increased HMPAO uptake compared to normal ECD uptake. Although both HMPAO and ECD have been shown to reflect rCBF in normal subjects, the mechanisms involved in their brain tissue retention differ. HMPAO uptake has been related to the intracellular content of glutathione (19), while ECD retention is associated with intracellular (6), as well as membranar esterase activity (20). Furthermore, we have recently reported that, in cell culture, HMPAO cell uptake also is dependent on the redox state of the cell, in addition to the intracellular glutathione content (10,11).

In a tumoral process, a necrotic center is surrounded by intact tumor cells but separated from them by a ring of dying cells in relation to the regional anoxo-ischemic state (21). In this condition, the production of proinflammatory cytokines, in particular tumor necrosis factor alpha (α -TNF), stimulates the activation of inflammatory cells, resulting in oxidative stress and causing intracellular xanthine dehydrogenase to convert into xanthine oxydase. During the metabolism of xanthine or hypoxanthine in uric acid, mediated by xanthine oxydase, there is a generation of oxygen-free radicals, such as superoxide radicals and hydrogen peroxide (22), which alter the intracellular glutathione content as well as the redox equilibrium. Therefore, one can hypothesize that the focal increase of oxygen-free radicals around the central necrotic tumor area will enhance (or even trigger) the cellular retention of HMPAO in a manner independent of rCBF. On the other hand, ECD uptake will be unaffected by these inflammation-promoted metabolic changes.

This study is not considered to be a prospective study in which sensitivity and specificity can be determined. A bias of selection existed, considering the selection criteria, but we know of no reports on increased uptake of ECD in the presence of normal uptake of HMPAO. Therefore, in addition to our preclinical observations, it is sufficient to suggest that the isolated, increased uptake of HMPAO is not rare and may be encountered more frequently in the presence of a brain tumor.

Furthermore, it should encourage the development of a prospective study to assess the value of HMPAO as a criteria of malignancy or a longitudinal study to correlate HMPAO uptake in brain tumors and prognosis.

CONCLUSION

On the basis of these clinical observations and the recent findings concerning cellular mechanisms of HMPAO and ECD metabolisms, we suggest that increased HMPAO retention in brain tumors also could be related to focal metabolic disorders and not only to regional perfusion abnormalities. This hypothesis probably could be extended to other cerebral pathologies, such as inflammatory lesions or cerebral abscesses, in which oxidative stress plays a pivotal role.

ACKNOWLEDGMENTS

We thank Professor Pierre Magistretti for his helpful comments and stimulating discussions and Christine Perron and Eric Fleury for their skillful technical assistance. This research was supported in part by Swiss National Foundation for Scientific Research grant 31-33781.92.

REFERENCES

1. Moretti JL, Caglar M, Weinmann P. Cerebral perfusion imaging tracers for SPECT: which one to choose? *J Nucl Med* 1995;36:359-363.
2. Neirinckx RD, Canning LR, Piper IM, et al. Technetium-99m d,l-HMPAO: a new radiopharmaceutical for SPECT imaging of regional cerebral blood perfusion. *J Nucl Med* 1987;28:191-202.
3. Andersen AR. Technetium-99m-D,L-hexamethylene-propyleneamine oxime (^{99m}Tc-HMPAO): basic kinetic studies of a tracer of cerebral blood flow. *Cerebrovasc Brain Metab Rev* 1989;1:288-318.
4. Newton MR, Austin MC, Chan JG, McKay WJ, Rowe CC, Berkovic SF. Ictal SPECT using technetium-99m-HMPAO: methods for rapid preparation and optimal deployment of tracer during spontaneous seizures. *J Nucl Med* 1993;34:666-670.
5. Walovitch RC, Hill TC, Garrity ST, et al. Characterization of technetium-99m-L,ECD for brain perfusion imaging, part 1: pharmacology of technetium-99m-ECD in nonhuman primates. *J Nucl Med* 1989;30:1892-1901.
6. Walovitch RC, Franceschi M, Picard M, et al. Metabolism of ^{99m}Tc-L,L-Ethyl cysteinate dimer in healthy volunteers. *Neuropharmacology* 1991;30:283-292.
7. Léveillé J, Demonceau G, Walovitch RC. Intrasubject comparison between technetium-99m-ECD and technetium-99m-HMPAO in healthy human subjects. *J Nucl Med* 1992;33:480-484.
8. Tsuchida T, Nishizawa S, Yonekura Y, et al. SPECT images of technetium-99m-ethyl cysteinate dimer in cerebrovascular diseases: comparison with other cerebral perfusion tracers and PET. *J Nucl Med* 1994;35:27-31.
9. Nakagawara J, Nakamura J, Takeda R, et al. Assessment of postischemic reperfusion and diamox activation test in stroke using ^{99m}Tc-ECD SPECT. *J Cereb Blood Flow Metab* 1994;14:S49-S57.
10. Slosman DO, Jacquier M, Pugin J, Rüfenacht DA, Donath A, Polla BS. Nature of the cellular retention of HMPAO and ECD: an in vitro study [Abstract]. *J Nucl Med* 1995;36:254P.
11. Jacquier-Sarlin MR, Polla BS, Slosman DO. Oxido-reductive state: the major determinant for cellular retention of ^{99m}Tc-HMPAO. *J Nucl Med* 1996;37:1413-1416.
12. Townsend DW, Wensveen M, Byars LG, et al. A rotating PET scanner using BGO block detectors: design, performance and applications. *J Nucl Med* 1993;34:1367-1376.
13. Babich JW, Keeling F, Flower MA, et al. Initial experience with ^{99m}Tc-HMPAO in the study of brain tumors. *Eur J Nucl Med* 1988;14:39-44.
14. Rodrigues M, Fonseca AT, Salgado D, Vieira MR. ^{99m}Tc-HMPAO brain SPECT in the evaluation of prognosis after surgical resection of astrocytoma. Comparison with other noninvasive imaging techniques (CT, MRI and ²⁰¹Tl SPECT). *Nucl Med Commun* 1993;14:1050-1060.
15. Lorberboym M, Segal D, Machac J, Sen C, Sacher M. Avid uptake of technetium-99m-HMPAO by an intracranial plasmacytoma during carotid balloon test occlusion. *J Nucl Med* 1995;36:800-803.
16. Grünwald F, Menzel C, Pietsch T, Pavics L, Hufnagel A, Biersack H-J. Increased technetium-99m-HMPAO uptake Grade II astrocytoma. *J Nucl Med* 1995;36:804-806.
17. Schwartz RB, Carvalho PA, Alexander E III, Loeffler JS, Folkerth R, Holman BL. Radiation necrosis versus high-grade recurrent glioma: differentiation by using dual-isotope SPECT with ²⁰¹Tl and ^{99m}Tc-HMPAO. *Am J Neuroradiol* 1991;12:1187-1192.
18. Lindegaard MW, Skretting A, Hager B, Watne K, Lindegaard K-F. Cerebral and cerebellar uptake of ^{99m}Tc-(d,l)-hexamethyl-propyleneamine oxime (HMPAO) in patients with brain tumor studied by single-photon emission computerized tomography. *Eur J Nucl Med* 1986;12:417-420.
19. Neirinckx RD, Burke JF, Harrison RC, Forster AM, Andersen AR, Lassen NA. The retention mechanism of technetium-99m-HMPAO: intracellular reaction with glutathione. *J Cereb Blood Flow Metab* 1988;8:S4-S12.
20. Jacquier-Sarlin MR, Polla BS, Slosman DO. The cellular basis of ECD brain retention. *J Nucl Med* 1996;37:1694-1697.
21. Hall EJ. The oxygen effect and reoxygenation. In: *Radiobiology for the radiologist*, 4th ed. Philadelphia: J.B. Lippincott Co.; 1994.
22. Janssen YMW, Van Houten B, Borm PJA, Mossman BT. Biology of disease: cell and tissue responses to oxidative damage. *Lab Invest* 1993;69:261-274.